

# Lhermitte-Duclos Disease

## Lhermitte-Duclos Hastalığı

M. ZAFER BERKMAN, ŞAFAK ULUER, TURGUT DERİNKÖK

SSK Okmeydanı Hospital Department of Neurosurgery, İstanbul, Turkey

**Abstract:** Lhermitte-Duclos disease is a rare disorder characterized by a slowly enlarging mass lesion in the cerebellum. A case of histopathologically confirmed Lhermitte-Duclos disease is reported and our findings are discussed.

**Key Words:** Cerebellum, displastic gangliocytoma, Lhermitte-Duclos disease

**Özet:** Lhermitte-Duclos hastalığı serebellumda yavaş büyüyen kitle lezyonu ile karakterize patolojidir. Histopatolojik olarak doğrulanmış bir Lhermitte-Duclos hastalığı olgusu bildirilmiş ve bulgularımız tartışılmıştır.

**Anahtar Sözcükler:** Displastik gangliositom, Lhermitte-Duclos hastalığı, serebellum

### INTRODUCTION

Lhermitte-Duclos disease, first described by Lhermitte and Duclos in 1920 (11), is a disease of rarely seen hamartamaous lesion mostly situated within a cerebellar hemisphere, presenting with posterior fossa tumor findings most commonly in young and middle age adults (2-4,7,11,12,14,18,23,25).

Since the exact nature of the pathogenesis is not fully understood, different names have been given to this disease in literature. Gangliomatosis, dysplastic gangliocytoma, benign hypertrophy of cerebellum, diffuse ganglioneuroma of cerebellar cortex, purkinjeoma, hamartoma of the cerebellum, neurocystic blastoma, hamartomablastoma, neurocytoma myelinicum, and gangliocytoma myelinicum diffusum are some of the other names used for this disease (7,10,19,23,26).

We report a case with histopathologically proven dysplastic gangliocytoma in which the

patient had undergone an operation with the diagnosis of posterior fossa tumor.

### CASE REPORT

The patient was a 24-year-old female, complaining of headache, ataxia, and visual disturbances in her right eye.

Her medical history revealed that she had 2 thyroid operations, the first four years ago, and the second one month ago, after which her complaints began.

Neurological examination demonstrated poor tandem gait with ataxia and deviation, dismetria, dysdiadochokinesia to the left side and bilateral papilledema.

Skull x-ray films showed no pathological findings. Computerized tomography (CT) revealed a mass lesion in the left cerebellar hemisphere

extending to superior vermis leading to distortion in the brain stem and the 4th ventricle with the ventral portion contrast-enhanced and resulting with triventricular hydrocephalus (Figure 1).

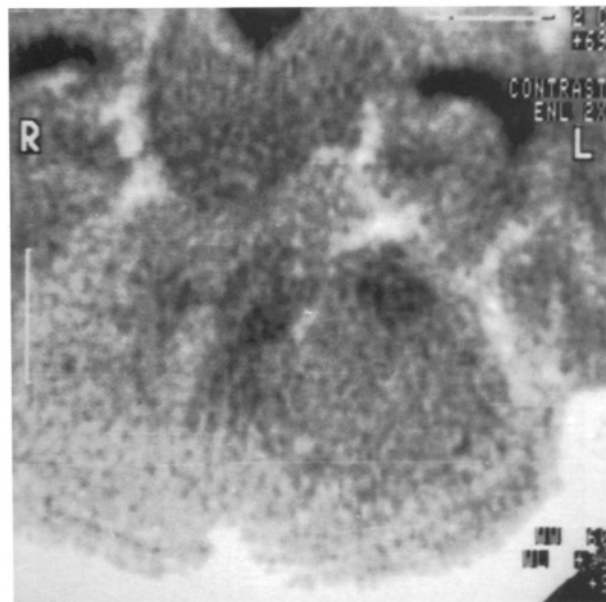


Figure 1. Preoperative CT shows a hypodense mass lesion in the left cerebellar hemisphere leading to the distortion of the 4th ventricle and resulting in the hydrocephalus and the ventromedial part of the lesion a dilated vascular structure.

Magnetic resonance imaging (MRI) demonstrated a lesion on the lateral side of the left cerebellar hemisphere, nonhomogenous iso/hypointense in T1 weighted, hyperintense in T2 weighted sections; excluding the peripheral vascular structures, the parenchyma of the lesion was not contrast-enhanced and its contours were not well defined; the lesion compressed the rostral brain stem and the 4th ventricle. There seemed a dilated vascular structure on ventromedial part of the lesion; triventricular hydrocephalus and a syringomyelic cavity measuring 15x7x7 mm in size extending between C2-C3 levels could be seen (Figure 2). Vertebral angiography revealed a left cerebellar venous angioma in the left inferior cerebellar region, in which radially located veins converged upwards and drained into a broad venous structure (Figure 3).

During surgery, at sitting position, suboccipital craniectomy and C1-C2-C3 laminectomy were performed. When dura was opened the enlarged left cerebellar hemisphere was encountered. Just 1 cm beneath the cortical surface, the tumoral tissue,

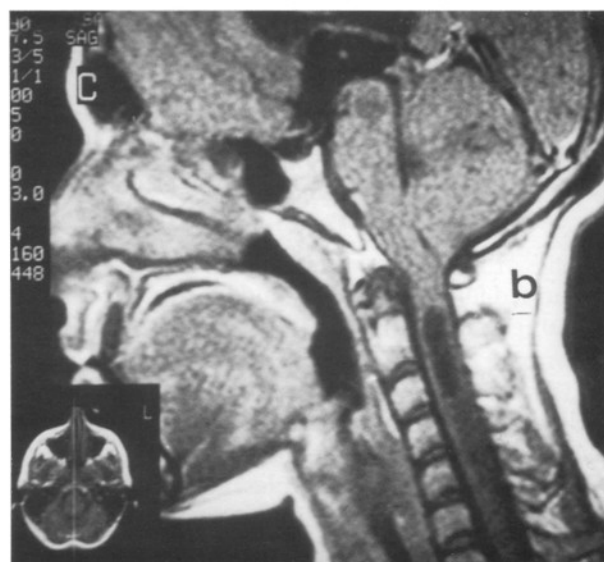
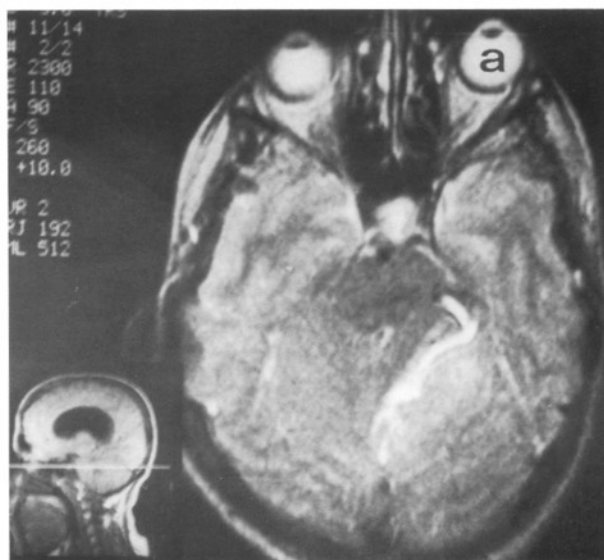


Figure 2 a and b. MRI shows a lesion on the left cerebellar hemisphere localized laterally, hyperintense non-contrast enhanced and compressing the upperbrain stem and the 4th ventricle; and in the ventromedial part of the lesion a dilated vascular structure, triventricular hydrocephaly, and syringomyelic cavity extending between C2-C3 level.

occupying fully 1/3 lateral part of the cerebellar hemisphere, grayish in color, nonhaemorrhagic but including small vascular malformations and partly aspiratable was found and totally excised. The venous angioma ventral to the tumor remained untouched. Then, applying a myelotomy, at C3 level the syringomyelic cavity was connected to the subarachnoid space by placing a shunt connector in between. Torkildsen shunting procedure was

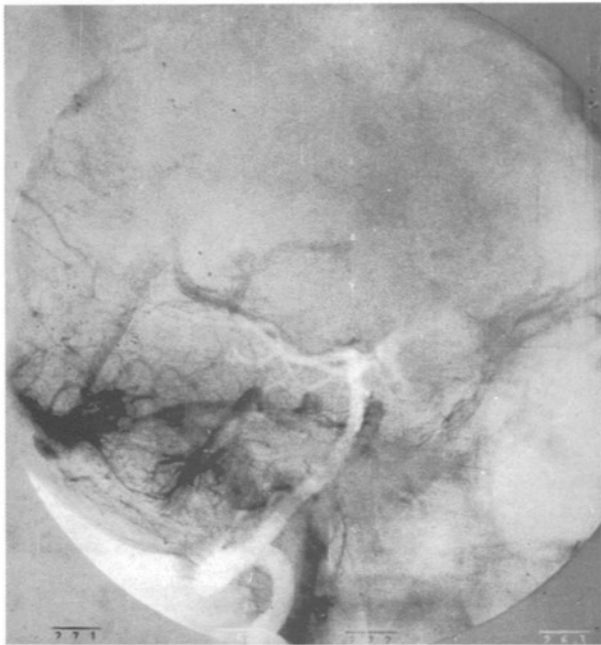

Figure 3. Vertebral angiography shows a cerebellar venous angioma in the left inferior cerebellar region where radially extending veins converge upwards and drain into a broad venous structure.

performed for hydrocephalus and the dura was closed by duraplasty.

Histopathological examination revealed proliferated ganglion cells in the fibrillar stroma, and venous and arterial proliferated vascular formations in the cerebellar tissue samples. No morphological finding designating malignancy was observed. Diagnosis was confirmed dysplastic gangliocytoma and AVM ( Figure 4).

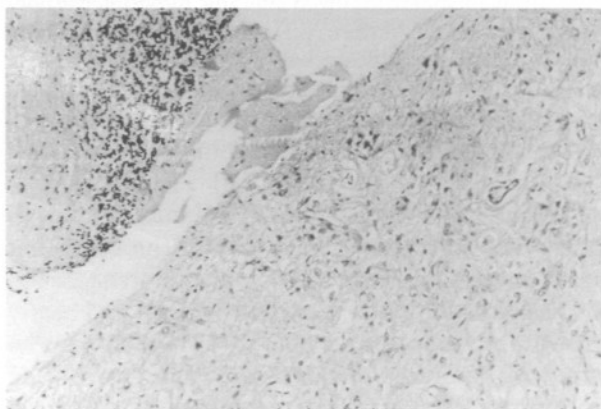


Figure 4. Histopathological features of the lesion illustrating proliferated mature ganglion cells in fibrillar stroma. H&E×40.

She was well after the operation.

Follow up for 4 years reveals that the patient is well without any neuropathological findings. Control MRI has demonstrated no signs of recurrence and hydrocephalus and syringomyelic cavity have disappeared (Figure 5).

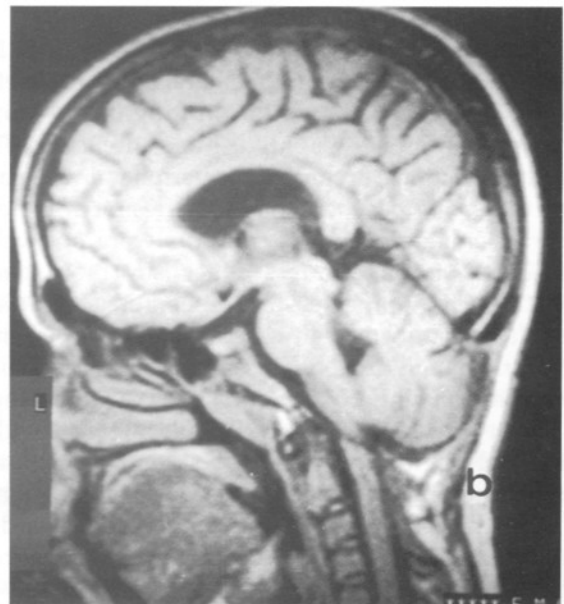
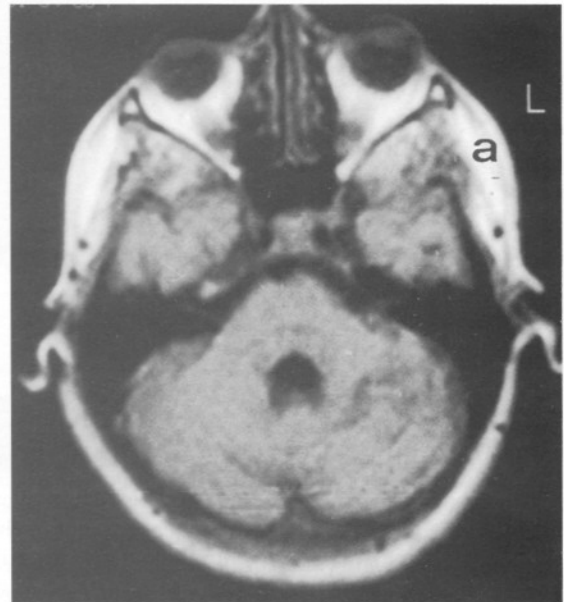


Figure 5 a and b. Control MRI demonstrates no signs of recurrence; hydrocephalus and syringomyelic cavity have disappeared.

## DISCUSSION

Lhermitte-Duclos disease first described in 1920 by Lhermitte and Duclos(11) is a rare benign hamartomatous lesion of the cerebellum (2, 8, 11, 14, 18, 23, 25). Only a few cases have been reported in literature ( 2-4, 6-12, 14-23, 25 ,26).

Whether it is a true neoplasm or a congenital anomaly needs to be investigated but because of the frequently accompanying congenital malformations such as megalencephaly, hydrocephaly, heterotopia, hydromyelia, and less frequently polydactily, neurofibromatosis, mental retardation, spongioblastoma, partial gigantism, metastatic perithelioma, hyperplastic tongue and epilepsy, it is considered a congenital anomaly (6, 7, 15, 17-21, 23). Ambler et al(3) have reported a familial case seen in both the mother and the son. In our case, in addition to hydrocephaly and syringomyelia as a new entity for literature, venous angioma is being reported.

Venous angioma is a vascular malformation, usually asymptomatic, incidentally seen in CT, MRI and in angiography or detected after a SAH or epilepsy. Venous angiomas are particularly localized supratentorially in the frontal or parietal regions, less frequently in the posterior fossa (1, 5, 13, 24).

Lhermitte-Duclos disease, though mostly seen in young adults, has been reported at ages ranging from neonatal period to 74-year-old. It is most frequently seen between the 2nd and the 4th decades (3, 4, 12, 14) . There is no sex predilection (14, 18). The patient in our case was a 24-year-old female.

Lhermitte-Duclos disease gives the typical findings of posterior fossa tumors. Most frequently headache, ataxia, visual disturbance, diplopia, nausea, and vomiting and less frequently paresthesia, neck pain, tinnitus, vertigo, confusion, hemiparesis, and mental changes are findings encountered (7, 12, 23).

Symptom duration ranges between 1 to 30 years, but most often between 1 to 3 years (1, 11, 12). Most commonly, the initial symptoms develop progressively but neurological deterioration can be seen spontaneously or following nonneurosurgical operation as in our case (3). Sudden decompensation and death have been reported in some cases (1, 10). Our case has been admitted due to complaints which arised one month after a guatr operation.

As there is no family history or multisystem organ involvement except for guatr, this disease is differentiated from the Cowden Syndrome, which is autosomal dominantly transfered and characterized by multisystem hamartamatous lesions (2,26).

Lhermitte-Duclos disease can not be definitely diagnosed radiologically before an operation and it presents with increased intracranial pressure and occipital bone deformity findings in direct craniograms (3,15). CT shows hypo or isodense non-contrast enhanced, and sometimes calcified lesions (6-8, 12, 14, 17-19, 22, 25). MRI shows hypoor isointense in T1, hyperintense in T2 non-contrast enhanced posterior fossa mass lesion (7,8,12,14,17, 18,25,26). Angiography reveals a vascular mass lesion (8,22). Radiological findings in our case correlate well with literature.

Histopathologically, a marked reduction in the central white matter, the expansion of the granular layer, hypertrophy of granuler cells, loss of purkinje cells, hypermyelinisation of the molecular layer, and multiple dysplastic ganglion cells in thickened folia can be seen (3,4,7,9, 22,23).

Treatment is surgical and surgical results are satisfactory (3,4,6,10,19,20,22,23). The greatest problem in surgery is the insufficient cleavage in some of the cases (3,4,10,15,17). Only 3 recurrences in the 2nd, 4th and 11th years were reported (4,11,21). The effect of RT is not fully understood and is yet to be investigated (12,13). In literature, there are catastrophic results in the operated posterior fossa venous angiomas so we left it untouched (1,5,24).

In conclusion, the fact that this phenomenon is accompanied by lesions of congenital origin supports the idea that Lhermitte-Duclos disease, which should be considered as the differential diagnosis of posterior fossa masses, is a congenital malformation rather than a tumor.

**Correspondence :** M. Zafer Berkman  
Halaskargazi Caddesi,  
Mimler Apt. No:337, Kat 4  
Şişli, İstanbul, Turkey  
Tel: 212-2344156  
212-2479882  
Fax: 212-2749101

REFERENCES

1. Abe M, Asfora WT, DeSalles AAF, Kjelberg RN: Cerebellar venous angioma with angiographically occult brain stem vascular malformation. Report two cases. *Surg Neurol* 33:400-403, 1990
2. Albrecht S, Haber RM, Goodman JC, Duvic M: Cowden disease and Lhermitte-Duclos disease. *Cancer* 70:869-876, 1992
3. Ambler M, Pogacar S, Sidman R: Lhermitte-Duclos disease (granular cell hypertrophy of the cerebellum): Pathological analysis of the first familial cases. *J Neuropathol Exp Neurol* 28:622-647, 1969
4. Banerjee AK, Gleadhill CA: Lhermitte-Duclos disease (diffuse cerebellar hypertrophy); prolonged post-operation survival. *Ir J Med Sci* 148:97-99, 1979
5. Biller J, Toffol GJ, Shea JF, Fine M, Azar Kia B. Cerebellar venous angiomas. *Arch Neurol* 42:367-370, 1985
6. Brown WR, Angelo JN, Kelly DL Jr: Lhermitte-Duclos disease: Case report with computerized tomographic scan. *Neurosurgery* 6:189-191, 1980
7. Carter JE, Merren MD, Swann KW: Preoperative diagnosis of Lhermitte-Duclos disease by magnetic resonance imaging. Case report. *J Neurosurg* 70:135-137, 1989
8. Grand S, Pasquier B, Le Bas JF,, Chirossel JP: Case report: Magnetic resonance imaging in Lhermitte-Duclos disease. *Brit J Radiol* 67:902-905, 1994
9. Izukawa D, Lach B, Benoit B: Gangliocytoma of the cerebellum: Ultrastructure and immunohistochemistry. *Neurosurgery* 22:576-581, 1988
10. Leech RW, Christoferson LA, Gilbertson RL: Dysplastic gangliocytoma (Lhermitte- Duclos disease) of the cerebellum: Case report . *J Neurosurg* 47:609-612, 1977
11. Lhermitte J, Duclos P: Sur un gânglioneurome diffus du cortex du cervelet. *Bull Assoc Franç Etude Cancer.* 99-107, 1920
12. Marano SR, Johnson PC, Spetzler RF: Recurrent Lhermitte- Duclos disease in a child. Case report. *J Neurosurg* 69:599-603, 1988
13. Martin NA, Wilson CB, Stein BM: Venous and cavernous malformation, in Wilson CB, Stein CB (eds), *Intracranial Arteriovenous Malformations*, Baltimore: William &Wilkins, 1984: 234-45
14. Milbouw G, Born JD, Martin D, Collignon J, Hans P, Reznik M ,Bonnal J: Clinical and radiological aspects of dysplastic gangliocytoma (Lhermitte- Duclos disease): A report of two cases with review of the literature. *Neurosurgery* 22:124-128, 1988
15. Oppenheimer DR: A "benign" tumour of the cerebellum. Report on two cases of diffuse hypertrophy of the cerebellar cortex with a review of nine previously reported cases. *J Neurol Neurosurg Psychiatry* 18:191-213, 1955
16. Özek MM, Zırh TA, Pamir MN, Sav A, Erzen C: Lhermitte-Duclos disease in a young adult case report. *Turk Neurosurg* 1:178-181, 1990
17. Pritchett PS, King TI: Dysplastic gangliocytoma of the cerebellum-an ultrastructural study. *Acta Neuropathol (Berl)* 42:1-5, 1978
18. Reeder RF, Saunders RL, Roberts DW, Fratkin JD, Cromwell LD: Magnetic resonance imaging in the diagnosis and treatment of Lhermitte-Duclos disease (Dysplastic Gangliocytoma of the cerebellum). *Neurosurgery* 23:240-245, 1988
19. Reznik M, Schoenen J: Lhermitte - Duclos disease. *Acta Neuropathol (Berl)* 59:88-94, 1983
20. Rilliet B, Mori Y: Dysplastic gangliocytoma of the cerebellum. *Schweiz Arch Neurol Neurchir Psychiatr* 124:13-27, 1979
21. Roessmann U , Wongmongkolrit T: Dysplastic gangliocytoma of the cerebellum in a newborn: Case report. *J Neurosurg* 60:845-847, 1984
22. Roski RA, Roessman U, Spetzler RF, Kaufman B, Nulsen FE: Clinical and pathological study of dysplastic gangliocytoma: Case report. *J Neurosurg* 55:318-321, 1981
23. Ruchoux MM, Gray F, Gherardi R, Schaeffer A, Comoy J, Poirier J: Orthostatic hypotension from a cerebellar gangliocytoma (Lhermitte-Duclos disease). Case report. *J Neurosurg* 65:245-252, 1986
24. Senegor M, Dohrmann GJ, Wollmann RL: Venous angiomas of the posterior fossa should be considered as anomalous venous drainage. *Surg Neurol* 19:26-32, 1983
25. Siddiqi SN, Fehlings MG: Lhermitte-Duclos disease mimicking adult-onset aqueductal stenosis. *J Neurosurg* 80:1095-1098, 1994
26. Wells GB, Lasner TM, Yousem DM, Zager EL: Lhermitte-Duclos disease and Cowden's syndrome in an adolescent patient. *J Neurosurg* 81:133-136, 1994