

Received: 17.08.2011 / Accepted: 29.09.2011

DOI: 10.5137/1019-5149.JTN.5151-11.3

Transforaminal Epidural Steroid Injection via a Preganglionic Approach for the Treatment of Lumbar Radicular Pain

Lomber Radiküler Ağrının Preganglionik Transforaminal Epidural Steroid Enjeksiyonuyla Tedavisi

Tufan CANSEVER¹, Serdar KABATAS¹, Erdinc CIVELEK¹, Atilla KIRCELLI², Cem YILMAZ³, Murat MUSLUMAN⁴, Demet OFLUOGLU⁵, Hakan CANER³

¹Baskent University, Faculty of Medicine, Department of Neurosurgery, Istanbul, Turkey

²Goztepe Safak Hospital, Department of Neurosurgery, Istanbul, Turkey

³Baskent University, Faculty of Medicine, Department of Neurosurgery, Ankara, Turkey

⁴Sisli Etfal Government Hospital, Department of Neurosurgery, Istanbul, Turkey

⁵Baskent University, Faculty of Medicine, Department of Physical Therapy and Rehabilitation, Istanbul, Turkey

Correspondence address: Tufan CANSEVER / E-mail: drtufan@gmail.com

ABSTRACT

AIM: To evaluate the effectiveness of transforaminal epidural steroid injection (TFESI) for lumbar radiculopathy with respect to effect of injection levels, gender, and age group.

MATERIAL and METHODS: Hundred-fifty-three consecutive patients who underwent to lumbar TFESI were enrolled. The outcomes were measured by using a visual numeric scale (VNS), NASS and EQ-5D. The relationship between possible outcome predictors and the therapeutic effect were evaluated.

RESULTS: All the patients completed the 2nd year follow-up visits. Significant differences were observed between the pre-procedure and post-procedure VNSs, NASS patients' satisfactions scores and EQ-5D ($P < 0.01$) except 1st and 2nd year follow-up ($P=0.12$, $P=0.27$ and $P=0.19$ respectively). Gender (higher in female patients) showed significant effect to pre-procedure VNS ($P=0.04$). An increase in the level number was significantly associated with an increase in the 6th month ($P=0.005$, $P=0.004$ respectively) and the 1st year ($P=0.05$, $P=0.029$ respectively) NASS and EQ-5D. No complication was occurred except discitis in two chronic renal failure patients.

CONCLUSION: Especially in the patients with severe co-morbidities TFESI is an option to provide higher life quality. The clinical course of the success of the TFESI decreases in one year and becomes stable thereafter. In the patients with immune deficiency, the practitioners should always be aware for an infectious complication.

KEYWORDS: Transforaminal, Steroid, Injection, Lumbar, Radiculopathy

ÖZ

AMAÇ: Lomber radikülopatide uygulanan transforaminal epidural steroid enjeksiyonunun (TFESİ) segment sayısı, cinsiyet ve yaş gruplarına göre etkinliğinin araştırılması.

YÖNTEM ve GEREÇLER: Lomber TFESİ 153 hastaya yapıldı. Hastaların sonuçları numerik ağrı skalası (NAS), NASS ve EQ-5D ile değerlendirildi. Sonucu etkileyebilecek faktörler ve bunların sonuçlara etkisi incelendi.

BULGULAR: Hastaların hepsi 2. yıl takiplerini tamamladı. NAS, NASS memnuniyet skalası ve EQ-5D ($P < 0.01$) değerlerinde, birinci ve ikinci yıl değerleri hariç (sırasıyla $P=0.12$, $P=0.27$ ve $P=0.19$) işlem öncesi ve sonrası tüm değerlerde anlamlı fark tespit edildi. Cinsiyet (bayan hastalarda daha yüksek) işlem öncesi VNS üzerinde etkiliydi ($P=0.04$). Segment sayısındaki artışın, altıncı ay ve birinci yıl NASS (sırasıyla $P=0.005$, $P=0.004$) ve EQ-5D (sırasıyla $P=0.05$, $P=0.029$) sonuçlarında anlamlı artışa sebep olduğu gözlemlendi. Kronik böbrek yetmezliğindeki iki hastada gelişen diskitis dışında hastalarda komplikasyon gelişmedi.

SONUÇ: Özellikle ağır kronik hastalıkları olan hastalarda TFESİ, hastaların hayat kalitelerinin yükseltilmesinde önemli bir seçenektir. Hastaların faydalanım oranları bir yıl içinde azalırken birinci yıldan itibaren sabit kalmaktadır. Özellikle bağışıklık problemi olan hastalarda, gelişebilecek enfeksiyon riski açısından tetikte olmak gerekmektedir.

ANAHTAR SÖZCÜKLER: Transforaminal, Steroid, Enjeksiyon, Lomber, Radikülopati

INTRODUCTION

Intervertebral disk herniation and degenerative lumbar spinal stenosis are the two most common causes of lumbosacral radiculopathy (6, 26). Laboratory evidence implicates inflammation of the affected nerve roots in the mechanism of pain (7). The involvement of inflammation has attracted the use of steroids to reduce the inflammation and, thereby, relieve the pain (7).

Lumbar transforaminal epidural steroid injection (TFESI) provides better delivery of medication to the site of radiculopathy with minimal risk of dural puncture.

TFESI, when appropriately performed, should result in significant improvement. These procedures can reduce the patient's pain by 64% to 81%, disability by 60% to 63% and depression by 56%. Considering the low risk and less expensive nature of the procedure, compared to surgical interventions, epidural injections with or without steroids seem to be cost effective (4).

Most of the studies suggest that TFESI has certain efficacy, but offers only short-term relief (2, 11, 13, 15, 22).

We report the effectiveness of preganglionic TFESI approach in patients with low back pain due to either the lumbosacral radiculopathy or stenosis. This study is the update of the study performed by Kabatas et al (12).

MATERIAL and METHODS

The advantages and disadvantages of TFESI were carefully explained to the patients and their families. During a 3-year period from February 2008 to June 2009, 153 consecutive patients (109 (71.2%) female and 44 (29.8%) male patients; mean age, 59.9±15.8 years; range, 22–90 years) who underwent lumbar TFESI at our department were enrolled in our study. Patients were suffering from their symptoms since 16.6± 12.7 months. Thirty-eight (%24.8) patients had TFESI from one, 70 (45.8%) from 2 levels, 30 (19.6%) from 3 levels, 11 (7.2%) from 4 levels and 4 (2.6 %) from 5 levels respectively. The selection criteria for inclusion were: 1. sustaining radicular pain for more than three months in duration; 2. failure of conservative treatment; 3. definitive evidence of nerve root compression with either subarticular or paracentral disk herniation or central canal and/or lateral recess stenosis at the supraadjacent intervertebral disc based on physical examination and magnetic resonance imaging (MRI). The exclusion criteria of study included: motor deficits; cauda equina syndrome; medical problems that contraindicated the procedure; history of an allergic reaction to local anesthetics or corticosteroids; psychogenic disorders; previous spinal surgery and/or ESIs; posttraumatic root compression or infectious etiologies.

TFESIs were performed in our department by one neurosurgeon. The treatment outcome was evaluated by direct questioning. The interviews were conducted by telephone by using the Visual Numeric Pain Scale (VNS), North American Spine Society (NASS) patient satisfaction

questionnaire and (Euro-Qol in 5 dimensions) EQ-5D (28). A nurse who did not know the patient history and the procedure queried the patients for 6 month, one year, two and third year follow-up by using VNS, NASS and EQ-5D.

The procedure

The procedure was performed by the preganglionic approach described by Le et al. (16, 17). They described that for the preganglionic approach, the landmark for needle insertion was slightly lateral to the pars interarticularis on the oblique view, and at the neural foramen near the nerve root impingement site at the supra adjacent disk level on the posteroanterior view. TFESIs were performed in the operation theatre equipped with a planar fluoroscope (Siemens™, Munich, Germany) while the patients were prone. After sterile preparation, draping, and local anesthesia with one per cent lidocaine, a 9-cm long, 21-gauge spinal needle (Stimuquik™ [insulated peripheral nerve block needle]; Arrow International, PA, USA) was advanced towards the involved neural foramen under fluoroscopic guidance. The needle position was tracked via fluoroscopy, and 1 mL of contrast material (Omnipaque 300™ [iohexol, 300 mg iodine per milliliter]; Amersham Health, Princeton, NJ) was injected to confirm epidural flow and to avoid intravascular, intradural, or soft-tissue infiltration. Upon confirmation of reaching the intended injection site, posteroanterior and oblique spot radiographs were obtained to document distribution of the contrast material. Lee et al. (16, 17) described that for the preganglionic approach, the landmark for needle insertion was slightly lateral to the pars interarticularis on the oblique view, and at the neural foramen near the nerve root impingement site at the supra adjacent disk level on the posteroanterior and oblique view (Figure 1A, B). Then 0.5 mL of bupivacaine HCl (Marcaine Spinal 0.5% Heavy™; AstraZeneca, Istanbul) was injected (~1 min), followed by 40 mg (1 mL) of methylprednisolone acetate suspension [Depomedrol™ Eczacibasi Ilac San., Luleburgaz, Kirklareli].

Follow-up and clinical evaluation

The mean follow-up of the patients were 20.70±5.6 months. The Visual Numeric Pain Scale (VNS), North American Spine Society (NASS) patient satisfaction questionnaire and (Euro-Qol in 5 dimensions) EQ-5D were used to evaluate the therapeutic efficacy of TFESIs (12). VNS measured experienced pain with 0 representing no pain and 10 representing the worst pain imaginable. The EQ-5D descriptive system comprises the following 5 dimensions: mobility, self-care, usual activities, pain/discomfort and anxiety/depression. Each dimension has 3 levels: no problems, some problems, extreme problems. A score of 5 was representing best score and 15 the worst score. In NASS classification 1 was representing the fully meeting of patient's expectation, 2 less improvement than the hoped expectation but the patient would undergo the same procedure again, 3 the TFESI helped but the patient would not undergo the same procedure again and 4 the same or worse status with respect to pre-operative status. Patients were evaluated before the procedure and at one week after the procedure. Those who responded favorably to TFESIs

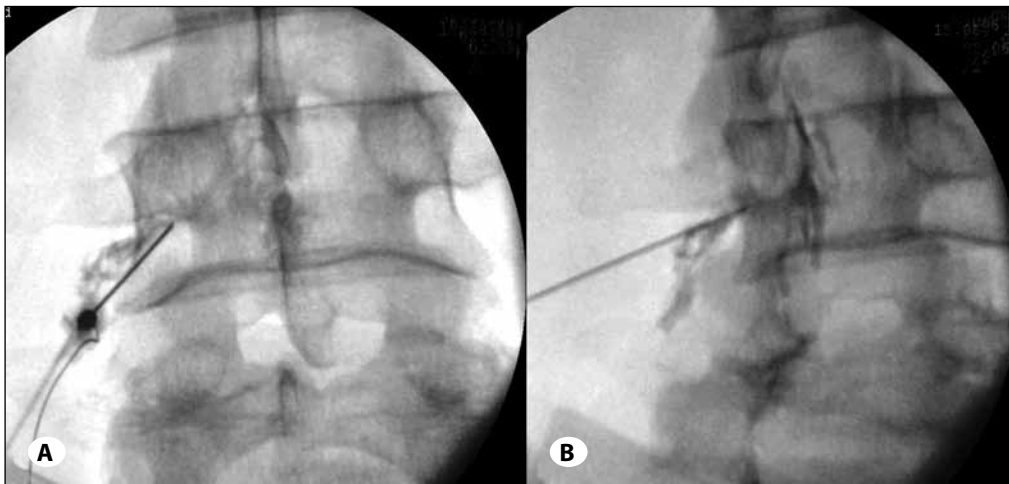


Figure 1: Upon confirmation of reaching the intended injection site, posteroanterior and oblique spot radiographs were obtained to document distribution of the contrast material. The landmark for needle insertion was slightly lateral to the pars interarticularis on the oblique view, and at the neural foramen near the nerve root impingement site at the supra adjacent disk level on the posteroanterior (A) and oblique (B) view.

were then placed in a spine rehabilitation program for four to six weeks to maximize the functional gains. Those who did not respond or responded partially were offered either surgery or physical therapy.

VNS and EQ-5D was recorded at the first clinical examination prior to TFESI. Patients were asked prior to, soon after, and one week after the injections. Patient outcomes were assessed one month after the TFESIs (short term) by a physical therapy and rehabilitation specialist (D. M.) who was blinded to the pre-injection scores. The evaluator used VNS, EQ-5D and NASS patient satisfaction questionnaire to assess the patient's own assessment with regard to the degree of improvement. Patients were then re-evaluated over the phone by a blinded independent observer (A. K.) at 6th month, 1st year and 2nd year. A reduction in the VNS of more than 50% after the injection and with NASS score of 1 and 2 and EQ-5D less than 9 were classified as successful treatment, and a reduction in the VNS of less than 50% after the injection; with NASS score of 3 and 4 and EQ-5D equal and more than 9 were classified as failed treatment. Patients who had subsequent surgery after injection were also deemed to have failed treatment.

Statistical analysis

Data were analyzed by SPSS version 13.0 software. The level of correlation between the pre-procedure and follow-up VNS, EQ-5D and NASS scores were determined using Pearson Correlation test, with $P < 0.05$ with 95% confidence intervals considered statistically significant. The effects of the variables (age, gender, symptom duration, level number pre-op EQ-5D and pre-op VNS) to the results were analyzed using linear regression test, with $P < 0.01$ with 99% confidence intervals considered statistically significant. Paired Samples T test was used to compare the means of the variables (VNS, EQ-5d and NASS) with $P < 0.05$ with 95% confidence intervals considered statistically significant.

RESULTS

All the patients completed the 2nd year follow-up visits. All VNS, EQ-5D and NASS scores were significantly

correlated with respect to their follow-up times ($P < 0.01$). The mean pre-procedure, post-procedure, 1st month, 6th months and 1st and 2nd year post-procedure VNSs (mean±SD) were 9.15 ± 0.44 , 1.12 ± 0.44 , 2.73 ± 1.3 , 3.88 ± 2.15 , 4.47 ± 2.6 and 5.2 ± 2.4 respectively (Figure 2). Significant differences were observed between the pre-procedure and post-procedure VNSs ($P < 0.01$) except 1st and 2nd year follow-up ($P=0.12$). Gender (higher in female patients) showed significant effect to pre-procedure VNS ($P=0.04$). NASS patients' satisfaction scores were 1.1 ± 0.6 , 1.6 ± 1.2 , 1.9 ± 1.4 and 2 ± 1.4 in the 1st month, 6th month, 1st year and second year follow-up's respectively (Figure 2). Significant differences were observed between all follow-up values ($P < 0.001$) except 1st and 2nd year follow-up ($P=0.27$). An increase in the level number was significantly associated with an increase in the 6th month ($P=0.005$) and the 1st year ($P=0.05$) NASS. The mean pre-procedure, 1st month, 6th month and 1st and 2nd year post-procedure EQ-5D scores were 14.5 ± 0.65 , 5.35 ± 1.6 , 6.8 ± 3.1 , 7.7 ± 4.1 and 8.2 ± 4.2 respectively (Figure 2). Significant differences were observed between all follow-up values ($P < 0.001$) except 1st and 2nd year follow-up ($P=0.19$). An increase in the level number was significantly associated with an increase in the 6th month ($P=0.004$) and the 1st year ($P=0.029$) EQ-5D. The success rate of the procedure with respect to follow-up periods was summarized in Figure 2. These were almost consistent and sustainable clinical improvement after TFESI over the 12 months period when VNS, EQ-5D and NASS progressively decreased. However there was no significant decrease in the success rate between 1st year and 2nd year follow-up.

These comparisons indicated that the therapeutic benefits of TFESIs occurred immediately by the injection, and the beneficial effects of TFESIs are decreasing slowly over twelve months and maintain almost stable thereafter (Figure 3).

Three patients required surgery in the first six months after the procedure. No patients required any surgical procedure after the 6th month follow-up.

No complication was occurred except discitis in two patients. Retrospective examination of the data of these patients

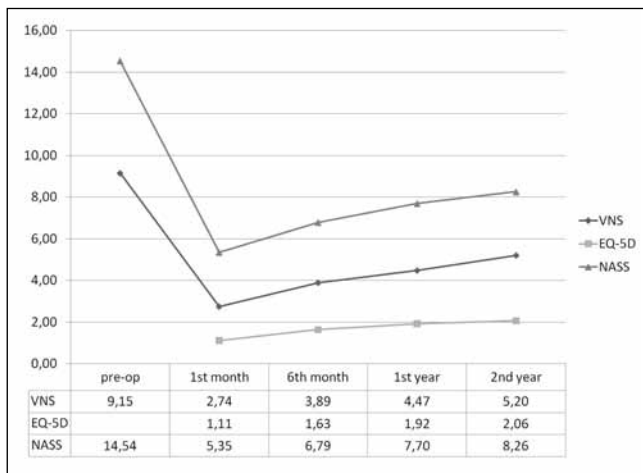


Figure 2: All VNS, EQ-5D and NASS scores respect to months.

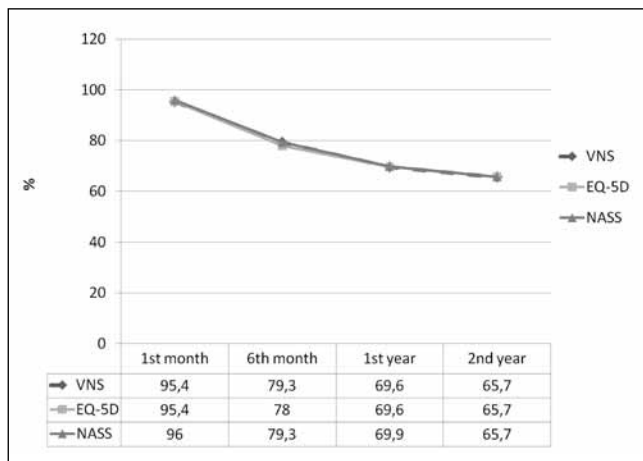


Figure 3: Success ratio of the patients respect to follow-up months.

revealed no insertion of the needle to the intervertebral disc space. However these two patients had immune deficiency due to hemodialysis-dependent chronic renal failure.

DISCUSSION

TFESI (by using a preganglionic technique) provides the injected material closer to the site of neural impingement and allow the delivery of medicine more directly to reduce inflammation and relieve pain (11, 16). Injections of the cocktail containing steroid and local anesthetics provide inhibition of prostaglandin synthesis, stabilization of cellular membranes, and suppression in immune responses, increase in neuronal blood flow, and washing out inflammatory mediators (such as interleukin-1, tumor necrosis factor and phospholipase A2), in addition to block nociceptive C fiber conduction (20, 26). As pain from disc disease is usually generated anteriorly in the epidural space, the ventral epidural spread is the main target for placement of injection fluid containing anti-inflammatory medications. TFESI delivers the injection material directly into the ventral epidural space but is localized in periradicular space of the same side and did not cross the midline and

therefore does not cover the contralateral side (3, 25). We therefore performed the procedure bilaterally if the patient had bilateral symptoms of radiculopathy

Jeong et al (11) concluded that there was no significant difference in therapeutic effect due to symptom duration at short-term (within one month) follow-up. Shorter symptom duration favors a better outcome than does longer symptom duration at midterm follow-up (6 month). This may mean that the patients with longer symptom duration have a tendency toward experiencing recurrent pain attacks. Patients with spinal stenosis exhibited a similar therapeutic effect when compared with those who had intervertebral herniated disk at short-term follow-up (41 of 47, 87.2%) (Table I). Lutz et al. have reported that patients with pre-injection symptom durations of less than 36 weeks were most likely to respond to treatment (18). Viton et al. have found that the decrease in pain was greater for the patients less than 50 years of age than for the older patients after TESI for lumbar radiculopathy (27). In our series, the symptom duration and age of the patients had no significant association with pre-procedural or short term or long term post-procedural clinical status.

One problem of epidural steroid injections is that their benefit lasts only for a short duration (2, 13, 15, 22). Ridley et al (22) reported that the therapeutic benefits disappeared within 6 months of treatment. Jeong et al (11) found a success rate of 60.4% in the patient group at the follow-up interval of more than 6 months. Lutz et al (18) showed that 75.4% of patients who underwent TFESI also had a successful midterm outcome at an average follow-up of 20 months. Other previous prospective randomized trials studying the effectiveness of TFESI concluded that these injections can provide positive long-term relief (24, 26) (Table I). In our series, the success rate was %95.4 in the first months; this rate showed progressive regression in the 6th month (%78) and in the 1st year (%69.6). However, this progression showed decrease between the 1st and the 2nd year (%65.7).

Ghahreman et al. (7) concluded that a significantly greater proportion of patients treated with transforaminal injection of steroid (54%) achieved relief of pain than did patients treated with transforaminal injection of local anesthetic (7%) or transforaminal injection of saline (19%), intramuscular steroids (21%), or intramuscular saline (13%). But over time, only some of the patients maintained relief beyond 12 months. Therefore steroid with local anesthetics was used in our clinic to maintain a longer success.

Initial observational studies showed that TFESI spared patients from surgery (28) or provided greater than 50% relief of pain in over 70% of patients (18). A controlled study confirmed the surgery-sparing effect (24), which persisted at 5-year follow-up (25). Especially in the patients with severe co-morbidities or in the patients with severe clinical symptoms who are very young for a complicated spine surgery, TFESI is a very strong option to provide higher life quality.

Table I: Success Rate of the Similar Series Cited in the Study

EQ-5D	1st month	6th month	1st year	2nd year
Cansever t	95,4	78	69,6	65,7
Jeong et al (11)	87,2	-	60.4	-
Lutz et al (18)	-	-	75.4	-
Ghahreman et al. (7)	-	-	54	-
Riew (24)	-	80.1	-	-

TFESI can be dangerous (1, 14), if carelessly performed. Guidelines for the safe procedure have been published (10), emphasizing particularly the need to be aware of unintended, intra-arterial injection of particulate steroids.

Manchikanti et al. concluded that a common problem encountered with epidural injections is inaccurate needle placement, which also results in inaccurate placement of the injectate (19). This study also showed significant intravascular needle placement (22%), with 5% of the total procedures being negative for flashback, as well as aspiration for blood, even though contrast injection was positive (19). We therefore used the local anesthetics for the test of the needle placement before the steroid injection. If the patients experience any paresis or paresthesia, the needle was replaced again to the optimum position.

Complications from lumbar TFESIs include increased pain, bleeding, dural puncture, subdural injection, damage to the spinal nerve, spinal cord infarction, and infection (14). Infectious complications following commonly performed lumbar TFESI are very rare. However, bacterial meningitis, epidural abscess formation and discitis have all been reported in the literature (8, 21, 29).

Intradiscal contrast injection is an infrequently reported event during lumbar transforaminal epidural steroid injections. The prevalence of inadvertent intradiscal injection during lumbar transforaminal epidural steroid injections was presented as 0.17% in the literature (10) and it was concluded that all of the patients received prophylactic antibiotics after inadvertent disk injection, and there were no infectious or other complications identified (10). In our study, spondylodiscitis was observed in two patients. Both of the patients have the same history of hemodialysis-dependent chronic renal failure. During the procedure inadvertent intradiscal injection was not detected and routine prophylactic antibiotics were given. Additionally, iohexol (omnipaque) by itself is bacteriostatic. This may be due to low immune response of these patients. To our knowledge, this is the first study that showed the chronic renal failure is a risk factor in spondylodiscitis development (two (11%) of the 18 chronic renal failure patients) after TFESI. Discitis resulting from discography procedures averages about 0.1% to 0.3% per patient per procedure (5). In the chronic renal failure patients this ratio was increased to 11.1% in our study. In our all procedures different needles are used for each level, which can potentially decrease the risk of introducing bacteria into a disc. Hooten et al (9) reported

the patients having infectious complications after spinal injections had a history of diseases or were taking medication that impaired immune function.

We were able to identify a limitation of our study. This was a retrospective analysis; we were only able to obtain the data within the medical record. But, most of the data (patients satisfaction scores) were obtained by an independent person who didn't know the patients medical history and the procedure.

CONCLUSION

Especially in the patients with severe co-morbidities or in the patients with severe clinical symptoms who are very young for a complicated spine surgery, TFESI is a very strong option to provide higher life quality. The clinical course of the success of the TFESI decreases in one year and form 96% to 70% however the course becomes stable thereafter. In the patients with immune deficiency the antibiotic prophylaxis can be given for a longer period even though the practitioners should always be aware for an infectious complication.

REFERENCES

1. Bogduk N, Dreyfuss P, Baker R, Yin W, Landers M, Hammer M, Aprill C: Complications of spinal diagnostic and treatment procedures. *Pain Med* 6:511–34, 2008
2. Bogduk N: Spine update: Epidural steroids. *Spine* 20:845–848, 1995
3. Botwin K, Natalicchio J, Brown LA: Epidurography contrast patterns with fluoroscopic guided lumbar transforaminal epidural injections: A prospective evaluation. *Pain Physician* 7:211–215, 2004
4. Buenaventura RM, Datta S, Abdi S, Smith HS: Systematic review of therapeutic lumbar transforaminal epidural steroid injections. *Pain Physician* 12:233-251, 2009
5. Cohen SP, Larkin TM, Barna SA, Palmer WE, Hecht AC, Stojanovic MP: Lumbar discography: A comprehensive review of outcome studies, diagnostic accuracy, and principles. *Reg Anesth Pain Med* 30:163–183, 2005
6. Cyteval C, Fescquet N, Thomas E, Decoux E, Blotman F, Taourel P: Predictive factors of efficacy of periradicular corticosteroid injections for lumbar radiculopathy. *AJNR Am J Neuroradiol* 27:978–982, 2006
7. Ghahreman A, Ferch R, Bogduk N: The efficacy of transforaminal injection of steroids for the treatment of lumbar radicular pain. *Pain Med* 11: 1149–1168, 2010

8. Hooten WM, Kinney MO, Huntoon MA: Epidural abscess and meningitis after epidural corticosteroid injection. *Mayo Clin Proc* 79:682–686, 2004
9. Hooten WM, Mizerak A, Carns PE, Huntoon MA: Discitis after lumbar epidural corticosteroid injection: A case report and analysis of the case report literature. *Pain Med* 7:46–51, 2006
10. International Spinal Intervention Society. Lumbar transforaminal injections. In: Bogduk N, ed. *Practice Guidelines for Spinal Diagnostic and Treatment Procedures*. San Francisco, CA: International Spinal Intervention Society; 2004:163–187
11. Jeong HS, Lee JW, Kim SH, Myung JS, Kim JH, Kang HS: Effectiveness of Transforaminal Epidural Steroid Injection by Using a Preganglionic Approach: A Prospective Randomized Controlled Study. *Radiology* 245: 584-590, 2007
12. Kabatas S, Cansever T, Yilmaz C, Kocyigit Ol, Coskun E, Demircay E, Akar A, Caner H: Transforaminal epidural steroid injection via a preganglionic approach for lumbar spinal stenosis and lumbar discogenic pain with radiculopathy. *Neurol India* 58: 248-252, 2010
13. Patel N: Re, Karppinen J, Malmivaara A, Kurunlahti M, Kyllönen E, Pienimäki T, Nieminen P, Ohinmaa A, Tervonen O, Vanharanta H. Periradicular infiltration for sciatica: A randomized controlled trial. *Spine* 26:1059–1067, 2001
14. Kennedy DJ, Dreyfuss P, Aprill CN, Bogduk N: Paraplegia following image-guided transforaminal lumbar spine epidural steroid injection: Two case reports. *Pain Med* 10:1389–1394, 2009
15. Koes BW, Scholten RJ, Mens JM, Bouter LM: Efficacy of epidural steroid injections for low-back pain and sciatica: A systematic review of randomized clinical trials. *Pain* 63:279–288, 1995
16. Lee JW, Kim SH, Choi JY, Yeom JS, Kim KJ, Chung SK, Kim HJ, Kim C, Kwack KS, Kwon JW, Moon SG, Jun WS, Kang HS: Transforaminal epidural steroid injection for lumbosacral radiculopathy: Preganglionic versus conventional approach. *Korean J Radiol* 7:139–144, 2006
17. Lee JW, Kim SH, Lee IS, Choi JA, Choi JY, Hong SH, Hong SH, Kang HS: Therapeutic effect and outcome predictors of sciatica treated using transforaminal epidural steroid injection. *AJR Am J Roentgenol* 187:1427-1431, 2006
18. Lutz GE, Vad VB, Wisneski RJ: Fluoroscopic transforaminal lumbar epidural steroids: An outcome study. *Arch Phys Med Rehabil* 79:1362–1366, 1998
19. Manchikanti L, Cash KA, Pampati V, Damron KS, McManus CD: Evaluation of lumbar transforaminal epidural injections with needle placement and contrast flow patterns: A prospective, descriptive report. *Pain Physician* 7(2):217-223, 2004
20. Onda A, Yabuki S, Kikuchi S, Satoh K, Myers RR: Effects of lidocaine on blood flow and endoneurial fluid pressure in a rat model of herniated nucleus pulposus. *Spine* 26: 2186–2191, 2001
21. Plastaras CT, Casey E, Goodman BS, Chou L, Roth D, Rittenberg J: Inadvertent intradiscal contrast flow during lumbar transforaminal epidural steroid injections: A case series examining the prevalence of intradiscal injection as well as potential associated factors and adverse events. *Pain Medicine* 11: 1765–1773, 2010
22. Ridley MG, Kingsley GH, Gibson T, Grahame R: Outpatient lumbar epidural corticosteroid injection in the management of sciatica. *Br J Rheumatol* 27:295–299, 1988
23. Riew KD, Park JB, Cho YS, Gilula L, Patel A, Lenke LG, Bridwell KH: Nerve root blocks in the treatment of lumbar radicular pain. A minimum five-year follow-up. *J Bone Joint Surg* 88: 1722–1725, 2006
24. Riew KD, Yin Y, Gilula L, Bridwell KH, Lenke LG, Laurusen C, Goette K: The effect of nerve-root injections on the need for operative treatment of lumbar radicular pain. *J Bone Joint Surg Am* 82-A:1589– 1593, 2000
25. Schaufele MK, Hatch L, Jones W: Interlaminar versus transforaminal epidural injections for the treatment of symptomatic lumbar intervertebral disc herniations. *Pain Physician* 9:361–366, 2006
26. Vad VB, Bhat AL, Lutz GE, Cammisa F: Transforaminal epidural steroid injections in lumbosacral radiculopathy. *Spine* 27: 11–16, 2002
27. Viton JM, Peretti-Viton P, Rubino T, Delarque A, Salamon N: Short-term assessment of periradicular corticosteroid injections in lumbar radiculopathy associated with disc pathology. *Neuroradiology* 40:59-62, 1998
28. Weiner BK, Fraser RD: Foraminal injection for lateral lumbar disc herniation. *J Bone Joint Surg* 79B:804–807, 1997
29. Yue WM, Tan SB: Distant skip level discitis and vertebral osteomyelitis after caudal epidural injection: A case report of a rare complication of epidural injections. *Spine* 28:E209–211, 2003