

Temporary Clamping of External Carotid Artery in Convexity, Parasagittal and Temporal Base Meningioma

Konveksite, Parasagittal ve Temporal Kaide Menenjiyomlarında Eksternal Karotid Arterin Geçici Olarak Kliplenmesi

Yad Ram YADAV¹, Vijay PARIHAR¹, Moneet AGARWAL¹, Pushp Raj BHATELE²

¹NSCB Medical College, Jabalpur MP India, Department of Neurosurgery, Jabalpur, India

²NSCB Medical College and MP CT/MRI Centre, Jabalpur MP India, Department of Radiodiagnosis, Jabalpur, India

Correspondence address: Yad Ram YADAV / E-mail: yadavyr@yahoo.co.in

ABSTRACT

AIM: The management of intraoperative bleeding during removal of a large hyper vascular meningioma is crucial for safe and efficient surgery. Preoperative embolization of meningioma is the best way to reduce vascularity of meningiomas but this technique is not readily available, costly and has its own limitations. The study is aimed to evaluate the use of temporary clamping of external carotid artery to reduce blood loss and operating time during excision of large convexity, parasagittal or temporal base meningiomas.

MATERIAL and METHODS: A prospective study of 115 consecutively operated meningiomas of size 5 cms or more were operated from January 2002 to December 2010. Temporary clamping of external carotid artery was done in 61 while 51 cases were managed without clamping.

RESULTS: There was significant reduction of blood loss, operative time and blood transfusion given in the temporary clipping group compared to non clipping group. There was stitch abscess in two patients each in clamping, and non clamping group. There was no scalp necrosis or mortality in any of the group.

CONCLUSION: Temporary clamping of external carotid artery is a safe, simple and cost-effective alternative to embolization for the surgery of large meningiomas. This can be practiced at all the centers.

KEYWORDS: Carotid artery external, Meningioma, Meningeal neoplasm, Convexity meningioma, Parasagittal meningioma, Ligation

ÖZ

AMAÇ: Hipervasküler büyük menenjiyomların çıkarılması sırasında intraoperatif kanamanın yönetimi etkin ve güvenli cerrahi için en kritik bir konudur. Preoperatif embolizasyon menenjiom vaskülaritesini düşüren en iyi yol olmakla beraber, maliyeti, her yerde bulunmayışı ve kendin mahsus sıkıntıları nedeni ile her zaman kullanılamamaktadır. Çalışmamızda, büyük boyutlu konveksite, parasagittal ve temporal kaide menenjiomlarında eksternal karotid arterin geçici olarak kliplenmesinin kan kaybını azaltıcı ve operasyon süresini düşürücü etkisi incelenmiştir.

YÖNTEM ve GEREÇ: Ocak 2002 ile Aralık 2010 arasında, prospektif olarak 5 cm ve daha büyük boyutlu 115 menenjiyom olgusu ardışık olarak çalışmaya alınmıştır. Olguların 61'inde eksternal karotid artere geçici klip konulurken, 51 olguda geçici klip kullanılmamıştır.

BULGULAR: Geçici kliplenmiş grupta kliplenmeyen gruba göre belirgin şekilde intraoperatif kanamada belirgin azalma, operasyon zamanında kısılma ve yapılan kan transfüzyonu miktarında azalma tesbit edildi. Geçici kliplenmiş ve kliplenmeyen gruptan birer hastada dikiş yeri apsesi gelişti. Her iki gruptaki olgulardan hiçbirinde skalp nekrozu ve mortalite gelişmedi.

SONUÇ: Büyük menenjiyomların embolizasyonuna alternatif bir yöntem olarak, eksternal karotid arterin geçici kliplenmesi basit, güvenilir, etkin ve tüm merkezlerde uygulanabilir bir yöntemdir.

ANAHTAR SÖZCÜKLER: Eksternal karotid arter, Menenjiyoma, Menenjiyal neoplazm, Konveksite menenjiyomu, Parasagittal menenjiyom, Bağlama

INTRODUCTION

The major problem in management of meningioma is increased vascularity of the tumor. The management of intraoperative bleeding during removal of large meningiomas is crucial for safe and efficient surgery. Preoperative embolization of meningioma is the treatment of choice in reducing vascularity (25). This facility is not universally available and the technique has got its own limitations. Vascularity of meningioma

can be reduced by proper use of cautery without prior embolization or by other methods such as radiotherapy, hydrogen peroxide (13) and alcohol injection (8, 14). We all know that there can be significant bleeding from scalp and bone apart from the bleeding from dura matter and the tumor in meningioma surgery. There are reports of massive blood loss from diploic vein while opening of the skull (17). We did not have access to the embolization in our institution until December 2010. Ligation or clamping of external carotid was used in

past and in the recent time in the treatment of meningiomas (15, 20). We therefore used temporary clamping of external carotid artery in 61 convexity, parasagittal and temporal base meningiomas to find out its safety and effectiveness.

MATERIAL and METHODS

This is a prospective study carried out in our institute from January 2002-December 2010. All 115 consecutively operated patients of large size (5 cm or more in diameter) convexity, parasagittal or temporal base meningiomas during the above period were studied. A detailed history and thorough physical examination, including Glasgow coma scale, was carried out. A CT scan was done in all patients (Figure 1) and MRI could be done in 80 patients due to financial restraint. Routine blood and biochemical investigation were done. A MR angiography of neck vessels was done in all the patients to delineate the vascular anatomy and blood supply of meningioma (Figure 2). Patients were divided into clamping or non clamping group. Three patients originally planned for non clamping group required clamping of artery due to excessive bleeding peroperatively and were excluded from the study. All patients were operated under general anesthesia. Ipsilateral external artery was exposed and clamped in the neck, prior to the skin incision of craniotomy. Special precautions were taken to watch for blood supply of the flap during the procedure. The clamp was removed after the complete excision of the tumor. Hemostasis was checked for 10 minutes after the removal of clip. The amount of blood loss, total blood transfused during the procedure and the duration of surgery were recorded.

Patients were observed for any postoperative flap necrosis, local infection and for any other complication. Fifty four patients with huge convexity, parasagittal or temporal base meningiomas, treated during same period, were treated without clipping of external carotid artery. Out of these 3 patients required clamping of external carotid peroperatively due to excessive bleeding from scalp and bone. These patients were excluded from the study. The amount of blood loss, duration of surgery and the amount of blood transfused were recorded and comparisons were done between clamping and non clamping group. Post-operative complications were also recorded. Both the clamping and non clamping groups were comparable in age, sex, neurological status and size of tumor. Same surgeon was involved in the both group surgeries. Postoperative CT scan and MRI scans were done in all the cases (Figure 3).

RESULTS

The youngest and the oldest operated patients were 17 and 62 years old with a mean age of 36 years in clamping group. There were 45 females in clamping group. There were 27 convexity, 28 parasagittal and 6 temporal base meningiomas in clamping group while these were 21, 27 and 3 respectively in non clamping group. The size of meningiomas varied from 5 to 8 cm with an average of 6.42 cm in clamping group while it was ranging from 5 to 7.8 cms with an average of 6.38 cm in non clamping group.

The blood loss ranged from 200 ml to 800 ml with an average of 336.09 (± 102.61) ml in the clamping group. While the blood loss in non clamping group ranged from 600 ml to 1400 ml with an average of 826.96 (± 191.73) ml. The blood loss was significantly reduced in the clamping group compared with non clamping group ($p < 0.0001$).

The amount of blood transfusion given in clamping group was from no transfusion to 700 ml with an average of 375.60 (± 144.10 ml) as compared to 700 ml to 1400 ml with an average of 867.39 (± 207.58) ml in non clamping group. The amount of blood transfusion given in clamping group was significantly lower than in non clamping group ($p < 0.0001$).

The operating time in the clipping group ranged from 135 minutes to 210 minutes with an average of 149.17 (± 15.56) minutes while it ranged from 205 minutes to 360 minutes with an average of 239.35 (± 43.07) minutes in non clip group. The operating time was significantly lesser in the temporary clipping group ($p < 0.0001$).

All the meningiomas except one each in clamping and non clamping groups were totally excised. Small part of tumor going into the partially occluded superior saggital sinus was left behind in both the groups. There was no mortality or scalp necrosis in any of the groups. There were only two cases of superficial skin infection in each group which were managed conservatively.

DISCUSSION

Blood supply from meningioma can be reduced by preoperative radiotherapy (22) intraoperative radiotherapy (4), embolization of the feeding vessel (5,25) and volumetric thermal devascularization (12). Coagulation of feeders supplying meningioma can also be performed during surgery without using any of the above method. Two stage surgeries have been described to reduce blood loss. A case of large sphenoid ridge atypical meningioma that was successfully resected using a combination of two-stage surgery and irradiation (19). In this case the tumor was still hemorrhagic and could be partially resected after the embolization of feeder vessels from the external carotid artery in the first surgery. There was a blood loss of 2,374 ml in first surgery. Second surgery was done after tumor irradiation to reduce blood loss.

Preoperative embolization is an effective method in the treatment of vascular meningioma when blood supply to the tumor is difficult to access at the time of surgery. It can also be done in the patients having supply from internal carotid; however, only few case reports of such embolization are available (2). Developments of better catheters, embolization material and occlusion of vessels to prevent embolization in undesired location have made embolization a safe method.

There are limitations of preoperative embolization like some vessels are unsuitable for embolization (21). In one study, there was no difference in blood loss and operative time in patients with or without embolization in skull base meningioma

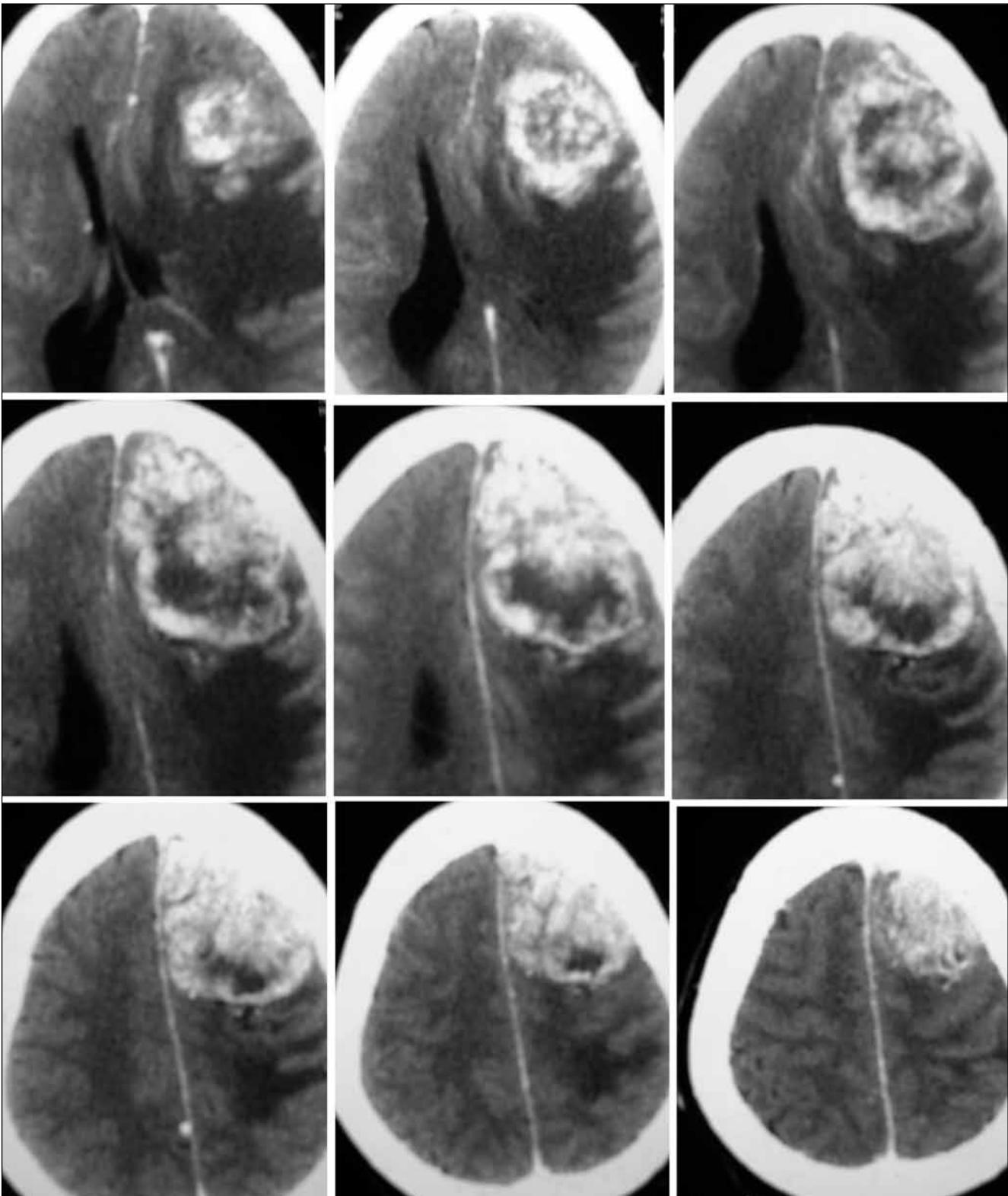


Figure 1: Preoperative axial CT scan of case 10 showing large left frontal meningioma.

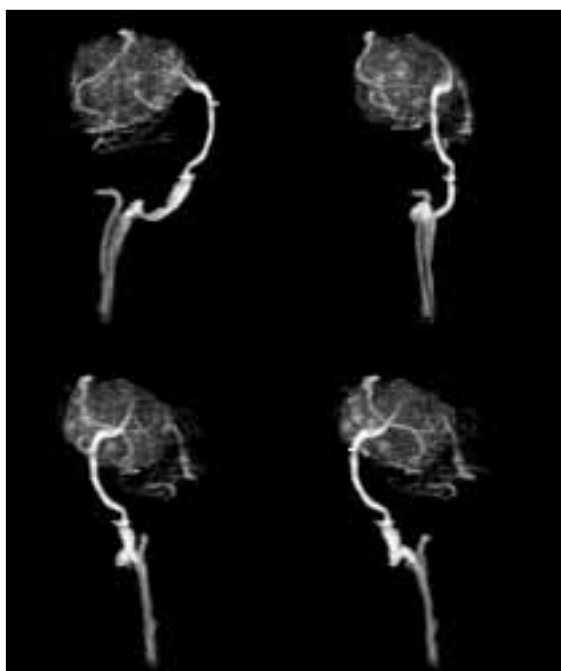


Figure 2: Postoperative axial CT scan showing complete excision of large left frontal meningioma of case 10.

of more than 6 cms size. This was due to many tiny blood vessel feeding tumor which were unsuitable for preoperative embolization (18). In another study, only about 60% tumors were embolized totally or sub totally while rests were partially embolized leaving significant blood supply to the tumor (7). Another limiting factor is its high cost and limited availability. Highly trained interventional neuroradiologists are needed for such a procedure. There are some complications associated with this technique also like death due to thromboembolization (6), necrosis of scalp (1), hemorrhage in tumor, subdural hematoma (3), increase in size of tumor and permanent major neurodeficit (21). Embolization procedure can produce injury to vessels with complications including arterio-venous fistula (23). Sub selective embolization can produce scalp necrosis (16). Hemorrhage in subarachnoid space are more common in large cystic meningioma treated by embolization (11,24). Availability of better catheters, newer embolization materials and expert neuroradiologists has decreased the complication rates in recent years but such facilities are not available at every centre.

Surgery of meningioma can also be done without prior embolization or temporary clamping. But significant blood loss can occur, especially in large meningiomas, from scalp,

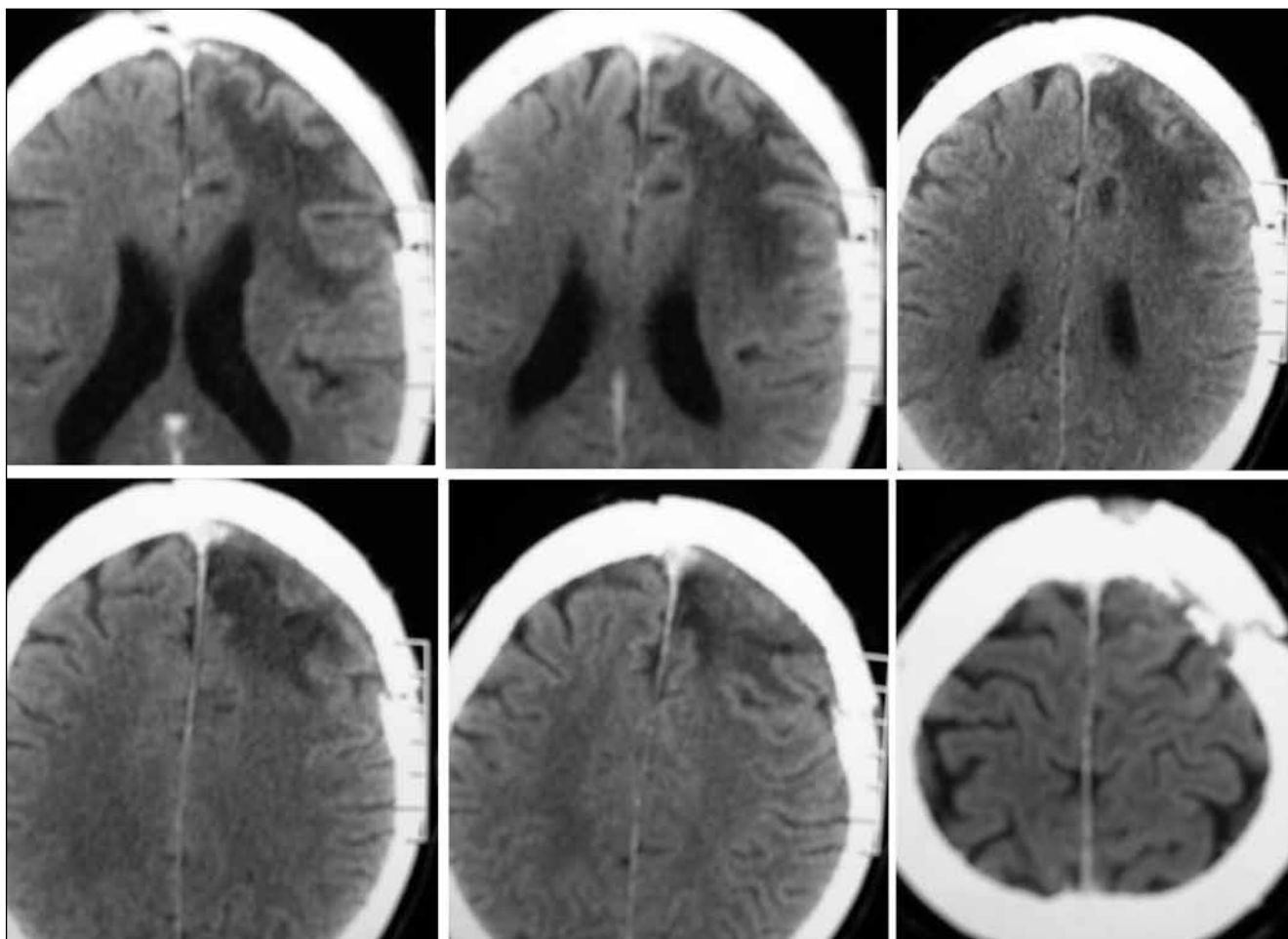


Figure 3: Magnetic resonance angiography showing major blood supply of meningioma from external carotid artery.

bone and dura mater before achieving hemostasis of these structures which is avoidable. The combined blood loss during removal of tumor and prior to tackling of tumor (loss occurring in raising scalp and bone flap) could be crucial for patients ultimate outcome.

The blood supply to all structures like scalp, skull, dura mater and tumor are reduced by the temporary clamping of external carotid artery therefore the total amount of blood loss is reduced in meningioma surgery. The feeders are mainly from external carotid in convexity, parasagittal and temporal base meningiomas. All the feeders, small or big (some of them are unsuitable for embolization), are cut off after the clamping of external carotid artery. The surgeon can release the temporary clip at any point if he or she feels that the vascularity of the flap is compromised. Neurological deterioration, due to increase in tumor size secondary to hemorrhage and necrosis in tumor, seen after pre-operative embolization, especially in huge meningioma, can be avoided. There is no need of an interventional radiologist and coordination of two departments. This method can be very effective in calvarial or extracalvarial meningioma.

There are also some limitations of this procedure also and some precautions need to be taken. It is essential to know detailed anatomy of external carotid artery and its branches preoperatively. It is important to know any anomalous origin of vessel from external carotid or any of its branches which may supply part of the brain (10). There can be good co-lateral circulation from the contra lateral external carotid artery (9,15), ipsilateral internal carotid artery or the vertebral artery leading to a good circulation distal to temporary clipping of the external carotid artery. Blood loss, though less, may occur after clamping of carotid artery in such cases. There is also a theoretical risk of scalp necrosis and increased chances of infection. But in our study, there was no case of scalp necrosis or any increased risk of infection in clamped group. This could be due to better tolerance of decreased blood flow by scalp tissues. It is seen that the tissues can tolerate decrease in blood flow up to 50 %. Temporary clamping of atherosclerotic vessels can give rise to embolic phenomenon and permanent occlusion of vessels, therefore such vessels especially in old patients should be tackled very gently and carefully.

CONCLUSION

The temporary clipping of external carotid artery for very large convexity, parasagittal and temporal base meningioma is an effective and safe alternative method to embolization to reduce blood loss and the operating time.

REFERENCES

1. Adler JR, Upton J, Wallman J, Winston KR: Management and prevention of necrosis of the scalp after embolization and surgery for meningioma. *Surg Neurol* 25:357-360, 1986
2. Arustamian SR, Konovalov AN, Makhmudov UB, Shimanskii VN, Taniashin SV, Edneva IaN, Dedegkaev AV: Preoperative embolization of the internal carotid artery in surgical treatment of meningioma in the base of the anterior and middle cranial fossae. *Zh Vopr Neurokhir Im N N Burdenko* 4: 37-39, 2003
3. Beretta L, Dell'Acqua A, Giorgi E, Napolitano L, Tommasino C, Righi C, Ferrari da Passano C, Motti E: Complications during preoperative embolization in intracranial meningioma. *Minerva Anestesiol* 58:111-114, 1992
4. Cho TH, Chung YG, Kim CY, Kim HK, Lee NJ, Chu JW, Choi MS: Intraoperative radiation therapy as an adjunctive therapy for huge and highly vascular parasagittal meningiomas. *J Korean Med Sci* 15:718-723, 2000
5. Dowd CF, Halbach VV, Higashida RT: Meningiomas: The role of preoperative angiography and embolization. *Neurosurg Focus* 15:E10, 2003
6. Gruber A, Bavinzski G, Killer M, Richling B: Preoperative embolization of hypervascular skull base tumors. *Minim Invasive Neurosurg* 43:62-71, 2000
7. Gruber A, Killer M, Mazal P, Bavinzski G, Richling B: Preoperative embolization of intracranial meningiomas: 17 years single center experience. *Minim Invasive Neurosurg* 43:18-29, 2000
8. Guanghui Wang, Jiman Li, Hong Zhang, Yuping Wu, Yangcheng Lv, Jiang Zhu: Anhydrous ethanol reduces intraoperative hemorrhage of intracranial highly vascularized large meningiomas. *Chinese-German Journal of Clinical Oncology* 9: 344-348, 2010, Online 1-June-2010
9. Hattori K, Miyachi S, Kobayashi N, Kojima T, Hattori K, Negoro M, Yoshida J, Nagasaka T: Contralateral meningeal artery supply of paramedian meningiomas. *Surg Neurol* 64: 242-248, 2005, discussion 248
10. Hayashi N, Kubo M, Tsuboi Y, Nishimura S, Nishijima M, Ahmed Abdel-Aal M, Endo S: Impact of anomalous origin of the ophthalmic artery from the middle meningeal artery on selection of surgical approach to skull base meningioma. *Surg Neurol* 68:568-571, 2007, discussion 571-572
11. Hayashi T, Shojima K, Utsunomiya H, Moritaka K, Honda E: Subarachnoid hemorrhage after preoperative embolization of a cystic meningioma. *Surg Neurol* 27:295-300, 1987
12. Kato A, Fujimoto Y, Taniguchi M, Hashimoto N, Hirayama A, Kinoshita M, Baba T, Maruno M, Yoshimine T: Volumetric thermal devascularization of large meningiomas *Neurosurg* 101:779-786, 2004
13. Lichtenbaum R, de Souza AA, Jafar JJ: Intratumoral hydrogen peroxide injection during meningioma resection. *Neurosurgery* 59(4 Suppl 2):ONS 470-473, 2006
14. Lonser RR, Heiss JD, Oldfield EH: Tumor devascularization by intratumoral ethanol injection during surgery. Technical note. *J Neurosurg* 88:923-924, 1998, Comment in: *J Neurosurg* 91:521-523, 1999

15. Mukherjee KK, Salunke P, Chhabra R, Adhikari S, Bharti N: Temporary bilateral external carotid artery clamping to reduce blood loss during removal of calvarial meningioma: A technical note. *Br J Neurosurg* 25:127-129, 2011
16. Ng SH, Wan YL, Wong HF, Ko SF, Yen PS, See LC, Lin TK, Ho YS: Preoperative embolization of meningiomas: Comparison of superselective and subselective techniques. *Formos Med Assoc* 97:153-158, 1998
17. Ohigashi Y, Tanabe A: A huge frontal meningioma associated with intraoperative massive bleeding and severe brain swelling-case report. *J Clin Neurosci* 8:54-58, 2001
18. Oka H, Kurata A, Kawano N, Saegusa H, Kobayashi I, Ohmomo T, Miyasaka Y, Fujii K: Preoperative superselective embolization of skull base meningiomas: Indications and limitations. *J Neurooncol* 40:67-71, 1998
19. Oi S, Saito K, Ichikawa M, Aimi Y, Okada T, Nagatani T, Shimoyama Y: Case of large sphenoid ridge meningioma treated by 2-stage surgery. *No Shinkei Geka* 36:885-890, 2008
20. Pradit C: Surgery of large skull base meningiomas with the external carotid artery ligation: Local Experience. *Journal of Health Science* 17(Supplement II): 405-410, 2008
21. Rosen CL, Ammerman JM, Sekhar LN, Bank WO: Outcome analysis of preoperative embolization in cranial base surgery. *Acta Neurochir (Wien)* 144:1157-1164, 2002
22. Takahashi J, Makita Y, Nabeshima S, Tei T, Keyaki A, Miyamoto Y: A case of hypervascular meningioma: The effect of preoperative irradiation. *No Shinkei Geka* 16:597-601, 1988
23. Terada T, Nakai E, Tsumoto T, Itakura T: Iatrogenic arteriovenous fistula of the middle meningeal artery caused during embolization for meningioma-case report. *Neurol Med Chir (Tokyo)* 37:677-680, 1997
24. Yu SC, Boet R, Wong GK, Lam WW, Poon WS: Postembolization hemorrhage of a large and necrotic meningioma. *Am J Neuroradiol* 25:506-508, 2004
25. Zhang XB, Jin ZY: Clinical application of presurgical embolization of meningiomas. *Zhongguo Yi Xue Ke Xue Yuan Xue Bao* 25:168-171, 2003