

Recurrent Cerebral Arteriovenous Malformation with a Posterior Inferior Cerebellar Artery Aneurysm

Posterior Inferior Serebeller Arter Anevrizması ile Birlikte Nüks Arteriovenöz Malformasyon Olgusu

Ahmet Murat MUSLUMAN, Halit CAVUSOGLU, Adem YILMAZ, Yunus AYDIN

Şişli Etfal Education and Research Hospital, Clinic of Neurosurgery, Istanbul, Turkey

Correspondence address: Ahmet Murat MUSLUMAN / E-mail: mmusluman@yahoo.com

ABSTRACT

AIM: Cerebral arteriovenous malformations (AVMs) are congenital lesions which rarely recur after complete microsurgical excision.

MATERIAL and METHODS: This case report presents a 35-year-old woman who had been referred with a hemorrhagic AVM five years ago. This patient has recently undergone microsurgical excision for her left parieto-occipital Grade II AVM and surgical clipping of the left posterior inferior cerebellar artery (PICA) aneurysm which was concomitantly detected. She is the oldest case reported whose AVM recurred as Grade III, which is bigger than her first AVM associated with an aneurysm.

CONCLUSION: Although some authors do not propose routine additional follow-up in adults after the initial negative postoperative angiogram, we believe that such patients should be followed clinically and radiologically.

KEYWORDS: Aneurysm, Arteriovenous malformation, Cerebral hemorrhage, Recurrence

ÖZ

AMAÇ: Serebral arteriovenöz malformasyonlar(AVMs) mikrocerrahi eksizyon sonrası nadiren nüks eden konjenital lezyonlardır. Bu makalede beş yıl önce kanama ile başvuran 35 yaşında kadın bir olgu sunulacaktır.

YÖNTEM ve GEREÇLER: Bu hastada sol parieto-okcipital Grade II AVM mikrocerrahi ile eksize edilmiş ve aynı seansta sol posterior inferior serebellar arter (PICA) anevrizması cerrahi ile kliplenmiştir. Olgu şimdiye kadar bildirilen en yaşlı, nüks AVM'u (Gr III) ilk AVM den büyük ve bir anevrizma ile beraber görülen ilk olgudur.

SONUÇ: Bazı yazarlar erişkinlerde ilk negatif postoperatif anjiyogramdan sonra düzenli takip önermese de, bu gibi hastalar klinik ve radyolojik olarak takip edilmelidir.

ANAHTAR SÖZCÜKLER: Anevrizma, Arteriovenöz malformasyon, Beyin kanaması, Nüks

INTRODUCTION

Intracranial AVMs are among the most challenging entities that confront neurosurgeons. The surgical treatment of AVMs of the brain is primarily intended to eliminate the continued risk of serious hemorrhage and progressive neurological deterioration. Complete surgical resection documented by postoperative angiography is believed to eliminate the risk of subsequent hemorrhage (2,6,9). An AVM rarely recurs after its microsurgical resection in adults. Published cases usually belong to the pediatric population (2,8,9,12). In the literature, only five recurrent AVMs have been detected (3,4,5,6,10) where one of them recurred two times (3). No AVM recurrence in a case with aneurysm has been published yet. A case with recurrent AVM bigger than the previous AVM has also not been reported in the literature. This case report presents a 35-year-old woman with recurrent AVM five years after angiographically-demonstrated excision of the first AVM and concomitantly clipped PICA aneurysm. She is also the oldest patient with a recurrent AVM.

CASE REPORT

History. A previously healthy 35-year-old female was admitted to our clinic with complaints of sudden onset of headache, vomiting, and right-sided weakness. She had also webbed vision which began November 2003. On neurological examination right homonymous hemianopsia and 4/5 hemiparesis on the right side were detected. Admission computed tomography (CT) scans were notable for a left occipital lobe hematoma with a rim of surrounding edema. Subsequent catheter angiography revealed a Spetzler–Martin Grade II AVM (size < 3 cm = 1 point, eloquent occipital lobe cortex = 1 point, superficial draining vein = 0 point) supplied by the distal branch of the left middle cerebral artery (MCA), and notable drainage into the superior sagittal sinus. Left vertebral artery angiogram revealed a saccular aneurysm measuring 8 x 4 mm on the left PICA (Figure 1A-E).

First Operation and Postoperative Course. On the fifth day of the hemorrhage, the intracerebral hematoma was drained with

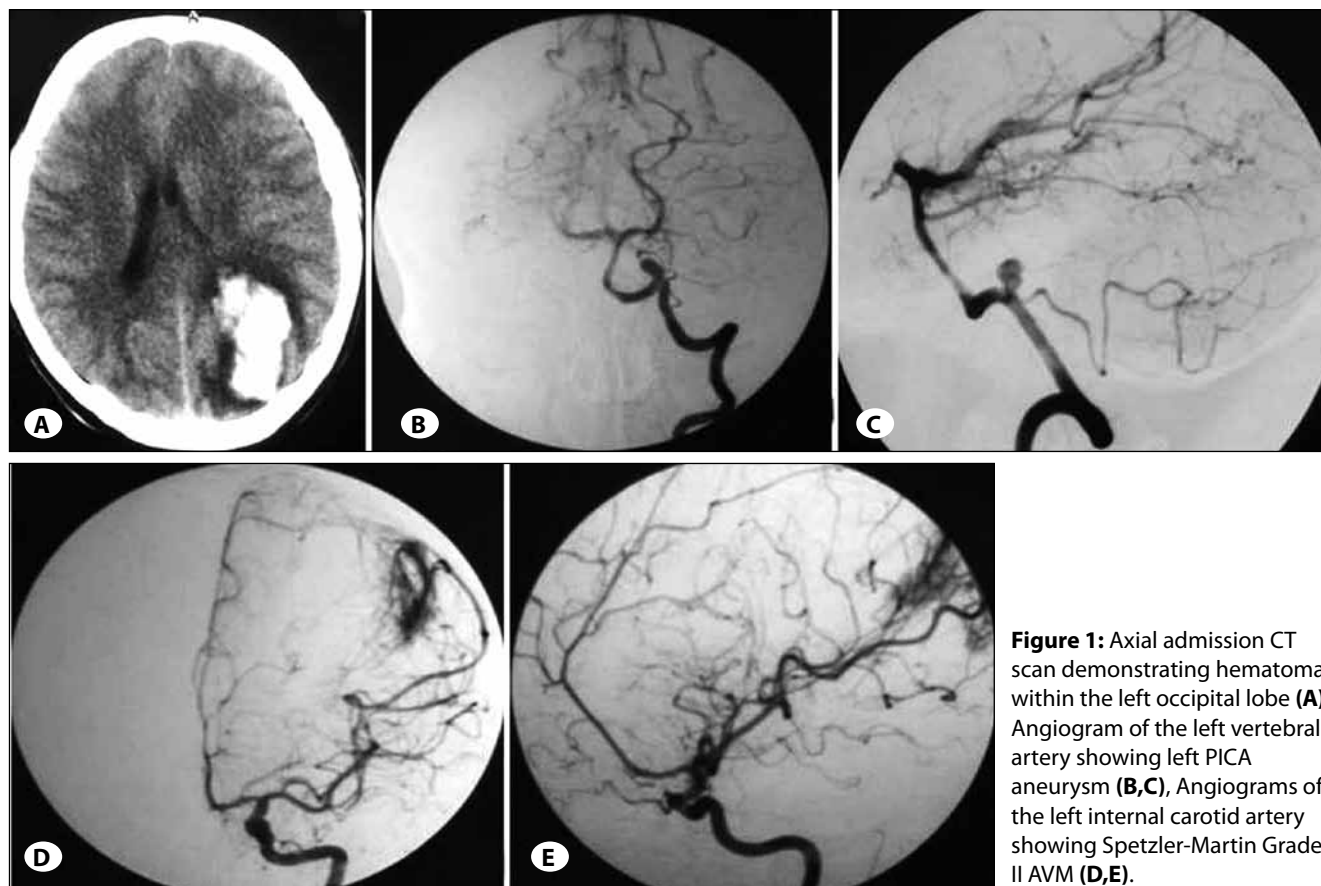


Figure 1: Axial admission CT scan demonstrating hematoma within the left occipital lobe (A), Angiogram of the left vertebral artery showing left PICA aneurysm (B,C), Angiograms of the left internal carotid artery showing Spetzler-Martin Grade II AVM (D,E).

a left parietooccipital craniotomy. The parietooccipital AVM was excised using microsurgical technique. Then left lateral suboccipital craniectomy was performed concomitantly at the same session and PICA aneurysm was clipped with a FE 740T Yaşargil aneurysm clip. No perioperative complication occurred. The early postoperative period was uneventful. Her right hemiparesis resolved completely. Partial improvement of her visual field defect was observed. Control angiography was performed 10 days after surgery. It demonstrated no residual aneurysm and AVM (Figure 2A-E). Histopathological analysis of the surgical specimen verified that the lesion was an AVM. Six months after resection, during tapering of her prophylactic antiepileptic therapy, she developed episodes of visual hallucinations consisting of floating colors and right focal motor epilepsy. Seizures were well controlled with oral antiepileptic drugs.

Recurrence. While the patient was monitored in the neurology clinic because of partial parietooccipital lobe epilepsy, her seizures became more frequent in two months despite dual antiepileptic therapy (Levetiracetam and Carbamazepin). Cranial MRI obtained on April 2008. MRI revealed signal areas with fine tubular structures consistent with AVM on the left parietooccipital region and surrounding gliotic changes. Subsequent catheter angiography was performed on May 2008. Angiography revealed a Spetzler–Martin Grade III AVM (size > 3 cm = 2 point, eloquent occipital lobe cortex = 1 point,

superficial draining vein = 0 point) feeding from the parieto-occipital branch of the left MCA and parieto-occipital branch of the left posterior cerebral artery (PCA), and draining into the superior sagittal sinus. Any filling defect suggesting a left aneurysm of PICA was not detected (Figure 3A-E). Contrary to the first angiogram, AVM increased in size (from 26x22 mm to 36x30 mm), and was feeding from the parieto-occipital branch of the left PCA which was not detected on the first angiogram. During an eleven-year period from 1998 to 2008, 117 operations were performed on patients with intracranial AVM. Of these patients one patient was identified harbouring recurrent AVM.

Second operation and Postoperative Course. AVM excision was achieved through previous craniotomy incision with microsurgical technique on May 2008. The early postoperative period was uneventful. Control angiography performed 10 days later revealed complete removal of AVM (Figure 4A-C). The patient was discharged without any neurological deficit. During one year follow-up, the patient did not experience any seizure.

Pathological examinations. Pathological specimens of case with recurrent AVM obtained during the first and the second operation were stained with conventional crystal violet and A1 immunohistochemical dyes for amyloidosis without any significant finding. Muscular structure of vascular walls was

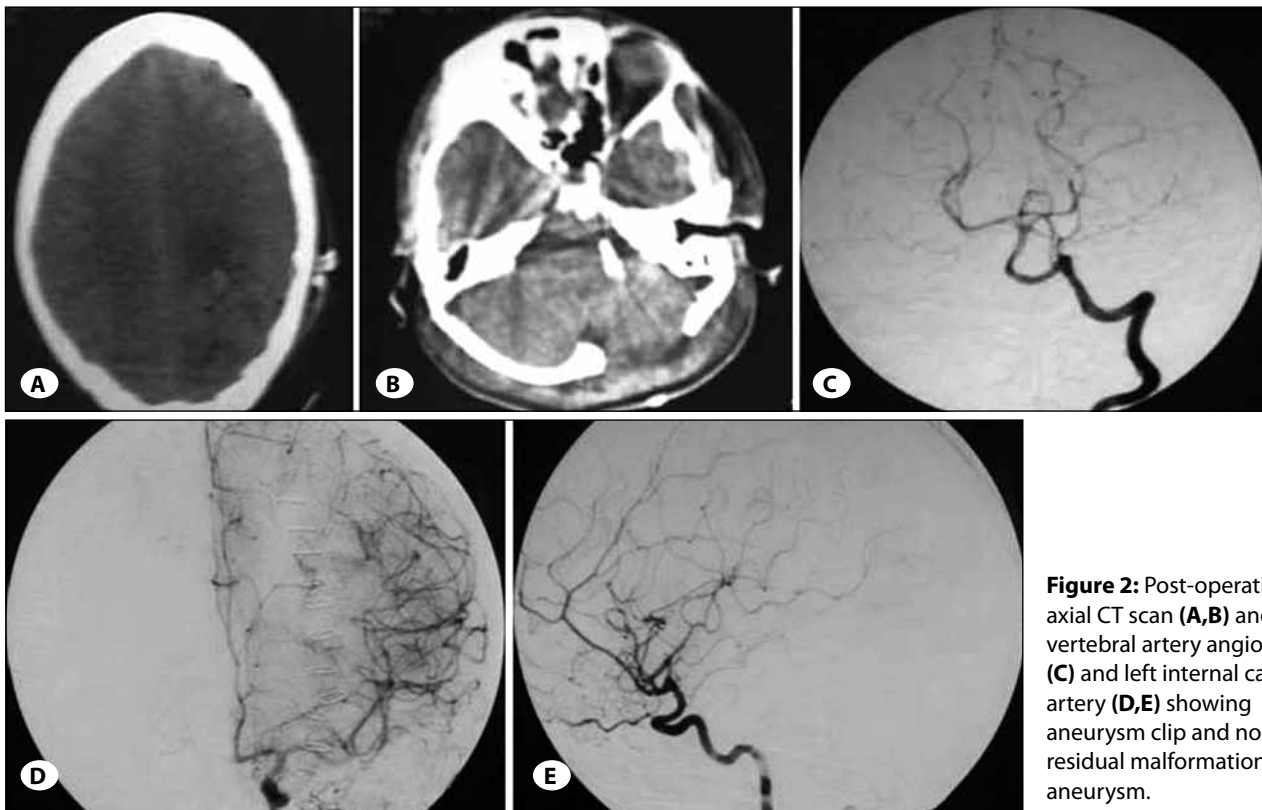


Figure 2: Post-operative axial CT scan (A,B) and left vertebral artery angiograms (C) and left internal carotid artery (D,E) showing aneurysm clip and no residual malformation and aneurysm.

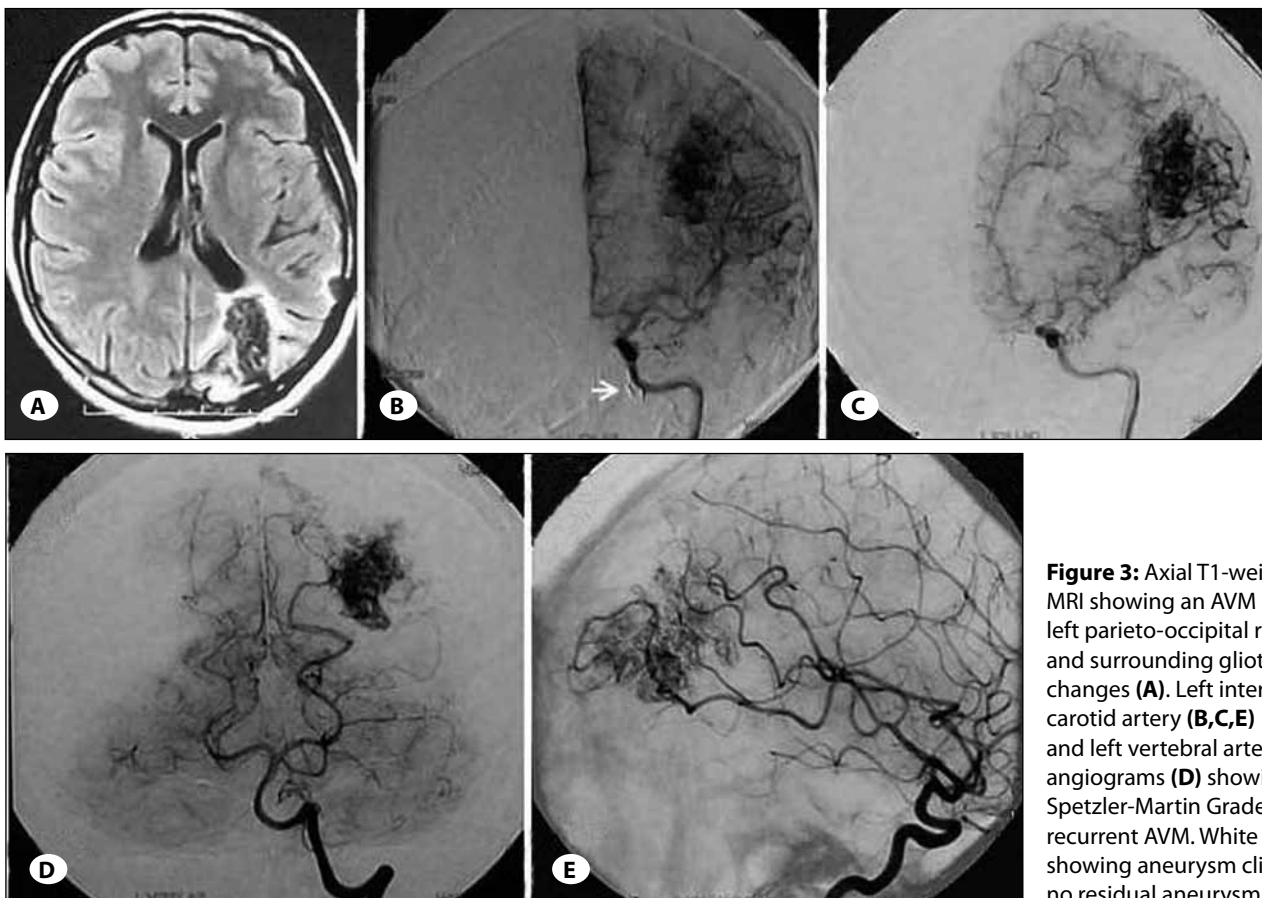


Figure 3: Axial T1-weighted MRI showing an AVM on the left parieto-occipital region and surrounding gliotic changes (A). Left internal carotid artery (B,C,E) and left vertebral artery angiograms (D) showing Spetzler-Martin Grade III recurrent AVM. White arrow showing aneurysm clip and no residual aneurysm (B).

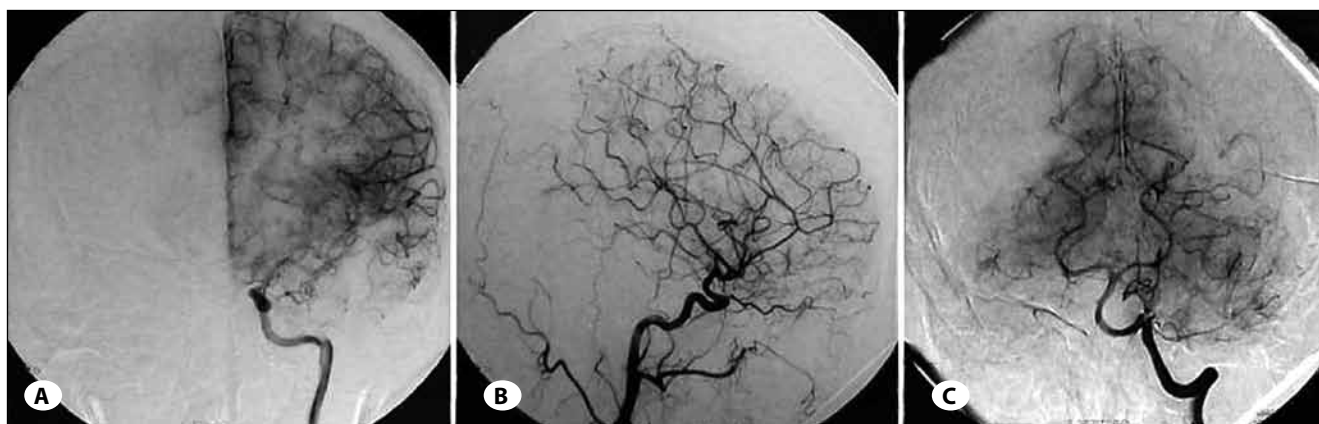


Figure 4: Post-operative left internal carotid artery (A,B) and left vertebral artery angiograms (C) showing no residual malformation.

evaluated as for vasculitis. Conventional elastic Van Giesson-Trichrom staining did not demonstrate any significant finding. The specimen was immunohistochemically stained for VEGF (vascular endothelial growth factor). A pathologically significant staining characteristic was not detected.

DISCUSSION

The primary indication to treat an AVM is to prevent a serious hemorrhage and its associated morbidity and mortality. Angiography is the gold standard for documenting AVM. Patients without residual nidus or early draining veins on postoperative angiograms are considered cured, and thus the risk of hemorrhage is eliminated. Recurrence of an AVM completely excised by microsurgical methods is not expected⁸ and thus routine angiographic controls are not performed during monitorization of the patient. Re-growth of an AVM after its complete removal has been described several times in children (8,9,13). Yaşargil (13) first described a pediatric case of recurrent AVM in a 17-year-old adolescent presenting with intracerebral hemorrhage. This child had negative findings on postoperative angiography with AVM recurrence in the right frontal opercular area 7 years after the initial resection. Only five AVM recurrences in adults have been reported in the literature (3,4,5,6,10). Those recurrent cases were aged between 19 and 33 years and time to recurrence

varied between 4 and 10 years. Our case recurred 5 years later and she was the oldest case reported so far. Adult recurrent AVMs were reported that their size were smaller than first one (Table I). They were feeding with vascular branches which also supplied the first AVM. Gabriel et al. (5) did not state the dimensions of their published case, while they defined the size of the recurrent AVM and indicated that it had identical configuration of the recurrent AVM with a bigger size which was perfused with the same vascular branches. Our recurrent AVM is markedly bigger than the first one and apparently perfused with branches of PCA which were not seen on the first angiogram, the AVM is more reminiscent of a racemose or “juvenile” type lesion.

In our opinion the bigger size of recurrent AVM of our case is due to bleeding of the first AVM. Starting from this point of view the question “are bleeding AVMs in reality bigger than those seen on angiograms?” can be on the agenda. Our answer is “yes”. Our case can give an opinion on this subject. Angiographic imaging obtained from bleeding AVMs is the imaging recruited from the gradient between pressures of cerebral perfusion and hematoma. Also the extracirculatory part of dysmorphic AVM due to bleeding could not be visualized which results in apparently and misleadingly smaller AVM. To demonstrate this issue, comparison of the

Table I: Summary of the Previously Reported Recurrent AVMs in Adults

Author, Year	Presenting complaint	Grade and Size of the first AVM excised	Grade and Size of the recurrent AVM excised	Second recurrence
Gabriel ⁵ , 1996	Bleeding	Gr III, NA	Gr III, 30 x 20 x 25 mm	
Hino ⁶ , 1999	Seizure	Gr I, < 3cm	Gr I, < 3cm (Smaller)	
Santoro ¹¹ , 2000	NA	Gr I, < 3cm	Gr I, < 3cm (Smaller)	
Freudenstein ⁴ , 2001	Bleeding	Gr I, < 3cm	Gr I, < 3cm (Smaller)	
Codd ³ , 2008	Bleeding	Gr III, < 3cm	Gr II, < 3cm (Smaller)	Gr III, < 3cm
Present Case	Bleeding	Gr II, < 3cm	Gr III, > 3cm (Bigger)	

NA = not available

first and the second angiograms obtained after complete resorption of the hematoma in large series of cases will be a beneficial study. Most recurrent AVMs presented with bleeding and there was no late follow-up angiography after first operation. We think that some of bleeding AVMs can not be detected on angiography in a latent period. Bleeding also occurs during excision of AVM and wholeness of AVM is demolished and hemodynamic feature of AVM is changed

Re-growth of AVMs and recurrent hemorrhages from residual AVMs raise an important question regarding the optimum timing for obtaining a postoperative angiogram. Most surgeons agree that angiography should be performed to exclude any residual AVM that may require further treatment (1,7). Current practice is to obtain images as soon as possible following resection to assess the risk of possible postoperative hemorrhage from a residual nidus. If a residual nidus is found, immediate re-exploration should be performed due to the risk of hemorrhage in the early postoperative period. In our clinic, perioperative angiography could not be obtained. Our practice is to obtain angiograms before discharge but after stabilization of the patient. At postoperative clinic visits, patients are advised to undergo angiography five years after surgery. We performed the first angiogram on the postoperative 10 day. Usually by the 7th to 10th postoperative day, edema and vasospasm are less of a concern and should not interfere with the angiographic visualization of a residual AVM. However during postoperative 10 days, the angiogram will possibly appear to be normal due to vasospasm, transient thrombosis in residual AVM, compression on residual AVM due to cerebral edema. According to this theory, subsequent relief of spasm, resolution of edema, or recanalization of feeding vessels may then expand and reveal the residual AVM, resulting in further symptoms or hemorrhage (1,5). If AVM can not resected completely, some residual malformations may not be detected on angiography in early postoperative period. We think that the missed feeders and abnormal vessels in the operation caused AVM to recur in our case. We believe that at the end of the operation very careful inspection should be necessary for the missed abnormal vessels and feeders.

In addition, cranial MRI obtained six months after first operation. MRI revealed no residual AVM in our case. We assume that to be a real recurrence in consideration of intact intraoperative surgical contours, absence of residual nidus or early filling of draining veins. Onset of epileptic attacks on postoperative 6th month, and inability to control seizures completely despite dual antiepileptic therapy suggested that our case demonstrated recurrence in the late postoperative period.

Pelletieri et al. (10) defined hidden compartment theory in AVM recurrence model. This theory suggests that angiographically unfilled areas of an AVM could exist, located either contiguous with or adjacent to a nidus, which can subsequently blossom under the new local hemodynamic state following resection. The authors suggest that this may explain AVM regrowth, and would account for the difference in feeding vessels between the initial and recurrent lesions.

Another explanation, although unsubstantiated, could be the existence of an angiogenic growth factor that promotes the initial development and potential regrowth of these anomalous vessels. Kader et al. (8) hypothesized that AVM growth is not limited to passive abnormal capillary formation during embryogenesis, but is an active angiogenic process that continues through childhood, eventually reaching a "mature" state where growth no longer occurs. These authors also suggest that a resection performed during this active growth stage in patients in whom proangiogenic tissue remains locally following surgery could increase the risk for recurrence. They also propose that proangiogenic factors such as VEGF might play a role in AVM recurrence. A pathologically significant staining of the vascular walls with VEGF immunohistochemical methods was not detected in our case. Conventional and immunohistochemical examinations in consideration of an association of vascular malformations with amyloidosis, vasculitis, and glycogen depot diseases did not reveal any abnormality.

Aneurysms associated with AVMs are reported to occur in 3% to 25% of the cases (11, 13). Aneurysms are generally encountered on feeder arteries of AVM. Intranidal or aneurysm unrelated to AVMs is less frequently seen (12). In our case, an aneurysm unrelated to AVM of the left PICA was detected. Lesions in association with aneurysms and AVM are usually treated at the same session or in accordance with triage. In our case it was possible to treat AVM and aneurysm using two different craniotomy approaches at the same session.

The AVM may recur due to remnant abnormal arteries. Although some authors do not propose routine additional follow-up in adults after the initial negative postoperative angiogram, careful long-term follow-up studies should be planned in such patients. We suggest that the follow-up should be early (1 month) and late (12 months) classical angiography and yearly MRI or CT angiography in order to survey AVM recurrence to detect a higher number of residual or recurrent AVMs. If symptoms and signs consistent with AVM re-growth appear, angiography is indicated.

REFERENCES

1. Ali MJ, Bendok BR, Rosenblatt S, Rose JE, Getch CC, Batjer HH: Recurrence of pediatric cerebral arteriovenous malformations after angiographically documented resection. *Pediatr Neurosurg* 39: 32–38, 2003
2. Andaluz N, Myseros JS, Sathi S, Crone KR, Tew JM Jr: Recurrence of cerebral arteriovenous malformations in children: Report of two cases and review of the literature. *Surg Neurol* 62: 324–331, 2004
3. Codd PJ, Mitha AP, Ogilvy CS: A recurrent cerebral arteriovenous malformation in an adult. *J Neurosurg* 109: 486–491, 2008
4. Freudenstein D, Duffner F, Ernemann U, Rachinger J, Grote E: Recurrence of a cerebral arteriovenous malformation after surgical excision. *Cerebrovasc Dis* 11: 59–64, 2001

5. Gabriel EM, Sampson JH, Wilkins RH: Recurrence of a cerebral arteriovenous malformation after surgical excision. Case report. *J Neurosurg* 84: 879–882, 1996
6. Hino A, Fujimoto M, Iwamoto Y, Takahashi Y, Katsumori T: An adult case of recurrent arteriovenous malformation after “complete” surgical excision: A case report. *Surg Neurol* 52: 156–159, 1999
7. Hoh BL, Carter BS, Ogilvy CS: Incidence of residual intracranial AVMs after surgical resection and efficacy of immediate surgical re-exploration. *Acta Neurochir (Wien)* 146: 1–7, 2004
8. Kader A, Goodrich JT, Sonstein WJ, Stein BM, Carmel PW, Michelsen WJ: Recurrent cerebral arteriovenous malformations after negative postoperative angiograms. *J Neurosurg* 85: 14–18, 1996
9. Kondziolka D, Humphreys RP, Hoffman HJ, Hendrick EB, Drake JM: Arteriovenous malformations of the brain in children: A forty year experience. *Can J Neurol Sci* 19: 40–45, 1992
10. Santoro A, Giuliani S, Paolini S: Recurrent arteriovenous malformation in an adult. Case illustration. *J Neurosurg* 93: 1082, 2000
11. Stapf C, Mohr JP, Pile-Spellman J, Sciacca RR, Hartmann A, Schumacher HC, Mast H: Concurrent arterial aneurysms in brain arteriovenous malformations with haemorrhagic presentation. *J Neurol Neurosurg Psychiatry* 73: 294-298, 2002
12. Yaşargil MG: *Microneurosurgery, Vol III B, AVM of the Brain, Clinical Considerations, General and Special Operative Techniques, Surgical Results, Nonoperated Cases, Caernous and Venous Angiomas, Neuroanesthesia.* New York: Thieme, 369-396, 1988
13. Yaşargil MG: *Microneurosurgery, III A, Stuttgart: Georg Thieme Verlag, 182-189, 1987*
10. Pellettieri L, Svendsen P, Wikholm G, Carlsson CA: Hidden compartments in AVMs - a new concept. *Acta Radiol* 38: 2–7, 1997