

Suitability of Collagen Matrix as a Dural Graft in the Repair of Experimental Posterior Fossa Dura Mater Defects

Deneysel Posterior Fossa Dura Mater Defektleri Tamirinde Kollajen Matriksin Greft Olarak Uygunluğunun İncelenmesi

ABSTRACT

OBJECTIVE: To investigate the suitability of collagen matrix as a dural graft in the repair of experimental posterior fossa dura mater defects.

METHODS: Thirty New Zealand white rabbits were deployed in the study and randomly divided into two groups. In both groups, a 1 cm_ piece of dura mater was excised. The dura mater defect was covered by collagen matrix in the study group and the excised dura mater was sutured up to yield the pre-craniectomy condition in control group. After a follow-up period, the control dura mater and graft zone were excised together with the adjacent cerebellar cortex. Recovery and meningocerebellar adhesions were examined macroscopically and stained sections underwent light microscopy for detection of cellular inflammatory response, fibroblastic proliferation, foreign body reaction and capsule formation.

RESULTS: In the study group, a fibrous membrane indistinguishable from normal dura was observed macroscopically. There was significantly more fibroblastic proliferation in the study group compared to the control group in the first and second months. Foreign body reactions persisted in the control group whereas no reaction was detected in the study group in the third month and this difference was statistically significant. No capsule formation was observed in either group.

CONCLUSION: These findings suggest suitability of collagen matrix for duraplasty in the posterior fossa.

KEY WORDS: Collagen matrix, Duraplasty, Posterior fossa

ÖZ

AMAÇ: Bu çalışmada posterior fossada deneysel olarak oluşturulan dura mater defektlerinin tamirinde dural greft olarak kollajen matriksin uygunluğu araştırıldı.

YÖNTEMLER: Çalışmada 30 adet Yeni Zellanda cinsi beyaz tavşan kullanıldı. Tavşanlar rastgele iki gruba ayrıldı. Her iki grupta 1 cm_ boyutlarında dura mater parçası eksize edildi. Çalışma grubunda dura mater defekti kollajen matriks ile örtüldü. Kontrol grubunda ise eksize edilen dura mater parçası tekrar eski konumuna sütüre edildi. Takip peryotlarının sonunda, kontrol dura mater ve greft uygulanan bölge alttaki serebellum korteksi ile birlikte eksize edildi. Makroskopik olarak iyileşme ve meningoserebellar adezyonlar incelendi. Kontrol ve greft alanlarının makroskopik incelenmesinden sonra dokular histolojik muayene için hazırlandı. Işık mikroskopunda, boyanmış olan kesitlerde; enflamatuar cevap, fibroblastik proliferasyon, yabancı cisim reaksiyonu ve kapsül oluşumu incelendi.

BULGULAR: Çalışma grubunda makroskopik olarak normal dura materden ayırt edilemeyen fibröz bir membranın teşekkül ettiği görüldü. 1. ve 2. aylarda fibroblastik proliferasyon, çalışma grubunda kontrol grubundan istatistiki olarak daha fazla idi. Yabancı cisim reaksiyonları karşılaştırıldığında, 3. ayda kontrol grubunda yabancı cisim reaksiyonunun devam ettiği çalışma grubunda ise, yabancı cisim reaksiyonunun olmadığı görüldü. Bu istatistiksel olarak anlamlı idi. Her iki grupta da tüm takip peryotlarında kapsül oluşumu gözlenmedi.

SONUÇ: Bu bulgular kollajen matriksin posterior fossada duraplasti için uygun olabileceği kanaatine varmamızı sağladı.

ANAHTAR SÖZCÜKLER: Arka çukur, Duraplasti, Kollajen matriks

Bülent ÇETİN¹
Göksin ŞENGÜL²
Yusuf TÜZÜN³
Cemal GÜNDOĞDU⁴
Hakan Hadi KADIOĞLU⁵
İsmail Hakkı AYDIN⁶

1,2,3,5,6 Department of
Neurosurgery and
4 Department of Pathology,
Medical School,
Atatürk University,
Erzurum, Turkey

Received : 07.11.2005
Accepted : 20.12.2005

Correspondence Address
Göksin ŞENGÜL
Aziziye Araştırma Hastanesi
Nöroşirürji S Blok, 25070,
Yenişehir, Erzurum, TURKEY
Phone : +90 442 3166333-2085 (int)
Fax : +90 442 3166340
E-mail : goksinsengul@hotmail.com
gsengul73@yahoo.com

INTRODUCTION

Repair of dural defects and dural closure without a leak is essential in reducing the risk of infection, brain herniation, cerebrospinal fluid (CSF) fistulae, meningocerebral adhesion and brain scarring (2).

Separation of the dura mater during prolonged posterior fossa surgery causes its retraction. In cases where cerebellar swelling is experienced or expected, primary closure is not possible due to the shrinkage of the edges of the dura mater or retraction of the dura making a dural graft necessary (4,15).

An experimental dura mater defect was created in the posterior fossa and suitability of collagen matrix as a graft was assessed.

MATERIAL and METHOD

The Ethical Committee of the Atatürk University Medical School approved the study protocol. Thirty New Zealand white rabbits weighing between 3.5 and 4.5 kg were used. The rabbits were divided into two groups as the study group and the control group. The animals were anesthetized with 5% isoflurane (Florane Liquid, Abbott Laboratories Ltd. Queensborough, Kent, UK) administered by a mask. Anesthesia was continued with 1-3% isoflurane inhalation. An occipitocervical midline incision was made and the bone was disclosed. A 1x1 cm piece of dura mater was excised with utmost care in order not to injure the pia-arachnoid membranes. The defect was covered with collagen matrix (Duragen, Integra, US) exceeding the edges and was soaked with 0.9% sodium chloride in the study group. In the control group, the excised dura mater piece was sutured in place with 6/0 silk suture material yielding the pre-craniectomy condition. Both groups were divided into three subgroups comprising of five rabbits with respect to the 1st, 2nd and 3rd follow-up months. The intervention sites were followed-up in all animals with regard to the development of CSF fistulae, hematoma, infection, and wound recovery.

All animals were anesthetized as described above at the end of the follow-up periods. The rabbits were put to death by intracardiac injection of 10% buffered formalin solution. The incision site was reopened. The bone defect was extended by excision of the craniotomy edges. The dura mater in the control animals and the grafted region in the study animals were excised along with the underlying cerebellar cortex. The control dura mater piece and the graft

region were separated from the cerebellar cortex with forceps and examined for recovery and adhesions. Meningocerebellar adhesions were assessed with the grading system described by Lee et al (0, no adhesion; 1, easily separated adhesions; 2, adhesions requiring minimal dissection; 3, adhesions requiring moderate dissection; 4, tight adhesions causing cortical tears during the removal of the graft) (12).

Following macroscopic examination of the control and graft areas, sections prepared from the tissues were stained with Hematoxylin-Eosin. Inflammatory response, fibroblastic proliferation, foreign body reaction and capsule formation were searched in these sections under the light microscope. Evaluation of the inflammatory response, fibroblastic proliferation, foreign body reaction and capsule formation was based on a grading system modified from the one described by Nordstrom et al (0, none; 1, minimal; 2, moderate; 3, intense) (16). The grading of capsule formation was based on its presence or absence.

Statistical Analysis

Data obtained from the grading of meningeal adhesions and histological responses were analyzed by the Chi-Square test using the Windows adapted SPSS version 10.0.

RESULTS

Macroscopic findings

All wounds recovered without any complications. Dura mater that was excised and re-sutured to its former position joined to the surrounding dura mater completely at the end of the first month in the control group; there was no change in these findings at the end of the second and third months. Collagen matrix began to be absorbed at the end of the first month in the study group and a fibrous membrane lighter and brighter than the intact dura mater developed in the implantation area. This newly formed membrane extended into the dura mater incessantly. Examination of the collagen matrix implantation area at the end of the second month in the study group revealed merging of the surrounding dura mater with the fibrous membrane tightly in a way that could not be distinguished from the dura mater morphologically. In the third month, collagen matrix had been absorbed completely and the newly formed fibrous membrane had blended in the surrounding dura mater, rendering it indistinguishable.

Although meningeocerebellar adhesions were less common in the first month in the collagen matrix group, this finding was not significant ($p = 0.490$). None of these animals had adhesions in the second month and the difference between the two groups was not statistically significant ($p = 0.292$). Neither group had adhesions in the third month.

Histopathological Findings

In the first month, the inflammatory response consisted of mononuclear cells in the collagen matrix group. Although the inflammatory response was more marked in the collagen matrix group compared to the control animals, this difference was not statistically significant ($p=0.766$). Histopathological examination revealed profound invasion of the collagen matrix by fibroblasts, collagen beginning to accumulate in the collagen matrix and collagen matrix being absorbed (Figure 1). Fibroblastic proliferation was more marked in the collagen matrix group than in the control animals ($p=0.030$). In contrast, there was no significant difference between the two groups in terms of foreign body reactions ($p = 0.197$) (Figure 2).

The inflammatory response had decreased by the second month in both groups and mononuclear cells were predominant (Figure 3). Inflammatory responses were equivalent in both groups. The amount of collagen and absorption of the collagen matrix had increased in the collagen matrix group and fibroblastic proliferation had decreased in both groups. Fibroblastic proliferation was more marked in the collagen matrix group compared to the control

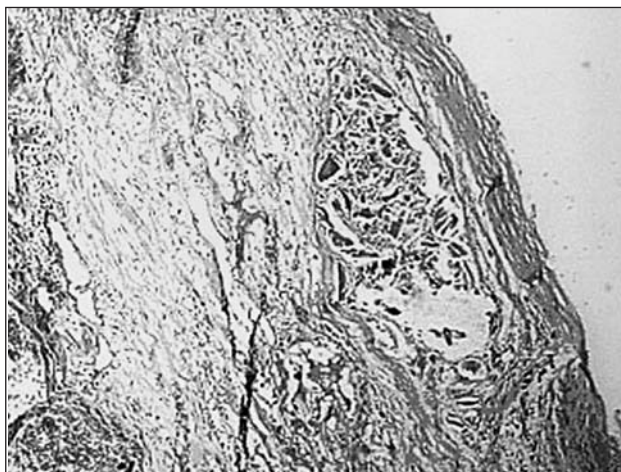


Figure 1: Partial graft residue and granulation tissue in the implant area one month after the implantation of collagen matrix (H & E, x100).

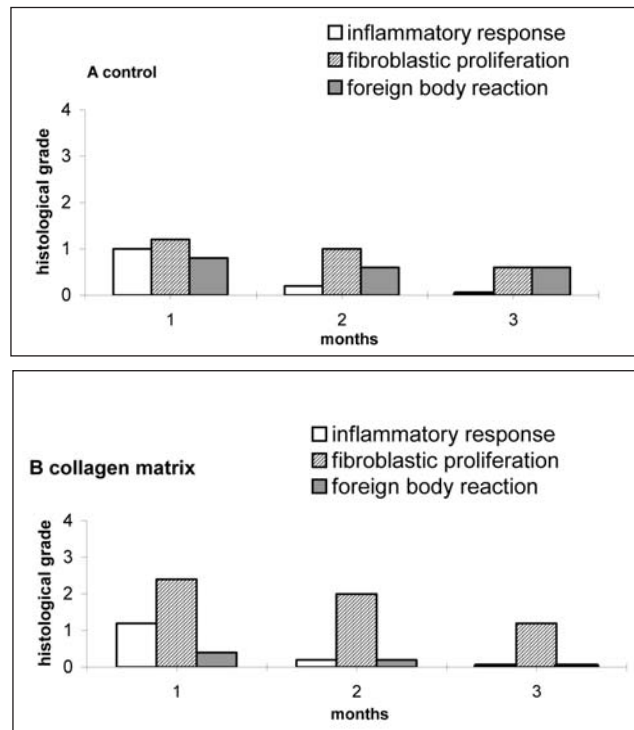


Figure 2: Means of inflammatory response, fibroblastic proliferation and foreign body reaction gradings in the control (A) and collagen matrix (B) groups.

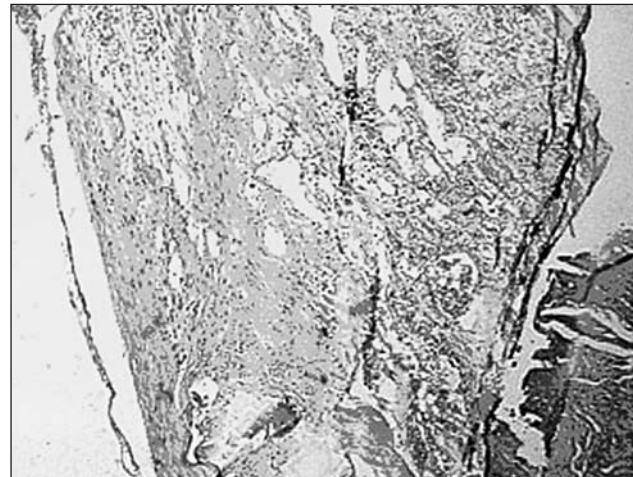


Figure 3: Mild mononuclear cell infiltration and prominent fibroblastic proliferation in the implant area 2 months after the collagen matrix implantation (H & E, x100).

group. Comparison of foreign body reactions yielded no statistical difference between the groups ($p = 0.565$) (Figure 2).

No inflammatory response was present in either group in the third month. Fibroblastic proliferation had decreased in both groups. Intense collagen accumulation was noted in the defect area in the collagen matrix group. Collagen matrix was

absorbed completely. No statistically significant difference was detected between the two groups with regard to fibroblastic proliferation ($p = 0.208$). While foreign body reaction persisted in the control group, there was no foreign body reaction in the collagen matrix group. The difference between the two groups was significant ($p = 0.038$) (Figure 2).

No capsule or neomembrane formation was present in either group throughout the follow-up periods.

DISCUSSION

Closure of a dural defect with fibrous tissue obtained from the operation area (pericranium or temporal fascia) is possible in many cases. Autografts such as pericranium and temporal fascia have many advantages as they are economical, nontoxic and easy to use. They possess excellent biological activities since they are non-immunogenic. Use of the patient's own fascial lath is not a popular procedure due to the requirement for an additional incision, prolongation of the operation time, complications in the donor area, meningocerebral adhesions, and the reluctance of the patients to have a second scar (2,16,20). Although temporal fascia and pericranium are ideal graft materials, they may not be available or obtained in adequate amounts or they may have been disrupted due to trauma or during a surgical intervention. Homologous, heterologous or synthetic graft materials are used in such conditions.

Inert and non-resorbable materials used for closing dural defects have considerable disadvantages as they are foreign bodies, cause intense inflammatory reactions, induce unusual neovascularization with late hemorrhages and hematomas in the long term and cause neural compression (10). Collagen is a resorbable material that has been tested in various forms such as film, layer and sponge (3,12,15). The results of our study indicate that collagen matrix is absorbed completely in the implantation region, and that the fibrous membrane blends into the surrounding dura mater rendering it indistinguishable from the normal dura mater. Elimination of collagen matrix by complete absorption was confirmed microscopically.

The porous nature of the collagen matrix seems to promote fibroblastic proliferation and facilitate dural repair (15). In addition, collagen itself is known to have a chemotactic interaction with fibroblasts. This interaction may aid in the

recolonization of the collagen implant (6,18). Dural repair with tight and usually synthetic materials is performed around the graft (8,18). Closure of the dural defect with these materials depends on the capsulation membrane formed by fibroblasts (21). Since the collagen matrix is porous, dural repair initiates in and proceeds through the graft. Thus, the risk of the capsule enclosing the collagen matrix is low. The porosity of the graft seems to be an essential feature in dural repair (15). Porosity of the graft material is not only responsible for its feasibility but it also allows invasion of the graft by fibroblasts to repair the tissue (11). In our experimental study, the collagen matrix was invaded by fibroblasts to varying degrees due to its porous nature in all animals.

Since the collagen matrix is a graft material used to cover the dura mater defect, the operation period is short. Suturing the graft to the edges of the dura may cause a CSF leak from the needle holes. Collagen has the advantage of eliminating this complication.

In the disruption of the pia-arachnoid layer, meningocerebral adhesions form regardless of the dural repair technique (17). While care was taken not to injure the pia-arachnoid membrane, minimal damage to the arachnoid was present in the animals with adhesions. The possibility of operative injury increases in the presence of cortical adhesions. Thus, graft material to be used for dural repair should either not produce cortical adhesions or form minimal ones. The finding that the number of adhesions formed by the collagen matrix was similar to the ones in the control group that were closed by their own dura maters is significant.

The fact that previously used collagen layers and collagen films caused an inflammatory response, neomembrane formation and meningocerebral adhesion possibly due to the tanning procedure, has created a lack of confidence in their use (7,9,12,14).

We suggest that the foreign body reaction persisting through the third month in the control group is due to the silk suture material used. The nonexistence of capsule and neomembrane formation in the collagen matrix group may be attributed to the porous nature of the collagen matrix and the use of the collagen matrix fibers by fibroblasts as support in the repair process (14). However, repair with many semi-synthetic materials develops around the graft and the graft is

encapsulated (1,8,13,19). Capsule and neomembrane formation may thicken and in the long run, cause neural compression and hemorrhage due to its fragile capillaries (1,5,22).

The shaping of the collagen matrix in the posterior fossa was easily achieved without the use of a time-consuming suturing process in our experimental study. Collagen matrix was found to tolerate permanent cerebellar swelling without increasing the risk of CSF leakage in cases with no hydrocephalus and if the wound is closed carefully layer-by-layer (15).

Collagen matrix seemed to be absorbed completely and was used easily without any suturing. Foreign body reactions were minimal and disappeared in the long term. The intensity of the inflammatory response to collagen matrix was similar to that in the control group. Since there was no pia-arachnoid injury, adhesions did not form. Collagen matrix joined the dura mater and allowed its regeneration successfully. Since neomembrane or graft capsulation was not present owing to the porous nature of the matrix and the use of collagen fibers by fibroblast as a support, hemorrhage from neomembranous fragile capillaries is unlikely.

This study indicates that collagen matrix may be suitable for posterior fossa duraplasty. This technique may be particularly useful in patients in whom primary closure of the dura is not possible due to shrinkage, retraction and excision, or in conditions where the dura should be left open to allow the development of edema.

REFERENCES

1. Adegbite AB, Paine KWE, Rozdilsky B: The role of neomembranes in formation of hematoma around Silastic dura substitute. Case report. *J Neurosurg* 58: 295-297, 1983
2. Caroli E, Rocchi G, Salvati M, Delfini R: Duraplasty: Our current experience. *Surg Neurol* 61: 55-59, 2004
3. Collins RL, Christiansen D, Zananis GA, Silver FH: Use of collagen film as a dural substitute. Preliminary animal studies. *J Biomed Mater Res* 25: 267-276, 1991
4. Fisher III WS, Braun D: Closure of posterior fossa dural defects using as a dural substitute: Technical note. *Neurosurgery* 31: 155-156, 1992
5. Gomez H, Little JR: Spinal cord compression: A complication of silicone-coated dacron dural grafts. Report of two cases. *Neurosurgery* 24: 115-118, 1989
6. Huc A: Collagen biomaterials, characteristics and applications. *J Am Leather Chem* 80: 195-212, 1985
7. Jannetta PJ, Whayne TF: Formaldehyde-treated, regenerated collagen film and film-laminate as a substitute for dura mater. *Surg Forum* 16: 435-437, 1965
8. Keener EB: Regeneration of dural defects. A review. *J Neurosurg* 16: 415-423, 1959
9. Kline DG: Dural replacement with resorbable collagen. *Arch Surg* 91: 924-929, 1965
10. Laquerriere A, Yun J, Tiollier J, Hemet J, Tadie M: Experimental evaluation of bilayered human collagen as a dural substitute. *J Neurosurg* 78:487-491, 1993
11. Laun A, Tonn JC, Jerusalem C: Comparative study of lyophilized human dura mater and lyophilized bovine pericardium as dural substitutes in neurosurgery. *Acta Neurochir* 107: 16-21, 1990
12. Lee JF, Odom GL, Tindall GT: Experimental evaluation of silicone-coated dacron and collagen fabric-film laminate as a dural substitutes. *J Neurosurg* 27: 558-564, 1967
13. Macfarlane MR, Symon L: Lyophilized dura mater: experimental implantation and extended clinical neurosurgical use. *J Neurol Neurosurg Psychiatry* 42: 854-858, 1979
14. Narotam PK, van Dellen JR, Bhoola K, Raidoo D: Experimental evaluation of collagen sponge as a dural graft. *Br J Neurosurg* 7: 635-641, 1993
15. Narotam PK, van Dellen JR, Bhoola KD: A clinicopathological study of collagen sponge as a dural graft in neurosurgery. *J Neurosurg* 82: 406-412, 1995
16. Norstrom MR, Wang TD, Neel III HB: Dura mater soft-tissue augmentation: Evaluation in rabbit model. *Arc Otolaryngol Head Neck Surg* 119: 208-214, 1993
17. Penfield WG: Meningocerebral adhesions. A histological study of the results of cerebral incision and cranioplasty. *Surg Gynecol Obstet* 39: 803-810, 1924
18. Postlethwaite AE, Seyer JM, Kang AH: Chemotactic attraction of human fibroblasts to type I, II and III collagens and collagen-derived peptides. *Proc Natl Acad Sci USA* 75: 871-875, 1978
19. Pudenz RH, Odom GL: Meningocerebral adhesions. An experimental study of the effect of human amniotic membrane, amnioplastin, beef allantoic membran, cargin membrane, tantalum foil and polyvinyl alcohol films. *Surgery* 12: 318-344, 1942
20. Reddy M, Schöggel A, Reddy B, Saringer W, Weigel G, Matula C: A clinical study of a fibrinogen-based collagen fleece for dural repair in neurosurgery. *Acta Neurochir* 144: 265-269, 2002
21. Sakas DE, Charnvises K, Borges LF, et al: Biologically inert synthetic dural substitutes. Appraisal of a medical-grade aliphatic polyurethane and a polysiloxane-carbonate block copolymer. *J Neurosurg* 73: 936-941, 1990
22. Simpson D, Robson A: Recurrent subarachnoid bleeding in association with dural substitute. Report of three cases. *J Neurosurg* 60: 408-409, 1984