

# Traumatic Spondylolisthesis of the Axis Treated with Direct C2 Pars Screw

## Aksisin Travmatik Spondilolistezisinde Direkt C2 Pars Vidası ile Tedavi

### ABSTRACT

**OBJECTIVE:** The optimal treatment modality for traumatic spondylolisthesis of the axis is still a controversial issue. Many conservative, posterior and anterior fixation techniques have been used to treat these injuries. The C2 pars (isthmus) was used as a novel screw anchor point in upper cervical spine injuries. The direct C2 pars screws are also used to fixate the posterior and anterior parts of the C2 vertebra.

**METHODS:** Four cases with traumatic spondylolisthesis of the axis were presented. The cases were classified as type II according to Levine and Edwards' classification. C2 pars was used to fixate the posterior C2 elements to the C2 body.

**RESULTS:** While a direct C2 pars screw was used for C2 fixation in two cases, a C2 pars-C3 lateral mass screw-plate system was used in the remaining two cases. A clinical and radiological improvement was achieved in all cases.

**CONCLUSION:** It is concluded that the C2 pars can be used as screw-bone interface in upper cervical spine traumas. The direct C2 pars screw can fixate the C2 in well-selected cases. The additional C2-3 fixation increases the C2-3 stability.

**KEYWORDS:** Direct C2 pars screw, Hangman fracture, Traumatic spondylolisthesis of the axis

### ÖZ

Aksisin travmatik spondilolistezisinde optimum tedavinin ne olduğu halen tartışmalıdır. Bu travmalarda birçok konservatif tedavi yönteminin yanı sıra, posterior ve anterior fiksasyon teknikleri de tanımlanmıştır. Öte yandan C2 vertebraasının pars bölümü (isthmus) üst servikal omurga yaralanmalarında fiksasyon noktası olarak kullanılmaktadır. C2 pars vidası bu bölgede tek başına da kullanılarak C2'nin anterior ve posterior bölümlerinin birbirine fiske etmektedir.

**YÖNTEM:** Levine ve Edwards sınıflamasına göre tip 2 olarak değerlendirilen dört C2 travmatik spondilolistezis olgusu sunulmaktadır. Olguların dördünde de C2 pars vidası kullanılmıştır.

**BULGULAR:** İki olguda yalnızca C2 pars vidası ile yetinilirken, diğer iki olguda C2 pedikül-C3 yan kitle vidası ile C2-3 stabilizasyon yapılmıştır. Tüm olgularda klinik ve radyolojik iyileşme sağlanmıştır.

**SONUÇ:** Bu çalışma üst servikal yaralanmalarda C2 pars bölümünün fiksasyon noktası olarak kullanılabilirliğini göstermiştir. İyi seçilmiş olgularda C2 pars vidası ile C2'nin ön ve arka bölümleri birbirlerine fiske edilebilirken, C2-3 fiksasyonunun ise C2-3 stabilitesini artırabileceği sonucuna varılmıştır.

**ANAHTAR SÖZCÜKLER:** Aksisin travmatik spondilolistezisi, Direkt C2 pars vidası, Hangman kırığı

Sedat DALBAYRAK<sup>1</sup>

Mesut YILMAZ<sup>2</sup>

Mustafa FIRIDIN<sup>3</sup>

Sait NADERİ<sup>4</sup>

- 1,2,3 Lütfü Kırdar Research and Training Hospital, Neurosurgery Clinic, İstanbul, Turkey  
4 Ümraniye Research and Training Hospital, Neurosurgery Clinic, İstanbul, Turkey

Received : 10.01.2009

Accepted : 02.03.2009

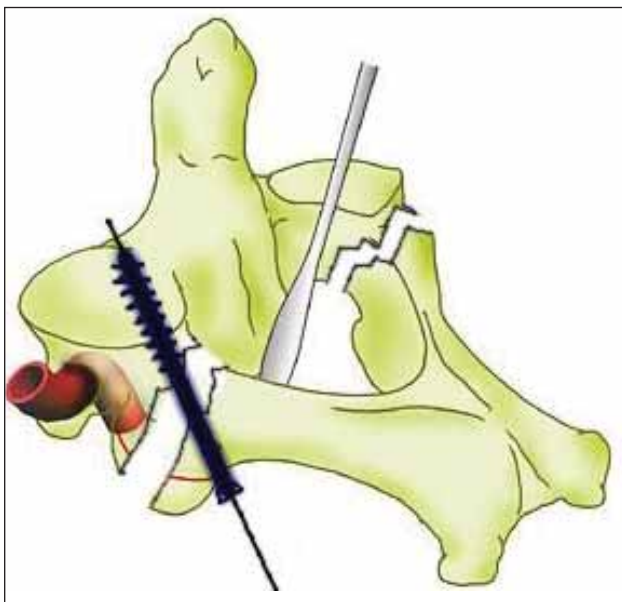
Correspondence address:

Sedat DALBAYRAK

E-mail: sedalbayrak@yahoo.com

**INTRODUCTION**

Traumatic spondylolisthesis of the axis (TSA), also known as Hangman fracture, is one of the well-known injuries involving the upper cervical spine. It has various stable and unstable types. The treatment spectrum includes a variety of non-surgical treatments using collars and halo, and various surgical treatments (14). Despite developments in the diagnosis and surgical technologies, the optimum surgical treatment of choice remains controversial. The classical anterior approaches include anterolateral and transoral C2-3 discectomy and fusion techniques (23). The posterior techniques include C1-2 or C2-3 stabilization techniques (2,4,9,15). Recently C2 pedicle and pars have been an appropriate point of fixation during posterior upper cervical spine surgery (11,24,25). (Figure 1). The use



*Figure 1: The technique of the C2 pars screw fixation. Note that the C2 pedicle should be palpated using a fine dissector after removal of soft tissues.*

of pedicle and pars as a part of complex upper cervical spine instrumentation encouraged spine surgeons to use these points for fixation of the anterior and posterior parts of the C2 vertebra (5,10,12,17,19-21). This, on the one hand, provides a good fixation of the C2 vertebra, and also preserves the C1-2 and C2-3 motion segments. The aim of this study was to review the results obtained from the C2 pars screw in four cases with TSA.

**MATERIALS and METHODS**

The clinical, radiological and surgical aspects of four cases with TSA were reviewed. The pain severity was assessed using the VAS score, the neurological score using the ASIA score, and the radiological assessments were performed using plain cervical spine radiographs, cervical spine CT and MRI. The C2-3 spondylolisthesis was measured using the distance between the lines parallel to posterior walls of C2 and C3 vertebral bodies, and the C2-3 angulation was measured as the angle between the lines joining the C2 inferior end plate and C3 superior endplates.

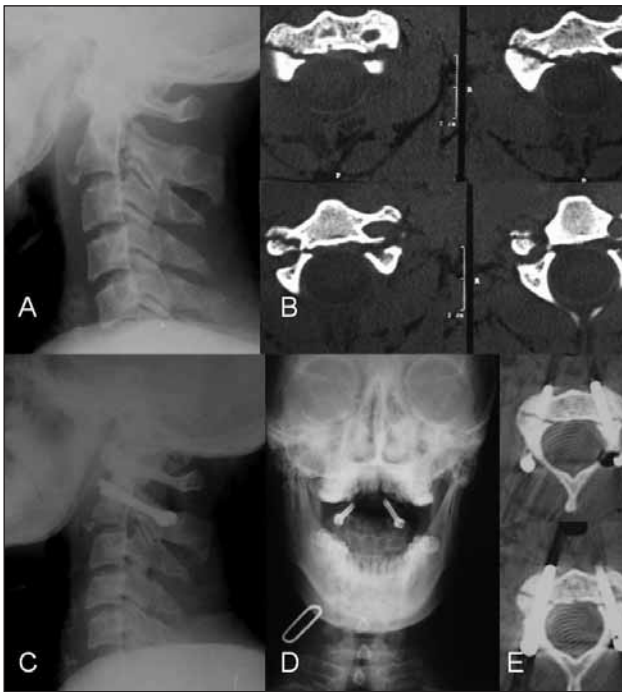
**RESULTS**

The clinical, radiological and surgical aspects of the cases were listed in table I. There were four cases, including two male and two female patients. The patients' ages ranged between 23 and 47 years (mean 34 years). The cases were admitted to the hospital 2 to 18 days after the trauma. The trauma was due to a traffic accident in two cases and due to falling in two cases. All cases presented with pain. The VAS scores ranged between 7 and 9 (mean 7.75). The ASIA score was found to be E in three cases and C in one case. The C2-3 spondylolisthesis was measured between 2 to 8 mm, and the angulation rate was found to be 0-22 degrees. Surgical treatment included direct pars screw in two cases (Figure 2) and C2 pars-C3 lateral

**Table I:** The clinical, radiological and surgical details of the four operated cases.

Age	sex	Type	NS-pre	VAS-pre	Slip-pre	Angle-pre	NS-PO	VAS-PO	Slip-PO	Angle-PO	Surgery
23	F	II	E	7	8	21	E	3	1	0	C2 DPS
25	M	II	E	8	2	0	E	0	0	0	C2 DPS
42	M	II	E	7	6	11	E	1	1	0	C2-3 fix.
47	K	II	C	9	4	0	D	0	1	0	C2-3 fix.

Note: F: Female, M: Male, Type: the type of fracture according to Levine and Edwards classification, NS-pre: Neurological status before surgery according to ASIA classification, VAS-pre: The severity of pain according to VAS score, slip-pre: the amount of C2-3 slip in mm before surgery, Angle-pre: C2-3 angle before surgery, NS-PO: Neurological status after surgery according to ASIA classification, VAS-PO: The severity of pain according to VAS score after surgery, slip-PO: the amount of C2-3 slip in mm after surgery, angle-PO: C2-3 angle after surgery, DPS: Direct pars screw, C2-3 fix: C2-3 fixation.



**Figure 2:** A case treated with direct pars screw fixation. Plain radiographic (A) and computed tomographic (B) images showing TSA. Postoperative plain radiographs (C, and D), and computed tomographic images (D) show the fixation of the C2 posterior elements to the C2 anterior elements.

mass screw-plate fixation in two cases. VAS scores reduced to 0 in two cases, to 1 in one case and reduced to 3 in one case (mean 1). Neurological state improved to ASIA D in a case with C score before the surgery. The slip amount reduced to 0 in one, and to 1 mm in three cases. The C2-3 angulation reduced in all cases. The follow-up ranged from 8 to 40 months (mean 24 months). Fusion was achieved in all cases.

**DISCUSSION**

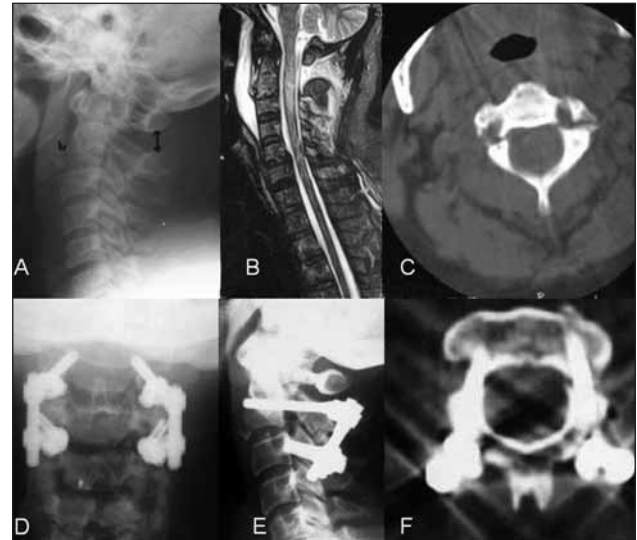
The results of this study showed the effectiveness of pars screws to fixate TSA. The long-term results of this study also revealed a good fusion rate.

TSA has been classified in different manners. Effendi provided a classification (8). Levine and Edwards (13) modified Effendi’s classification as following:

Type 1: Non-displaced fractures with no angulation between C2 and C3 and a fracture dislocation of less than 3 mm,

Type 2: Fracture with significant angulation (>11°) and displacement (>3.5 mm),

Type 2A: Fracture with minimum displacement and significant angulation (>11°),



**Figure 3:** A case treated with C2 pars – C3 lateral mass screw fixation. Lateral plain radiograph (A) and axial computed tomographic images (C) show the bilateral C2 pars fractures causing TSA. T2-weighted cervical spine image (B) shows prevertebral hematoma, posterior ligamentous injury and contusion within the spinal cord. Postoperative plain radiographs (D, and E), and computed tomographic images (F) show C2-3 stabilization using C2 pars and C3 lateral mass screw.

Type 3: Fractures with severe angulation and displacement associated with unilateral or bilateral C2-3 facet dislocation

Using the aforementioned classifications, many conservative and surgical approaches to TSA have been recommended. Classically, type 1 TSA cases can be treated conservatively. Type 2 and 3 fractures require an anterior or posterior surgical treatment. An anterior approach, transoral or extraoral C2-3 fusion and fixation, addresses C2-3 disc herniation and C2-3 stabilization (10,23). An anterior approach, however, does not address the fractured line on the pediculoisthmic component. On the other hand, a posterior approach can fixate posterior and anterior parts of the C2 vertebra, and the addition of posterior C2-3 fixation can stabilize this segment. Unlike an anterior approach, the posterior approach does not address traumatic C2-3 disc herniation. A combined approach covers all elements of the C2-3 segment. An alternative surgical option includes direct screw fixation of C2 pars or pedicle.

The C2 pars and pedicle connect posterior elements of the C2 vertebra to the C2 body (7,16).

Direct C2 pedicle screw fixation technique for TSA was first described by Laconte et al. in 1964 (12). Direct fixation of pars fracture using a screw crossing the fracture line has the advantage of preserving motion of the C1-2 segment that can offer good results in terms of the cervical spine alignment. The study of Laconte was followed by Saillant and Bleyne (19). Successful results after the use of this technique were reported in different studies (5,10,17,20,21).

Suchomel et al. (20), reviewing 41 cases of TSA, reported the use of direct pars screw fixation in 11 type I TSA cases. They performed posterior C2-3 stabilization in all cases of type II, and in selected cases of type I TSA that had the evidence of discoligamentous injury as shown by MRI or discography. They reported 100% fusion rate in all cases. A similar good outcome was reported by Boullosa et al., after the use of direct pedicle screw fixation in 10 cases of TSA. They reported a good outcome in eight cases using direct pedicle screw fixation. However, an additional C2-3 stabilization was necessary in two cases.

In another study, Hakato and Woriski (10) compared the results after pars screw fixation (n=8) and transoral C2-3 fixation (n=9). They reported fusion in all cases. The C1-2 motion segment was preserved in all cases. They addressed the potential difficulty of reduction of flexion type dislocations during the transoral approach. They therefore recommended pars screw fixation in flexion type dislocations, and transoral C2-3 fixation in extension type dislocations.

Verheggen and Jensen (22) reported their results of surgical treatment in 15 cases of type II and III hangman fracture using pedicle screws in a clinical study. They reported a significant improvement of C2-3 displacement and angulation, especially in type IIA cases. However, they did not recommend the use of pedicle screw fixation in the presence of traumatic disc herniation. We agree with Verheggen and Jensen, and it is our opinion that the direct pars or pedicle screw fixation is not indicated in cases complicated with traumatic disc herniation.

Biomechanical aspects of C2 pedicle or pars fixation techniques have been investigated recently (1,2,6,18). The destabilizing effect of discoligamentous destruction on the C2-3

biomechanics has been shown by many biomechanical studies. Arand et al. (1,2), studied destabilizing effects of stepwise C2 pedicle osteotomy (defect 1) followed by anterior longitudinal ligament section (defect 2), disc injury (defect 3), and posterior longitudinal ligament section (defect 4). They also studied the stabilizing effects of C2 pedicle screw, anterior H plate and locking plate fixation in the aforementioned destabilization scenarios. They reported that a pedicle screw increased stiffness mildly in all loading conditions compared to the intact value in defect 1. However, the addition of discoligamentous injury (as seen in defect 2,3, and 4) resulted in decreased stiffness, particularly in flexion and extension.

Our results support the evidence of effectiveness of direct pars screw in cases without discoligamentous injury. We agree with Arand et al. that pedicle screw fixation is not adequate in cases associated with severe discoligamentous injury. We performed C2-3 stabilization in such cases.

The effectiveness of the pedicle or pars screw was also studied by Duggal et al. (6) who showed that direct screw fixation of the pars after TSA effectively limits lateral bending and axial rotation, while ineffectively limiting flexion and extension, if there is excessive disc damage. The authors of that study also reported that C2-3 posterior fixation provides more rigid stability when compared to anterior C2-3 fixation.

The effectiveness of pedicle screw in cases of TSA without discoligamentous injuries may require the revision of the classification systems, addressing the injuries of the anterior longitudinal ligament, intervertebral disc, posterior longitudinal ligament, and facet joints.

It is concluded that the use of C2 pedicle screws, isolated or in connection with C3 lateral mass screws, is a good approach for fixation of cases of TSA (type II, type IIA, and III). The lack of discoligamentous injury is the key point during the surgical decision-making process. In cases without discoligamentous injury, a reduction and C2 pars screw fixation seem to be effective. However, the presence of discoligamentous injury dictates the connection of C2 pedicle or pars screws to C3 lateral mass screws.

## REFERENCES

1. Arand M, Hartwig E, Kinzl L, Gebhard F: Spinal navigation in cervical fractures--a preliminary clinical study on Judet-osteosynthesis of the axis. *Comput Aided Surg* 6: 170-175, 2001
2. Arand M, Neller S, Kinzl L, Claes L, Wilke HJ: The traumatic spondylolisthesis of the axis. A biomechanical in vitro evaluation of an instability model and clinical relevant constructs for stabilization. *Clin Biomech (Bristol, Avon)*17: 432-438, 2002
3. Boullosa JLR, Colli BO, Carlotti CG, Tanaka K, dos Santos MBM: Surgical management of axis' traumatic spondylolisthesis. Hangman's fractures. *Arq Neuropsiquiatr* 62: 821-826, 2004
4. Borne GM, Bedou GL, Pinaudeau M: Treatment of pedicular fractures of the axis. A clinical study and screw fixation technique. *J Neurosurg* 60: 88-93, 1984
5. Bristol R, Henn JS, Dickman CA: Pars screw fixation of a hangman's fracture: technical case report. *Neurosurgery* 56(1 Suppl):E204, 2005
6. Duggal N, Chamberlain RH, Perez-Garza LE, Espinoza-Larios A, Sonntag VK, Crawford NR: Hangman's fracture: a biomechanical comparison of stabilization techniques. *Spine* 32:182-187, 2007
7. Ebraheim NA, Fow J, Xu R, Yeasting RA: The location of the pedicle and pars interarticularis in the axis. *Spine* 26:E34-37, 2001
8. Effendi B, Roy D, Cornish B, Dussault RG, Laurin CA: Fractures of the ring of the axis. *J Bone Joint Surg* 63: 319-327, 1981
9. Grob D, Magerl F: Surgical stabilization of C1 and C2 fractures. *Orthopaede* 16: 46-54, 1987
10. Hakato J, Wrofski J: Operative treatment of hangman's fractures of C2. Posterior direct pars screw repair or anterior plate-cage stabilization? *Neurol Neurochir Pol* 42:28-36, 2008
11. Judet R, Roy-Camille R, Saillant G: Fractures du Rachis cervical. *Actualites de chirurgie orthopedique de l'hopital Raymond-poincare*. No VIII: Fractures du rachis cervicale Paris: Masson, 1970, 174-195
12. Leconte P: Fracture et luxation des deux premieres vertebres cervicales. In: Judet R (ed): *Luxation congenitale de la hanche. Fractures du cou-de-pied rachis cervical. Actualites de chirurgie orthopedique de l'hopital Raymond-poincare*. Vol 3. Paris: Masson et Cie, 1964: 147-166
13. Levin AM, Edwards CC: The management of traumatic spondylolisthesis of the axis. *J Bone Jont Surg* 67A: 217-226, 1985
14. Moon MS, Moon JL, Moon YW, Sun DH, Choi WT: Traumatic spondylolisthesis of the axis: 42 cases. *Bull Hosp Jt Dis* 60: 61-66, 2001
15. Naderi S, Crawford NR, Song GS, Sonntag VK, Dickman CA: Biomechanical comparison of C1-C2 posterior fixations. Cable, graft, and screw combinations. *Spine* 23:1946-1955, 1998
16. Naderi S, Arman C, Güvençer M, Korman E, Senoğlu M, Tetik S, Arda N: An anatomical study of the C-2 pedicle. *J Neurosurg Spine* 1:306-310, 2004
17. Rajasekaran S, Vidyadhara S, Shetty AP: Iso-C3D fluoroscopy-based navigation in direct pedicle screw fixation of Hangman fracture: a case report. *J Spinal Disord Tech* 20: 616-619, 2007
18. Reddy C, Ingahalikar AV, Channon S, Lim TH, Torner J, Hitchon PW: In vitro biomechanical comparison of transpedicular versus translaminar C-2 screw fixation in C-3 instrumentation. *J Neurosurg Spine* 7:414-418, 2007
19. Saillant G, Bleyne JF: Fracture des pedicules de l'axis. In: Roy-Camille R (ed): *Rachis cervical traumatique non neurologique. Pathologie traumatique de l'épaule et de la ceinture scapulaire*. Paris: Masson, 1979, pp 88-98
20. Suchomel P, Hradil J, Barsa P, Buchvald P, Lukás R, Taller S, Fröhlich R: Surgical treatment of fracture of the ring of axis - "hangman's fracture. *Acta Chir Orthop Traumatol Cech* 73:321-328, 2006.
21. Taller S, Suchomel P, Lukás R, Beran J: CT-guided internal fixation of a hangman's fracture. *Eur Spine J* 9:393-397, 2000
22. Verheggen R, Jansen J. Hangman's fracture: arguments in favor of surgical therapy for type II and III according to Edwards and Levine. *Surg Neurol* 49:253-261, 1998
23. Wilson AJ, Marshall RW, Ewart M: Transoral fusion with internal fixation in a displaced hangman's fracture. *Spine* 24:295-298, 1999
24. Xiao ZM, Zhan XL, Gong de F, Chen QF, Luo GB, Jiang H: C2 pedicle screw and plate combined with C1 titanium cable fixation for the treatment of atlantoaxial instability not suitable for placement of C1 screw. *J Spinal Disord Tech* 21:514-517, 2008
25. Xie N, Ni B, Chen DY, Ye XJ, Xiao JR, Yuan W: Combined anterior C2,3 reduction and fusion with posterior compressive C2 pedicle screw fixation for the treatment of unstable Hangman's fractures: 16 cases review. *Zhonghua Wai Ke Za Zhi* 46:267-269, 2008