

Iatrogenic Injury to the Spinal Accessory Nerve: Late Surgery

Spinal Aksesuar Sinirin İyatrojenik Yaralanması: Geç Cerrahi

ABSTRACT

The spinal accessory nerve (SAN) is responsible for the main motor innervation to the trapezius muscle. It is susceptible to iatrogenic injury as its course is superficial and close to the posterior lymph node chain and the posterior cervical triangle is covered only by skin and the investing fascia of the neck. SAN palsy may be mistaken for glenohumeral joint or muscular injury because the patient's complaint may initially be shoulder pain. It is recommended to repair the nerve within three months after the injury for the best results, but we also obtained a good result although we operated on the patient nine months after the injury.

Injury of the SAN should be considered in the differential diagnosis when there is a history of an operation in the posterior triangle of the neck. Surgical repair of the SAN results in a favorable outcome. It is possible to obtain good results even with late surgery.

KEY WORDS: Spinal accessory nerve, Iatrogenic nerve lesion, Nerve repair, Late surgery

ÖZ

Spinal aksesuar sinir (SAS) trapezius kasının esas motor innervasyonundan sorumludur. Sinirin yüzeye yakın seyri, posterior lenf nodu zincirine olan yakın komşuluğu ve posterior servikal üçgenin sadece cilt ve boyun fasyası ile kaplı olması, aksesuar siniri travmalara yatkın kılmaktadır. Hastanın ilk şikayeti omuz ağrısı olabileceğinden SAS zayıflığı glenohumeral eklem veya kas incinmesi ile karıştırılabilir. En iyi sonuçların alınabilmesi için sinirin ilk üç ay içinde onarılması önerilmektedir, ancak biz hastamızı sinirin hasar görmesinden dokuz ay sonra ameliyat etmemize rağmen iyi bir sonuç elde ettik.

SAS hasarı, posterior servikal üçgende bir operasyon hikayesi varlığında ayırıcı tanıda akılda tutulmalıdır. SAS'in cerrahi tamirinin sonuçları iyidir. Geç cerrahilerde dahi iyi sonuçlar elde etmemiz mümkündür.

ANAHTAR SÖZCÜKLER: Spinal aksesuar sinir, İyatrojenik sinir hasarı, Sinir tamiri, Geç cerrahi

Mehmet DANEYEMEZ
Doğa GÜRKANLAR
İlker SOLMAZ
Cağlar TEMİZ

Department of Neurosurgery,
Gülhane Military Medical Academy,
Ankara, Turkey

Received: 06.05.2005

Accepted: 12.09.2005

Correspondence Address:

Doğa GÜRKANLAR

Gülhane Askeri Tıp Akademisi

Beyin ve Sinir Cerrahisi Kliniği

Ankara, TURKEY

Phone : +90 312 304 53 18

Fax : +90 312 304 53 00

E-mail : dgurkanlar@hotmail.com

INTRODUCTION

The spinal accessory nerve (SAN) provides motor innervation to the trapezius and sternocleidomastoid (SCM) muscles (7). The spinal accessory nerve is susceptible to injury during operations such as biopsy of a lymph node, procedures involving the neurovascular structures and resection of a tumor in the posterior triangle of the neck. This injury results in weakness of the shoulder in abduction, pain and stiffness in the shoulder girdle and asymmetry of the neck line, drooping of the shoulder and winging of the scapula. Although early repair of the nerve has been recommended, the diagnosis of a SAN injury may be delayed as shoulder pain is a common problem, particularly following iatrogenic injuries (8,14,17,23).

CASE

A 20 year-old male patient who had suffered an injury of the SAN during a lymph node biopsy on the right side with the use of local anesthesia 9 months ago was admitted to our outpatient clinic. At the time of biopsy, the patient had reported acute pain like an electrical current. After the biopsy, the patient had noted weakness in shoulder abduction, drooping of the shoulder and asymmetry of the neckline and winging of the right scapula.

The physical examination and electrodiagnostic study which was performed 3 months after the injury revealed marked trapezius atrophy (Figure 1) and complete injury of the right SAN.

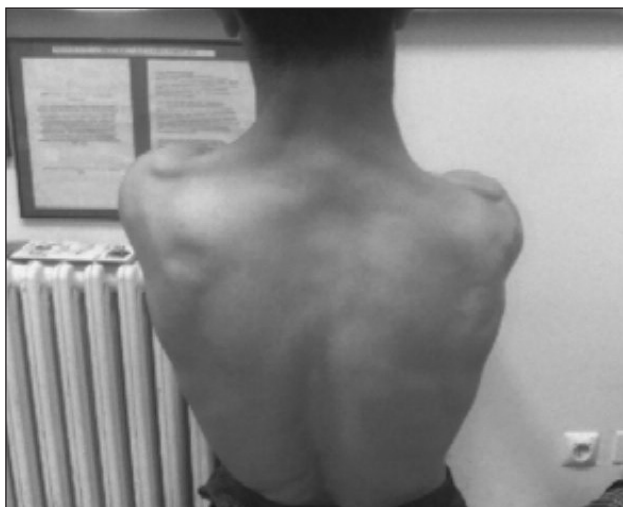

Figure 1: Physical examination revealed marked trapezius muscle atrophy

We operated on the patient under general anesthesia nearly nine months after the surgery; the previous incision for the lymph node biopsy was extended and this incision permitted both proximal exposure of the SAN and distal exposure of its branches. Our dissection was atraumatic and proceeded from the scar-free areas to the site of the previous operation. The SCM muscle, transverse cervical and greater auricular nerves served as guides. The SAN was running from beneath the lateral border of the SCM and approximately 8 cm. cranial to the clavicle. The nerve was also 1 cm cephalad to the exit point of the greater auricular nerve at the posterior margin of the SCM muscle. The nerve was completely severed nearly 2 cm. distal to the lateral border of the SCM muscle. We performed an end-to-end repair without putting tension on the nerve using the microscope and 9.0 microsutures.

Post-operatively, a Philadelphia collar was worn to restrict the motion of the neck. A sling was used to keep the forearm flexed at elbow in order to prevent the shoulder from being pulled downward then the patient was put in a rehabilitation program.

Nerve regeneration was confirmed by electromyography two months after the operation when polyphasic regenerative potentials were noted.

Surgical Anatomy

The SAN receives input from both the brain stem (nucleus ambiguus) and the upper levels of the cervical spinal cord, usually the first four. The spinal rootlets course cephalad in the ventral spinal canal to join the medullary descending rootlets. They form the SAN, which exits the cranium through the jugular foramen. Below the base of the cranium, the nerve lies lateral to the internal jugular vein. The nerve then courses either anterior (56%) or posterior (44%) to the internal jugular vein (9), where it lies behind the stylohyoid and digastric muscles. The nerve then tunnels beneath the more proximal SCM muscle, which it innervates. Even complete injury to the proximal SAN does not produce paralysis of the SCM muscle as this junction is also shared by spinal branches from C2, C3, and sometimes C4.

The SAN runs from beneath the posterior or lateral border of the SCM muscle (Figure 2), 8.2 cm \pm 1.01 cm. cranial to the clavicle, as reported in a recent anatomic study of cadavers (9). It is in close juxtaposition to the greater auricular nerve, which wraps around the lateral border of the SCM to course in the cephalad direction. An anatomic study of




Figure 2: The SAN running from beneath the posterior or lateral border of the SCM muscle (figure belongs to another patient whose nerve is in continuity)

cadavers has indicated that the SAN almost always lies cephalad to the greater auricular nerve at the level of the lateral SCM, and usually within 2 cm. of it. These two nerves together form an important landmark (20). Preauricular and postauricular sensory branches can be configured with the SAN, but they tend to wrap around the SCM muscle.

The SAN then courses obliquely across the posterior triangle, where it lies on the surface of the levator scapula muscle. On reaching the superior position of the trapezius, it branches to innervate this muscle. It supplies short branches to the trapezius along the superior and posterior border of the neck and longer branches to descend into the thoracic portion of the muscle.

Occasionally the SAN becomes bifid, usually where the proximal or medial trapezius muscle arises. In some cases, branches from C2 or even C3 spinal nerves may supplement input to the trapezius, especially the lower or spinal portion of that muscle (20). The majority of the evidence points strongly to the fact that the main motor supply to the trapezius muscle is by the cranial nerve XI. Certainly, by the time the nerve is seen in the posterior triangle, it is the sole source of motor supply to the trapezius. Regardless of whether it has received contributions from the cervical plexus before entering the posterior triangle, the patient will have a major trapezius motor loss if the SAN is injured in that area (11).

DISCUSSION

The SAN is susceptible to iatrogenic injury because its course is superficial and close to the posterior lymph node chain and the posterior cervical triangle is covered only by skin and the investing fascia of the neck (2,9,10). This anatomy explains the fact that cervical lymph node biopsy is the most common cause of iatrogenic accessory nerve injury and accessory nerve palsy, associated with winging of scapula and difficulty with shoulder abduction as in our patient (3,6,10,12,14,17).

The diagnosis is often delayed possibly due to the lack of familiarity with the anatomy of the posterior cervical triangle (17).

The SAN is the main motor innervation to the trapezius muscle (11).

Injury to the SAN can cause weakness or paralysis of the trapezius muscle. Loss of motor function of the trapezius muscle leads to winging of the scapula and to periscapular pain caused by atrophy of this relatively large shoulder and upper back muscle (2,21). SAN palsy may be mistaken for glenohumeral joint or muscular injury as the patient's complaint may initially be shoulder pain (2,21). It is sometimes associated with arm pain and occipital and posterior neck discomfort (11).

Non-operative treatment is indicated if there is evidence of recovery within three months after the onset of symptoms (5,13,16,18). The recovery should be clinically evident (3,4). The patient who has no signs of a clinical recovery should be managed operatively (16).

Our patient was selected for operation because he had complete loss of trapezius function with denervation as assessed by electromyography and had no signs of clinical recovery. End-to-end epineural repair was performed as the injured nerve was electrically silent and a short gap existed. Stimulation of the nerve also helped us in identification and preservation of the nerve as Midwinter et al. reported (15). Gabel and Nunley (5), as well as Leffert (13) recommended repair of the nerve within three months after the injury for the best results, but we also obtained a good result although we operated on the patient nine months after the injury.

If we could have seen the patient soon after the injury we could consider early repair of the nerve because SAN injuries by glass or knife wounds can be repaired relatively earlier (11).

If managed correctly, the outcome of surgery for SAN palsy is usually good, as shown in our case and in other studies (11,17,19).

Patients note dramatic relief of symptoms especially when contraction of the trapezius becomes evident on physical examination.

CONCLUSION

Injury of the SAN should be considered in the differential diagnosis when there is a history of an operation in the posterior triangle of the neck. Surgical repair of the SAN results in a favorable outcome. It is possible to obtain good results even with late surgery

REFERENCES

1. Bigliani LU, Perez-Sanz JR, Wolfe IN: Treatment of trapezius paralysis. *J Bone Joint Surg Am* 67A: 871-877, 1985
2. Brown H, Burns S, Kaiser CW: The spinal accessory nerve plexus, the trapezius muscle, and shoulder stabilization after radical neck cancer surgery. *Ann Surg* 208: 654-661, 1988
3. Donner TR, Kline DG: Extracranial spinal accessory nerve injury. *Neurosurgery* 32: 907-910, 1993
4. Dunn AW: Trapezius paralysis after minor surgical procedures in the posterior cervical triangle. *Southern Med J* 67:312-315, 1974
5. Gabel G, Nunley JA: Spinal accessory nerve. Gelberman R.H. (ed), *Nerve Repair and Reconstruction*, Volume 1, Philadelphia: J.B. Lippincott, 1991: 445-452
6. Gordon SL, Graham WP III, Black JT, Miller SH: Accessory nerve function after surgical procedures in the posterior triangle. *Arch Surg* 112:264-268, 1977
7. Grant JCB: *An Atlas of Anatomy*. Baltimore: Williams & Wilkins 1972
8. Hudson AR: Extracranial spinal accessory nerve injury. *Neurosurgery* 32: 911, 1993 (comment)
9. Kierner AC, Zelenka I, Heller S, Burian M: Surgical anatomy of the spinal accessory nerve and the trapezius branches of the cervical plexus. *Rach Surg* 135:1428-1431, 2000
10. Kline DG, Hudson AR: *Nerve Injuries: Operative Results for Major Nerve Injuries, Entrapments and Tumors*. Philadelphia, W.B. Saunders Co., 1995
11. Kim HD, Cho YJ, Tiel RL, Kline DG: Surgical outcomes of 111 spinal accessory nerve injuries. *Neurosurg* 53: 1106-1113, 2003
12. Kretchmer T, Antoniadis G, Braun V, Rath SA, Richter HP: Evaluation of iatrogenic lesions in 722 surgically treated cases of peripheral nerve trauma. *J Neurosurg* 94: 904-912, 2001
13. Leffert RD: *Neurological problems*. Rockwood C.A. Jr., Matsen, F.A. (ed), *The Shoulder*, volume 3, Philadelphia, W.B. Saunders, 1990: 750-773
14. Matz PG, Barbaro NM: Diagnosis and treatment of iatrogenic spinal accessory nerve injury. *Am Surg* 62: 682-685, 1996
15. Midwinter K, Willat D: Accessory nerve monitoring and stimulation during neck surgery. *J Laryngol Otol* April 116:272-274, 2002
16. Minami A, Kaneda K: Surgery of peripheral nerves and functional reconstruction. *OS NOW*, 3:74-83,1991
17. Nakamichi K, Tachibana S: Iatrogenic injury of the spinal accessory nerve: Results of repair. *J Bone Joint Surg Am* 80A:1616-1621,1998
18. Okinaga S, Nagano A, Ochiai N, Tajiri Y: Treatment for iatrogenic accessory nerve palsies. *J Japanese Soc Surg Hand* 8:977-980,1992
19. Osgaard O, Exkesen V, ROsenbon J: Microsurgical repair of iatrogenic accessory nerve lesions in the posterior triangle of the neck. *Acta Chir Scand* 153:172-173, 1987
20. Soo KC, Guiloff Rj, Oh A, Della Rovere GO, Westbury G: Innervation of the trapezius muscle: A study in patients undergoing neck dissections. *Head Neck* 12: 488-495, 1990
21. Waiter JM, Bigliani LU: Spinal accessory nerve injury. *Clin Orthop* 368:5-16, 1999
22. Wilbourn AJ: Iatrogenic nerve injuries. *Neurol Clin* 16:55-82,1998
23. Williams WW, Twyman RS, Donell ST, Birch R: The posterior triangle and the painful shoulder: Spinal accessory nerve injury. *Ann R Coll Surg Eng* 78:521-525, 1996