

# Protein S Deficiency, Epileptic Seizures, Sagittal Sinus Thrombosis and Hemorrhagic Infarction after Ingestion of Dimenhydrinate

## Dimenhidrinat Alımı Sonrası Gelişen Sagital Sinüz Trombozu, Hemorajik Infarkt, Epilepsi ve Protein S Yetersizliği

### ABSTRACT

Congenital protein S deficiency is associated with an increased risk of venous thrombosis. A 14-year-old boy presented with epileptic seizures and thrombosis of the superior sagittal sinus and frontal hemorrhagic venous infarction after ingestion of 50 mg of dimenhydrinate, an antiemetic drug. The patient was found to be heterozygous for the factor V Leiden mutation and had a functional protein S deficiency. He recovered completely within a month after conservative treatment. Dimenhydrinate may have disrupted a subclinical pre-existing condition in this case.

**KEY WORDS:** Protein S deficiency, Sagittal sinus thrombosis, Venous hemorrhagic infarction, Dimenhydrinate

### ÖZ

Doğmalık S protein yetmezliği yüksek oranda venöz tromboz riski taşır. Bir bulantı-kusma ilacı olan dimenhidrinat ilacından 50 mgr alan 14 yaşında bir erkek çocuğunda gelişen epileptik nöbetler, süperior sagital sinüs trombozu ve frontal hemorajik infarkt olgusu sunulmaktadır. Hastada faktör V Leiden mutasyonu için heterozigot bulunmuş ve işlevsel S protein yetmezliği saptanmıştır. Hastada cerrahi girişim uygulanmamıştır. Bir aylık konservatif tedavi dönemi ile tamamen iyileşmiştir. Bilgilerimize göre, bu hasta dimenhidrinat alımı sonrası hemorajik venöz infarkt gelişen ilk yayımlanmış olgudur. Bu olguda subklinik olarak mevcut durumu dimenhidrinat bozmuş olabilir.

**ANAHTAR SÖZCÜKLER:** Protein S yetmezliği, Sagital sinüs trombozu, Venöz hemorajik infarkt, Dimenhidrinat

Nezih OKTAR

Tayfun DALBASTI

Ege University School of Medicine,  
Neurosurgery Department Izmir, Turkey

Received: 16.05.2007

Accepted: 04.12.2007

Correspondence address:

**Nezih OKTAR**

Ege University School of Medicine,  
Neurosurgery Department Izmir, Turkey

Phone : 02324636130

Fax : 02324636130

E-mail : nezih.oktar@ege.edu.tr

## INTRODUCTION

Protein S is a vitamin K-dependent protein synthesized in the liver, vascular endothelium and megakaryocytes, and plays an important physiologic role in the protein C anticoagulant system. This anticoagulant system is one of the major regulators of hemostasis and acts inhibiting clot formation and by promoting fibrinolysis. Protein S functions as a cofactor for activated protein C on the vascular membrane to facilitate the degradation of clotting factors Va and VIIa, down-regulating clot formation (18). Protein S deficiency, either congenital or acquired, may lead to serious thrombotic events such as thrombophlebitis, deep vein thrombosis, pulmonary embolism, or an increased propensity to venous thrombosis (10, 14). We report a 14-year-old boy presenting with epileptic seizures due to thrombosis of the superior sagittal sinus and frontal hemorrhagic infarction after ingestion of the antiemetic drug dimenhydrinate (NN-dimethyl-2-diphenyl-methoxyethylamine; 8-Chloro theophyllinate=diphenhydramine).

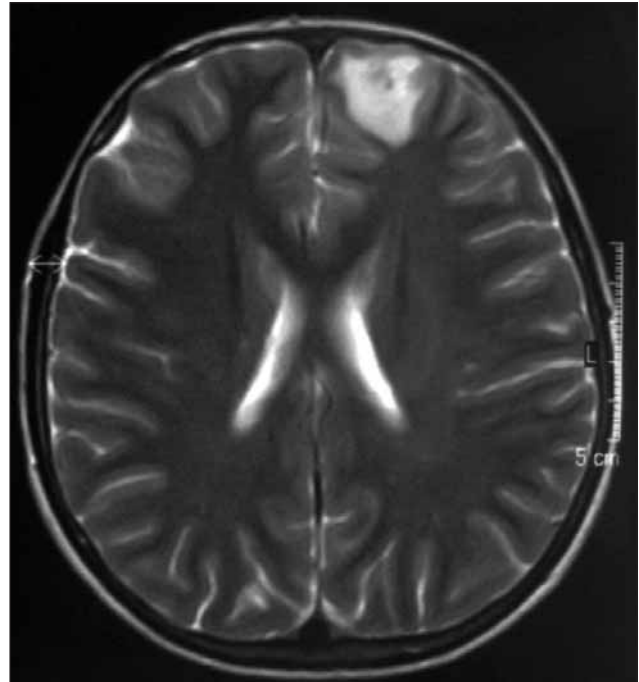
## CASE REPORT

A fourteen-year-old boy presented with repeated epileptic seizures less than one hour after ingestion of 50 mg of dimenhydrinate (Dramamine®) for antiemetic purposes due to motion sickness. The patient had not been on a prolonged trip previously and used the drug prior entering the bus. Brain CT scans showed a hypodense lesion in the left frontal lobe. MRI revealed a hyperintense lesion on T2W radiologically diagnosed as a hemorrhagic infarction of the left frontal parenchyma (Figure 1.). Almost half of the anterior part of the sagittal sinus was thrombosed as demonstrated on MRA studies (Figure 2.). Protein S activity was low (31%; Normal range 55-100%). ESR was 10-25mm and fibrinogen was normal (3.67 g/L; Normal range 1.5-4.0 g/L). Total genomic DNA isolation performed from the peripheral blood sample and factor V, MTHFR (Methylene tetra hydrofolate reductase), and prothrombin gene amplification carried out with multiplex PCR (Polymerase chain reaction). Factor V Leiden mutation (G1691A), prothrombin G20210A, MTHFR C677T mutations were searched using the PCR method (19). The patient was heterozygous for the factor V Leiden mutation and had a functional protein S deficiency. The patient's mother also had low protein S but had never had clinical

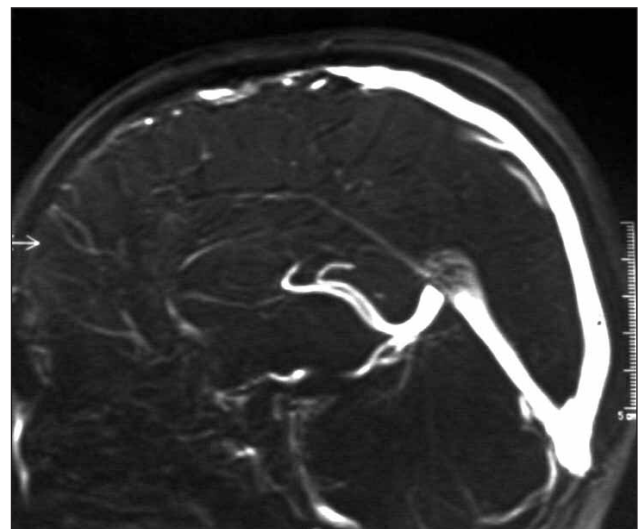
complications. He was put on aspirin and a temporary anti-epileptic drug regimen with carbamazepine. All the clinical symptoms, seizure and radiological signs had resolved a month later (Figure 3).

## DISCUSSION

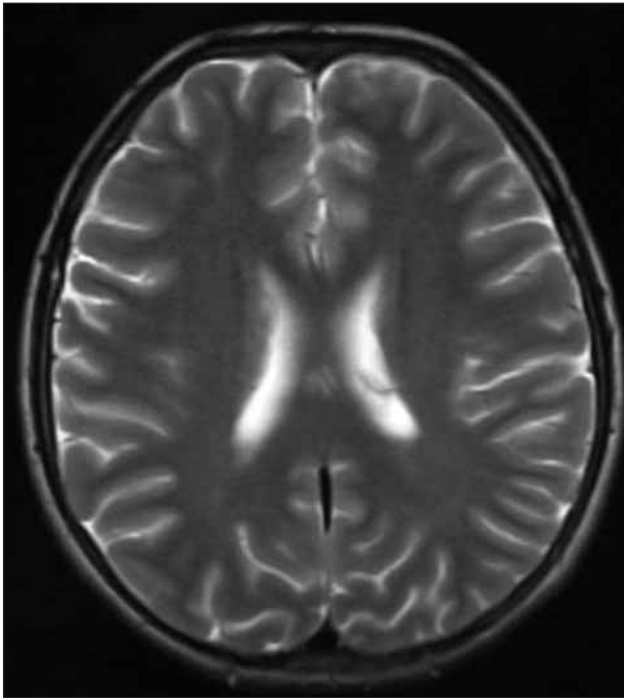
Congenital and acquired protein S deficiency is associated with an increased risk of venous



*Figure 1: T2-weighted MRI showing an hyperintense lesion radiologically diagnosed as hemorrhagic infarction on the left frontal lobe.*



*Figure 2: MR venography shows absence of flow in the anterior 1/3 part of the superior sagittal sinus in MRA study.*



*Figure 3: Complete resolution of the lesion a month later in the follow-up MRI.*

thrombosis (1, 7). The prevalence of protein S deficiency has been estimated to be less than 1 case per 300 in the general population. Two-thirds of patients with a congenital deficiency of protein S (levels less than 50% of normal) may present with venous thrombosis in young adulthood (5, 17). The frequency of free protein deficiency in stroke patients has been found to be higher than the expected prevalence in the general population (15). Some patients with thrombotic states may develop progressive intracranial arterial occlusions as well, possibly secondary to a permanent thrombogenic stimulus (20).

Protein S is a naturally occurring vitamin K-dependent protein that in conjunction with active protein C inhibits the clotting cascade. Protein S deficiency is known to be of clinical significance in patients with deep venous thrombosis or pulmonary emboli and the treatment for these patients is long-term anticoagulation. Measurement of total and free protein S, antithrombin III and protein C levels should be part of the evaluation for any young adult who has had a stroke (2). Oral contraceptive use is one of the best-known predisposing factors for cerebral infarction (12). Cerebral venous thrombosis and cerebral infarction from arterial origin are the

most common forms of neurological involvement. There are multiple pathophysiological mechanisms of stroke in these patients and can vary as in the antiphospholipid syndrome embolism from valvular abnormalities related to hematological disturbance to thrombosis of extracranial or intracranial vessels. Some hereditary findings have also been reported concerning protein S deficiency that may be asymptomatic as in our case's mother (6). A family history of protein S deficiency will definitely play a constructive role in the management for similar future cases.

Dimenhydrinate is a traditional and inexpensive antiemetic and an over-the-counter drug used to prevent motion sickness. It also has some therapeutic benefits in childhood dizziness (11). Dimenhydrinate is closely related to diphenhydramine HCl. The differences relate to the weight-for-weight potency (50 mg dimenhydrinate contains 29 mg of the drug diphenhydramine), delay of action (dimenhydrinate must dissociate into diphenhydramine and its counterpart in the body before it is active, therefore diphenhydramine produces effects sooner), and degree of sedation produced. Chemically, dimenhydrinate is a salt of two drugs: diphenhydramine and 8-chlorotheophylline, a chlorinated derivative of the theophylline. Although in use for a long time, the dose-response, precise estimation of side effects, optimal time of administration and benefit of repetitive doses still remain unclear (4). High doses (5,000 mg) of dimenhydrinate may be fatal with multiple ischemic lesions, status epilepticus and infarction with severe neurological deficit as in a rare overdose usage case (13). Status epilepticus, coma, and life-threatening ventricular dysrhythmias were reported in a 4-month-old infant intentionally administered an overdose of dimenhydrinate (21). Diphenhydramine overdose causing hyperpyrexia, status epilepticus, coma, and cardiac arrhythmias has been reported in adult cases (3, 8, 9, 16, 22, 23). To our knowledge our presented case is the first reported case of a hemorrhagic venous infarction caused by the ingestion of dimenhydrinate. Dimenhydrinate may have disrupted a subclinical pre-existing condition in our case.

## REFERENCES

1. Aderjan R, Börsche J, Schmidt G: Poisoning by diphenhydramine--forensic-toxicologic interpretation of analytic results. *Z Rechtsmed* 88: 263-270, 1982

2. Barinagarrementeria F, Cantu Brito C, Izaguirre R, de la Pena A: Progressive intracranial occlusive disease associated with deficiency of protein S. Report of two cases. *Stroke* 24: 1752-1756, 1993
3. Blayney AW, Colman BH: Dizziness in childhood. *Clin Otolaryngol Allied Sci* 9: 77-85, 1984
4. Clark RF, Vance MV: Massive diphenhydramine poisoning resulting in a wide-complex tachycardia: successful treatment with sodium bicarbonate. *Ann Emerg Med* 21: 318-321, 1992
5. Comp PC, Nixon RR, Cooper MR, Esmon CT: Familial protein S deficiency is associated with recurrent thrombosis. *J.Clin Invest* 74: 2082-2088, 1984
6. Dahlback B: Factor V and protein S as cofactors to activated protein C. *Haematologica* 82:91-95, 1997
7. Espana F, Villa P, Mira Y, Grancha S, Royo M, Estelles A, Vaya A, Aznar J: Factor V Leiden and antibodies against phospholipids and protein S in a young woman with recurrent thromboses and abortion. *Haematologica* 84: 80-84, 1999
8. Farrell M, Heinrichs M, Tilelli JA: Response of life threatening dimenhydrinate intoxication to sodium bicarbonate administration. *J Toxicol Clin Toxicol* 29: 527-535, 1991
9. Kranke P, Morin AM, Roewer N, Eberhart LH: Dimenhydrinate for prophylaxis of postoperative nausea and vomiting: a meta-analysis of randomized controlled trials. *Acta Anaesthesiol Scand* 46: 238-244, 2002
10. Köppel C, Ibe K, Tenczer J: Clinical symptomatology of diphenhydramine overdose: an evaluation of 136 cases in 1982 to 1985. *J Toxicol Clin Toxicol* 25: 53-70, 1987
11. Kurkowska-Jastrzebska I, Wicha W, Dowzenko A, Vertun-Baranowska B, Pytlewski A, Boguslawska R, Czlonkowska A: Concomitant heterozygous factor V Leiden mutation and homozygous prothrombin gene variant (G2021A) in patient with cerebral venous thrombosis. *Med Sci Monit.* 9: 41-45, 2003
12. Lagosky S, Witten CM: A case of cerebral infarction in association with free protein S deficiency and oral contraceptive use. *Arch Phys Med Rehabil* 74: 98-100, 1993
13. Laversuch CJ, Brown MM, Clifton A, Bourke BE: Cerebral venous thrombosis and acquired protein S deficiency: an uncommon cause of headache in systemic lupus erythematosus. *Br J Rheumatol* 34: 572-575, 1995
14. Martinez HR, Rangel-Guerra RA, Marfil LJ: Ischemic stroke due to deficiency of coagulation inhibitors. Report of 10 young adults. *Stroke* 24: 19-25, 1993
15. Moraes C, Lofthouse E, Eikelboom J, Thom J, Baker R: Detection of protein S deficiency: a new functional assay compared to an antigenic technique. *Pathology* 32: 94-97, 2000
16. Pages M, Milhaud D, Heroum C, Blard JM: Cerebrovascular complications and hereditary protein S deficiency: 2 cases. *Rev Neurol (Paris)* 152: 288-291, 1996
17. Pragst F, Herre S, Bakdash A: Poisonings with diphenhydramine--a survey of 68 clinical and 55 death cases. *Forensic Sci Int* 161: 189-197, 2006
18. Rinder CS, D'Amato SL, Rinder HM, Cox PM. Survival in complicated diphenhydramine overdose. *Crit Care Med* 16: 1161-1162, 1988
19. Rintelen C, Yegneswaran S, Griffin JH: Anticoagulant dysfunction of human Arg352Trp-activated protein C caused by defective factor Va inactivation. *Thromb Haemost* 85: 274-279, 2001
20. Sacco RL, Owen J, Mohr JP, Tatemichi TK, Grossmann BA: Free protein S deficiency: a possible association with cerebrovascular occlusion. *Stroke* 20: 1657-1661, 1989
21. Sharma AN, Hexdall AH, Chang EK, Nelson LS, Hoffman RS: Diphenhydramine-induced wide complex dysrhythmia responds to treatment with sodium bicarbonate. *Am J Emerg Med* 21: 212-215, 2003
22. Walker FJ. Protein S and thrombotic disease. *PSEBM* 200: 285-295, 1992
23. Winn RE, McDonnell KP: Fatality secondary to massive overdose of dimenhydrinate. *Ann Emerg Med* 22: 1481-1484, 1993