

# Seeding Metastasis in the Scalp After Removal of the Meningioma: A Case Report

## Meningioma Cerrahisi Sonrası Skalpte Ekilme Metastazı: Olgu Sunumu

### ABSTRACT

**INTRODUCTION:** Meningiomas originate from meningotheial cells. Meningioma is a common neoplasm in the CNS, representing about 15-20 percent of all primary intracranial tumors. Although malignant forms may spread via blood, lymphatic drainage and cerebrospinal fluid to distant sites, metastasis from a low-grade meningioma is very unlikely.

**CASE REPORT:** A 19-year-old female was admitted to our hospital in 2001, with a one-month history of headache and two episodes of convulsions. Physical and neurological examinations were normal. Computed tomography and magnetic resonance imaging revealed an intracranial, extra-axial space-occupying lesion at the left frontal region. After total removal of the tumor, histopathology revealed WHO grade 1 meningioma. There was no neurological deficit after surgery. Three years after the tumor resection, subcutaneous metastasis developed on the scalp just behind the scar left by the previous surgery. Histopathology of the second lesion also revealed a WHO grade 1 meningioma.

**CONCLUSION:** Isolated distinct metastasis from malignant meningioma has been mentioned in two reports previously. This is the first report that shows the seeding metastasis from low-grade meningioma to the surgical trajectory in the subcutaneous tissue of the scalp.

**KEY WORDS:** Meningioma, metastasis, scalp

### ÖZ

**GİRİŞ:** Meningiomalar meningotelyal hücrelerden orijin alır. Meningiomalar tüm primer intrakranyal tümörlerin yaklaşık %15-20'sini oluşturur. Malign formları için kan, lenfatik yollar ve serebrospinal sıvı yollarını kullanarak uzak alanlara yayılım bildirilse de, düşük gradlı meningiomalar için metastaz alışılmadık bir durumdur.

**OLGU SUNUMU:** 19 yaşında kadın hasta 2001 yılında 1 aydır süren baş ağrısı ve 2 kez tekrarlayan konvulziyon öyküsü ile hastaneye başvurdu. Fizik muayenesi ve nörolojik muayenesi normaldi. Bilgisayarlı tomografi ve Manyetik rezonans görüntülerde sol frontal bölgede intrakranyal, ekstraaksiyel yerleşimli tümör izlendi. Tümörün total eksizyonunu takiben histopatoloji sonucu WHO grad I meningioma idi. Cerrahi sonrası nörolojik defisit yoktu. Cerrahi tedaviden 3 yıl sonra skalp insizyon hattının hemen arkasında gelişen subkutan kitle total olarak çıkarıldı. Bu kitlenin histopatolojik tanısı da WHO grad I meningioma idi.

**SONUÇ:** Malign meningiomalarda izole uzak metastaz daha önce 2 kez bildirilmiştir. Bildirdiğimiz olgu ise, düşük grad meningiomadan cerrahi yol boyunca skalpte subkutan dokuya metastaz saptanan ilk olgudur.

**ANAHTAR SÖZCÜKLER:** Meningioma, metastaz, skalp

Müslüm GÜNEŞ<sup>1</sup>

Bekir TUĞCU<sup>2</sup>

Ömür GÜNALDI<sup>3</sup>

Utku ADILAY<sup>4</sup>

Çiçek BAYINDIR<sup>5</sup>

Semih BILGIÇ<sup>5</sup>

1,2,3,4,6 2nd Neurosurgery Clinic,  
Bakırköy Mental Health and  
Nervous Diseases Education and  
Research Hospital,  
Istanbul, Turkey

5 Department of Neuropathology,  
School of Medicine, Istanbul  
University, Istanbul, Turkey

Received : 21.02.2005

Accepted: 12.05.2005

Correspondence Address:

**Bekir TUĞCU**

Sirpsindigi sok. Koksak Apt.

31/5 Merter 34010 Istanbul -Turkey

Phone : +90 0212 5438667

E-mail : deniztugcu@superonline.com

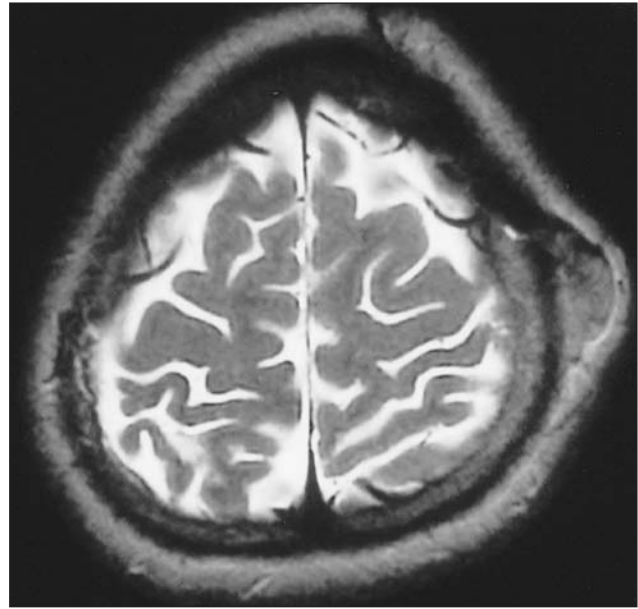
**INTRODUCTION**

Meningiomas originate from the meningotheial cells. They make up 20 percent of all primary intracranial tumors. They are considered to be benign neoplasms. Despite their benign character, malignant meningiomas can spread to distant areas through blood, lymph and cerebrospinal fluid. Furthermore, dissemination of cells to different sites from malignant meningiomas has been reported previously.

**CASE REPORT**

A 19-year-old female was admitted to our hospital in 2001, with a one-month history of headache and two episodes of convulsions. Physical and neurological examinations were normal. Computed tomography and magnetic resonance imaging revealed an intracranial, extra-axial space-occupying lesion at the left frontal region. The tumor was totally removed by surgery; the histopathological diagnosis was WHO grade 1 meningioma. There was no neurological deficit after surgery.

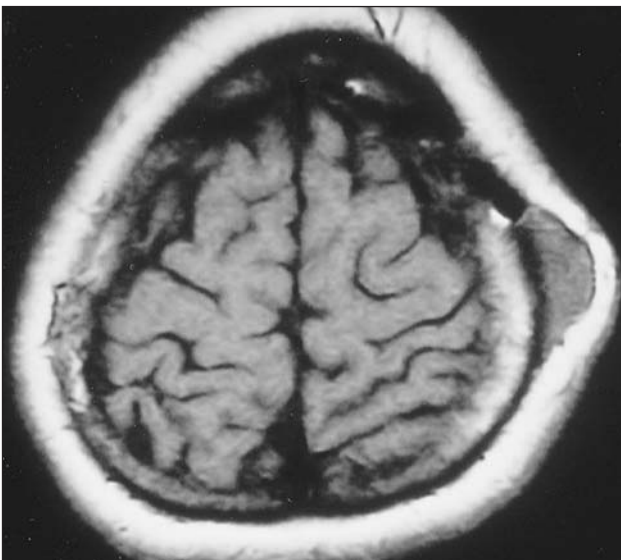
Three years after the first surgery, she was admitted to our hospital with a two-month history of a gradually enlarging subcutaneous mass, just behind the scar left by the previous surgery. Neurological examination was normal. Axial, coronal T1- and axial T2-weighted magnetic resonance imaging revealed an isointense lesion in the scalp (Figure 1A, 1B). After gadolinium DTPA



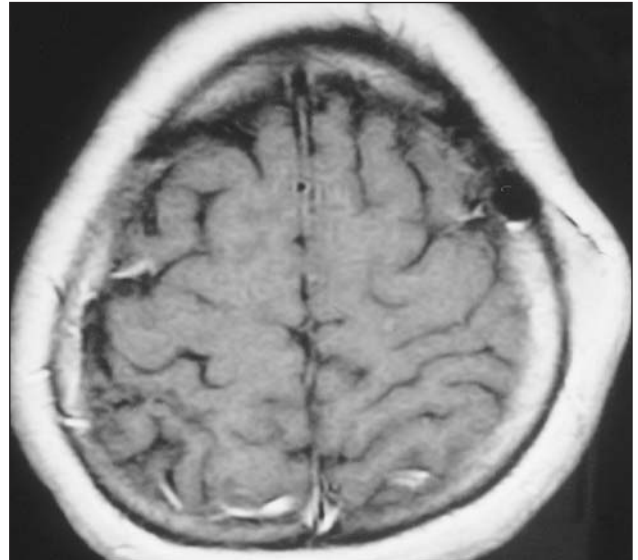
**Figure 1B:** Axial T2-weighted magnetic resonance imaging revealed isointense mass in the subcutaneous tissue.

administration, magnetic resonance imaging showed dense enhancement in the mass lesion (Figure 1C, 1D). There was no spread towards the underlying bone or intracranial compartment.

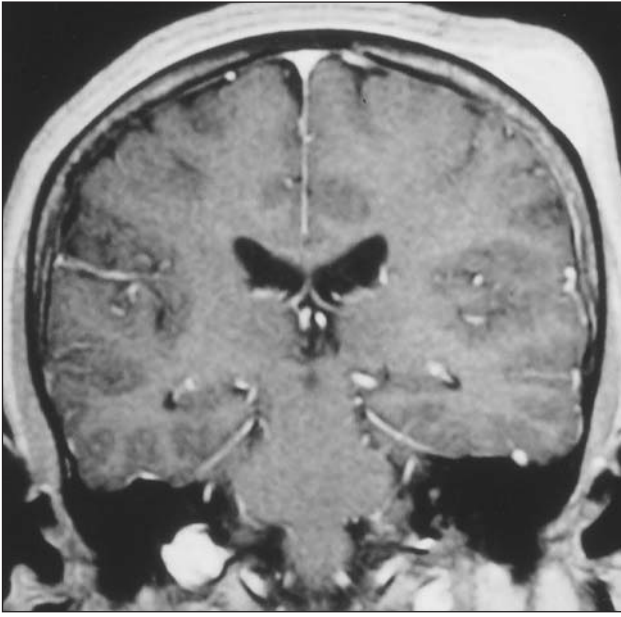Total tumor removal was performed. Histopathology again revealed a WHO grade 1 meningioma (Figure 1E, 1F). No recurrence was seen at the four-month follow-up examination.



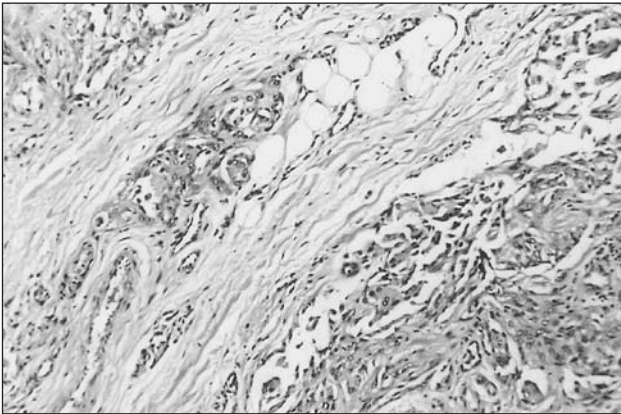
**Figure 1A:** Axial T1-weighted magnetic resonance imaging revealed isointense mass in the subcutaneous tissue.



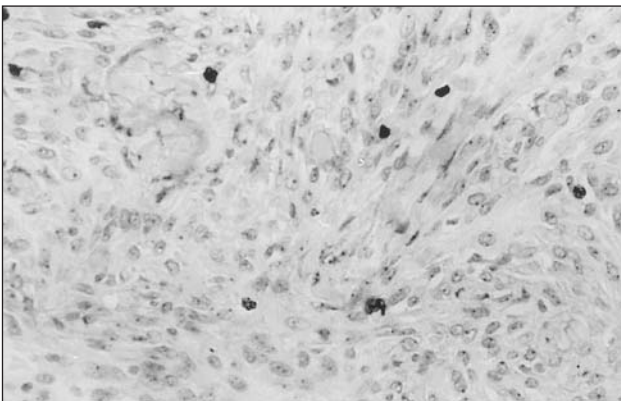
**Figure 1C:** After gadolinium DTPA administration axial T1-weighted magnetic resonance imaging showed dense enhancement in the mass lesion.



**Figure 1D:** After gadolinium DTPA administration coronal T1-weighted magnetic resonance imaging showed dense enhancement in the mass lesion.



**Figure 1E:** Histopathology revealed benign meningioma. (HE stain, X125 magnification)



**Figure 1F:** The Ki 67 (MIB 1) labeling index showed mainly WHO grade 1 meningioma (Ki 67 labeling index X310 magnification)

## DISCUSSION

Meningiomas constitute 20 percent of all intracranial tumors. They are typically slow growing and usually non invasive. Hence they are perceived as benign neoplasms. Although their natural behavior is benign, 1-2 percent of all meningiomas can metastasize [10]. Furthermore local recurrence rates after complete resection vary from 10 to 30 percent. The histological grade of the tumor is the most important property to predict metastases and recurrences. Malignant forms of meningioma, which make up 2-10 percent of all meningiomas, are aggressive tumors. Malignant meningiomas have potential for spread to distance locations via blood, lymph or cerebrospinal fluid [1,5,6,8,9,12,14,15]. In addition, two reports show that malignant meningiomas can recur in the surgical tract after removal of tumor. The site of metastasis was the abdominal surgical site that was incised for the fatty graft in one study, and in the incision line at the scalp in another [7,12].

Meningiomas can occur rarely at atypical primary locations. Meningiomas that originated in the neck, retroperitoneal space, nose and scalp have been reported in the literature [3,4,13]. This has been explained by different mechanisms. Probable mechanisms are metastasis from a primary intracranial meningioma, ectopic arachnoid tissue or embryonic nests of arachnoid cells, gene mutation due to previous radiotherapy and pharmacological therapy.

Metastasis from a WHO grade I meningioma is an extremely rare condition [2,11]. The common sites of metastasis from both malignant and benign meningiomas are the lung, lymph nodes and liver. To our knowledge, this is the first report that shows the seeding metastasis from a low-grade meningioma to the surgical trajectory of the subcutaneous tissue of the scalp. Because the histopathology was the same for both of the tumors and the patient had not received any radiotherapy (thus excluding the possibility of post-radiotherapy meningioma formation), we hypothesize that the mechanism of metastasis was the dissemination of the tumor cells via the surgical tools during surgery. Furthermore, radiological findings did not show any intracranial recurrence in addition to the isolated subcutaneous lesion. For these reasons, the mechanism of the metastasis seems to be seeding of tumor cells in the subcutaneous tissue.

## CONCLUSION

In conclusion, although surgical treatment of the convexity meningiomas without involvement of the superior sagittal sinus is not difficult for most neurosurgeons, precautions must be taken during surgery to avoid dissemination of the tumor cells.

## REFERENCES

- Allen IV, McClure J, McCormick D, Gleadhill CA. LDH isoenzyme pattern in a meningioma with pulmonary metastases. *J Pathol* 123: 187-191, 1977
- Corde-Nicolas M, Lopez-Gines C, Perez-Bacete M, Rolden P, Talamantes F, Barbera J. Histologically benign metastatic meningioma: morphological and cytogenetic study: case report. *J Neurosurg*. 98; 194-198, 2003
- Cummings TJ, George TM, Fuchs HE, McLendon RE. The pathology of extracranial scalp and skull masses in young children. *Clin Neuropathol*. 23; 34-43, 2004
- Huszar M, Fanburg JC, Dickersin GR, Kirshner JJ, Rosenberg AE. Retroperitoneal malignant meningioma. A light microscopic, immunohistochemical and ultrastructural study. *Am J Surg Pathol*. 20; 492-499, 1996
- Lee TT, Landy HJ. Spinal metastases of malignant intracranial meningioma. *Surg Neurol*. 50; 437-441, 1998
- Lowden RG, Taylor HB. Angioblastic meningioma with metastasis to the breast. *Arch Pathol*. 98; 373-375, 1974
- Lüdemann WO, Obler R, Tatagiba M, Samii M. Seeding of malignant meningioma along a surgical trajectory on the scalp. *J Neurosurg*. 97; 683-686, 2002
- Ludwin SK, Conley FK. Malignant meningioma metastasizing through the cerebrospinal pathways. *J Neurol Neurosurg Psychiatry*. 38; 136-142, 1975
- Mori H, Sugiyama Y, Terabayashi T, Niida H, Yamamoto K, Kitazawa T, Wakaki K. Related Articles, Links Abstract [recurrent meningioma with malignant changes and extracranial multiple metastases] No Shinkei Geka. 16; 899-902, 1988 (Japanese).
- Pasquier B, Gasnier F, Pasquier D, Keddari E, Morens A, Couderc P. Papillary meningioma. Clinicopathologic study of seven cases and review of the literature. *Cancer*. 58; 299-305, 1986
- Pramesh CS, Saklani AP, Pantvaidya GH, Heroor AA, Naresh KN, Sharma S, Deshpande RK. Benign metastasizing meningioma. *Jpn J Clin Oncol*. 33; 86-88, 2003
- Sadahira Y, Sugihara K, Manabe T. Iatrogenic implantation of malignant meningioma to the abdominal wall. *Virchows Arch*. 438; 316-318, 2001
- Tampieri D, Pokrupa R, Melanson D, Ethier R. Primary ectopic meningioma of the neck: MR features. *J Comput Assist Tomogr*. 11; 1054-1056, 1987
- Travitzky M, Libson E, Namirovsky I, Hades I, Gobizon A. Doxil induced regression of pleuro-pulmonary metastases in a patient with malignant meningioma *Anticancer drugs*. 14; 247-250, 2003
- Yacoub M, Naccache JM, Kujas M, Valegre D, Kambouchner M. Isolated pleural metastases from an atypical meningioma. *Rev Mal Respir*. 20; 433-436, 2003