

Cavernous Sinus Hemangiomas: Two Case Reports

Kavernöz Sinüs Hemanjiomları: İki Olgu Sunumu

ABSTRACT

Extra-axial cavernous sinus hemangiomas are rare and represent 3% of all benign cavernous sinus tumors. Total removal of cavernous sinus hemangiomas is difficult due to the risk of severe intraoperative bleeding and the complicated neurovascular structures of the cavernous sinus. These lesions have characteristic radiological features but can be misdiagnosed as meningiomas and neurilemmomas. We report two cases of cavernous sinus hemangiomas which were treated by surgery and gamma knife surgery.

KEY WORDS: Cavernous sinus hemangioma, cavernous sinus, middle fossa

ÖZ

Ekstra-aksiyal yerleşimli kavernöz sinüs hemanjiomları nadir olarak görülür ve tüm selim yapılı kavernöz sinüs tümörlerinin %3 kadarını oluştururlar. Kavernöz sinüs hemanjiomlarının total olarak çıkartılmaları intraoperatif aşırı kanama riskinden ve kavernöz sinüsün komplike nörovasküler yapılarından dolayı oldukça zordur. Kendilerine has radyolojik özellikleri vardır fakat tanı esnasında meningioma ve nörolemmomalar ile karışabilirler. Biz bu yazıda kavernöz sinüs hemanjiomu nedeniyle cerrahi ve gama knife cerrahisi ile tedavi edilen iki adet olguyu sunuyoruz.

ANAHTAR SÖZCÜKLER: Kavernöz sinüs hemanjiomu, kavernöz sinüs, orta fossa

Murat COŞAR
A. Celal IPLIKÇIOĞLU
Cem A. GÖKDUMAN
Sirzat BEK
M. Aziz HATIPOĞLU

Neurosurgery Department,
Social Security Okmeydanı Teaching
Hospital, Istanbul, Turkey

Received : 09.08.2004
Accepted : 13.04.2005

Correspondence address:

Murat COŞAR
Bulgurlu Mah. Soğutlucayır Caddesi
Milli Sokak No:1/3
81190 Çamlıca-Üsküdar, Istanbul, Turkey
GSM : +90 532 5106190
Fax : +90 212 2217800
E-mail : drcosar@ hotmail.com

INTRODUCTION

Cavernous hemangiomas are uncommon vascular malformations which can be found in any part of the central nervous system. However, they are seen only rarely in the region of the cavernous sinus. They expand as an extracerebral tumor to the base of middle fossa by elevating the floor of the dura mater (2, 4, 6, 10-12, 21). Cavernous sinus hemangiomas (CSH) may present with various neurological features such as headache, seizure, hemorrhage or neurological deficits (2). Total removal of CSH is difficult because of the devastating, uncontrollable bleeding and complex neurovascular structures (5, 12, 15). We report two cases of CSH which were treated by surgery and gamma knife surgery.

Case 1:

A 60-year-old, right-handed man admitted to our clinic with sudden onset of decreased visual acuity. His neurological examination was normal except for right homonymous hemianopsia. Computerised tomography (CT) scan revealed an enhanced mass within the left cavernous sinus extending to the left middle fossa and a subacute hemorrhagic infarct on the left occipital lobe (Figure 1A, 1B). Magnetic resonance imaging (MRI) showed a tumor 5x4x3 cm in size, with hypointensity on T1-weighted images, hyperintensity on T2-weighted images and homogenous enhancement (Figure 1C). Digital subtraction angiography (DSA) revealed minimal pooling via the branches of left intracavernous internal carotid artery (ICA). The tumor was compressing the left ICA, left posterior communicating artery (PComA) and left posterior cerebral artery (PCA) (Figure 1D). Subtotal resection of the mass was performed via a left fronto-temporal craniotomy. Histopathology confirmed the diagnosis of cavernous hemangioma. The patient had an uneventful postoperative course except for right homonymous hemianopsia and left third nerve palsy. Follow-up MRI of the patient one month after the operation showed residual tumoral mass within the cavernous sinus (Figure 1E). Gamma-knife surgery was performed two months after the operation.

Case 2:

A 37-year-old man presented with a six-month history of headache and dizziness. His neurological examination was normal. MRI showed a tumor 3x4x5 cm in size, with hypointensity on T1-weighted

images, hyperintensity on T2-weighted images and homogenous enhancement (Figure 2A). DSA showed that the tumor was feeding via the branches of left intracavernous ICA (Figure 2B). The anterior temporal approach following a frontotemporal craniotomy was used for the operation. The bleeding during surgery was uncontrollable, permitting only a biopsy and minimal resection. The histopathological diagnosis was cavernous hemangioma. The postoperative course was uneventful. Surgery was followed by gamma-knife surgery. Follow-up MRI of the patient one year (Figure 2C) and two years (Figure 2D) after the gamma-knife surgery revealed minimal residual tumoral mass.

DISCUSSION

Cavernous hemangiomas can occur in all parts of the central nervous system but are only rarely seen in the cavernous sinus. CSH represent 3% of all benign cavernous sinus tumors (5). CSH originate from the cavernous sinus and expand to the floor of the middle fossa. They may sometimes present tumor-like behaviour and may grow slowly and compress the surrounding structures (1, 6, 21).

Histologically, cavernous hemangiomas have two subtypes; A and B. Subtype A is composed of a large number of thin-walled endothelial vascular spaces

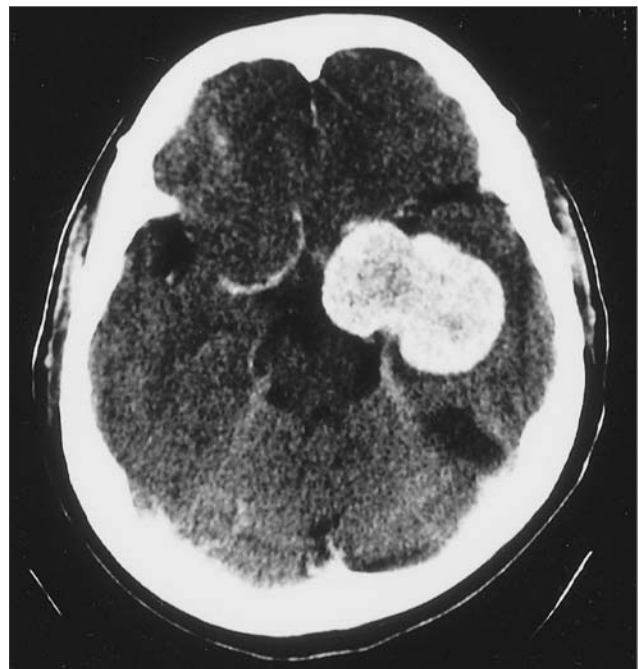

Figure 1A: Case 1: Preoperative contrast axial CT scan shows enhancing of tumoral mass on the left temporal lobe.

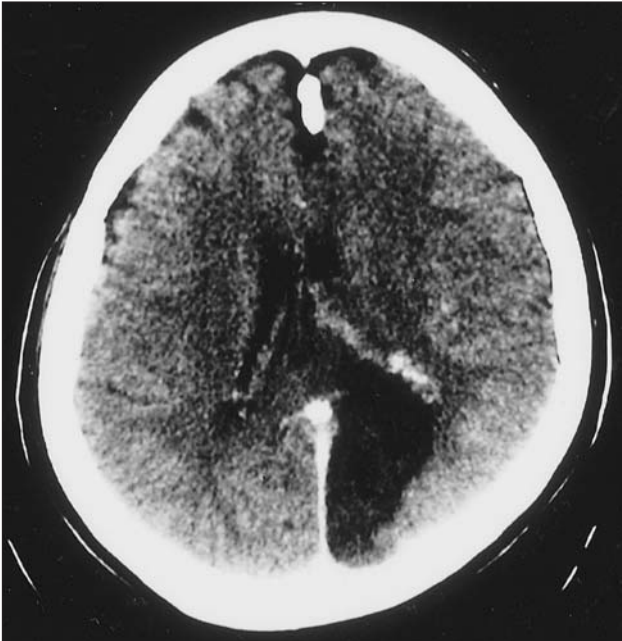

Figure 1B: Case 1: Preoperative contrast axial CT scan shows infarct on the feeding area of left PCA.

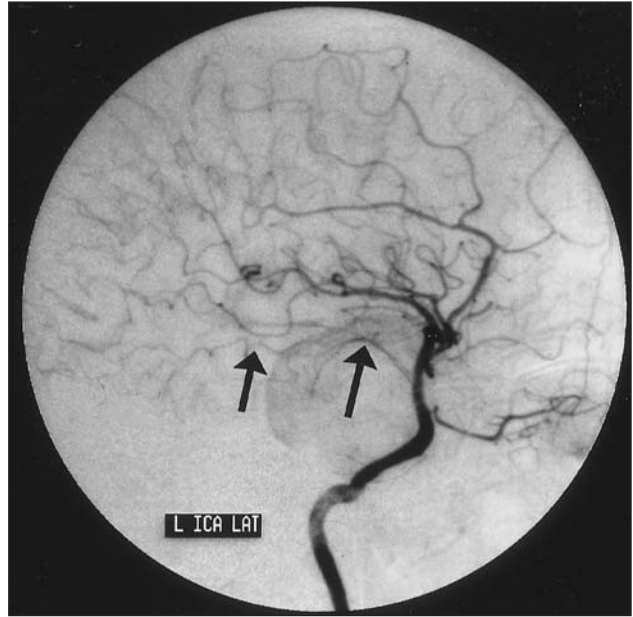


Figure 1D: Case 1: Preoperative intracranial lateral DSA shows pooling of tumoral mass and the compression of the left ICA, P Com A and PCA.

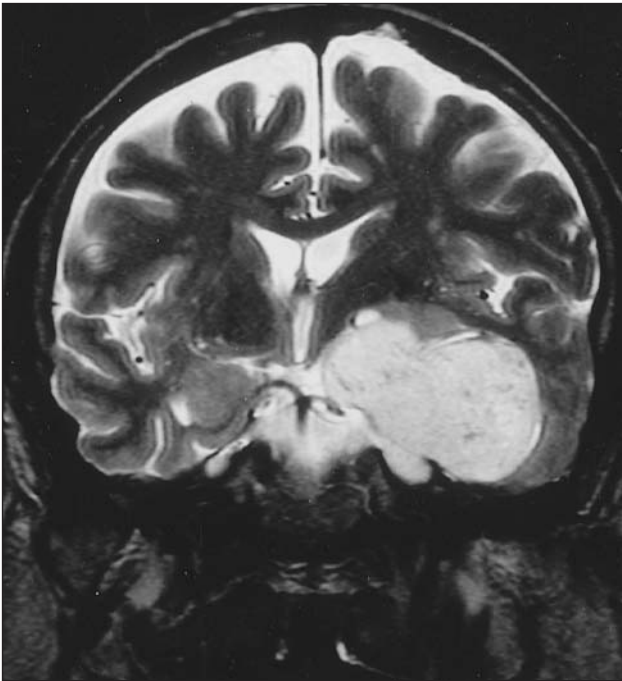


Figure 1C: Case 1: Preoperative T2-weighted coronal MRI shows tumoral mass on the left temporal lobe related to the cavernous sinus.

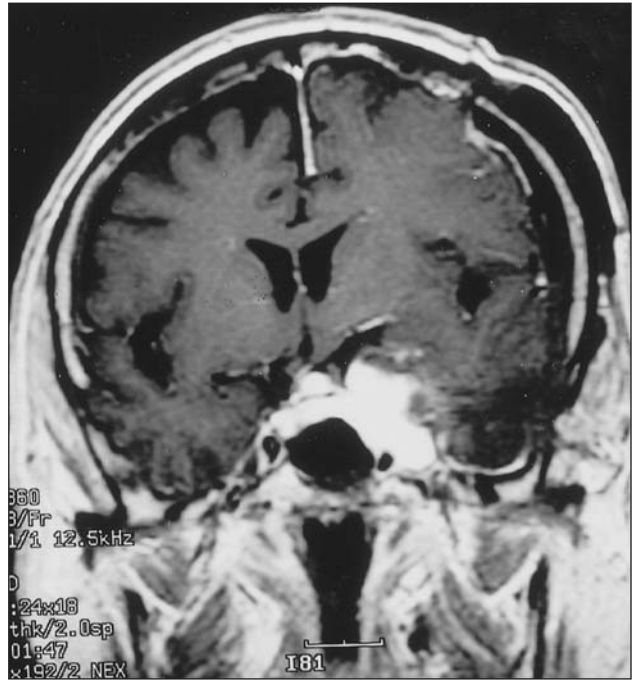


Figure 1E: Case 1: Postoperative T1-weighted contrast coronal MRI shows residual tumoral mass on the left temporal lobe related with cavernous sinus.

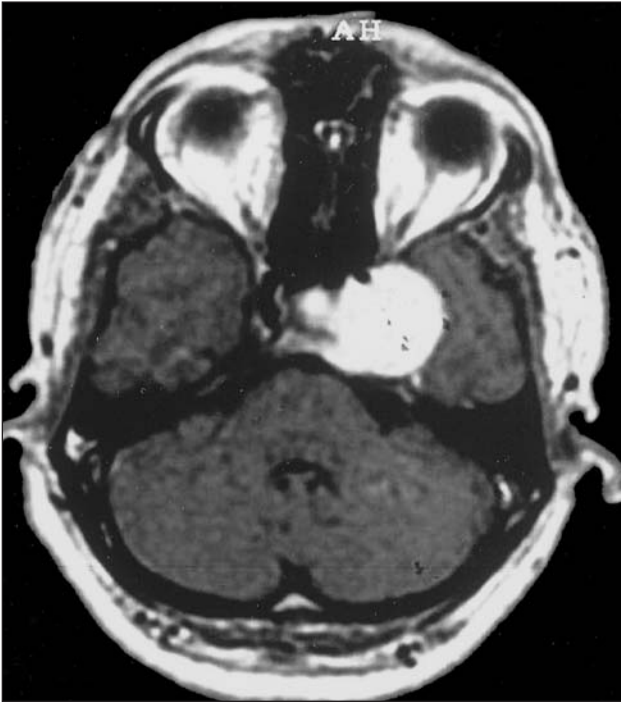

Figure 2A: Case 2: Preoperative T1-weighted contrast axial MRI shows tumoral mass on the left temporal lobe related with cavernous sinus.

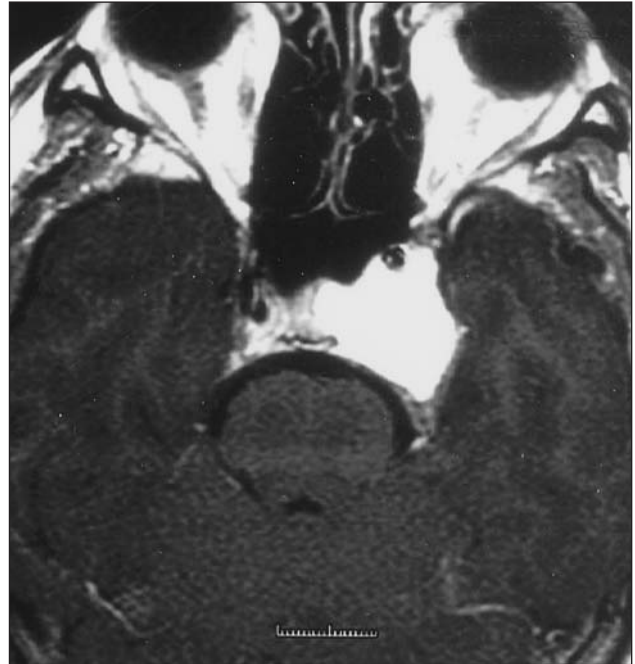

Figure 2C: Case 2: Postoperative T1-weighted contrast axial MRI shows residual tumoral mass on the left temporal lobe related with cavernous sinus, one year after the operation.

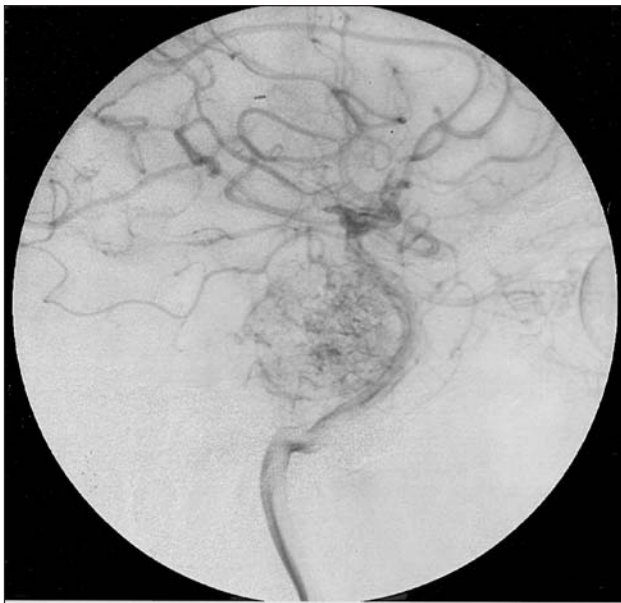


Figure 2B: Case 2: Preoperative intracranial lateral DSA shows pooling of tumoral mass and the compression of the left ICA.

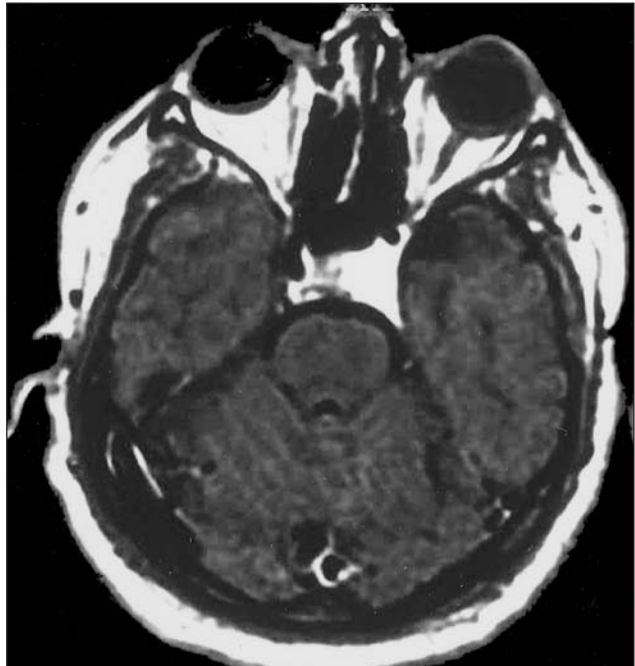

Figure 2D: Case 2: Postoperative T1-weighted contrast axial MRI shows residual tumoral mass on the left temporal lobe related with cavernous sinus, two years after the operation.

with scanty connective tissue between the lumina. It has more tendency to bleed compared to subtype B which has a solid parenchyma (8, 17). There is no neural tissue within these lesions (15).

CSH tend to become quite large before the patient manifests signs and symptoms (23). Clinical signs and symptoms can not distinguish CSH from other cavernous sinus lesions. Headache, cranial neuropathies (especially III, IV, V/II, V/III, VI), worsened vision and acuity, diplopia, ptosis, retroorbital pain, exophthalmos, endocrinopathy, trigeminal neuralgia, hemi- or monoparesis can be seen in these patients (5). There is a higher incidence in females in the fifth and sixth decade of their lives (93 %), but no correlation was found between the blood estrogen levels and development of the lesion (5). It is well-known that the symptoms can change during pregnancy and that they can disappear or improve after delivery (9, 18). CSH are generally found in females (5) although both of our cases were males. In contrast to cavernomas, CSH do not have hereditary characteristics and are not seen as multiple lesions (1, 14, 19).

CSH are very different from the more common parenchymal cavernomas. Unlike parenchymal cavernomas, the channels in CSH are arterialized and they rarely present with hemorrhage (18).

Calcification is unusual on CSH but they generally demonstrate bone erosion of the anterior clinoid, sella turcica and sphenoid bone (3, 5). CT scans show hypo-, iso- or hyperdense lesions and homogeneous enhancement and the lesions can be misdiagnosed as meningiomas and neurilemmomas on CT scans (3, 5, 10, 16). On MRI, CSH show hypointensity or isointensity on T1-weighted and hyperintensity on T2-weighted images (5, 18). Parenchymal cavernomas are usually occult in angiographic studies but CSH generally have vascular blush in DSA. The blood supply of CSH usually come from branches of the intracavernous ICA (meningohypophyseal trunk) or external carotid artery via the middle meningeal or accessory meningeal arteries (5, 9).

CSH are well demarcated by the presence of a fibrous pseudocapsule as a dissection plane. Total removal of these lesions is difficult due to the risk of severe intraoperative bleeding and the complicated neurovascular structures of the cavernous sinus (4, 5, 18). Oculomotor, trochlear and trigeminal nerves can

be separated from the lesion by their dural sleeves but separation of the abducent nerve is difficult as it is not protected by a dural sheath (2,5,15). Only a few reported cases have been totally removed without cranial nerve injury (18).

The blood supply of CSH must be coagulated initially for devascularization of the lesion during surgery (5). This procedure helps to diminish the incidence of mortality which increases up to 12.5% as reported in the literature (1, 3, 5, 12). Tumor devascularization by intratumoral ethanol (7), plastic adhesive material (2) or fibrin glue injection (4) can help the neurosurgeon. Induced hypotension (12) or preoperative embolization (20) may also help to control the bleeding during surgery.

Radiation therapy has been recommended as a primary treatment or adjuvant therapy to decrease the size and vascularity of the mass (22). Stereotaxic radiotherapy or gamma knife can be performed to the rest of the tumor pieces or if the surgical excision is impossible (20, 13).

In conclusion, total removal of extra-axial CSH is difficult due to the risk of bleeding but surgery must always be considered as an option because of the benign characteristics of these lesions. Preoperative diagnosis is important since CSH are lesions with a high tendency to bleed. Gamma knife or stereotaxic radiotherapy may be chosen for residual tumors.

REFERENCES

1. Bristot R, Santoro A, Fantozzi L, Deflini R: Cavernoma of the cavernous sinus: Case report. *Surg Neurol* 48: 160-163, 1997
2. Hashimoto M, Yokota A, Ohta H, Urasaki E: Intratumoral injection of plastic adhesive material for removal of cavernous sinus hemangioma. *J Neurosurg* 93: 1078-1081, 2000
3. Kawai K, Fukui M, Tanaka A, Kuramoto S, Kitamura K: Extracerebral cavernous hemangioma of the middle fossa. *Surg Neurol* 9: 19-25, 1978
4. Kim IM, Yim MB, Lee CY, Son EI, Kim DW, Kim SP, Sohn CH: Merits of intralesional fibrin glue injection in surgery for cavernous sinus cavernous hemangioma. *J Neurosurg* 97: 718-721, 2002
5. Linskey ME, Sekhar LN: Cavernous sinus hemangiomas: A series, a review, and an Hypothesis. *Neurosurgery* 30: 101-108, 1992
6. Lombardi D, Giovanelli M, De Tribolet N: Sellar and parasellar extraaxial cavernous hemangiomas. *Acta Neurochir* 130: 47-54, 1994
7. Lonser RR, Heiss JD, Oldfield EH: Tumor devascularization by intratumoral ethanol injection during surgery; technical note. *J Neurosurg* 88: 923-924, 1998
8. Meyer FB, Lombardi D, Scheithauer B, Nichols DA: Extra-axial cavernous hemangiomas involving the dural sinuses. *J Neurosurg* 73: 187-192, 1990

9. Moore T, Ganti SR, Mawad ME: CT and angiography of primary extradural juxtaseellar tumors. *AJR* 145: 491-496, 1985
10. Mori K, Handa H, Gi H, Mori K: Cavernomas in the middle fossa. *Surg Neurol* 14: 21-31, 1980
11. Namba S: Extracerebral cavernous hemangioma of the middle cranial fossa. *Surg Neurol* 19: 379-388, 1983
12. Ohata K, Naggar AL, Takami T, Morino M, Adawy YE, El Sheik K, Inoue Y, Hakuba A: Efficacy of induced hypotension in the surgical treatment of large cavernous sinus cavernomas. *J Neurosurg* 90: 702-708, 1999
13. Peker S, Kiliç T, Şengöz M, Pamir MN: Radiosurgical treatment of cavernous sinus cavernous haemangiomas. *Acta Neurochir (Wien)* 146: 337-341, 2004
14. Rigamonti D, Hadley MN, Drayer BP, Johnson PC: Cerebral cavernous malformations: incidence and familial occurrence. *N Eng J Med* 319: 343-7, 1988
15. Rosenblum B, Rothman AS, Lanzieri C, Song S: A cavernous sinus cavernous hemangioma. *J Neurosurg* 65: 716-718, 1986
16. Sephernia A, Tatagiba M, Brandis A, Samii M, Prawitz R-H: Cavernous angioma of the cavernous sinus: case report. *Neurosurgery* 27: 151-155, 1990
17. Shi J, Hang C, Pan Y: Cavernous hemangiomas in the cavernous sinus. *Neurosurgery* 45: 1308-1314, 1999
18. Shi J, Wang H, Hang C, Pan Y, Liu C, Zhang Z: Cavernous hemangiomas in the cavernous sinus: Case report. *Surg Neurol* 52: 473-479, 1999
19. Suzuki Y, Shibuya M, Baskaya MK, Takakura S, Yamamoto M, Saito K, Glaizer SS, Sugita K: Extracerebral cavernous angiomas of the cavernous sinus in the middle fossa. *Surg Neurol* 45: 123-132, 1996
20. Thompson TP, Lunsford D, Flickinger JC: Radiosurgery for hemangiomas of the cavernous sinus and orbit: technical case report. *Neurosurgery* 47: 778-783, 2000
21. Voigt H, Yasargil MG: Cerebral cavernous hemangiomas or cavernomas: Incidence, Pathology, localization, diagnosis, clinical features and treatment: review of the literature and report of an unusual case. *Neurochirurgia (Stuttg)* 19: 59-68, 1976
22. Yamamoto Y, Weining Z, Ohashi T: Intracavernous cavernous hemangioma: dynamic CT findings and effectiveness of irradiation-case report. *Neurol Med Chir* 32: 93-95, 1992
23. Zabramski JM, Awasthi D: Extraaxial cavernous malformations, in Awad IA, Barrow DL (eds): *Cavernous Malformations*. Park Ridge III: AANS: 133-144, 1993