

Transorbital Stab Wound From A Speargun: A Case Report

Zıpkın ile Transorbital Delici Yaralanma Bir Olgu Sunumu

YUSUF ERŞAHİN, MEHDİ SADAT, TAŞKIN YURTSEVEN, SAFFET MUTLUER

Division of Pediatric Neurosurgery, Ege University Faculty of Medicine, İzmir, Turkey

Geliş Tarihi: 1.5.1998 ⇔ Kabul Tarihi: 25.8.1999

Abstract: Penetrating stab wounds of the skull rarely occur in civilians. In the absence of direct injury to the brainstem or laceration of a major intracranial vessel, the prognosis for these injuries is good. Transorbital stab wounds causing intracranial complications are more common in children than in adults, and are reported more often in boys than girls. A 9-year-old girl presented with a spear penetrating her left orbita. A cranial computed tomographic scan confirmed that the tip of the spearhead had passed through the left orbital roof and was penetrating the left temporal lobe. The barbed spearhead was removed via craniotomy after cutting off three of the spear's prongs. The child recovered completely after surgery and was neurologically intact 1 year following the injury. Postoperative magnetic resonance angiography (MRA) was also normal. Barbed objects should not be removed by retracing their route of entry. MRA can be used to screen for important potential vascular complications.

Key words: Transorbital injury, speargun, magnetic resonance angiography, stab wound

Özet: Sivillerde kafatasının penetran yaralanmaları nadirdir. Beyin sapının doğrudan yaralanması ya da büyük intrakranial damarların laserasyonunun olmadığı durumlarda prognoz iyidir. İntrakranial komplikasyonlara yolaçan transorbital delici yaralanmalar çocuklarda erişkinlere göre daha sıktır ve kızlardan daha çok erkeklerde bildirilmiştir. Sol orbitaya penetre zıpkınla 9 yaşında bir kız çocuğu kliniğimize getirildi. Bilgisayarlı tomografide zıpkının uçlarından bir tanesi sol orbita tavanından sol temporal loba uzanmaktaydı. Zıpkının üç ucu kökünden kesildikten sonra kraniotomi ile kancalı uç çıkarıldı. Operasyondan sonra hasta tamamen düzeldi ve bir yıl sonraki takibinde nörolojik defisiti bulunmamaktaydı. Postoperatif manyetik rezonans anjiyografi (MRA) normal bulundu. Ucu kancalı nesnelere girdikleri yoldan çıkarılmamalıdır. MRA'nın vasküler komplikasyonları taramada kullanılabilmesi akılda tutulmalıdır.

Anahtar Sözcükler: Transorbital yaralanma, zıpkın, manyetik rezonans anjiyografi, delici yaralanma

INTRODUCTION

Penetrating stab wounds of the skull are very rare in civilians (5,6,10,13,22). These are typically seen in the young adult male, and are usually related to interpersonal violence, assaults, and gang warfare (5,6,10,11,12,13,22). Only a small number of reported cases, particularly in children, have resulted from accidental stabbing (3,4,8,9,18). Here we report a case of transorbital stab wound from a speargun.

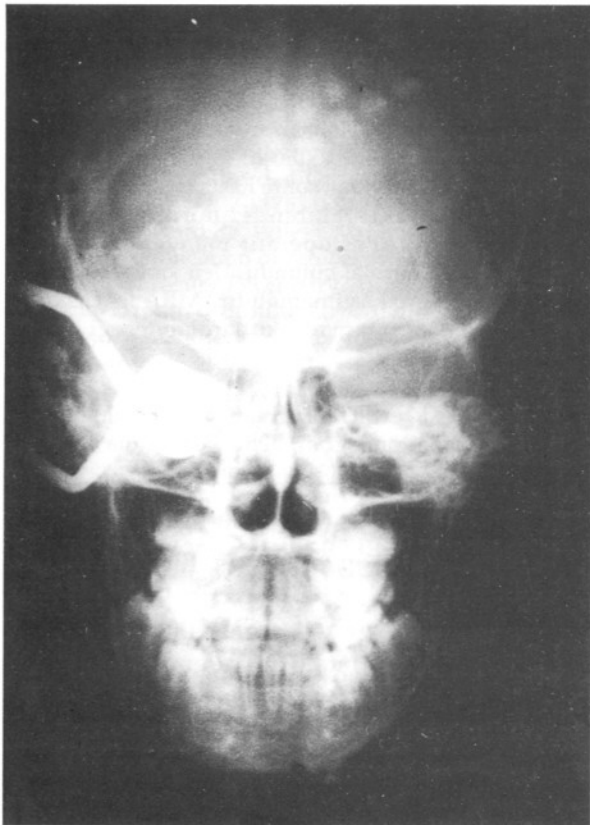
CASE REPORT

A 9-year-old girl presented with a spear penetrating her left orbita. The patient's brother had accidentally shot her with a speargun. She had vomited several times before admission. On presentation, the girl was drowsy but coherent and cooperative. One of three prongs of the spearhead had penetrated near the left inner canthus, and the left periorbital region was swollen (Figure 1).

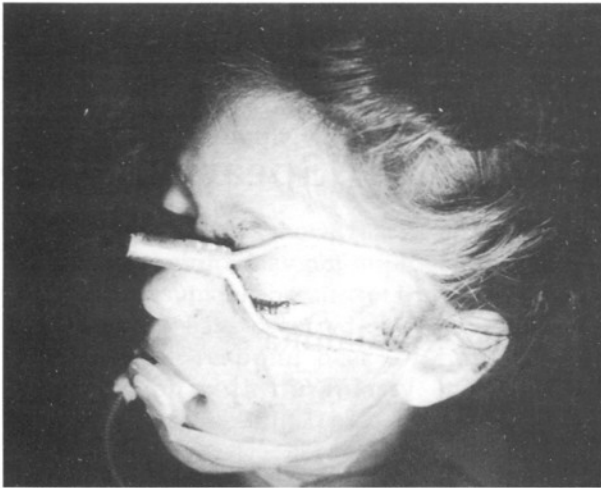

Figure 1: A photograph taken with the patient on the operating table shows one of the barbed spearheads in situ.

Neurological examination revealed no remarkable deficit. Plain x-ray films of the skull showed a spear with three barbs at the tip, one of which had penetrated the cranium (Figure 2). A cranial computed tomography (CT) scan confirmed that one tip had penetrated the left temporal lobe through the



left orbital roof (Figure 3). Tetanus prophylaxis was administered and the patient was started on antibiotics that covered gram-positive, gram-negative, and anaerobic organisms. The patient was transported to the operating room. Once she was anaesthetized, the three prongs of the spear were cut with a metal saw used by orthopedic surgeons and the shaft of the spear was then removed and discarded. Next, a frontotemporal craniotomy was performed and the one barbed tip was located a few millimeters beneath the surface of the cerebral cortex. An incision was then made through the cortex and the TIP was removed through this new clean wound, as opposed to the route of entry. The wound was irrigated and the surgical site was then closed in standard fashion.

Within a week, the periorbital swelling and chemosis had subsided. The vision in the patient's left eye was normal. Postoperative magnetic resonance imaging (MRI) showed the trajectory of the spear in the temporal lobe (Figure 4), and magnetic resonance angiography (MRA) was normal 1 week after the injury. MRA was repeated 6 months later, and revealed no vascular complications. The patient was asymptomatic and neurologically intact 1 year after the injury.

DISCUSSION

The mechanism of injury in transcranial stab wounds differs from that of missile or gunshot injuries in that here is no concentric zone of coagulative necrosis (7). Also, unlike in motor vehicle accidents, brain damage is restricted to the wound tract (15). In the absence of direct injury to the

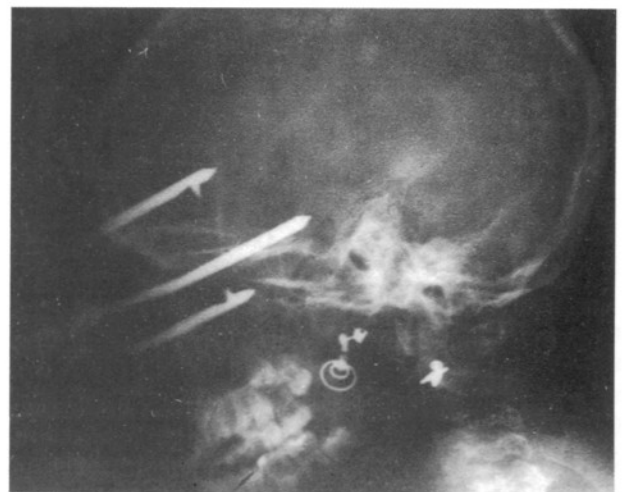


Figure 2: (a) Posterior-anterior and (b) lateral x-ray films of the skull show the penetrating spear.

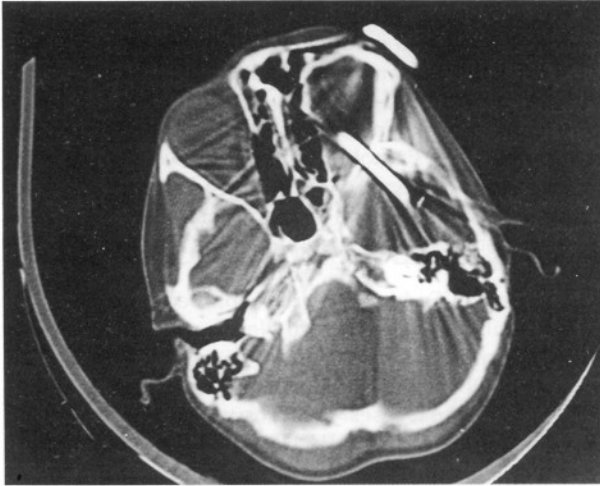


Figure 3: A CT scan shows one of the spearheads penetrating the left temporal lobe through the left orbital roof.

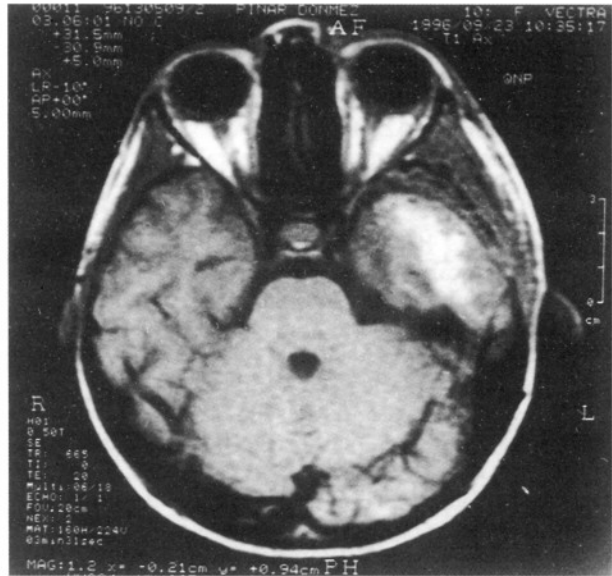


Figure 4: Note the blood in the trajectory of the spearhead on MRI.

brainstem or laceration of a major intracranial vessel, the prognosis is good for this type of injury. Transorbital stab wounds causing intracranial complications are more common in children than in adults, and are reported more often in boys than girls (6). Objects entering the orbit tend to be funneled toward the apex. Typically, the superior orbital fissure, or the thin orbital plate allows access to the intracranial contents in these cases. It has been noted that the globe often escapes injury if a slender-pointed instrument is used. In low-velocity stabbings, the eyeball moves into the space occupied by the copious orbital fatty tissue that surrounds the eye. However, the eyeball is frequently injured when a large object is involved (17,20).

Birch-Hirschfield (1) and Kjer (14) reported 30 cases of tetanus caused by transorbital injury. Ventricular damage, pneumocephalus, subdural, intracerebral and intraventricular hemorrhage damage to the cavernous sinus, carotid-cavernous fistulae traumatic cerebral aneurysms, occlusion of the carotid artery, and brain abscesses have all been reported as cerebral complications of transorbital stab wounds (2,6,13). CT scanning can detect intracranial damage or hematoma (19), but interpretation of CT scans may be seriously impaired by artifact when a penetrating metal object is embedded in the cranium.

Kieck and Villiers (13) found five cerebral aneurysms at the base of the brain in 20 cases following transorbital stab wound. They advised doing repeat cerebral angiograms to detect vascular damage. In 1969, Chaddock (4) operated on a 6-year-

old girl with a traumatic aneurysm of the middle cerebral artery following a speargun injury. A traumatic aneurysm usually ruptures between 2 and 6 weeks, and it has been recommended that angiography be done 7 to 10 days after injury (16). Transorbital speargun injuries are very rare, and, to our knowledge, only two cases have been reported in the English literature (17,21).

Maximal tissue damage with a barbed object occurs when the removal attempt retraces the route of entry. If we had removed the penetrating barbed spearhead this way, there could have been serious damage to the optic nerve and globe. In conclusion, tetanus prophylaxis and antibiotics may prevent the infectious complications of a stab wound. Barbed objects should not be removed by retracing the route of entry. MRA is advised as screening for potential important vascular complications.

Correspondence: Yusuf Erşahin
P.O. Box 30
Karşıyaka,
35602 İzmir, Türkiye

REFERENCES

1. Brisch-Hirschfield A: Puncture wound of the orbit. In: von Graefe A, Saemisch T (Eds) *Handbuch der gesamttem Augenheilkunde*. Berlin: Springer, 1930, pp 461-471

2. Bullock R, van Dellen JR: Acute carotid-cavernous fistula with retained knife blade after transorbital stab wound. *Surg Neurol* 24: 555-558, 1985
3. Bursick DM, Selker RG: Intracranial pencil injuries. *Surg Neurol* 16:427-431, 1981
4. Chadduck WM: Traumatic cerebral aneurysm due to speargun injury. Case report. *J Neurosurg* 31:77-79, 1969
5. De Villiers JC, Grant AR: Stab wounds at the craniocervical junction. *Neurosurgery* 17:930-936, 1985
6. De Villiers JC, Sevel D: Intracranial complications of transorbital stab wounds. *Br J Ophthalmol* 59:52-56, 1975
7. Demsey LC, Winestock DP, Hoff JT: Stab wounds of the brain. *West J Med* 126:1-4, 1977
8. Dujovny M, Osgood CP, Maroon JC, Janetta P: Penetrating intracranial foreign bodies in children. *J Trauma* 15:981-986, 1975
9. Erşahin Y Mutluer S, Güzelbağ E: Transorbital stab wound: a case report. *Turk J Ped* 36:71-77, 1994
10. Haworth CS, De Villiers JC: Stab wound to the temporal fossa. *Neurosurgery* 23:431-435, 1988
11. Herring CS, Lumsden AB, Tindall SC: Transcranial stab wounds: a report of three cases and suggestions for management. *Neurosurgery* 23:658-662, 1988
12. Khalil N, Elwany MN, Miller JD: Transcranial stab wounds: morbidity and medicolegal awareness. *Surg Neurol* 35:294-299, 1991
13. Kieck CF, De Villiers JC: Vascular lesions due to transcranial stab wounds. *J Neurosurg* 60:52-56, 1984
14. Kjer P: Orbital and transorbital stab wounds. *Arch Ophthalmol* 51:811-821, 1954
15. Lindenberg R: Trauma of meninges and brain In: Minder J (Ed) *Pathology of the Nervous System*, vol 2, New York: McGraw-Hill, 1977, pp 1721
16. Melville R, De Villiers JC: Peripheral cerebral arterial aneurysm caused by stabbing. *S Afr Med J* 51:471-473, 1977
17. Mezue WC, Saddeqi N, Ude A: Barbed spear injury to the skull base: case report. *Neurosurgery* 28:428-430, 1991
18. Reeves DL: Penetrating craniocerebral injuries: report of two unusual cases. *J Neurosurg* 23:204-205, 1965
19. Solomon KD, Pearson PA, Tetz MR, Baker RS: Cranial injury from unsuspected penetrating orbital trauma: a review of five cases. *J Trauma* 34: 285-289, 1993
20. Tani PM, Larsen PA, Carroll RP: An unusual knife injury to the orbit: a case report. *Ophthalmic Surg* 8: 43-46, 1977
21. Tanton JH, Elliott DC: Fishing-spear injury of the orbit. *Am J Ophthalmol* 64:973-974, 1967
22. Van Dellen JC, Lipschitz R: Stab wounds of the skull *Surg Neurol* 10:110-114, 1978