

Original Investigation

Stereotactic and Functional

# Precision of Intraoperative Cone-Beam Computed Tomography in Electrode Placement and Complications in Asleep Deep Brain Stimulation Surgery: A Multidetector Computed Tomography-Verified Comparative Study

Ali Haluk DUZKALIR<sup>1</sup>, Yavuz SAMANCI<sup>1,2</sup>, Selcuk PEKER<sup>1,2</sup>

<sup>1</sup>Koc University Hospital, Department of Neurosurgery, Istanbul, Turkiye

<sup>2</sup>Koc University, School of Medicine, Department of Neurosurgery, Istanbul, Turkiye

Corresponding author: Selcuk PEKER ✉ peker@selcukpeker.com

## ABSTRACT

**AIM:** To examine intraoperative cone-beam computed tomography (iCBCT) accuracy, and the need for postoperative imaging to confirm electrode position, and to assess the complications of deep brain stimulation (DBS) surgery.

**MATERIAL and METHODS:** Thirty-two movement disorder patients and 69 targets were retrospectively reviewed. All patients had preoperative non-stereotactic 3.0 Tesla magnetic resonance imaging (MRI), preoperative stereotactic multidetector computed tomography (MDCT), post-implantation iCBCT, and postoperative conventional MDCT scans. Stereotactic coordinates of electrode tips were compared between postoperative MDCT and iCBCT. We calculated the absolute and Euclidian differences (ED) between iCBCT and postoperative MDCT coordinates for each electrode. To assess whether intraoperative brain shifting influenced electrode tip localisation, subdural pneumocephalus volume was measured in iCBCT images.

**RESULTS:** The mean absolute (scalar) differences in x, y, and z coordinates were not significantly different from the absolute precision value of 0 ( $p>0.05$ ). The mean ED between the iCBCT electrode tip and the postoperative MDCT electrode tip coordinates was  $<1\text{mm}$  ( $0.55\pm 0.03\text{ mm}$ ) and differed significantly from zero ( $p<0.0001$ ). There was no correlation between pneumocephalus volume and electrode coordinate deviation.

**CONCLUSION:** iCBCT can eliminate the need for routine postoperative studies since it is a safe, effective, and rapid procedure that can be performed at any step of the surgery. It provides reliable and definitive confirmation of correct DBS electrode placement.

**KEYWORDS:** Precision, Deep brain stimulation, Euclidean distance, Intraoperative cone-beam computed tomography, Pneumocephalus

**ABBREVIATIONS:** CSF: Cerebrospinal fluid, CT: Computed tomography, iCT: Intraoperative computed tomography, iCBCT: Intraoperative cone-beam computed tomography, DBS: Deep brain stimulation, ED: Euclidean distance, ET: Essential tremor, GPi: Globus pallidus internus, IPG: Implantable pulse generator, MDCT: Multidetector computed tomography, MER: Microelectrode recording, MRI: Magnetic resonance imaging, PD: Parkinson's disease, PSA: Posterior subthalamic area, STN: Subthalamic nucleus, Vim: Ventral-intermediate nucleus, 3D: 3-dimensional.



## ■ INTRODUCTION

Deep brain stimulation (DBS) is increasingly used in the treatment of drug-resistant movement disorders, epilepsy, pain syndromes and psychiatric diseases in selected patients (22). Following appropriate patient selection, the electrodes should be placed in appropriate anatomical locations for effective and satisfactory results (8). Verifying the final electrode position is one of the primary challenges associated with the DBS procedure, which must be completed before proceeding to the implantable pulse generator (IPG) implantation step during surgery. For this reason, some medical centers opt to transport the patient from the operating room to the radiology unit to conduct magnetic resonance imaging (MRI) or multidetector computed tomography (MDCT), followed by a return trip to the operating room, which increases the surgical risks for the patient (7).

For neurosurgical performance assessment, intraoperative imaging modalities such as intraoperative magnetic resonance imaging (iMRI), intraoperative computed tomography (iCT), or cone-beam CT (iCBCT) have been shown to increase patient safety and provide a measure of immediate quality control. The O-arm™ system (O-arm O2 Imaging System; Medtronic Inc, Dublin, Ireland) is an iCBCT widely used in spinal and orthopedic surgery. The O-arm can provide both two-dimensional (2D) fluoroscopy and three-dimensional (3D) CBCT images. In recent years, the O-arm™ system has provided sufficient accuracy for intraoperative electrode localization (1,3,9). In our clinic, O-Arm™ has been used since October 2020 for intraoperative confirmation of electrode position accuracy in DBS surgery, and the new generation O-arm™ O2 enables conducting stereotactic registration (8). It reduces revision surgery rates by enabling verification of electrode coordinates in the operating room and correcting malpositions if any (17). However, many centers continue to perform an additional postoperative MRI or MDCT to confirm the electrode position and identify potential postoperative complications (9,17).

This retrospective clinical study aimed to evaluate the accuracy of iCBCT and the need for additional postoperative imaging to confirm electrode position and assess complications in DBS surgery.

## ■ MATERIAL and METHODS

We collected retrospective data from thirty-two patients who underwent DBS surgery for Parkinson's disease (PD), dystonia, and essential tremor (ET), and who underwent a complete set of preoperative non-stereotactic 3.0 Tesla MRI, preoperative stereotactic MDCT, post-implantation iCBCT, and postoperative conventional MDCT scan between October 2020 and October 2024.

All procedures performed in this study were in accordance with the ethical standards of the institutional and/or national research committee and with the 1964 Helsinki Declaration and its later amendments or comparable ethical standards. This study was approved by the Ethics Committee of Koc University Hospital (Decision date: 13.01.2022; Number: 2022.021.IRB1.016).

All patients underwent a complete preoperative 3.0 Tesla brain MRI one day before surgery. On the day of surgery, a Leksell® Coordinate Frame G (Elekta, Stockholm, Sweden) was mounted under general anesthesia, and a stereotactic MDCT was performed. MR and stereotactic MDCT images were then co-registered using BrainLab™ Elements (BrainLab, Inc., Munich, Germany), followed by distortion correction. The targets used according to the patients' indications were the subthalamic nucleus (STN), ventral intermediate nucleus (Vim), posterior subthalamic area (PSA) and globus pallidus internus (GPi).

After identification of the target coordinates, patients were transferred to the operating room, and surgery was performed. All surgeries were conducted under general anesthesia without microelectrode recording (MER). After implantation of all DBS electrodes, the skin incisions were completely closed, and a 0.8 mm slice thickness zero-gantry-angle iCBCT was performed without removing the frame. The images were then transferred to BrainLab™ Elements and co-registered with preoperative planning images. Once the surgeon was satisfied with the final position of the electrodes, the frame was removed, and the IPG was implanted subclavially and connected to the electrodes via extension cables. If there were no intraoperative and postoperative complications, a conventional MDCT was performed within the first six hours after the operation was completed, in order to verify electrode localization and possible complications. All patients were operated on at the same institution by the same neurosurgeon.

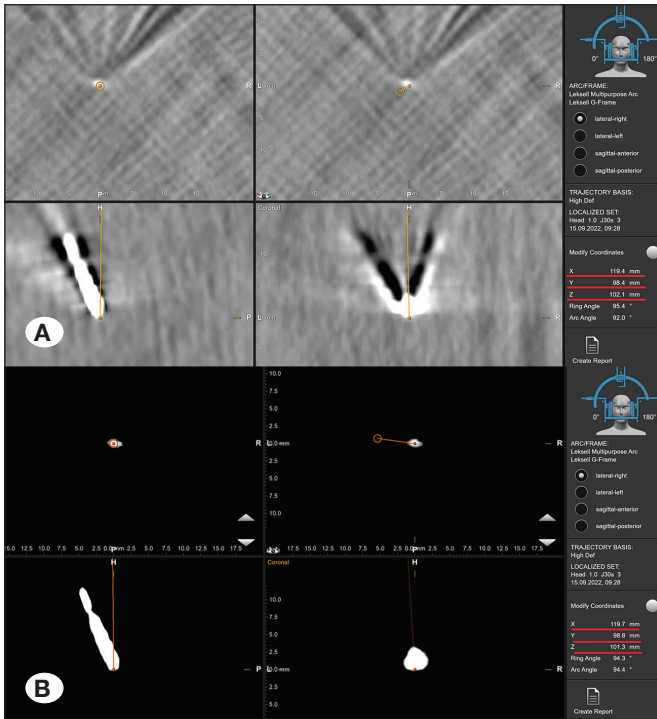
### iCBCT Accuracy Analysis

Preoperative stereotactic MDCT was used as a reference, and the coordinates (x, y, and z) of each electrode tip on the iCBCT images were compared separately with the coordinates on the postoperative MDCT images. For this purpose, the iCBCT images acquired after the implantation of electrodes were co-registered with the preoperative stereotactic MDCT images using BrainLab™ Elements. The coordinates of the electrode tips on the iCBCT images were then determined. The same procedure was performed by fusing postoperative MDCT images with preoperative stereotactic MDCT images.

The distance between electrode tip coordinates on iCBCT and postoperative MDCT images co-registered with preoperative stereotactic MDCT is 3-dimensional (3D). This distance was calculated using the Euclidean distance (ED) formula, which is not just the distance in one plane (like x, y, and z), but the distance between two points in 3D space. It is the square root of the sum of the squares of the differences in the x, y, and z directions:

$$ED = [(x_2 - x_1)^2 + (y_2 - y_1)^2 + (z_2 - z_1)^2]^{1/2}$$

Compared to MDCT, iCBCT images have more electrode artifacts, making it challenging to visualize the electrode tips clearly. Therefore, both iCBCT and postoperative MDCT images were darkened using the "windowing" option in BrainLab™ Elements to eliminate artifacts and to set a standard for precise detection of the electrode tips for both modalities. This allowed clear visualization of the electrode tips and determining the coordinates by eliminating metal artifacts in all planes (Figure 1).



**Figure 1:** Figures demonstrating the determination of the electrode tip coordinates from an intraoperative cone-beam computed tomography (iCBCT) series. **A)** Electrode tip marked on iCBCT images with obvious metal artifacts. **B)** Same iCBCT images darkened by the “windowing” option in BrainLab Elements. The tip of the electrode is more clearly visible. Note the coordinate differences in the measurements (red lines).

**Analysis of Pneumocephalus**

iCBCT images were evaluated for the presence of pneumocephalus to determine whether intraoperative brain shift significantly affected the accuracy of iCBCT measurements of the electrode tips. The volume of the air between the brain surface and the inner table of the skull in axial sections from the vertex to the level of the foramen magnum, was calculated using OsiriX DICOM viewer (Pixmeo SARL, Bernex, Switzerland) software.

**Statistical Analysis**

For each patient, iCBCT and postoperative MDCT electrode tip coordinates were compared in the x, y, and z directions. To assess the accuracy of the iCBCT, the mean absolute difference (± standard error of the mean) in each direction was calculated, and a student t-test was performed for each variable measured on iCBCT and the postoperative MDCT. The relationship between the volume of pneumocephalus and ED was assessed by the Pearson correlation. Statistical significance was defined as p<0.05.

**RESULTS**

Of the thirty-two patients included in the study, twenty-two were male, and ten were female, with a median age of 48

**Table I:** Demographics, Diagnosis, and Anatomical Targets Used in Patients Who Underwent DBS Implantation Surgery Using iCBCT

Parameters	n
Number of patients	32
Number of DBS electrodes	69
Median age, years	48
Male : Female	22 : 10
<b>Diagnosis</b>	<b>n (%)</b>
Dystonia	15 (46.8)
Parkinson’s disease	11 (34.4)
Essential tremor	6 (18.8)
<b>Anatomical targets</b>	<b>n (%)</b>
Globus pallidus internus	33 (47.8)
Subthalamic nucleus	26 (37.7)
Ventralis intermedius nucleus	8 (11.6)
Posterior subthalamic area	2 (2.9)

(range, 5-71). Fifteen patients underwent DBS surgery for dystonia, eleven for PD, and six for ET. Thirty-one patients underwent bilateral DBS surgery, while one received unilateral DBS. In three patients with two ET and one dystonia, four electrodes were placed bilaterally in two different targets. A total of sixty-nine electrodes were evaluated. Demographics, diagnosis, and anatomical targets are summarized in Table I.

Differences in x, y, and z coordinates and ED values (iCBCT vs. postoperative MDCT) were calculated for each implanted electrode. To measure precision, the mean absolute (scalar) differences in x, y, and z coordinates were calculated as 0.25 ± 0.04 mm, 0.32 ± 0.03 mm, and 0.37 ± 0.04 mm, respectively, which were not significantly different from the value of 0 considered as absolute precision (p=0.92, p=0.96, p=0.95, for x, y and z coordinates, respectively). The mean ED between the iCBCT electrode tip and the postoperative MDCT electrode tip coordinates was 0.55 ± 0.03 mm and differed significantly from zero (p<0.0001). When the coordinates of all electrodes were evaluated, the average absolute (scalar) difference was a maximum of 0.7 mm, and the ED was a maximum of 0.8 mm, with all values <1 mm.

Volumes of the subdural air images were analyzed to determine whether intraoperative pneumocephalus significantly affected the accuracy of O-Arm measurements of the electrode tips. The iCBCT images taken after electrode placement in twelve patients showed no pneumocephalus. In the remaining twenty patients, the volume of pneumocephalus ranged between 0.3-14.12 cm<sup>3</sup> (3.9 ± 1.7 cm<sup>3</sup>). There was no difference between the right and the left ED values and pneumocephalus volumes (p>0.05). None of the patients developed complications during hospitalization, including epidural, subdural, or intracerebral hemorrhage.

## ■ DISCUSSION

In this retrospective clinical study, the accuracy of iCBCT was compared with conventional MDCT, and iCBCT was found to be a safe and effective imaging modality that provided reliable and definitive intraoperative confirmation of correct electrode placement and detection of pneumocephalus by co-registering with preoperative planning. In our study, the spatial accuracy of O-Arm was statistically equivalent to MDCT. Therefore, O-Arm imaging after electrode placement may be sufficient alone to verify electrode coordinates.

DBS is a surgical intervention with confirmed efficacy and safety in the treatment of movement disorders, and it is also emerging as a promising therapeutic option for psychiatric disorders. The number of DBS surgeries has increased notably in recent years; however, there is still a broad spectrum of postoperative outcomes. Therefore, the electrodes should be placed in the most accurate coordinates possible.

Conventional MDCT and MRI have long been used for postoperative evaluation; nevertheless, they are costly and may bring about difficulties, especially in children, obese or claustrophobic patients. In addition, postoperative MDCT scanning for this purpose causes additional ionizing radiation exposure to patients (7). Several studies have compared the effective doses of MDCT and iCBCT, demonstrating that iCBCT significantly reduces the radiation dose (15,16). Similarly, using iCBCT in DBS surgery has been reported to significantly reduce (24-50% less) ionizing radiation exposure in patients (7,14,18,23).

iCBCT is a relatively new technique in imaging DBS electrodes, and the first case report was published in 2010, describing only the procedure without any quantitative data (2). The authors concluded that the fiducial box of the Leksell stereotactic frame could not fit within the O-arm's field of view, making the device unsuitable for frame registration.

Shahlaie et al. compared the accuracy of iCBCT scan with postoperative MRI in fifteen patients and found that electrode tip measurements with iCBCT and postoperative MRI scans were statistically similar, with mean vector and scalar differences between iCBCT and postoperative MRI of <1.1 mm in the x, y, and z coordinates (18).

Sharma and Deogaonkar investigated the accuracy of targeting using iCBCT during DBS surgery and reported the precision of iCBCT compared to postoperative CT in x, y, and z directions as  $0.65 \pm 0.09$  mm ( $p=0.84$ ),  $0.58 \pm 0.08$  mm ( $p=0.98$ ),  $1.13 \pm 0.10$  mm ( $p=0.08$ ), respectively. These differences in the cited studies did not reach statistical significance in any direction, as seen in our study ( $0.25 \pm 0.04$  mm,  $0.32 \pm 0.03$  mm, and  $0.37 \pm 0.04$  mm, respectively) (19).

Holloway and Docef investigated the accuracy of the final electrode position and reliability of target planning using stereotactic iCBCT compared with MDCT. They reported an ED value of  $0.72 \pm 0.38$  mm (9). Similarly, Smith and Bakay compared the accuracy of iCBCT with postoperative MRI in twelve patients (fifteen electrodes) using a frameless DBS system with MER. They reported the mean ED as  $1.52 \pm 1.78$

mm ( $p=0.0052$ ) and concluded that iCBCT might provide clues to electrode location during the procedure, especially in DBS procedures where electrophysiology is less valuable (21).

Carlson et al. evaluated the coordinates of 71 electrodes and reported no significant difference between the mean ED values of iCBCT, postoperative MRI, and postoperative CT (5). Two years later, they also published the findings of a retrospective study comparing the accuracy of stereotactic registration using images obtained with iCBCT and stereotactic CT. They reported that the ED values of stereotactic coordinates obtained with iCBCT, and CT registration were not significantly different (4).

In a recent clinical study and literature review reported by Furlanetti et al. regarding the benefits and cost-effectiveness of using iCBCT in DBS surgery, the results of twenty-six studies using intraoperative imaging (MRI, CT, or CBCT) were analyzed (7). The mean ED value was  $1.38 \pm 0.51$  mm in ten studies using iCBCT. The exact value was reported as  $1.79 \pm 0.60$  mm for nine intraoperative MRI studies and  $1.83 \pm 0.76$  mm for seven studies using iCBCT. The same study reported that the mean ED values in studies using iCBCT were significantly lower than those using intraoperative MRI or CT (iMRI vs. iCBCT,  $p<0.001$ ; iCT vs. iCBCT,  $p<0.001$ ). Although different workflows were used in these studies, the findings suggest that the accuracy of iCBCT may be superior to other modalities.

The mean ED value for our study was  $0.57 \pm 0.03$  mm. The mean ED values of the literature reported by Furlanetti et al. and the values reported in our study are less than the acceptable deviation of 2 mm (7). The mean ED value found in our study is significantly lower ( $p<0.05$ ) than the literature values reported by Furlanetti et al. (7). This may be because MER was used in most of these studies, and this difference in ED values may have occurred as a result of the final position of the electrodes in DBS surgeries using MER is determined not only according to MRI or anatomical atlas data but also according to electrophysiologic data.

A systematic review of the literature revealed a significant improvement in the accuracy of DBS surgery over the last fifteen years (from an initial mean ED value of  $1.90 \pm 0.69$  to  $1.50 \pm 0.50$  mm,  $p<0.001$ ), regardless of the stereotactic imaging method used to verify the final position of the electrodes (7). This may be due to advances in imaging equipment, new MRI sequences for image-based targeting, or software development for image fusion. The better accuracy of electrode coordinates in DBS surgeries using iCBCT compared to iCT and iMRI can be explained by faster image acquisition during surgery and easy retrieval to the surgical field when rescanning is required, resulting in less cerebrospinal fluid (CSF) leakage, and less brain shift (6,9,12).

To the best of our knowledge, this is the first study in the English literature evaluating the relationship between pneumocephalus and iCBCT use in DBS surgery. Contrary to previous studies, we did not find an association between pneumocephalus and the deviation of electrode coordinates (11,13,20). This may be due to the low rate of pneumocephalus in our cohort. Awake

surgery, number of brain penetrations (MER application), and experience have been reported as independent predictors for pneumocephalus (13). Our pneumocephalus rates may have been low since all surgical procedures in our study were performed under general anesthesia without MER. It is conceivable that the relationship between the use of iCBCT in DBS surgery and pneumocephalus may be shown in a study with higher statistical power.

Regarding the drawbacks of iCBCT, its major disadvantage compared to MDCT is the lack of reliable soft tissue visualization (10). The artifact of frame pins and electrodes further corrupts the image. Therefore, it is suboptimal for detecting ventricular penetration or intracerebral hemorrhage during DBS procedures (17). Consequently, MDCT is indicated in patients with unexpected side effects after surgery. iCBCT is also a large device, and it is, therefore, essential to plan the procedure prior to the surgery, prepare the setup to allow easy access to the patient if necessary, and maintain a sterile surgical field. We believe keeping the iCBCT in the surgical field is unnecessary during the entire operation. Instead, it may be moved into the surgical field after implantation of the electrodes to confirm their final positions. If repositioning of the DBS electrode is required, repeated imaging using the iCBCT may expose patients to repeated doses of ionizing radiation. It is also critical to be aware of the potential harm of increased radiation on the organization and workflow of the operating room.

### Limitations

This study has several limitations. Firstly, it is a relatively small, single-center, retrospective study, which may limit the power of statistical analyses and the generalizability of results, despite the fact that our patient cohort and the number of electrodes we evaluated are larger than those in similar studies. Future multi-center studies with larger patient cohorts would be beneficial to increase statistical robustness and improve the applicability of findings.

Another limitation can be the inherent inaccuracy introduced when iCBCT images are fused to the pre- or postoperative images. However, the poor soft tissue resolution of the iCBCT does not allow to use AC-PC line for measurements. The evidence needed to implement the iCBCT for stereotactic registration is nevertheless, in our view, sufficiently met through our data.

Finally, although our study demonstrates the effectiveness of iCBCT in confirming electrode placement, we did not assess the clinical outcomes and long-term effects associated with this approach. Future research including a detailed analysis of treatment outcomes could provide a more comprehensive evaluation of the effectiveness and safety of iCBCT in DBS procedures.

### CONCLUSION

iCBCT is a safe and effective procedure that provides reliable and definitive intraoperative confirmation of correct DBS electrode placement via fusion with preoperative planning. Rapid performance at any step of the surgery can eliminate

the need for routine postoperative studies. Additionally, iCBCT enables direct confirmation of electrode placement in the operating room, thereby eliminating the need to transfer the patient to another department for imaging. This capability significantly shortens the overall surgery time and reduces the risk of certain complications, such as infections, while also offering several benefits over MDCT or MRI, including reduction in costs, ionizing radiation exposure, image acquisition time, and patient discomfort, all while maintaining targeting accuracy.

### Declarations

**Funding:** No financial support was received for this research.

**Availability of data and materials:** The datasets generated and/or analyzed during the current study are available from the corresponding author by reasonable request.

**Disclosure:** All authors certify that they have no affiliations with or involvement in any organization or entity with any financial interest (such as honoraria; educational grants; participation in speakers' bureaus; membership, employment, consultancies, stock ownership, or other equity interest; and expert testimony or patent-licensing arrangements), or non-financial interest (such as personal or professional relationships, affiliations, knowledge or beliefs) in the subject matter or materials discussed in this manuscript.

### AUTHORSHIP CONTRIBUTION

Study conception and design: SP

Data collection: AHD, YS

Analysis and interpretation of results: AHD, YS

Draft manuscript preparation: AHD, YS

Critical revision of the article: SP

All authors (AHD, YS, SP) reviewed the results and approved the final version of the manuscript.

### REFERENCES

1. Bot M, Van Den Munckhof P, Bakay R, Stebbins G, Verhagen Metman L: Accuracy of intraoperative computed tomography during deep brain stimulation procedures: Comparison with postoperative magnetic resonance imaging. *Stereotact Funct Neurosurg* 95:183-188, 2017. <https://doi.org/10.1159/000475672>.
2. Caire F, Gantois C, Torny F, Ranoux D, Maubon A, Moreau JJ: Intraoperative use of the medtronic O-arm for deep brain stimulation procedures. *Stereotact Funct Neurosurg* 88:109-114, 2010. <https://doi.org/10.1159/000280823>.
3. Caire F, Guehl D, Burbaud P, Benazzouz A, Cuny E: Intraoperative 3D imaging control during subthalamic Deep Brain Stimulation procedures using O-arm® technology: Experience in 15 patients. *Neurochirurgie* 60:276-282, 2014. <https://doi.org/10.1016/j.neuchi.2014.05.005>.
4. Carlson JD: Stereotactic registration using cone-beam computed tomography. *Clin Neurol Neurosurg* 182:107-111, 2019. <https://doi.org/10.1016/j.clineuro.2019.05.004>.
5. Carlson JD, McLeod KE, McLeod PS, Mark JB: Stereotactic accuracy and surgical utility of the O-arm in deep brain stimulation surgery. *Operative Neurosurgery* 13:96-107, 2017. <https://doi.org/10.1227/NEU.0000000000001326>.

6. Ellenbogen JR, Tuura R, Ashkan K: Localisation of DBS electrodes post-implantation, to CT or MRI? Which is the best option? *Stereotact Funct Neurosurg* 96:347-348, 2018. <https://doi.org/10.1159/000493576>.
7. Furlanetti L, Hasegawa H, Oviedova A, Raslan A, Samuel M, Selway R, Ashkan K: O-arm stereotactic imaging in deep brain stimulation surgery workflow: A utility and cost-effectiveness analysis. *Stereotact Funct Neurosurg* 99:93-106, 2021. <https://doi.org/10.1159/000510344>.
8. Holewijn RA, Bot M, van den Munckhof P, Richard Schuurman P: Implementation of intraoperative cone-beam computed tomography (O-arm) for stereotactic imaging during deep brain stimulation procedures. *Operative Neurosurg* 19: E224-229, 2020. <https://doi.org/10.1093/ons/opaa110>.
9. Holloway K, Docef A: A quantitative assessment of the accuracy and reliability of O-arm images for deep brain stimulation surgery. *Neurosurgery* 72 Suppl Operative 1:47-57, 2013 <https://doi.org/10.1227/NEU.0b013e318273a090>.
10. Katisko JPA, Kauppinen MT, Koivukangas JP, Heikkinen ER: Stereotactic operations using the O-arm. *Stereotact Funct Neurosurg* 90:401-409, 2012. <https://doi.org/10.1159/000341699>.
11. Kim YH, Kim HJ, Kim C, Kim DG, Jeon BS, Paek SH: Comparison of electrode location between immediate postoperative day and 6 months after bilateral subthalamic nucleus deep brain stimulation. *Acta Neurochir* 152:2037-2045, 2010. <https://doi.org/10.1007/s00701-010-0771-x>.
12. Mirzadeh Z, Chapple K, Lambert M, Dhall R, Ponce FA: Validation of CT-MRI fusion for intraoperative assessment of stereotactic accuracy in DBS surgery. *Mov Disord* 29:1788-1795, 2014. <https://doi.org/10.1002/MDS.26056>.
13. Mirzadeh Z, Chen T, Chapple KM, Lambert M, Karis JP, Dhall R, Ponce FA: Procedural variables influencing stereotactic accuracy and efficiency in deep brain stimulation surgery. *Oper Neurosurg* 17:70-78, 2019. <https://doi.org/10.1093/ons/opy291>.
14. Peng T, Kramer DR, Lee MB, Barbaro MF, Ding L, Liu CY, Kellis S, Lee B: Comparison of intraoperative 3-dimensional fluoroscopy with standard computed tomography for stereotactic frame registration. *Oper Neurosurg* 18:698-709, 2020. <https://doi.org/10.1093/ons/opz296>.
15. Pietzka S, Grieser A, Winter K, Schramm A, Metzger M, Semper-Hogg W, Grunert M, Ebeling M, Sakkas A, Wilde F: Comparison of the effective radiation dose in the region of the facial skull between multidetector CT, dental conebeam CT and intraoperative 3D C-arms. *Cranio-maxillofac Trauma Reconstr* 17:270-278, 2023. <https://doi.org/10.1177/19433875231213906>.
16. Schafer S, Nithianathan S, Mirota DJ, Uneri A, Stayman JW, Zbijewski W, Schmidgunst C, Kleinszig G, Khanna AJ, Siewerdsen JH: Mobile C-arm cone-beam CT for guidance of spine surgery: Image quality, radiation dose, and integration with interventional guidance. *Med Phys* 38:4563-4574, 2011. <https://doi.org/10.1118/1.3597566>.
17. Servello D, Zekaj E, Saleh C, Pacchetti C, Porta M: The pros and cons of intraoperative CT scan in evaluation of deep brain stimulation lead implantation: A retrospective study. *Surg Neurol Int* 7:S551-556, 2016. <https://doi.org/10.4103/2152-7806.187534>.
18. Shahlaie K, Larson PS, Starr PA: Intraoperative computed tomography for deep brain stimulation surgery: Technique and accuracy assessment. *Neurosurgery* 68 Suppl Operative 1:114-124, 2011. <https://doi.org/10.1227/NEU.0b013e31820781bc>.
19. Sharma M, Deogaonkar M: Accuracy and safety of targeting using intraoperative "o-arm" during placement of deep brain stimulation electrodes without electrophysiological recordings. *J Clin Neurosci* 27:80-86, 2016. <https://doi.org/10.1016/j.jocn.2015.06.036>.
20. Sillay KA, Kumbier LM, Ross C, Brady M, Alexander A, Gupta A, Adluru N, Miranpuri GS, Williams JC: Perioperative brain shift and deep brain stimulating electrode deformation analysis: Implications for rigid and non-rigid devices. *Ann Biomed Eng* 41:293-304, 2013. <https://doi.org/10.1007/s10439-012-0650-0>.
21. Smith AP, Bakay RAE: Frameless deep brain stimulation using intraoperative O-arm technology: Clinical article. *J Neurosurg* 115: 301-309, 2011. <https://doi.org/10.3171/2011.3.JNS101642>.
22. Suchorska B, Ruge MI: Deep brain stimulation: Current applications and future prospects. *Discov Med* 20:403-411, 2015.
23. Zhang K, Bhatia S, Oh MY, Cohen D, Angle C, Whiting D: Long-term results of thalamic deep brain stimulation for essential tremor: Clinical article. *J Neurosurg* 112:1271-1276, 2010. <https://doi.org/10.3171/2009.10.JNS09371>.