



Tumour Shrinkage and Good Facial Nerve Function After Planned Partial Resection and Gamma Knife Radiosurgery in Koos 4 Vestibular Schwannoma

Mohammed AL-AHMARI^{1*}, Max KEIZER^{2*}, Bander AL-DHAFERY¹, Daniëlle EEKERS³, Koos HOVINGA², Henricus KUNST^{4,5}, Yasin TEMEL²

¹King Fahad Hospital of Imam Abdulrahman Bin Faisal University, Department of Radiology, Al-Khobar, Zip code 34445, Saudi Arabia.

²Maastricht University Medical Centre, Medicine and Life Sciences, Faculty of Health, School for Mental Health and Neuroscience (MHeNS), Department of Neurosurgery, P.O. Box 5800, 6202 AZ Maastricht, the Netherlands

³Maastricht University Medical Centre, GROW – School for Oncology and Developmental Biology, Department of Radiation Oncology (Maastricht), Maastricht, the Netherlands

⁴Maastricht University Medical Center, Department of Otorhinolaryngology, Maastricht, the Netherlands

⁵Radboud University Medical Center, Department of Otorhinolaryngology, Nijmegen, the Netherlands

*Both authors contributed equally

Corresponding author: Max KEIZER ✉ max.keizer@mumc.nl

ABSTRACT

AIM: To evaluate clinical and radiological outcome in surgically treated Koos 4 vestibular schwannomas.

MATERIAL and METHODS: Volumetric analysis of the tumour volumes before surgery, after surgery (before radiation), and at follow-up time-points after radiation was performed. Clinical data on facial nerve function and complications were collected. Approximately 6 months after surgery, all patients were treated with a single fraction of stereotactic radiosurgery using the gamma knife radiosurgery with a mean marginal dose of 12.9 Gy to the residual tumour volume.

RESULTS: Mean tumour volume was 11.64 cm³ which was reduced to a mean volume of 4.17 cm³ after partial resection. After a mean follow-up of 100 months, residual tumour showed a decrease in volume in 20 patients, stable disease in one patient and two patients showed progressive tumour volume requiring a second operation in one patient. Facial nerve function was preserved in all patients. One patient suffered from a trigeminal neuralgia after radiation.

CONCLUSION: Planned partial resection followed by radiation for patients with Koos 4 vestibular schwannoma is an effective strategy to preserve facial nerve function and achieve tumour control. Residual tumours after planned partial resection showed a mean decrease in volume of 50% at the last follow-up time point.

KEYWORDS: Vestibular schwannoma, Partial resection, Gamma knife, Tumour volume, Facial nerve

INTRODUCTION

Vestibular schwannoma (VS) is a benign skull base tumour resulting from the proliferation of Schwann cells of the vestibulocochlear nerve (56). VS is a slow growing tumour that usually expands from the internal auditory canal

(IAC) toward the cerebellopontine angle (CPA). VS accounts for 10% of all intracranial tumours and approximately 90% of all tumours in the CPA (24,56). In the last two decades, the use of magnetic resonance imaging (MRI) has contributed to more incidental detection of VS. In up to 0.07% of individuals undergoing an MRI of the brain, a VS was detected (24,46). A

Mohammed AL-AHMARI : 0000-0001-8316-2088

Max KEIZER : 0000-0001-8263-9550

Bander AL-DHAFERY : 0000-0003-4666-9730

Daniëlle EEKERS : 0000-0003-1917-6279

Koos HOVINGA : 0000-0002-1415-8189

Henricus KUNST : 0000-0003-1162-6394

Yasin TEMEL : 0000-0002-3589-5604



This work is licensed by "Creative Commons Attribution-NonCommercial-4.0 International (CC)".

recent study suggested that within the United States alone, the incidence rate has increased significantly from 1.5 over the past half-century to 4.2 per 100,000 persons in the last decade (31). Since the vestibulocochlear nerve is responsible for hearing and balance, VS patients usually show symptoms related to these functions, such as tinnitus, hearing loss, vertigo, and headache (35,47,50,55). Symptoms vary from one patient to another and are mostly dependent on tumour volume (43). Common treatment strategies are the 'wait and scan policy', surgical resection, and/or stereotactic radiosurgery (SRS) (43). Taking into account differences in patient characteristics, treatment selection is highly dependent on tumour volume and unilateral or bilateral (neurofibromatosis type 2 (NF2)) occurrence (59). VS size is classified into four grades using the Koos grading scale: intracanalicular (Koos 1), intra-/extrameatal (Koos 2), tumour touching the brainstem (Koos 3), and tumour compression of the brain-stem (Koos 4) (20). This study focuses predominantly on Koos 4 VS.

Large VS compress the brainstem and may cause symptoms of cranial nerve disorders, ataxia, hydrocephalus and cerebrospinal tract impairment and therefore prompts a surgical decompression. Over the past decades, complete tumour resection has been considered the treatment of first choice (26,30). This strategy has shown high rates of VS control, ranging between 90.9–100% (49). However, as the tumour is often adjacent to the facial nerve (FN) in large VS, preserving this critical structure combined with the goal of leaving no residual tumour creates a major challenge. In a recent systematic review, the pooled overall gross-total resection rate was estimated to be 77%, with higher rates associated with surgeon's experience (49). Good facial nerve function House-Brackmann (HB) Grade 1 or 2 after total resection fluctuated between 27% and 85% (11,26,30,45,57,60,61). Leaving a residue of VS around the FN (partial or subtotal resection) ensures better preservation of neurological and sensory functions. Yet, partial resection alone was found to be associated with a higher probability of tumour growth in up to 53% of cases (3,10,16,42,51).

In large VS, SRS alone may cause transient swelling, adding more compression to the brainstem and is therefore not the preferred first treatment (54); however, it has shown to better control small to medium VS (on a scale ranging from 87% to 97%) with favourable FN function outcomes (5,6,29). Therefore, a combined approach of partial resection with irradiation of the residual tumour seems to be a logical treatment for large VS. Throughout the last two decades, Gamma Knife (GK) radiosurgery after partial resection, with a marginal dose between 12–13 Gy to the residual tumour, has shown beneficial FN function outcomes, ranging between 86% and 100%, with tumour control rates of 79% and higher (7,15,22,23,39,40,41,53,58). This slightly more conservative approach has gained gradual attention among the skull base surgical community. Nine studies (7,15,22,23,39,40,41,53,58) have reported on using this combined approach.

The aim of our retrospective study is to illustrate local control, FN outcomes, surgical complications, and radiotherapy side effects in managing Koos 4 VS using this combined approach.

■ MATERIAL and METHODS

Inclusion and Exclusion Criteria

After obtaining permission from the medical ethical committee (METC 2018-0843), data were collected retrospectively. All patients harbouring histopathologically confirmed Koos 4 VS treated via a partial resection followed by GK radiosurgery, with preoperative and postoperative MRI scans, were included in the study. This study included patients from 2007 until 2018 with all required treatment data available.

Imaging Protocol and Clinical Workflow

All patients received a 1 mm T1-weighted contrast-enhanced brain MRI and a T2-weighted 0.6 mm (cochlea sequence) axial imaging of the cerebellopontine area. This protocol was performed preoperatively and during follow-up. All surgically treated patients with VS were discussed in the multidisciplinary skull base team. According to the local protocol, patients with Koos 4 and occasionally Koos 3 VS (if the patient had a strong preference for surgery) were treated with the combined approach. All patients presented with severe hearing loss. Therefore, tumour resection was conducted via the translabyrinthine route with the aim of achieving tumour volume reduction and FN preservation. This approach included dissection of the internal auditory meatus, besides mastoidectomy and labyrinthectomy, with secure exposition of the FN. To avoid any damage to FN, electromyography based two-channel facial monitoring was used during surgery. Surgeries were performed in a joint effort involving experienced surgeons from both otorhinolaryngology (ENT) and the neurosurgery departments. The ENT surgeon started with the labyrinthectomy, and the neurosurgeon resected the tumour. After surgery, the patient was discharged within 3–5 days and a follow up appointment was scheduled after approximately three months.

GK Radiosurgery

Within six months after surgery the residual VS was treated with GK radiosurgery, a dose between 12.0 and 13.0 Gy (mean: 12.9 Gy) was prescribed, covering 99% of the residual tumour. All radiosurgery treatments were performed using the Leksell Gamma Knife 4C and, from 2008 onwards, the Leksell Gamma Knife Perfection, and from 2015 the Gamma Knife Icon. To ensure the exact delivery of the prescribed dose, the GK centre used a volumetric 1 mm (without slice gap) T1-weighted contrast-enhanced MRI and 0.8 mm T2 weighted MRI for planning purposes.

Definition of Radiological and Clinical Control

In order to assess tumour volumes, four MRI scans were retrieved from the database system for each patient. These scans represented a chronological sequence of when the tumour was initially diagnosed (V_{T1}), after surgery (V_{T2} tumour volume at the time of GK), first MRI scan after GK (V_{T3}), and at the last available follow-up (V_{T4}). Based on the literature, VS patients might have an increase in tumour volume following GK (pseudo-progression or transient swelling), which will resolve in time (19). The first and second authors (radiologist with neuro imaging expertise) performed all volume measurements

manually using 3DSlicer (<https://www.slicer.org/>), (Figure 1) (12).

Radiological control refers to the status of the tumour volume at V_{T_4} in relation to V_{T_2} by calculating the change. A difference of 20% between scans was considered the measurement error (38,52). Therefore, the tumour status at V_{T_4} was classified into three categories: regression when V_{T_4} is less than 80% of V_{T_2} ; stable when the V_{T_4} is within a margin of $\pm 20\%$ from V_{T_2} ; progression when V_{T_4} is larger than 120% of the V_{T_2} . Clinical

control refers to the absence of the need for further treatment (GK or surgery) after completing the initial treatment approach.

Statistical Analyses

Forward stepwise ANOVA regression was applied to find any predictive variable in relation to the tumour volume at the last follow-up (V_{T_4}). The tumour volume V_{T_4} was the dependent variable and included the following variables in the candidate pool of predictors: age, sex, tumour location, tumour volume

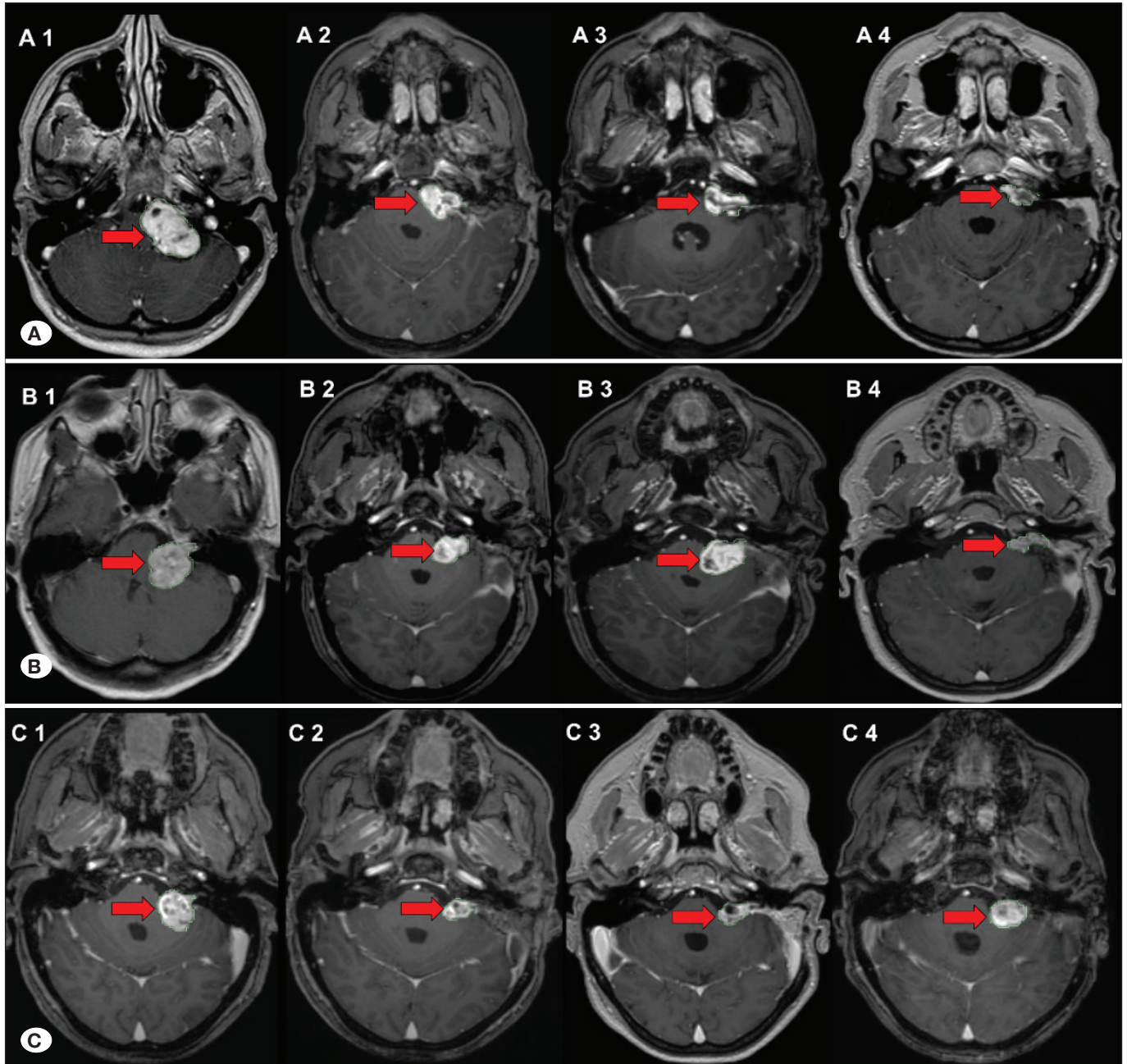


Figure 1: Transverse T1 3D MRI scans with gadolinium contrast in three patients (A, B, C) with left sided VS, representing tumour shrinkage (A), transient swelling followed by shrinkage (B), and progression (C). 1 = pre-operative tumour, 2 = tumour before Gamma Knife, 3 = tumour 15 months after Gamma Knife, 4 = last follow-up.

before and after surgery, tumour volume directly after GK, time interval between surgery and GK, and time interval between GK and the last follow-up. The level of significance was set at p -value ≤ 0.05 , and all statistical tests were performed using the IBM Statistical Package for Social Science (SPSS) software, version 26.0.

■ RESULTS

Demographic and Treatment Data

A total of 23 patients with complete datasets were included in the analysis. This group consisted of 13 (57%) females and 10 (43%) males, with a mean age of 49 (range 22-73 years). Prior to surgery, all patients presented with hearing loss. Other symptoms included ataxia, vertigo, and tinnitus. Most of the VS tumours (74%) were located on the left side of the brain (17 left versus 6 on the right), and the mean tumour volume before surgery was 11.64 cm^3 (range $4.59 - 31.02 \text{ cm}^3$). All patients underwent planned partial resection, and the mean residual volume was 4.17 cm^3 (range $1.29 - 10.99 \text{ cm}^3$). Following surgery by a mean (SD) time of $6 (\pm 2)$ months, all patients received a marginal dose of 12- 13 Gy covering 99% of the tumour volume.

Tumour Control

After a mean follow-up time of 100 months (range 42-170) after GK, tumour control was achieved in 21 patients (91% control rate), and two patients showed tumour volume increase requiring re-operation in one (4%). Interval between GK radiosurgery and the progression manifestation in this patient was 16 months. The tumour control group showed two patterns of response: shrinkage in 20 patients (87%) and stable in one patient (4%). Five patients experienced transient progression after GK followed by shrinkage (Table I), (Figure 1).

Forward Stepwise Regression

Tumour volume at the last follow-up (dependent variable) showed no linear relationship with any of the predictor variables (age, sex, tumour location, volumes before and after surgery, interval between surgery and GK, and interval between GK and the last follow-up), except with the volume after GK. Volume after GK accounted for 41% of the variation in volume at the last follow-up, and the ANOVA test indicated that the model was significant ($p < 0.001$). This implies that overall, patients responded well to the surgical approach in combination with GK treatment.

Functional Preservation

Prior to surgery, all patients had a normal functioning FN (H-B Grade 1). These functions were maintained after surgery in all except one patient who had a temporary H-B Grade 3 that was resolved after four weeks. At the time of the last follow-up, normal FN function was achieved in all patients.

Surgical Complications and Radiation-Induced Effects

In this cohort, no patient developed an infection, bleeding, or any surgical-related complication after surgery. However, one

patient developed communicating hydrocephalus three years after the combined therapy and required a ventriculoperitoneal shunt. One patient underwent a second surgery due to tumour progression. Concerning early radiation-induced toxicities, only one patient suffered from a temporary paraesthesia in the trigeminal area. This developed six years later into a trigeminal neuralgia, which was treated with carbamazepine. No other late toxicities were seen in any of the patients.

■ DISCUSSION

The present study assessed the feasibility of managing Koos 4 VS more conservatively by utilizing the combined approach. All patients had a Koos 4 VS, and suffered from complete hearing loss on the side of the tumour and had normal FN function. Therefore, the goal of surgery was to reduce the mass effect and preserve FN functionality by leaving some rest tumour around the FN. After surgery, the mean tumour volume was reduced from 11.64 cm^3 to 4.17 cm^3 . GK radiosurgery within 6 months after surgery resulted in tumour control in 91% of the patients with a mean follow-up of 100 months. This control is within the range of rates that have been published in studies reporting on the combined approach (79-100%) (7,15,22,23,39,40,41,53,58). These rates were pooled by a recent systematic review aiming at a better assessment of the efficacy of the combined approach in large VS. Two hundred and thirty patients with a tumour volume ranging from 1.16 to 9.35 cm^3 (at the time of the SRS) were included in the analysis, and the estimated overall tumour control rate was 93.9% after 46 months (48).

To evaluate the tumour's response after treatment, all tumours were delineated manually to estimate a three-dimensional volume. Although this method takes more time than the traditional two-dimensional method, it is more accurate and has been found to be associated with a lower inter-observer error (27,52). At the last follow-up after GK irradiation, tumour stability was reported in one patient (4%), shrinkage in 20 patients (87%), and increase in volume in two patients (8%). Reducing the tumour volume allowed the GK radiosurgery to control residues in a comparable way to small-to-medium-sized VS ($< 3 \text{ cm}$) when treated primarily by SRS, 92.7% after a mean follow-up of 51.24 months, reported by a meta-analysis study (44). Interestingly, in our cohort five tumours demonstrated post-radiation growth followed by shrinkage. Okunaga et al. stated that a true VS progression is only assured if the tumour growth continues for more than two years (37), and more recently, Fouard et al. indicated that a minimum five years of follow-up is required (14).

The challenge in VS management is that there is no specific method for identifying the growth rate or tumour behaviour. For example, a study that aimed to characterize the growth rate in 381 patients with small-to-medium-sized VS following a wait-and-scan policy reported that 32.5% had growth progression, 59.3% of the tumours remained stable, and 8.1% shrank after a mean interval of 4.2 years between the first and last scans (34). Although no interventions were done, some tumours shrank. It is also known that VS may grow again, even after being macroscopically completely resected

Table I: Vestibular Schwannoma Volume Measurements in cm³ for All Patients at Four Time Points: (V_{T1}) Before Surgery, (V_{T2}) Before GK, (V_{T3}) After GK, and (V_{T4}) at the Last Follow-Up. Furthermore, the Disease Status and Follow-Up Duration are Displayed. *Case 2 underwent a second operation, the pre- and post-op volumes are presented.

Case	V_{T1}	V_{T2}	Amount of resection	V_{T3}	V_{T4}	Volume difference [$V_{T2}-V_{T4}$]	% of volume difference	Tumour control	Follow-up time (months)
1	7.12	2.14	70%	2.05	2.36	-0.22	+ 10%	Stable	79
2	4.59	1.74	62%	1.87	4.51/1.24*	-2.77	+ 159%	Progression	80
3	31.02	9.93	68%	6.35	3.06	6.87	- 69%	Shrinkage	106
4	17.66	8.23	53%	7.56	6.06	2.17	- 26%	Shrinkage	76
5	5.00	1.49	70%	1.30	0.15	1.34	- 90%	Shrinkage	72
6	10.9	2.28	79%	1.60	0.17	2.11	- 92%	Shrinkage	99
7	7.00	4.42	37%	3.55	1.88	2.54	- 57%	Shrinkage	72
8	4.91	2.92	40%	4.08	3.66	-0.74	+ 25%	Progression	75
9	11.00	4.88	56%	5.18	2.34	2.54	- 52%	Shrinkage	93
10	7.00	2.08	70%	1.44	0.44	1.64	- 79%	Shrinkage	42
11	8.62	4.24	51%	3.52	2.45	1.79	- 42%	Shrinkage	101
12	12.28	5.57	55%	5.88	2.28	3.29	- 59%	Shrinkage	66
13	9.35	3.27	65%	1.80	1.04	2.23	- 68%	Shrinkage	57
14	5.47	1.29	76%	1.00	0.34	0.95	- 74%	Shrinkage	119
15	10.57	5.60	47%	5.39	2.92	2.68	- 48%	Shrinkage	74
16	7.66	3.35	56%	2.74	1.92	1.43	- 43%	Shrinkage	139
17	20.00	3.86	81%	1.65	0.93	2.93	- 76%	Shrinkage	116
18	20.20	6.64	67%	3.76	1.13	5.51	- 83%	Shrinkage	125
19	5.40	1.76	67%	1.33	0.27	1.49	- 85%	Shrinkage	147
20	17.93	10.99	39%	9.40	2.62	8.37	- 76%	Shrinkage	141
21	22.02	3.45	84%	2.96	1.74	1.71	- 50%	Shrinkage	141
22	15.45	2.52	84%	2.69	1.01	1.51	- 60%	Shrinkage	104
23	6.54	3.17	51%	6.23	0.18	2.99	- 94%	Shrinkage	170

(36). Moreover, it is possible for patients undergoing radiation therapy to develop a late transient tumour enlargement (within four years after being irradiated) followed by shrinkage (14,32). Important to note is that many factors such as inflammation, and angiogenesis can influence the biological behaviour and volumetric growth of sporadic VS (8,9).

A key finding in the current study was the successful preservation of FN function in all patients (100%). This finding is in line with most of the previously published rates after the combined approach, which range from 85.7% to 100% (48). In literature, total resection of large VS as a treatment method takes up the largest number of previous publications and normally includes large sample sizes (49). This treatment preference is, mainly due to the excellent tumour control rates,

reported in many articles (49). However, the FN preservation after total resection is highly dependent on the surgeon's experience (4,33). With an increase in VS volume, the FN will be stretched around the tumour and become thinner, making it more susceptible to injury during surgery (17). A dysfunction in the FN may significantly influence the patient's quality of life (39,43). Hence, a more conservative resection combined with GK radiosurgery may be considered beneficial for both the patient and the treating surgeon as it may ease the procedure for the surgeon and assure a high chance of functional preservation for the patient.

The absence of post-surgical and GK complications observed in the current study was in accordance with previous studies on the combined approach. Table II indicates that complications

Table II: Data Related to Surgical Complications and Radiation-Induced Effects Following the Subtotal Resection of Large VS and Subsequent GK Radiosurgery, Respectively. These Data were Extracted from the 10 Studies That Followed the Combined Approach, Including the Current Study

Reference	Number of Patients	Surgical Approach	Surgical Complications	Mean Prescribed (marginal) dose, in Gy. (range)	Radiation-Induced Effects
Iwai et al., (23)	14	13 Retrosigmoid & 1 Transtentorial	No complications	12.1 (10–14.1)	No complications
Park et al., (40)	8	NR	-	12	No complications
Yang et al., (58)	61	Retrosigmoid	NR	11.8 (11-13)	No complications
Fuentes et al., (15)	8	NR	NR	12.5 (9-14)	No complications
Van de Langenberg et al., (53)	50	25 Retrosigmoid & 25 Translabyrinthine	<ul style="list-style-type: none"> Minor complications include: hematoma in 2 patient, hydrocephalus in 2 patients, VP drainage in 1 patient, lumbar drainage in 1 patient, CN IX & X temporary dysfunction in 3 patients, CN IX & X persistent dysfunction 1 patient, temporary abducens paresis in 1 patient. 1 major complication (hemiparesis). 	11 (9.4-11.9)	<ul style="list-style-type: none"> H-B Grade II transient facial paresis in 2 patients. Transient trigeminal hypaesthesia in 1 patient. Persisting facial nerve spasms in 1 patient (improved with a botulinum toxin injections every 3 months).
Pan et al., (39)	18	Retrosigmoid	Delayed hydrocephalus in 1 patient required a placement of a VP shunt.	12	No complications
Iwai et al., (22)	40	Retrosigmoid	<ul style="list-style-type: none"> Only minor complications: Lung abscess due to aspiration pneumonia in 1 patient. Aseptic meningitis in 1 patient (treated with steroids). Pulmonary embolism in 1 patient. 	12 (10-12)	<ul style="list-style-type: none"> Transient facial spasms in 2 patients. Transient trigeminal neuropathy in 2 patients. All symptoms were resolved spontaneously.
Radwan et al., (41)	22	NR	<ul style="list-style-type: none"> Facial numbness in 4 patients (3 improved before radiosurgery). Temporary dysphagia and dysarthria 	12.5 (12-14)	<ul style="list-style-type: none"> Mild trigeminal neuropathy in 1 patient (last for 3 months).
Daniel et al., (7)	32	Retrosigmoid	<ul style="list-style-type: none"> Transient facial hypoesthesia (resolved with time) Transient vagus nerve deficit (resolved after 6 months) 	12 (11-12)	No complications
Present study	23	Translabyrinthine	No complications	12.9 (12-13)	Trigeminal paraesthesia/ neuralgia in one patient.

NR: Not reported, and the symbol “-“ indicates that there is no clear data.

after partially resecting large VS are few, and may resolve with time or medication. Major complications (non-neurological), such as wound infection, cerebral spinal fluid leakage, and meningitis, were more frequently reported after complete resection (2). A main objective of surgery in this combined approach is to achieve brain stem decompression and to

reduce tumour volume to accommodate the radiosurgery, even though complete removal of the tumour would technically be feasible. The combined treatment reduces operation time as well as the degree of invasiveness, which is a plausible explanation for the decrease in complications. In 2011, Van de Langenberg et al. noted a lower number of surgical

complications after the combined approach by comparing their post-surgical outcomes with the literature (53). However, by gathering data from all the studies that reported the combined approach, this conclusion can be further strengthened.

Nowadays, symptoms after GK radiosurgery do not constitute a major concern compared to early reports. Initially after the first use of GK to treat VS by Leksell (28), prescribed doses were commonly between 12–25 Gy (13,21,25). The high variation in the prescribed doses among early studies, with the most frequent being > 14 Gy, was because of the belief that VS can survive low doses. Although high control rates were achieved by these studies (90–100%), incidents of trigeminal neuropathy, reaching 81.7% in one study (13) and hearing deterioration were also high (21,25). The last two decades have witnessed some consensus agreement on the dose range of 12–13 Gy. In the case of small-to-medium-sized VS treated primarily by radiosurgery, a marginal dose of 12–13 Gy has shown its efficacy in excellent control rates (>90%) and much lower incidents of toxicities (1,5,18). All studies of the combined approach (Table II), including the current study, consistently used this dosing scheme and showed similar results to those of small-to-medium-sized VS.

One limitation of our study is that the number of patient with large VS treated between 2007 and 2018 in our department using the combined approach was larger, but due to incomplete data, the current study had a limited sample size of complete datasets. Additional limitations include the retrospective nature of the study design, which may have added some degree of bias to the results. Nevertheless, reporting volume change over time and functional outcomes of the combined approach for large VS neurosurgical treatment remains valuable.

CONCLUSION

Upfront planning for a partial resection followed by GK radiosurgery is an effective and safe treatment choice for patients with Koos 4 VS. The efficacy consists of good tumour control and a low number of complications, respectively.

ACKNOWLEDGEMENTS

The authors are grateful to Mr. Gil Stevenson for his support in the analysis of the data.

Declarations

Funding: No financial support was received for this research.

Availability of data and materials: The datasets generated and/or analyzed during the current study are available from the corresponding author by reasonable request.

Disclosure: The authors declare no competing interests.

AUTHORSHIP CONTRIBUTION

Study conception and design: YT

Data collection: MA, MK, YT

Analysis and interpretation of results: MA, MK, BD

Draft manuscript preparation: MA, MK

Critical revision of the article: MK, BD, SM, DE, DK, JV, YT

Other (study supervision, fundings, materials, etc...): MA, MK, BD, DE, KH, HK, YT

All authors (MA, MK, BD, DE, KH, HK, YT) reviewed the results and approved the final version of the manuscript.

REFERENCES

1. Apicella G, Paolini M, Deantonio L, Masini L, Krenqli M: Radiotherapy for vestibular schwannoma: Review of recent literature results. *Rep Pract Oncol Radiother* 21:399-406, 2016. <https://doi:10.1016/j.rpor.2016.02.002>.
2. Betka J, Zvěřina E, Balogová Z, Profant O, Skřivan J, Kraus J, Lisý J, Syka J, Chovanec M: Complications of microsurgery of vestibular schwannoma. *BioMed Res Int* 2014:315952, 2014. <https://doi:10.1155/2014/315952>.
3. Bloch DC, Oghalai JS, Jackler RK, Ossofsky M, Pitts LH: The fate of the tumor remnant after less-than-complete acoustic neuroma resection. *Otolaryngol Head Neck Surg* 130:104-112, 2004. [https://doi:10.1016/s0194-5998\(03\)01598-5](https://doi:10.1016/s0194-5998(03)01598-5).
4. Bloch O, Sughrue ME, Kaur R, Kane AJ, Rutkowski MJ, Kaur G, Yang I, Pitts LH, Parsa AT: Factors associated with preservation of facial nerve function after surgical resection of vestibular schwannoma. *J Neurooncol* 102:281-286, 2011. <https://doi:10.1007/s11060-010-0315-5>.
5. Boari N, Bailo M, Gagliardi F, Franzin A, Gemma M, Vecchio AD, Bolognesi A, Picozzi P, Mortini P: Gamma knife radiosurgery for vestibular schwannoma: Clinical results at long-term follow-up in a series of 379 patients. *J Neurosurg* 121:123, 2014. <https://doi:10.3171/2014.8.Gks141506>.
6. Chung WY, Liu KD, Shiao CY, Wu HM, Wang LW, Guo WY, Ho DM, Pan DH: Gamma knife surgery for vestibular schwannoma: 10-year experience of 195 cases. *J Neurosurg* 102 Suppl:87-96, 2005
7. Daniel RT, Tuleasca C, George M, Pralong E, Schiappacasse L, Zeverino M, Maire R, Levivier M: Preserving normal facial nerve function and improving hearing outcome in large vestibular schwannomas with a combined approach: Planned subtotal resection followed by gamma knife radiosurgery. *Acta Neurochir* 159:1197-1211, 2017. <https://doi:10.1007/s00701-017-3194-0>.
8. De Vries M, Briaire-de Bruijn I, Malessy MJA, de Bruijn SFT, van der Mey AGL, Hogendoorn PCW: Tumor-associated macrophages are related to volumetric growth of vestibular schwannomas. *Otol Neurotol* 34:347-352, 2013. <https://doi:10.1097/MAO.0b013e31827c9fbf>.
9. De Vries M, Hogendoorn PCW, Briaire-de Bruyn I, Malessy MJA, van der Mey AGL: Intratumoral hemorrhage, vessel density, and the inflammatory reaction contribute to volume increase of sporadic vestibular schwannomas. *Virchows Arch* 460:629-636, 2012. <https://doi:10.1007/s00428-012-1236-9>.

10. El-Kashlan HK, Zeitoun H, Arts HA, Hoff JT, Telian SA: Recurrence of acoustic neuroma after incomplete resection. *Am J Otol* 21:389-392, 2000. [https://doi:10.1016/s0196-0709\(00\)80049-6](https://doi:10.1016/s0196-0709(00)80049-6).
11. Falcioni M, Fois P, Taibah A, Sanna M: Facial nerve function after vestibular schwannoma surgery. *J Neurosurg* 115:820-826, 2011. <https://doi:10.3171/2011.5.Jns101597>.
12. Fedorov A, Beichel R, Kalpathy-Cramer J, Finet J, Fillion-Robin JC, Pujol S, Bauer C, Jennings D, Fennessy F, Sonka M, Buatti J, Aylward S, Miller JV, Pieper S, Kikinis R: 3D Slicer as an image computing platform for the Quantitative Imaging Network. *Magn Reson Imaging* 30:1323-1341, 2012. <https://doi:10.1016/j.mri.2012.05.001>.
13. Foote RL, Coffey RJ, Swanson JW, Harner SG, Beatty CW, Kline RW, Stevens LN, Hu TC: Stereotactic radiosurgery using the gamma knife for acoustic neuromas. *Int J of Radiat Oncol Biol Phys* 32:1153-1160, 1995. [https://doi.org/10.1016/0360-3016\(94\)00454-S](https://doi.org/10.1016/0360-3016(94)00454-S).
14. Fouard O, Daisne JF, Wanet M, Regnier M, Gustin T: Long-term volumetric analysis of vestibular schwannomas following stereotactic radiotherapy: Practical implications for follow-up. *Clin Transl Radiat Oncol* 33:1-6, 2022. <https://doi.org/10.1016/j.ctro.2021.12.003>.
15. Fuentes S, Arkha Y, Pech-Gourg G, Grisoli F, Dufour H, Regis J: Management of large vestibular schwannomas by combined surgical resection and gamma knife radiosurgery. *Prog Neurol Surg* 21:79-82, 2008. <https://doi:10.1159/000156709>.
16. Godefroy WP, van der Mey AGL, de Bruine FT, Hoekstra ER, Malessy MJA: Surgery for large vestibular schwannoma: residual tumor and outcome. *Otol Neurotol* 30:629-634, 2009. <https://doi:10.1097/MAO.0b013e3181a8651f>.
17. Gurgel RK, Dogru S, Amdur RL, Monfared A: Facial nerve outcomes after surgery for large vestibular schwannomas: Do surgical approach and extent of resection matter? *Neurosurgical Focus* 33:E16, 2012. <https://doi:10.3171/2012.7.Focus12199>.
18. Hasegawa T, Kida Y, Kato T, Iizuka H, Kuramitsu S, Yamamoto T: Long-term safety and efficacy of stereotactic radiosurgery for vestibular schwannomas: Evaluation of 440 patients more than 10 years after treatment with Gamma Knife surgery. *J Neurosurg* 118:557-565, 2013. <https://doi:10.3171/2012.10.Jns12523>.
19. Hayhurst C, Zadeh, G: Tumor pseudoprogression following radiosurgery for vestibular schwannoma. *Neuro Oncol* 14: 87-92, 2012. <https://doi.org/10.1093/neuonc/nor171>
20. Hitselberger WE, House WF: Classification of acoustic neuromas. *Arch Otolaryngol* 84:245-246, 1966.
21. Ito K, Kurita H, Sugawara K, Mizuno M, Sasaki T: Analyses of neuro-otological complications after radiosurgery for acoustic neuromas. *Int J Radiat Oncol Biol Phys* 39:983-988, 1997. [https://doi:10.1016/s0360-3016\(97\)00507-5](https://doi:10.1016/s0360-3016(97)00507-5).
22. Iwai Y, Ishibashi K, Watanabe Y, Uemura G, Yamanaka K: Functional preservation after planned partial resection followed by gamma knife radiosurgery for large vestibular schwannomas. *World Neurosurg* 84:292-300, 2015. <https://doi.org/10.1016/j.wneu.2015.03.012>.
23. Iwai Y, Yamanaka K, Ishiguro T: Surgery combined with radiosurgery of large acoustic neuromas. *Surg Neurol* 59:283-289, 2003. [https://doi.org/10.1016/S0090-3019\(03\)00025-9](https://doi.org/10.1016/S0090-3019(03)00025-9).
24. Jeyakumar A, Seth R, Brickman TM, Dutcher P: The prevalence and clinical course of patients with 'incidental' acoustic neuromas. *Acta Otolaryngol* 127:1051-1057, 2007. <https://doi:10.1080/00016480701200210>.
25. Kondziolka D, Lunsford LD, McLaughlin MR, Flickinger JC: Long-term outcomes after radiosurgery for acoustic neuromas. *New England J Med* 339:1426-1433, 1998. <https://doi:10.1056/nejm199811123392003>.
26. Lanman TH, Brackmann DE, Hitselberger WE, Subin B: Report of 190 consecutive cases of large acoustic tumors (vestibular schwannoma) removed via the translabyrinthine approach. *J Neurosurg* 90:617-623, 1999. <https://doi:10.3171/jns.1999.90.4.0617>.
27. Lawson McLean AC, McLean AL, Rosahl SK: Evaluating vestibular schwannoma size and volume on magnetic resonance imaging: An inter- and intra-rater agreement study. *Clin Neurol Neurosurg* 145:68-73, 2016. <https://doi:10.1016/j.clineuro.2016.04.010>.
28. Leksell L: A note on the treatment of acoustic tumours. *Acta Chir Scand* 137:763-765, 1971
29. Lunsford LD, Niranjan A, Flickinger JC, Maitz A, Kondziolka D: Radiosurgery of vestibular schwannomas: Summary of experience in 829 cases. *J Neurosurg* 102:195-199, 2005. https://doi:10.3171/sup.2005.102.s_supplement.0195.
30. Mamikoglu B, Wiet RJ, Esquivel CR: Translabyrinthine approach for the management of large and giant vestibular schwannomas. *Otol Neurotol* 23:224-227, 2002.
31. Marinelli JP, Lohse CM, Carlson ML: Incidence of vestibular schwannoma over the past half-century: A population-based study of Olmsted County, Minnesota. *Otolaryngol Head Neck Surg* 159:717-723, 2018. <https://doi:10.1177/0194599818770629>.
32. Meijer OW, Weijmans EJ, Knol DL, Slotman BJ, Barkhof F, Vandertop WP, Castelijns JA: Tumor-volume changes after radiosurgery for vestibular schwannoma: Implications for follow-up MR imaging protocol. *AJNR Am J Neuroradiol* 29: 906-910, 2008. <https://doi:10.3174/ajnr.A0969>.
33. Moffat DA, Hardy DG, Grey PL, Baguley DM: The operative learning curve and its effect on facial nerve outcome in vestibular schwannoma surgery. *Am J Otol* 17:643-647, 1996
34. Moffat DA, Kasbekar A, Axon PR, Lloyd SKW: Growth characteristics of vestibular schwannomas. *Otol Neurotol* 33: 1053-1058, 2012. <https://doi:10.1097/MAO.0b013e3182595454>.
35. Myrseth E, Pedersen PH, Møller P, Lund-Johansen M: Treatment of vestibular schwannomas. Why, when and how? *Acta Neurochir* 149:647-660, 2007. <https://doi:10.1007/s00701-007-1179-0>.
36. Nakatomi H, Jacob JT, Carlson ML, Tanaka S, Tanaka M, Saito N, Lohse CM, Driscoll CLW, Link MJ: Long-term risk of recurrence and regrowth after gross-total and subtotal resection of sporadic vestibular schwannoma. *J Neurosurg* 133:1052-1058, 2017. <https://doi:10.3171/2016.11.Jns16498>.
37. Okunaga T, Matsuo T, Hayashi N, Hayashi Y, Shabani HK, Kaminogo M, Ochi M, Nagata I: Linear accelerator radiosurgery for vestibular schwannoma: Measuring tumor volume changes on serial three-dimensional spoiled gradient-echo magnetic resonance images. *J Neurosurg* 103:53-58, 2005. <https://doi:10.3171/jns.2005.103.1.0053>.

38. Pan HC, Cheng FC, Sun MH, Chen CC, Sheehan J: Prediction of volumetric data errors in patients treated with gamma knife radiosurgery. *Stereotact Funct Neurosurg* 85:184-191, 2007. <https://doi.org/10.1159/000101297>.
39. Pan HC, Sheehan J, Sheu ML, Chiu WT, Yang DY: Intracapsular decompression or radical resection followed by Gamma Knife surgery for patients harboring a large vestibular schwannoma. *J Neurosurg* 117 Suppl:69-77, 2012. doi:10.3171/2012.6.gks12697.
40. Park CK, Jung HW, Kim JE, Son YJ, Paek SH, Kim DG: Therapeutic strategy for large vestibular schwannomas. *J Neurooncol* 77:167-171, 2006. <https://doi.org/10.1007/s11060-005-9015-y>.
41. Radwan H, Eisenberg MB, Sandberg Knisely JP, Ghaly MM, Schuller M: Outcomes in patients with vestibular schwannoma after subtotal resection and adjuvant radiosurgery. *Stereotact Funct Neurosurg* 94:216-224, 2016. <https://doi.org/10.1159/00047520>.
42. Ramina R, Coelho Neto M, Bordignon KC, Mattei T, Clemente R, Pires Aguiar PH: Treatment of large and giant residual and recurrent vestibular schwannomas. *Skull Base* 17:109-117, 2007. <https://doi.org/10.1055/s-2006-953510>.
43. Rosahl S, Bohr C, Lell M, Hamm K, Iro H: Diagnostics and therapy of vestibular schwannomas - an interdisciplinary challenge. *GMS Curr Top Otorhinolaryngol Head Neck Surg* 16:Doc03, 2017. <https://doi.org/10.3205/cto000142>.
44. Rykaczewski B, Zabek M: A meta-analysis of treatment of vestibular schwannoma using Gamma Knife radiosurgery. *Contemp Oncol* 18:60-66, 2014. <https://doi.org/10.5114/wo.2014.39840>.
45. Samii M, Gerganov VM, Samii A: Functional outcome after complete surgical removal of giant vestibular schwannomas. *J Neurosurg* 112:860-867, 2010. <https://doi.org/10.3171/2009.7.Jns0989>.
46. Schmidt RF, Boghani Z, Choudhry OJ, Eloy JA, Jyung RW, Liu JK: Incidental vestibular schwannomas: A review of prevalence, growth rate, and management challenges. *Neurosurg Focus* 33:E4, 2012. <https://doi.org/10.3171/2012.7.Focus12186>.
47. Stangerup SE, Caye-Thomasen P, Tos M, Thomsen J: The natural history of vestibular schwannoma. *Otol Neurotol* 27: 547-552, 2006. <https://doi.org/10.1097/01.mao.0000217356.73463.e7>.
48. Starnoni D, Daniel RT, Tuleasca C, George M, Levivier M, Messerer M: Systematic review and meta-analysis of the technique of subtotal resection and stereotactic radiosurgery for large vestibular schwannomas: A "nerve-centered" approach. *Neurosurg Focus* 44:E4, 2018. <https://doi.org/10.3171/2017.12.Focus17669>.
49. Starnoni D, Giammattei L, Cossu G, Link MJ, Roche PH, Chacko AG, Ohata K, Samii M, Suri A, Bruneau M, Cornelius JF, Cavallo L, Meling TR, Froelich S, Tatagiba M, Sufianov A, Paraskevopoulos D, Zazpe I, Berhouma M, Jouanneau E, Verheul JB, Tuleasca C, George M, Levivier M, Messerer M, Daniel RT: Surgical management for large vestibular schwannomas: A systematic review, meta-analysis, and consensus statement on behalf of the EANS skull base section. *Acta Neurochir* 162:2595-2617, 2020. <https://doi.org/10.1007/s00701-020-04491-7>.
50. Thomas C, Di Maio S, Ma R, Vollans E, Chu C, Clark B, Lee R, McKenzie M, Martin M, Toyota B: Hearing preservation following fractionated stereotactic radiotherapy for vestibular schwannomas: Prognostic implications of cochlear dose. *J Neurosurg* 107:917-926, 2007. <https://doi.org/10.3171/jns-07/11/0917>.
51. Vakilian S, Souhami L, Melançon D, Zeitouni A: Volumetric measurement of vestibular schwannoma tumour growth following partial resection: Predictors for recurrence. *J Neurol Surg Part B Skull Base* 73:117-120, 2012. <https://doi.org/10.1055/s-0032-1301395>.
52. Van de Langenberg R, de Bondt BJ, Nelemans PJ, Baumert BG, Stokroos RJ: Follow-up assessment of vestibular schwannomas: Volume quantification versus two-dimensional measurements. *Neuroradiol* 51:517-524, 2009. <https://doi.org/10.1007/s00234-009-0529-4>.
53. Van de Langenberg R, Hanssens PEJ, Van Overbeeke JJ, Verheul JB, Nelemans PJ, De Bondt BJ, Stokroos RJ: Management of large vestibular schwannoma. Part I. Planned subtotal resection followed by Gamma Knife surgery: Radiological and clinical aspects - Clinical article. *J Neurosurg* 115:875-884, 2011.
54. Van de Langenberg R, Hanssens PEJ, Verheul JB, van Overbeeke JJ, Nelemans PJ, Dohmen AJ, de Bondt BJ, Stokroos RJ: Management of large vestibular schwannoma. Part II. Primary Gamma Knife surgery: Radiological and clinical aspects. *J Neurosurg* 115:885-893, 2011. <https://doi.org/10.3171/2011.6.Jns101963>.
55. Weber DC, Chan AW, Bussiere MR, Harsh IVGR, Ancukiewicz M, Barker IIFG, Thornton AT, Martuza RL, Nadol JJB, Chapman PH, Loeffler JS: Proton beam radiosurgery for vestibular schwannoma: Tumor control and cranial nerve toxicity. *Neurosurgery* 53:577-588, 2003. <https://doi.org/10.1227/01.NEU.0000079369.59219.C0>.
56. Whitmore RG, Urban C, Church E, Ruckenstein M, Stein SC, Lee JY: Decision analysis of treatment options for vestibular schwannoma. *J Neurosurg* 114:400-413, 2011. <https://doi.org/10.3171/2010.3.jns091802>.
57. Wiet RJ, Mamikoglu B, Odom L, Hoistad DL: Long-term results of the first 500 cases of acoustic neuroma surgery. *Otolaryngol Head Neck Surg* 124:645-651, 2001. <https://doi.org/10.1177/019459980112400609>.
58. Yang SY, Kim DG, Chung HT, Park SH, Paek SH, Jung HW: Evaluation of tumor response after gamma knife radiosurgery for residual vestibular schwannomas based on MRI morphological features. *J Neurol Neurosurg Psychiatry* 79:431-436, 2008. <https://doi.org/10.1136/jnnp.2007.119602>.
59. Yao L, Alahmari M, Temel Y, Hovinga K: Therapy of sporadic and NF2-related vestibular schwannoma. *Cancers* 12:835, 2020. <https://doi.org/10.3390/cancers12040835>.
60. Zhang X, Fei Z, Chen YJ, Fu LA, Zhang JN, Liu WP, He XS, Jiang XF: Facial nerve function after excision of large acoustic neuromas via the suboccipital retrosigmoid approach. *J Clin Neurosci* 12:405-408, 2005. <https://doi.org/10.1016/j.jocn.2004.03.042>.
61. Zhang Z, Nguyen Y, De Seta D, Russo FY, Rey A, Kalamarides M, Sterkers O, Bernardeschi D: Surgical treatment of sporadic vestibular schwannoma in a series of 1006 patients. *Acta Otorhinolaryngol Ital* 36:408-414, 2016. <https://doi.org/10.14639/0392-100X-1176>.