

Original Investigation

Spine and Peripheral Nerves

# Unilateral Vertebroplasty in the Treatment of Osteoporotic Vertebral Compression Fractures: Effects of Cement Amount on Pain, Coronal Balance, and New Compression Fracture Formation

Mehmet MERAL<sup>1</sup>, Merdan ORUNOGLU<sup>2</sup>

<sup>1</sup>Private Erciyes Hospital, Department of Neurosurgery, Kayseri, Türkiye

<sup>2</sup>Kayseri State Hospital, Neurosurgery Clinic, Kayseri, Türkiye

Corresponding author: Mehmet MERAL ✉ m.meral@erciyeshastanesi.com.tr

## ABSTRACT

**AIM:** To evaluate the impact of the volume of cement injected during unilateral percutaneous vertebroplasty (PVP) on the occurrence of new fractures, as well as its effect on coronal balance and pain management in patients with osteoporotic vertebral compression fractures (OVCFs).

**MATERIAL and METHODS:** A total of 64 OVCF patients who underwent unilateral PVP were included in this study, and categorized into two groups based on the amount of cement injected during the procedure. The first group comprised 34 patients with an injected cement volume of  $\leq 3$  ml (37 levels), while the second group comprised the rest with an injected cement volume of  $> 3$  ml (39 levels). Coronal balance changes were evaluated immediately after the procedure and at 6 months post-operatively. The incidence and timing of new fractures following the initial vertebroplasty were also analyzed.

**RESULTS:** No statistically significant difference was found between the two groups regarding improvement in pre- and post-operative Visual Analog Scale scores. Similarly, no significant difference was observed in the Cobb angle measurements between the groups. New fractures developed in 1 patient from the small amount cement augmented group, and in 7 patients from the large amount cement augmented group, revealing a statistically significant difference in the incidence of new fracture formation.

**CONCLUSION:** A higher volume of cement injection during PVP appears to be a risk factor for the increased incidence of new fractures at other vertebral levels in patients with OVCF and these fractures typically occur within six months following the initial procedure. However, the volume of cement did not significantly affect clinical outcomes such as pain relief, mobility, or the restoration of coronal alignment.

**KEYWORDS:** Spinal fractures, Compression, Osteoporotic fractures, Vertebroplasty

**ABBREVIATIONS:** **OVCF:** Osteoporotic vertebral compression fractures, **PVP:** Percutaneous vertebroplasty, **PKP:** Percutaneous kyphoplasty, **BMD:** Bone mineral densitometry, **CT:** Computerized tomography, **MRI:** Magnetic resonance images

## INTRODUCTION

Osteoporotic vertebral compression fractures (OVCFs) represent a significant health concern, particularly as the aging population continues to grow. Although conservative treatment was once the gold standard, minimal-

ly invasive procedures such as percutaneous vertebroplasty (PVP) and percutaneous kyphoplasty (PKP) are now widely recognized as standard and effective interventions for managing OVCFs in elderly patients. These procedures offer several benefits, including vertebral height restoration, prevention of instability, and effective pain control (2,9).

Despite these advantages, studies have reported an increased incidence of new compression fractures at different vertebral levels following these procedures (26). However, the etiology remains unclear, with inconclusive evidence on whether these fractures result from cement injection or the natural progression of osteoporosis. Additionally, it is uncertain whether the risk of new fractures significantly differs between these procedures and conservative treatments. While some OVCFs remain aligned in the coronal and sagittal planes after PVP or PKP, others cause deterioration in these planes. Research on the impact of cement volume injected during PVP or PKP on coronal balance is insufficient. Specifically, the ideal cement volume and the effects of deviating from this volume on coronal balance remain poorly understood.

This study aims to evaluate the effects of cement volume injected during unilateral PVP on the formation of new fractures. It also seeks to elucidate the impact of cement volume on changes in coronal balance and pain control.

## ■ MATERIAL and METHODS

The Local Institutional Review Board approved the study (Approval No. E-75717723-619-259771912).

### Patients and Study Design

This study retrospectively analyzed 165 patients with OVCFs treated with PVP between 2015 and 2023. Inclusion criteria were as follows: vertebroplasty performed with a diagnosis of OVCF, a *T-score* below  $-2.5$  on bone mineral densitometry (BMD), and negative pathology results from intraoperative biopsies. Patients with neurological deficits, canal compression, *T-scores* above  $-2.5$  on BMD, obesity, significant cardiovascular disease, cancer, regional infection, radiotherapy history, or insufficient documentation were excluded. Pathological samples were collected perioperatively to rule out spinal tumors.

This study included 64 patients, who were categorized into two groups based on the volume of cement injected during surgery. Group 1 comprised 34 patients (37 levels) with cement volumes of  $\leq 3$  ml, while Group 2 included 30 patients (39 levels) with cement volumes  $> 3$  ml. Data on cement volume were extracted from operative notes in patient files. The occurrence and timing of new fractures following the initial vertebroplasty were recorded. Coronal balance was assessed using the segmentary Cobb angle on radiographs taken immediately after surgery and approximately 6 months postoperatively. Pain levels were evaluated preoperatively and postoperatively using the visual analog scale (VAS).

### Radiological Evaluation

Radiographic assessment was performed using a  $90 \times 35$ -cm standard scoliosis cassette (Siemens Multifunctional Radiographic Unit, Germany) that were utilized for assessments of coronal balance. Radiographs were captured in the posterior-anterior (PA) view from a distance of 1.8 m with patients standing with arms at their sides. Fractures and vertebroplasty outcomes were further assessed using computed tomography (CT) and magnetic resonance imaging

(MRI); (Siemens, Germany) and analyzed via Picture Archiving and Communication Systems. All measurements were recorded by the authors.

### Surgical Procedure

All PVP procedures were performed under fluoroscopic guidance in the operating room with patients in the prone position. Prophylactic antibiotics were administered preoperatively. To correct kyphosis, two transverse cylinders were placed beneath the chest and iliac crest. Local anesthesia with sedation was employed in most cases; however, general anesthesia was required in seven patients due to insufficient sedation. Local anesthesia involved 1% lidocaine administration. Unilateral vertebroplasty was performed, with the entry point shifted 5 mm laterally to improve centralization.

### Statistical Analysis

Data normality was assessed using the Shapiro–Wilk test and visual inspection of graphs. The Mann–Whitney *U* test was used to compare independent groups, and the Wilcoxon test evaluated changes within dependent groups. Relationships between categorical variables were analyzed using the chi-square test.

## ■ RESULTS

A total of 64 patients (76 levels) were evaluated, including 44 females and 20 males, with a mean age of 73.9 (68–79) year in Group 1 and 74.5 (67–80) year in Group 2. The mean follow-up duration was 4 (1–8) year. In Group 1, 23 patients were female, and 11 were males, with fractures located in the thoracolumbar ( $n=22$ ), lumbar ( $n=8$ ), and thoracic ( $n=7$ ) regions. Group 2 included 21 females and 9 males, with fractures distributed in the thoracolumbar ( $n=24$ ), lumbar ( $n=9$ ), and thoracic ( $n=6$ ) regions. No statistically significant differences were observed between the groups regarding female-to-male ratio, age, or fracture levels (Table I).

VAS scores showed no statistically significant difference in preoperative and postoperative improvement between the groups. Similarly, changes in the Cobb angle in early and late postoperative periods did not differ significantly (Table II and Figure 1).

The overall cement leakage rate was 40% in 24 patients across all groups. Specifically, cement leakage occurred in 11 (36.6%) patients in the first group and 13 (43%) patients in the second group. However, the difference between the two groups was not statistically significant.

New fractures developed in one patient in the first group and seven patients in the second group. In the second group, new fractures occurred within 6 months of the initial operation, whereas in the second group, fractures were observed within the first year post-operation. Of these new fractures, three occurred in adjacent segments and five in non-adjacent segments. Regarding fracture levels, four fractures were observed at a single level, and four occurred at two or more levels. Cement volumes used in patients with new fractures were as follows: T11, 3.5 ml; L1, 4 ml; T12, 3.5 ml; L1, 5.5 ml; L2, 4 ml; L2, 6 ml; L1, 5 ml. A statistically significant difference

**Table I:** Distribution of Age, Gender and Fracture Levels According to Groups

	≤3 ml	>3 ml	χ <sup>2</sup> and/or p-value
Age [median (1 <sup>st</sup> -3 <sup>rd</sup> Quartile)]	73.9 (68-79)	74.5 (67.75-80)	p=0.981
Male (% , n/total)	32.3 (11/34)	30.0 (9/30)	χ <sup>2</sup> =0.077 p=0.781
Female (% , n/total)	67.6 (23/34)	70.0 (21/30)	
Fracture Level			
Thoracolumbar (T11-L2) (% , n/total)	59.5 (22/37)	61.5 (24/39)	χ <sup>2</sup> =0.170 p=0.918
Lumbar region (L3-4-5) (% , n/total)	21.6 (8/37)	23.1 (9/39)	
Thoracic region (T5-11) (% , n/total)	23.1 (7/37)	15.4 (6/39)	
Bone Mineral Density (DEXA, T-score)	-2.9	-2.8	p=0.697

A chi-square test was used. Data are expressed with median (1<sup>st</sup> quartile-3<sup>rd</sup> quartile) and % (n/total).

**Table II:** Statistical Evaluation of Coronal Cobb Angles and Visual Analogue Scale (VAS) Score Changes

Cobb Angle (°)	≤3 ml	>3 ml	p-value*
Preoperative	4 (2-9)	4.5 (3-6)	0.732
Postoperative	4.5 (2-8.25)	5 (2.75-8)	0.716
VAS Score			
Preoperative	8 (7-8)	7 (7-8)	0.842
Postoperative	3 (2-3.25)	3 (2-3.25)	0.450
p-value <sup>+</sup>	<b>p&lt;0.001</b>	<b>p&lt;0.001</b>	

P\*: Wilcoxon test P\*: Mann-Whitney U test. Data are expressed with median (1<sup>st</sup> quartile-3<sup>rd</sup> quartile).

**Table III:** New Fracture Formation Statistics

	≤3 ml n=34, 37 levels	>3 ml n=30, 39 levels	χ <sup>2</sup> and/or p-value
New spinal fracture			
(+)	0.027 (1/37)	0.179 (7/39)	X <sup>2</sup> =5.192 <b>p=0.023</b>
(-)	0.972 (36/37)	0.820 (32/39)	
p-value	<b>p&lt;0.05</b>	<b>p&lt;0.05</b>	

A chi-square test was used. Data are expressed % (n/total).

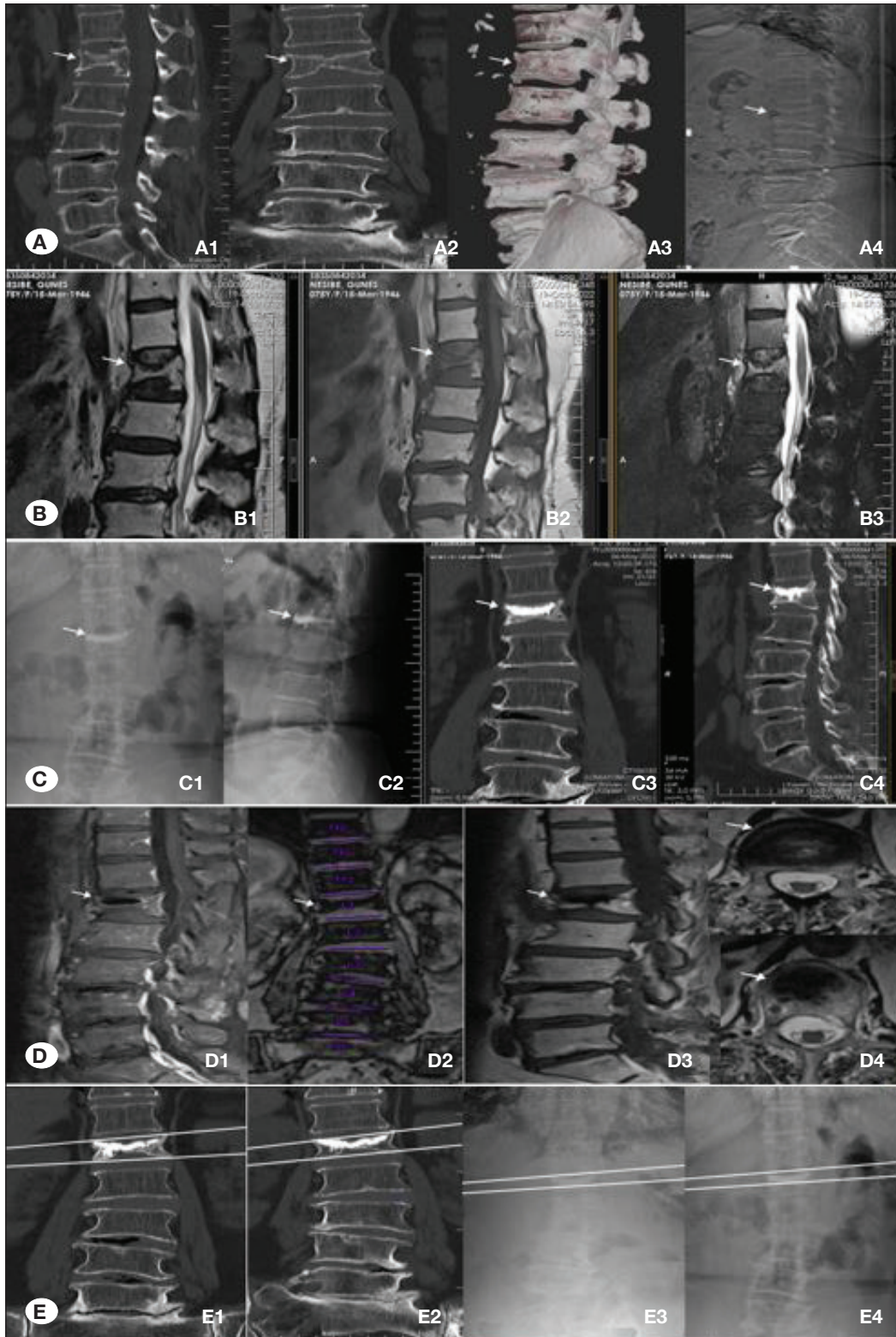
was found between the two groups concerning new fracture formation (p=0.023, X<sup>2</sup> = 5.192; Table III and Figure 2).

## DISCUSSION

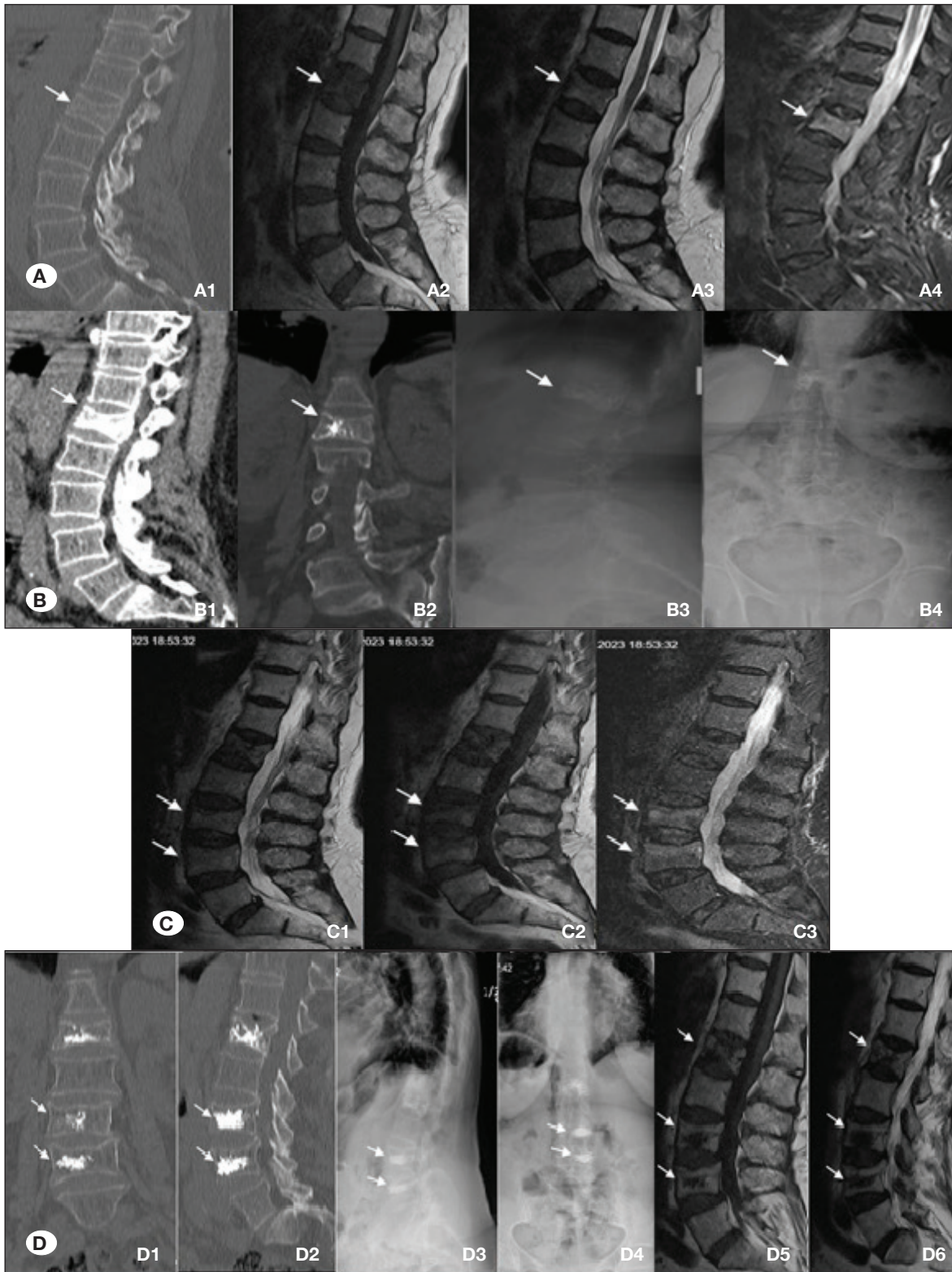
The vertebral body bears most of the axial load on the spine, and its dimensions correlate with the load it supports. Muscle imbalance and weakness can alter spinal biomechanics, potentially causing chronic pain syndromes (1). Uneven load distribution across spinal components results in varied stress levels at each motion segment. When these stress levels exceed the structural capacity of the components, damages such as cracking, breaking, tearing, or rupture may occur (1).

Percutaneous vertebroplasty is recognized as a safe and effective treatment for OVCFs, particularly in patients with acute or persistent chronic pain. It offers significant advantages over conservative treatment (10). Studies have consistently demonstrated the efficacy of PVP, whether performed at single or multiple fracture levels, in reducing pain and improving functional outcomes (14,20). Recent research suggests that unilateral PVP provides comparable radiographic and clinical results to bilateral PVP, including significant pain relief, improved back function, and restored vertebral strength (3,13,15,19,22,24-26).

Excessive cement injection to reinforce osteoporotic vertebrae can lead to increased spinal stiffness beyond healthy levels,



**Figure 1:** A 78-year-old female presented with low back pain and restricted movement, with no history of trauma and without neurological deficits. **A)** Preoperative imaging, including CT (A1, A2), 3D CT (A3), and X-ray (A4), shows an osteoporotic compression fracture at L1. **B)** Preoperative MRI images (T2, T1, and STIR sequences) reveal edema and height loss at L1 (B1, B2, B3). **C)** Postoperative X-ray (C1, C2) and CT images (C3, C4) demonstrate vertebroplasty of L1. **D)** Postoperative sagittal (D1) and coronal (D2) MRI images and sagittal STIR (D3) and axial (D4) MRIs, confirm vertebroplasty outcomes. **E)** Early and late Cobb angle measurements: 7° (postoperative first week) and 6° (postoperative sixth month). Coronal CT images (E1, E2) and PA X-rays (E3, E4) illustrate these changes.



**Figure 2:** A 71-year-old female with an L1 vertebral fracture presented with back pain, restricted movement, and muscle spasms but no trauma history and without neurological deficits. **A)** Preoperative imaging (A1–A4). Unilateral PVP (4 ml) was performed. **B)** Postoperative CT and X-ray images (B1–B3) confirm vertebroplasty of L1. **C)** Six months post-procedure, the patient experienced low back pain, restricted movement, and postural issues. MRI findings revealed new fractures at L3 and L4 (C1–C3). **D)** Unilateral vertebroplasties with 4.5 ml and 5 ml of cement were performed at L3 and L4, respectively. Postoperative imaging (CT, X-ray, and MRI; D1–D6) illustrates the outcomes of the second procedure.

making the spinal system more vulnerable to stress and new fractures. Asymmetric cement distribution, especially in large volumes, promotes unilateral load transfer, potentially causing new bone fractures (5,12,21,27). Load-sharing systems emphasize spinal balance. However, an unbalanced spinal column leads to increased tension and nonuniform loading. In cases of bone pathologies, insufficiency in the anterior column may arise, and deficiencies in bone or disc integrity can alter normal biomechanics (1). Such changes may disrupt the vertebral balance, and it is hypothesized that large cement-filling volumes may not represent the most biomechanically appropriate intervention (5,12,21,27).

Zhang et al. conducted a meta-analysis highlighting the widespread use of PKP and PVP in OVCs. They noted that new vertebral fractures frequently occur after these procedures (27). Another meta-analysis reported no significant difference in the incidence of new fractures between cement reinforcement and medical treatment in patients with OVCF (21). On the other hand, Frankel et al. found that adjacent-level fractures occurred in 25% of patients treated with PKP within 3 months, while no such fractures were observed in the PVP group. The researchers concluded that PVP effectively alleviates pain and prevents adjacent-level fractures when performed using minimal cement and a unilateral approach (5).

Adjacent-segment fractures have been reported following vertebroplasty. Cortet et al. observed 72 new fractures during the long-term follow-up (1–3 yr) of 106 patients who underwent 212 vertebroplasty procedures, with 25 fractures occurring within the first year (4). These fractures were more common at the thoracolumbar junction. Presumed etiological factors include increased spinal stiffness from excessive cement injection and cement leakage into intervertebral disc spaces or interosseous clefts, with increased stress on adjacent vertebrae and elevated risk of fractures (16). It is recommended that the cement volume be tailored to the body volume of the fractured vertebra to mitigate the risk of adjacent-segment fractures (12).

In the present study, new fractures were observed in 23.3% of patients who received cement volumes exceeding 3 ml, compared with 0.03% in those with cement volumes below this threshold. These findings indicate a close correlation between cement volume and the incidence of new osteoporotic fractures. Comparative studies of vertebroplasty and kyphoplasty have shown both techniques to be equally effective in restoring mechanical function following severe vertebral wedge fractures. However, kyphoplasty has demonstrated greater success in restoring vertebral height and correcting wedge deformities (11). Both methods yielded similar improvements in height restoration and wedge angle reduction, but kyphoplasty resulted in lower rates of cement leakage into the disc space, paravertebral soft tissues, or vessels, making it a safer alternative. Smaller cement volumes also resulted in fewer complications (6).

Morvin et al. conducted a comparative study to evaluate the risk of adjacent-level fractures associated with PKP and PVP. Their findings revealed that both procedures carry a low risk

of inducing adjacent-level fractures. The most critical factors contributing to new fractures after these interventions were identified as the severity of osteoporosis and biomechanical changes in the treated spinal region caused by persistent kyphosis. Importantly, they noted that adjacent vertebrae are prone to fracturing even in the absence of these procedures (15).

A comprehensive review emphasized the role of vertebral height restoration via balloon kyphoplasty in managing vertebral compression fractures. Beyond immediate pain relief, this technique was shown to improve spinal alignment, support functional recovery, and enhance overall quality of life. Vertebral height restoration appears to hold significant promise for alleviating pain, restoring mobility, and enabling a better quality of life for affected individuals (18).

Research indicates that only a small amount of bone cement approximately 15% of the vertebral volume is needed to restore fractured spinal stiffness to pre-fracture levels. Using larger volumes increases vertebral stiffness beyond normal levels, potentially destabilizing the spinal system. Overfilling results in asymmetrical load distribution, which heightens the risk of biomechanical complications. Thus, procedures utilizing smaller cement volumes with symmetrical placement are considered more biomechanically appropriate (12).

Khalilollah et al. found that increasing cement volume during PVP did not effectively reduce postoperative pain. Instead, achieving a wide distribution of cement within the vertebral body was more critical for pain relief than the volume used (8). Another investigation examining the relationship between cement volume and clinical outcomes reported no significant association between cement volume and complications such as epidural leakage and pulmonary embolism. While smaller cement volumes were sufficient for pain management and reducing adjacent-level fractures, larger volumes were required for fracture restoration, which led to increased leakage rates. This study recommended tailoring the cement volume to the size and level of the fractured vertebra (7).

In our study, leakage rates were higher in patients who received more than 3 ml of cement; however, no statistically significant difference in clinical outcomes, such as pain relief, was observed between those who received higher or lower volumes.

Tan et al. evaluated the effects of unilateral and bilateral PVP (23). Both approaches significantly reduced pain and restored vertebral height while positively influencing lordosis restoration. However, bilateral PVP provided superior stabilization of coronal balance compared with unilateral PVP. The study also found that multilevel PVP was associated with greater coronal balance deterioration than single-level procedures. This deterioration was attributed to factors beyond vertebral height changes, including biomechanical imbalances involving the fractured vertebra, adjacent vertebrae, and intervertebral discs. Notably, although an increased Cobb angle was observed in some cases with higher cement volumes, the difference was not statistically significant.

## Limitations

This study had certain limitations. The groups had differing underlying pathologies, making it challenging to achieve exact comparability. Additionally, the post-surgical osteoporosis treatments administered to patients varied across groups, which may have influenced outcomes.

## CONCLUSION

The use of high cement volumes during PVP is a significant risk factor for new fractures in adjacent vertebrae, particularly within the first 6 months after the procedure. However, the amount of cement used did not significantly impact clinical improvements, such as pain relief or coronal angle restoration. Further research involving larger patient cohorts is warranted to validate these findings.

## Declarations

**Funding:** No financial support was received for this research.

**Availability of data and materials:** The datasets generated and/or analyzed during the current study are available from the corresponding author by reasonable request.

**Disclosure:** The authors declare no competing interests.

## AUTHORSHIP CONTRIBUTION

Study conception and design: MM

Data collection: MM, MO

Analysis and interpretation of results: MM, MO

Draft manuscript preparation: MM

Critical revision of the article: MM

Other (study supervision, fundings, materials, etc.): MM, MO

All authors (MM, MO) reviewed the results and approved the final version of the manuscript.

## REFERENCES

- Ashman RB, Birch JG, Bone LB, Corin JD, Herring JA, Johnston CE 2nd, Ritterbush JF, Roach JW: Mechanical testing of spinal instrumentation. *Clin Orthop Relat Res* 227:113-125, 1988. <https://doi.org/10.1097/00003086-198802000-00015>
- Bademci G, Aydin Z, Batay F, Attar A, Caglar S: Yaşlılarda ağrılı osteoporotik vertebra çökme kırıklarının tedavisinde kifoplasti, vertebroplasti etkinliğinin değerlendirilmesi. *Türk Geriatri Dergisi* 8:5-6, 2005 (in Turkish).
- Chen C, Wei H, Zhang W, Gu Y, Tang G, Dong R, Xu Y, Chen L: Comparative study of kyphoplasty for chronic painful osteoporotic vertebral compression fractures via unipedicular versus bipedicular approach. *J Spinal Disord Tech* 24:E62-65, 2011. <https://doi.org/10.1097/BSD.0b013e318228f470>
- Cortet B, Cotten A, Boutry N, Dewatre F, Flipo RM, Duquesnoy B, Chastanet P, Delcambre B: Percutaneous vertebroplasty in patients with osteolytic metastases or multiple myeloma. *Rev Rhum Engl Ed* 64:177-183, 1997.
- Frankel BM, Monroe T, Wang C: Percutaneous vertebral augmentation: An elevation in adjacent-level fracture risk in kyphoplasty as compared with vertebroplasty. *Spine J* 7: 575-582, 2007. <https://doi.org/10.1016/j.spinee.2006.10.020>
- Hiwatashi A, Westesson PL, Yoshiura T, Noguchi T, Togao O, Yamashita K, Kamano H, Honda H: Kyphoplasty and vertebroplasty produce the same degree of height restoration. *AJNR Am J Neuroradiol* 30:669-673, 2009. <https://doi.org/10.3174/ajnr.A1442>
- Jin YJ, Yoon SH, Park KW, Chung SK, Kim KJ, Yeom JS, Kim HJ: The volumetric analysis of cement in vertebroplasty: Relationship with clinical outcome and complications. *Spine* 36:E761-772, 2011. <https://doi.org/10.1097/BRS.0b013e3181fc914e>
- Khalilollah S, Abdolhoseinpour H, Rezaei E, Fakhr MS: The relationship between pain relief and the amount and distribution of injected cement in kyphoplasty for osteoporotic vertebral fractures. *Eur Rev Med Pharmacol Sci* 27:8540-8549, 2023. doi: 10.26355/eurrev\_202309\_33779.
- Kiraz I, Dagtekin A: Osteoporotik vertebra kırıkları vertebroplasti / kifoplasti-avantajları / dezavantajları. *Türk Nöroşir Derg* 30:516-520, 2020 (in Turkish).
- Klazen CA, Lohle PN, de Vries J, Jansen FH, Tielbeek AV, Blonk MC, Venmans A, van Rooij WJ, Schoemaker MC, Juttmann JR, Lo TH, Verhaar HJ, van der Graaf Y, van Everdingen KJ, Muller AF, Elgersma OE, Halkema DR, Fransen H, Janssens X, Buskens E, Mali WP: Vertebroplasty versus conservative treatment in acute osteoporotic vertebral compression fractures (Vertos II): An open-label randomised trial. *Lancet* 376:1085-1092, 2010. [https://doi.org/10.1016/S0140-6736\(10\)60954-3](https://doi.org/10.1016/S0140-6736(10)60954-3)
- Landham PR, Baker-Rand HL, Gilbert SJ, Pollintine P, Annesley-Williams DJ, Adams MA, Dolan P: Is kyphoplasty better than vertebroplasty at restoring form and function after severe vertebral wedge fractures? *Spine J* 15:721-732, 2015. <https://doi.org/10.1016/j.spinee.2014.11.017>
- Liebschner MA, Rosenberg WS, Keaveny TM: Effects of bone cement volume and distribution on vertebral stiffness after vertebroplasty. *Spine* 26:1547-1554, 2001. <https://doi.org/10.1097/00007632-200107150-00009>
- Meral M, Orunoglu M, Bicer E, Berkyurek E, Koc RK: Osteoporotic vertebral fracture; comparative analysis of unilateral and bilateral vertebroplasty results. *J Türk Spinal Surg* 35:38-42, 2024. <https://doi.org/10.4274/jtss.galenos.2024.74046>
- Moulin B, Tselikas L, Gravel G, Al Ahmar M, Delpla A, Yevich S, Hakime A, Territehau C, De Baere T, Deschamps F: Safety and efficacy of multilevel thoracolumbar vertebroplasty in the simultaneous treatment of six or more pathologic compression fractures. *J Vasc Interv Radiol* 31:1683-1689.e1 2020. <https://doi.org/10.1016/j.jvir.2020.03.011>
- Movrin I, Vengust R, Komadina R: Adjacent vertebral fractures after percutaneous vertebral augmentation of osteoporotic vertebral compression fracture: A comparison of balloon kyphoplasty and vertebroplasty. *Arch Orthop Trauma Surg* 130:1157-1166, 2010. <https://doi.org/10.1007/s00402-010-1106-3>

16. Mut M, Naderi S: Risk of refracture and adjacent vertebra fracture after vertebroplasty and kyphoplasty. *World Spine J* 2:1-4, 2007.
17. Papanastassiou ID, Eleraky M, Murtagh R, Kokkalis ZT, Gerochristou M, Vrionis FD: Comparison of unilateral versus bilateral kyphoplasty in multiple myeloma patients and the importance of preoperative planning. *Asian Spine J* 8:244-252, 2014. <https://doi.org/10.4184/asj.2014.8.3.244>
18. Patel SK, Khan S, Dasari V, Gupta S: Beyond pain relief: An in-depth review of vertebral height restoration after balloon kyphoplasty in vertebral compression fractures. *Cureus*. 15:e46124, 2023. <https://doi.org/10.7759/cureus.46124>
19. Rebolledo BJ, Gladnick BP, Unnanuntana A, Nguyen JT, Kepler CK, Lane JM: Comparison of unipedicular and bipedicular balloon kyphoplasty for the treatment of osteoporotic vertebral compression fractures: A prospective randomised study. *Bone Joint J* 95-B:401-406, 2013. <https://doi.org/10.1302/0301-620X.95B3.29819>
20. Singh AK, Pilgram TK, Gilula LA: Osteoporotic compression fractures: outcomes after single- versus multiple-level percutaneous vertebroplasty. *Radiol* 238:211-220, 2006. <https://doi.org/10.1148/radiol.2381042078>
21. Song D, Meng B, Gan M, Niu J, Li S, Chen H, Yuan C, Yang H: The incidence of secondary vertebral fracture of vertebral augmentation techniques versus conservative treatment for painful osteoporotic vertebral fractures: A systematic review and meta-analysis. *Acta Radiol* 56:970-979, 2015. <https://doi.org/10.1177/0284185114544240>
22. Steinmann J, Tingey CT, Cruz G, Dai Q: Biomechanical comparison of unipedicular versus bipedicular kyphoplasty. *Spine* 30:201-205, 2005. <https://doi.org/10.1097/01.brs.0000150831.46856.87>
23. Tan Y, Liu J, Li X, Fang L, He D, Tan J, Xu G, Zhou X: Multilevel unilateral versus bilateral pedicular percutaneous vertebroplasty for osteoporotic vertebral compression fractures. *Front Surg* 9:1051626, 2023. <https://doi.org/10.3389/fsurg.2022.1051626>
24. Tohmeh AG, Mathis JM, Fenton DC, Levine AM, Belkoff SM: Biomechanical efficacy of unipedicular versus bipedicular vertebroplasty for the management of osteoporotic compression fractures. *Spine* 24:1772-1776, 1999. <https://doi.org/10.1097/00007632-199909010-00004>
25. Yan L, He B, Guo H, Liu T, Hao D: The prospective self-controlled study of unilateral transverse process-pedicle and bilateral puncture techniques in percutaneous kyphoplasty. *Osteoporos Int* 27:1849-1855, 2016. <https://doi.org/10.1007/s00198-015-3430-5>
26. Yilmaz A, Cakir M, Yucetas CS, Urfali B, Ucler N, Altas M, Aras M, Serarslan Y, Koc RK: Percutaneous kyphoplasty: Is bilateral approach necessary? *Spine* 43:977-983, 2018. <https://doi.org/10.1097/BRS.0000000000002531>
27. Zhang H, Xu C, Zhang T, Gao Z, Zhang T: Does percutaneous vertebroplasty or balloon kyphoplasty for osteoporotic vertebral compression fractures increase the incidence of new vertebral fractures? A meta-analysis. *Pain Physician* 20:E13-E28, 2017. <https://doi.org/10.36076/ppj.2017.1.E13>