



# Repeat Microvascular Decompression for Recurrent Trigeminal Neuralgia

Pinar ESER<sup>1</sup>, Hanside Setenay UNAL<sup>1</sup>, Marzieh Karimi KHEZRI<sup>1</sup>, Alper TURKKAN<sup>2</sup>, Ahmet BEKAR<sup>1</sup>

<sup>1</sup>Bursa Uludag University Faculty of Medicine, Department of Neurosurgery, Bursa, Türkiye

<sup>2</sup>Bursa Medicana Hospital, Department of Neurosurgery, Bursa, Türkiye

Corresponding author: Ahmet BEKAR ✉ abekar@uludag.edu.tr

## ABSTRACT

**AIM:** To review our experience with patients presenting with recurrent trigeminal neuralgia (TN) and who have undergone repeat microvascular decompression surgery (rMVD).

**MATERIAL and METHODS:** This retrospective observational study was conducted at the Department of Neurosurgery at a university hospital. Patients who initially experienced complete pain relief after the first MVD but later had a recurrence of TN symptoms which required an rMVD were included in the study. Pain control outcomes were evaluated based on the Barrow Neurological Institute (BNI) scale score.

**RESULTS:** Of the 375 patients who underwent MVD for TN over a 20-year period, 19 patients (6 females and 13 males) with a mean age of  $57.68 \pm 9.78$  years developed symptom recurrence which necessitated an rMVD (5.06%). The average duration of the symptoms before the rMVD was  $16.1 \pm 19.36$  months. The mean BNI score of the patients before the rMVD was  $4.5 \pm 0.5$ . Recurrence was primarily attributed to compression by a new offending vessel ( $n=9$ , 47.4%) or a Teflon granuloma ( $n=8$ , 42.1%). Two patients (10.5%) did not have any identifiable compression. During a follow-up period of  $106.3 \pm 58.3$  months, excellent pain relief (BNI-I) was achieved in 10 patients (52.6%). Eight patients (42.1%) experienced a good outcome (BNI-III), and one patient (5.3%) experienced a poor outcome (BNI-IV).

**CONCLUSION:** Recurrence of TN symptoms can occur even after an initially successful MVD. Subsequent MVDs should be considered as the primary treatment option for recurrent TN, as it significantly controls pain with low morbidity.

**KEYWORDS:** Microvascular decompression, Outcome, Partial sensory rhizotomy, Recurrence, Trigeminal neuralgia

**ABBREVIATIONS:** BNI: Barrow Neurological Institute, CSF: Cerebrospinal Fluid, PSR: Partial sensory rhizotomy, REZ: Root entry zone, rMVD: Repeat microvascular decompression, SCA: Superior cerebellar artery, TN: Trigeminal neuralgia

## INTRODUCTION

Trigeminal neuralgia (TN) is the most common cranial neuralgia (20,41), which is typically characterized by unilateral, recurrent, and brief electric shock-like pains confined to one or more divisions of the trigeminal nerve (16). Idiopathic or primary TN occurs without a known etiologic factor, accounting for approximately 95% of cases. Secondary TN is caused by factors such as space occupying lesions,

including tumors and arteriovenous malformations, compression by a dolichoectatic basilar artery, or multiple sclerosis (26).

The currently accepted pathophysiological mechanism of TN is the demyelination of the primary sensory afferents of the trigeminal nerve in the root entry zone (REZ) near the brainstem (26). Initially proposed by Dandy (12), consistent evidence has since pointed to a neurovascular conflict, involving trigemi-

nal nerve compression in the cerebellopontine cistern, as the cause of TN in >30% of the cases. This compression leads to morphological changes and demyelination of the nerve in approximately 50% of the patients (1,27).

Although drug therapy can effectively control TN in most patients, treatment failure, intolerance due to medication toxicity or side effects (26), and symptom adaptation are common factors leading to the consideration of invasive treatment options in approximately 50% of the patients with TN (2,4,11). Currently, non-destructive microneurosurgical decompression of the conflicting vessels, known as microvascular decompression (MVD), is widely accepted as the first line of treatment for patients with classical TN. MVD addresses the root cause of TN and offers the possibility of a cure (3). Current evidence demonstrates that MVD provides excellent pain control in patients with classical TN, and it is rarely associated with mortality and morbidity (36). Specifically, initial pain relief has been reported in 80.3%–96% of patients (29,30), with sustained pain control of up to 88% at the 5-year follow-up (3,29,30,39) and 70% at the 10-year follow-up (2,3). However, 1%–4% of patients continue to experience recurrent pain each year (35). Although less invasive methods such as glycerol or radiofrequency rhizotomy, balloon compression, and stereotactic radiosurgery are available, current evidence strongly supports the effectiveness and safety of repeat MVD (rMVD) for treating recurrent or persistent TN following an initial MVD (iMVD) (24,25,35).

Herein, we aimed to provide a comprehensive review of our experience with 19 patients who underwent rMVD for recurrent TN. We analyzed various aspects of their clinical characteristics, operative findings, surgical outcomes, and any associated surgical complications.

## ■ MATERIAL and METHODS

The study was approved by Bursa Uludag University Faculty of Medicine Clinical Research Ethics Committee (Date:04.07.2023, No:2023-15/12). We conducted a retrospective analysis of the data from patients who were followed-up for a minimum of 12 months and had undergone MVD for TN at our clinic. This data analysis encompassed the period from January 2003 to December 2022. Additionally, we obtained informed consent from all the patients who were included in this study.

Our study specifically focused on patients who experienced complete pain relief without the need for medications following their iMVD, which was performed by the senior author (AB), but subsequently suffered from TN recurrence which required a rMVD. We conducted a thorough retrospective review of the patients' medical records, which included pre- and postoperative inpatient and outpatient notes, images, operative videos, and operative and neuroradiological reports.

To comprehensively analyze factors potentially affecting postoperative outcomes, we collected data on patient demographics (age and sex) and pain characteristics, such duration (in months), location (side and distribution across V1, V2, or V3), and severity [assessed using the Barrow Neurological Institute

(BNI) scale score] (34). We also recorded pain-free intervals (in months) and the level of benefit (excellent, good or poor) following both the iMVD and rMVD. Furthermore, intraoperative findings and any surgical complications were documented for further evaluation.

Recurrence was defined as the reappearance of typical TN symptoms on the same side of the face, requiring medical attention, in patients who had been pain-free after a successful iMVD (37). We obtained the final measurements of pain and facial numbness from medical records or through telephonic inquiries from patients who had not visited the outpatient clinic in the last 3 months.

Throughout both the pre- and postoperative periods, the pain severity and facial numbness were evaluated using the BNI scale and facial numbness score (Table I), respectively. These assessments were conducted by an independent neurosurgeon who was unaware of the patients' treatment history, ensuring an unbiased evaluation.

### rMVD for recurrent TN

All patients underwent MVD using the retrosigmoid approach and were placed under general anesthesia. The patient was positioned either in a lateral decubitus or supine position. The head was secured with a three-pin head holder, maintained in slight flexion, and fixed onto the operating table. In the lateral decubitus position, the head was placed parallel to the floor or it was converted to the contralateral side if needed. The previous surgical incision was reopened and, if necessary, extended either superiorly or inferiorly. The standard retromastoid suboccipital craniotomy flap was raised or the previously inserted cranioplasty material was removed to reveal the posterior and inferior boundaries of the sigmoid and transverse sinuses, respectively. The previous craniectomy site was enlarged as required, using a high-speed drill. Subsequently, the dura was gently freed from any scar tissue and carefully opened under a surgical microscope. To facilitate cerebellar relaxation, the lateral medullary cistern was opened to allow cerebrospinal fluid (CSF) release. The cerebellum was gently retracted inferomedially, revealing the superior petrosal veins that were protected unless their sacrifice was compulsory. Thereafter, the arachnoid membranes adhered around the trigeminal nerve were dissected to expose the entire course of the nerve and the complete REZ for optimal decompression. If compression by a new offending vessel was identified, the vascular loop was separated from the trigeminal nerve. It was then transposed between the tentorium and cerebellum by decompressing with an intervening Teflon. Great care was taken to ensure that all points of contact between the vessel and the trigeminal nerve were completely eliminated. If a Teflon granuloma is causing compression, the fibrotic granulomas were skeletonized and completely excised using microsurgical sharp dissection to free the trigeminal nerve from the Teflon. Subsequently, new Teflon material was inserted for decompression. Furthermore, gentle partial sensory rhizotomy (PSR) was performed in patients with granuloma formation and in those with no obvious compression (10). PSR involves the coagulation of the regions corresponding to the patient's preoperative pain distribution (middle 1/3 of REZ for V2 and

**Table I:** Summary of Characteristics and Clinical Outcomes of Patients with Recurrent Trigeminal Neuralgia Who Underwent Repeated Microvascular Decompression Procedure

	Number of patients n=19 (%)
Sex	
Male	13 (68.4)
Female	6 (31.6)
Age at time rMVD (mean years $\pm$ SD, years)	57.68 $\pm$ 9.78
Duration of Symptoms before rMVD (mean $\pm$ SD, months)	16.1 $\pm$ 19.36
BNI Scale Score Before rMVD (mean $\pm$ SD)	4.5 $\pm$ 0.5
IV	
V	
Lateralization of pain	
Left	11 (57.9)
Right	8 (42.1)
Painful division(s) before rMVD	
Single division	8 (41.1)
V1	-
V2	7 (36.8)
V3	1 (5.2)
Multiple divisions	11 (57.8)
V1-2	-
V1-3	-
V2-3	6 (31.5)
V1-2-3	5 (26.3)
Operative Findings	
Arachnoid adhesions	19 (100)
Vessel compression	9 (47.4)
SCA	6 (31.6)
AICA	2 (10.5)
SPV	1 (5.2)
Teflon granulomas	8 (42.1)
No Compressive Effect	2 (10.5)
Postoperative BNI Scale Score (mean $\pm$ SD)	2 $\pm$ 1.1
I	10 (52.6)
II	-
III	8 (42.1)
IV	1 (5.3)
Follow-up time (mean $\pm$ SD, months)	106.3 $\pm$ 58.3
Postoperative Complications	
Facial weakness	1 (5.3)
CSF collection	1 (5.3)
Cerebellar infarction	1 (5.3)

**AICA:** Anterior inferior cerebellar artery, **rMVD:** Repeat MVD, **SCA:** Superior cerebellar artery, **SPV:** Superior petrosal vein, **V1, V2, V3:** Three branches of trigeminal nerve.

lower 1/3 for V3) using a bipolar cautery at a very low current. After meticulous hemostasis was obtained, the dura was closed in a watertight fashion, and a cranioplasty was performed using methylmethacrylate (26).

Postoperative pain outcomes were defined as excellent (BNI-I), good (BNI-II/III) or poor (BNI-IV/V) (22). During the preparation of this article, all patients whose final follow-up visits were more than three months ago were called and their final pain status was enquired.

All statistical analyses were performed using GraphPad Prism (version 7; GraphPad Software, San Diego, CA, USA). Quantitative data were expressed as mean  $\pm$  standard deviation. One-way ANOVA, followed by the Tukey's post hoc test, was used for the comparison of different groups. The Student's t-test was used to compare the independent means of two groups. The categorical variables were presented as frequency and percentage values [n (%)] and compared using the Pearson Chi-square test. A p-value of <0.05 was considered statistically significant.

## RESULTS

### Patient and Pain Characteristics

Of the 375 patients who underwent MVD for TN, 19 presented with recurrence of symptoms that required a rMVD (5.06%). Of the 19 patients, 6 (31.6%) were female and 13 (68.4%) were male; their mean age was 57.68  $\pm$  9.78 years (range, 41–75 years) at the time of the rMVD. The mean age of this cohort during their iMVD was 55.26  $\pm$  9.53 years (range, 40–74 years). The left side was affected in 11 patients (57.9%) and the right in eight patients (42.1%). Before the iMVD, a single branch was affected in eight patients (42.1%; V2, n=7; V3, n=1) and multiple divisions were affected in 11 patients (57.9%). The mean duration of symptoms before the first operation was 93.25  $\pm$  72.61 months (range, 4–264 months). In all patients, the mean complete pain-free period with no need for medication after the iMVD was 39.46  $\pm$  52.16 months (range, 6–180 months). The BNI pain score was Grade IV in nine patients (47.4%) and Grade V in the rest (n = 10; 52.6%) before the rMVD. The mean BNI score of the patients before the rMVD was 4.5  $\pm$  0.5. The mean duration of symptoms before the rMVD was 16.1  $\pm$  19.36 months (range, 1–60 months). The mean interval between the two surgeries was 37.43  $\pm$  45.50 months (range, 1–168 months). Before the rMVD, a single division was involved in nine patients (47.4%) and multiple divisions were involved in 10 patients (52.6%). The mean follow-up duration of the patients who underwent rMVD was 106.3  $\pm$  58.3 months.

### Intraoperative Findings

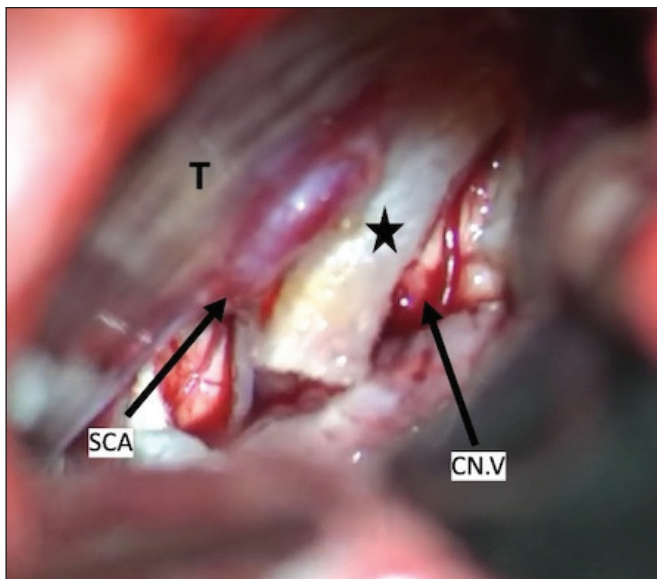
The superior cerebellar artery (SCA) was the single offending vessel in 15 (78.9%) patients at the time of the iMVD. In three patients (15.8%), multiple vascular compressions were observed. One patient (5.3%) had only venous compression (Table I).

Arachnoid adhesions were evident in all patients during the rMVD. Compression by a new offending vessel was identified

in nine patients (47.4%); the vascular loop was transposed between the tentorium and cerebellum using Teflon. The offending vessel was the SCA in six (31.6%) of these cases. A Teflon granuloma was identified in eight (42.1%) patients (Figure 1). No compressive factors were encountered in the remaining two patients (10.5%) during the rMVD, except for severe adhesions around the REZ of the fifth nerve, which could have caused the recurrent symptoms. In patients with a granuloma (8/19) and no compressive structures (2/19), we performed PSR via gentle bipolar coagulation after MVD to facilitate pain control.

**Surgical Outcomes and Complications**

Excellent pain outcome (BNI-I) was achieved in 10 patients (52.6%). Eight of the patients (42.1%) experienced a good



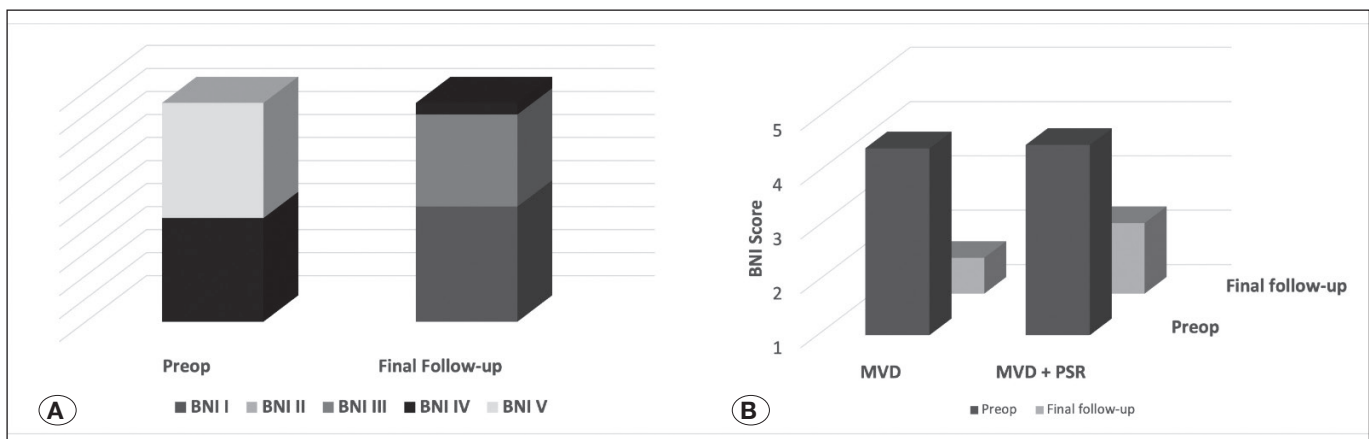
**Figure 1:** Intraoperative (rMVD) images showing a Teflon granuloma (black star) which is compressing on the right trigeminal nerve. **T:** tentorium, **CN.V:** fifth cranial nerve, **SCA:** superior cerebellar artery, rMVD,

outcome (BNI-III), and one (5.3%) experienced a poor outcome (BNI-IV). The mean BNI score at the final follow-up after rMVD was  $2 \pm 1.1$ . Significant reduction in the BNI scores were achieved ( $4.5 \pm 0.5$  vs.  $2 \pm 1.1$ ,  $p < 0.001$ ), and a favorable outcome (excellent + good) was achieved in 93.7% of our cases (Figure 2A). The posterior fossa of the patient with a BNI of Grade IV after the rMVD was explored; there was no significant compression on the REZ of the fifth nerve during surgery. We were able to achieve excellent pain control in six (66.7%) patients with vascular compression at the final follow-up; the remaining three (33.3%) experienced a good outcome (BNI-III). Specifically, in patients with arterial or venous vascular compression, statistically significant pain control was achieved based on their BNI score ( $4.44 \pm 0.49$  vs.  $1.66 \pm 0.94$ ;  $p < 0.0001$ ).

The pain significantly reduced after rMVD in patients with a Teflon granuloma (preoperatively,  $4.62 \pm 0.48$ ; postoperatively,  $2.25 \pm 0.96$ ;  $p < 0.0001$ ). Approximately 37% ( $n = 3$ ) of the patients with a Teflon granuloma experienced excellent (BNI-I) pain relief; whereas, 62.5% ( $n = 5$ ) of this group experiences a good (BNI-II/III) outcome.

Although there was a tendency for a reduced BNI score postoperatively in patients who had no obvious compression, this difference was not statistically significant (preoperatively,  $4.5 \pm 0.5$ ; postoperatively,  $2.5 \pm 1.5$ ;  $p = 0.2311$ ) because of the negative exploration during the rMVD. We achieved excellent pain control (BNI-I) in one of the patients with a negative exploration; however, the BNI score improved from BNI-V to only BNI-IV in another patient; this was considered a poor outcome.

Significant pain control was achieved postoperatively both in patients who underwent only MVD (preoperatively,  $4.44 \pm 0.49$ ; postoperatively,  $1.66 \pm 0.94$ ;  $p < 0.0001$ ) and in those who underwent MVD and PSR (preoperatively,  $4.6 \pm 0.48$ ; postoperatively,  $2.3 \pm 1.1$ ;  $p < 0.0001$ ). The BNI scores did not significantly differ at the final follow-up between the patients who underwent MVD alone and those who underwent MVD and PSR ( $1.66 \pm 0.94$  vs.  $2.3 \pm 1.1$ ;  $p = 0.3832$ ) (Figure 2B).



**Figure 2:** Bar graphs demonstrating preoperative and postoperative BNI scores at the final follow-up. **A)** Overall BNI scores. **B)** BNI scores in patients who have undergone MVD alone and in those who have undergone PSR in addition to MVD. **BNI:** Barrow Neurological Institute; **MVD:** Microvascular decompression; **PSR:** Percutaneous sensory rhizotomy.

Three patients (15.7%) complained of BNI-II facial numbness at the final follow-up. Mild temporary facial weakness (n=1; 5.3%), CSF collection (n=1; 5.3%) and cerebellar infarction (n=1; 5.3%) occurred as complications following the rMVD. All the complications were successfully managed conservatively. There was no mortality in this cohort of patients.

The patient characteristics, intraoperative findings, and surgical outcomes are presented in Table I.

## ■ DISCUSSION

The notion that normal vessels could cause cranial nerve disorders by compressing the involved nerve roots was first hypothesized by Dandy and Gardner and later elaborated on by Jannetta to develop the MVD procedure (25). MVD was first applied to a patient with a hemifacial spasm via a retromastoid approach by Janetta in 1966 (19). Since then, it has been considered among the greatest discoveries and advances in neurosurgery and medicine based on the current evidence demonstrating excellent pain control following MVD for patients with classical TN and the rarity of mortality and morbidity (29,41). Currently, MVD is a well-defined and highly effective method that is considered potentially curative for TN (18). With MVD, it is possible to mobilize the vasculature which is responsible for the clinical picture, which provides non-destructive, effective, and permanent symptomatic relief. However, not all the patients completely benefit from MVD, and excellent pain relief cannot always be achieved. Approximately 5%–10% of the patients continue to experience pain after an MVD. Moreover, up to 5% of patients per year harbor the risk of recurrent pain (25,35).

Several factors have been proposed to result in persistent or recurrent TN symptoms, including inadequate decompression of the fifth nerve, development of inflammatory adhesions, Teflon granuloma formation, excessive Teflon insertion or its dislocation, and new vascular compression after the iMVD. Arachnoid adhesions have been reported in majority of the patients with TN who have undergone rMVD (15,40,42). Furthermore, although previous studies are in general agreement on the reasons behind TN recurrence, the reported ratios for each greatly vary.

According to the results of a recent meta-analysis, the presence of a new arterial loop (26.7%), granuloma formation (19.6%), and venous compression (8.89%) were the main causes of recurrence; however, no cause was identified in approximately one-third of the patients (25). Vascular compression caused by an artery, a vein, or both have been reported in several studies focusing on recurrent TN (8,13,17,33). In a series of eight patients who underwent rMVD for persistent symptoms, 87.5% of the patients displayed arterial compression; the remaining had venous compression (17). The decompression during the iMVD was inadequate and new conflict sites appeared at the motor root, rather than the sensory root, in 62.5% (5/8) of the patients who had undergone rMVD. In the study by in Feng et al., the compressive effect of the petrosal veins was observed in 13.3% (2/15) of the patients with recurrence; there was no compressive vasculature in 40% of their patients (14). Similar-

ly, Chen et al. identified compression of the trigeminal nerve by an artery and vein in 36.6% and 14.6% of patients with TN recurrence (n=41); there was no vascular compression in 29.3% of their patients (8). The presence of a high percentage of venous compression or no vascular compression during the rMVD was a common feature among other similar studies with even higher ratios. In the study by Ravina et al. compression by the petrosal veins was observed in 55.5% of the patients with recurrent TN; no compression was observed in 11.1% of the patients (34). Similarly, Lee et al. reported recurrence of new veins at the previously treated site in 87.5% of the patients with recurrent TN (25). Similar to the findings of most previous studies, compression by a new offending artery was the main cause of recurrence (47.4%) in the present study. We observed compression by the superior petrosal veins in two patients (10.5%), one of which was accompanied by a greater compression by the SCA. Furthermore, approximately 10.5% of the patients had no evidence of compressive structures on exploration during the rMVD. In all patients with arterial compression or venous compression, we were satisfied with the decompression achieved using Teflon. In patients with negative explorations, we performed PSR with gentle coagulation using a bipolar cautery. In patients with vascular compression, we observed significant pain control following rMVD (preoperatively,  $4.44 \pm 0.49$ ; postoperatively,  $1.66 \pm 0.94$ ;  $p < 0.0001$ ). Similar to the findings in literature, we achieved excellent pain control in 66.7% of our cases with either arterial or venous compression. However, although there was a tendency for pain control, as determined by the BNI scores, in patients with no obvious compression, this difference was not statistically significant (preoperatively,  $4.5 \pm 0.5$ ; postoperatively,  $2.5 \pm 1.5$ ;  $p = 0.2311$ ). We believe, this occurred due to the limited number of patients in this group (n=2).

Several materials have been suggested to decompress neurovascular conflict during MVD, including muscle, cotton, Ivalon sponge, and polytetrafluoroethylene (Teflon;). Among these materials, Teflon has been considered an ideal material for decompression. Therefore, it is the most widely used material because of its high tissue acceptance, lack of resorption, and low complication potential (5,7). It is reportedly a completely inert material initially. However, slippage or displacement is a well-known complication of Teflon felt (13,25). Moreover, it is reportedly associated with inflammatory foreign body reactions, leading to adhesions, fibrotic changes, and rarely, granuloma formation around the trigeminal nerve. This could result in recurrences. The overall incidence of Teflon granuloma formation is reportedly 1.5%–7.3% following MVD (5,7,31,32). Conversely, studies have consistently underlined the presence of Teflon granuloma as a major cause behind the recurrence of pain symptoms. Specifically, the reported rate of Teflon granuloma presence in the rMVD studies ranges between 18.11% to 71.43% (5,24,25,33,38).

Teflon granuloma formation occurs in response to an inflammatory reaction primarily involving multinuclear giant cells and lymphocytes (5). This inflammatory response is believed to be triggered particularly when the Teflon comes in contact with the CSF or blood (5,24). Thus, pushing the offending vessel away from the trigeminal nerve with Teflon, avoiding contact

with the nerve, and removing any blood from the Teflon during iMVD are recommended (24). Others have advised avoiding contact between the brainstem and Teflon as well as the tentorium or dura (5). They believe that the Teflon patch tends to transform into a granuloma when it comes in contact with the brainstem (28,31) and that it receives blood supply from the tentorium/dura (5). Similar to the findings of previous studies on TN recurrence, we observed that a Teflon granuloma was the second most common cause of recurrence in our series (8/19; 42.1%). In these patients, we sharply dissected and meticulously removed the Teflon material and introduced fresh Teflon for decompression. Subsequently, PSR of the relevant part of the trigeminal sensory root was performed.

PSR, which is the cutting or coagulation of a part of the sensory root of the trigeminal nerve, is rarely performed solely for the surgical management of TN because of the high recurrence potential and intolerable dysesthesia due to nerve damage (43). However, when performed in combination with MVD, PSR results in a pain-free rate of 95% after 2 years of follow-up or 69.5% during longer follow-up periods reaching 6 years; furthermore, the recurrence rates are significantly reduced after iMVD (6,44). Performing PSR in addition to MVD for recurrent TN is reportedly effective in controlling pain (19). Studies emphasizing the augmenting role of PSR following rMVD have reported excellent and good outcomes in >50% and >90% of the cases, respectively, during long-term follow-up (19). The mechanism of pain relief post-MVD is more complex than a simple neural decompression; PSR is believed to destroy the transmission duct by injuring the trigeminal root or ganglion, which alters the function of the ganglions accordingly (44). PSR in combination with MVD is generally recommended to prevent recurrences in patients with a non-neurovascular compression, venous compression, Teflon granuloma, or no identifiable offender during surgery (15,19,44). In the present study, PSR was performed after MVD in patients with no obvious compressive pathology and in those with a Teflon granuloma to facilitate pain control. Although we observed venous compression in two patients, one of which was accompanied by a greater compression by the SCA, we did not perform an additional PSR after the MVD because we were satisfied with the decompression using Teflon. We achieved a reduction in pain to BNI-I in both patients. Nevertheless, we were able to achieve significant pain control both in patients who underwent MVD alone as well as in those who underwent MVD and PSR. Moreover, the BNI scores at final follow-up were similar between patients who underwent MVD alone and in those who underwent MVD and PSR, ( $1.66 \pm 0.94$  vs.  $2.3 \pm 1.1$ ;  $p=0.3832$ ). Hence, our findings support the efficacy of MVD in addition to PSR for TN recurrence with causative pathologies that are believed to display unsatisfactory prognosis after a pure MVD. Facial numbness/dysesthesia is a common complication of PSR, and it has been reported in 20–80% of the cases (6,24,44). We observed facial numbness in 15.7% of our patients who had undergone MVD and PSR; however, it not disturb the patients' quality of life.

Previous studies on rMVD have revealed varying rates of postoperative complications occurring in approximately one-

third of the cases (9,14,25). Furthermore, they have consistently underlined recurrent MVD as a safe treatment option. According to a recent meta-analysis, complications are seen in 37% of the patients who have undergone rMVD. Transient or permanent facial paralysis, hearing loss, herpes simplex infection, diplopia, keratitis, meningitis, and CSF leakage are the most common complications reported following rMVD. In this study, the overall complication rate of 31.5% (n=6) was consistent with that reported in literature. Half of these cases developed facial numbness following PSR. Transient facial weakness, CSF collection, and cerebellar infarction were seen in one patient each. All the complications were managed conservatively.

In summary, MVD is an effective technique in controlling the pain symptoms of TN with low recurrence rates. Based on our study results, rMVD can be performed for the recurrence of TN symptoms, with high success rates and minimal complications that are comparable to that of iMVD.

Our study had several limitations that should be considered when interpreting our results. First, our observational study was a retrospective analysis. Additionally, the sample size was small. Nevertheless, herein, we have shared our experience of 19 years which is a relatively long-term study when compared with previous reports.

## CONCLUSION

TN symptoms can recur even after an initially excellent outcome following an MVD. Recurrence is often associated with the presence of an offending vessel (especially an artery), severe arachnoid adhesions, and a Teflon granuloma. Rarely, no obvious compression is observed. In cases of recurrent TN, an rMVD should be strongly considered as the primary treatment option. This approach offers the potential for significant pain control with a low risk of complications and morbidity.

## ACKNOWLEDGMENTS

Preparation for publication of this article is partly supported by Turkish Neurosurgical Society.

### Declarations

**Funding:** There is no funding to report.

**Availability of data and materials:** The datasets generated and/or analyzed during the current study are available from the corresponding author by reasonable request.

**Disclosure:** Authors declare no conflict of interest.

## AUTHORSHIP CONTRIBUTION

Study conception and design: PE

Data collection: HSU, MKK, AT

Analysis and interpretation of results: PE

Draft manuscript preparation: PE

Critical revision of the article: AB

Other (study supervision, fundings, materials, etc...): PE, HSU, AB

All authors (PE, HSU, MKK, AT, AB) reviewed the results and approved the final version of the manuscript.

## REFERENCES

- Antonini G, Di Pasquale A, Cruccu G, Truini A, Morino S, Saltelli G, Romano A, Trasimeni G, Vanacore N, Bozzao A: Magnetic resonance imaging contribution for diagnosing symptomatic neurovascular contact in classical trigeminal neuralgia: A blinded case-control study and meta-analysis. *Pain* 155:1464-1471, 2014. <https://doi.org/10.1016/j.pain.2014.04.020>
- Barker FG 2nd, Jannetta PJ, Bissonette DJ, Larkins MV, Jho HD: The long-term outcome of microvascular decompression for trigeminal neuralgia. *New England J Med* 334:1077-1083, 1996. <https://doi.org/10.1056/NEJM199604253341701>
- Bendtsen L, Zakrzewska JM, Abbott J, Braschinsky M, Di Stefano G, Donnet A, Eide PK, Leal PRL, Maarbjerg S, May A, Nurmikko T, Obermann M, Jensen TS, Cruccu G: European Academy of Neurology guideline on trigeminal neuralgia. *Eur J Neurol* 26:831-849, 2019. <https://doi.org/10.1111/ene.13950>
- Bennetto L, Patel NK, Fuller G: Trigeminal neuralgia and its management. *BMJ* 334:201-205, 2007. <https://doi.org/10.1136/bmj.39085.614792.BE>
- Bick SKB, Eskandar EN: Surgical treatment of trigeminal neuralgia. *Neurosurg Clin N Am* 28:429-438, 2017. <https://doi.org/10.1016/j.nec.2017.02.009>
- Capelle HH, Brandis A, Tschan CA, Krauss JK: Treatment of recurrent trigeminal neuralgia due to Teflon granuloma. *J Headache Pain* 11:339-344, 2010. <https://doi.org/10.1007/s10194-010-0213-4>
- Chen F, Niu Y, Meng F, Xu P, Zhang C, Xue Y, Wu S, Wang L: Recurrence rates after microvascular decompression in patients with primary trigeminal neuralgia and its influencing factors: A systematic review and meta-analysis based on 8,172 surgery patients. *Front Neurol* 12:738032, 2021. <https://doi.org/10.3389/fneur.2021.738032>
- Chen J, Lee S, Lui T, Yeh Y, Chen T, Tzaan W: Teflon granuloma after microvascular decompression for trigeminal neuralgia. *Surg Neurol* 53:281-287, 2000. [https://doi.org/10.1016/S0090-3019\(00\)00169-5](https://doi.org/10.1016/S0090-3019(00)00169-5)
- Chen JN, Yu WH, Du HG, Jiang L, Dong XQ, Cao J: Prospective comparison of redo microvascular decompression and percutaneous balloon compression as primary surgery for recurrent trigeminal neuralgia. *J Korean Neurosurg Soc* 61: 747-752, 2018. <https://doi.org/10.3340/jkns.2017.0196>
- Cheng J, Meng J, Lei D, Hui X: Repeat microvascular decompression for patients with persistent or recurrent trigeminal neuralgia: Prognostic factors and long-term outcomes. *Medicine* 98:e15167, 2019. <https://doi.org/10.1097/MD.00000000000015167>
- Cohen-Gadol AA: Microvascular decompression surgery for trigeminal neuralgia and hemifacial spasm: Naunces of the technique based on experiences with 100 patients and review of the literature. *Clin Neurol Neurosurg* 113:844-853, 2011. <https://doi.org/10.1016/j.clineuro.2011.06.003>
- Cruccu G, Gronseth G, Alksne J, Argoff C, Brainin M, Burchiel K, Nurmikko T, Zakrzewska JM; American Academy of Neurology Society & European Federation of Neurological Society: AAN-EFNS guidelines on trigeminal neuralgia management. *Eur J Neurol* 15:1013-1028, 2008. <https://doi.org/10.1111/j.1468-1331.2008.02185.x>
- Dandy WE: Concerning the cause of trigeminal neuralgia. *Am J Surg* 24:447-455, 1934. [https://doi.org/10.1016/S0002-9610\(34\)90403-7](https://doi.org/10.1016/S0002-9610(34)90403-7)
- Feng BH, Wang XH, Li ST: Posterior fossa re-exploration for recurrent trigeminal neuralgia: Operative findings and surgical techniques. *J Craniofac Surg* 29:1284-1286, 2018. <https://doi.org/10.1097/SCS.00000000000004576>
- Gu W, Zhao W: Microvascular decompression for recurrent trigeminal neuralgia. *J Clin Neurosci* 21:1549-1553, 2014. <https://doi.org/10.1016/j.jocn.2013.11.042>
- Han I, Shin D, Chang J, Kim K, Chang J, Huh R, Chung S: Effect of various surgical modalities in recurrent or persistent trigeminal neuralgia. *Stereotact Funct Neurosurg* 88:156-162, 2010. <https://doi.org/10.1159/000303530>
- Headache Classification Committee of the International Headache Society (IHS): The International Classification of Headache Disorders, 3rd edition. *Cephalalgia* 38:1-211, 2018. <https://doi.org/10.1177/0333102417738202>
- Huang Z, Pu B, Li F, Liu K, Hua C, Li C, Zhao C, Li J, Li X: Analysis of failed microvascular decompression in patients with trigeminal neuralgia. *J Neurolog Surg B Skull Base* 81: 567-571, 2020. <https://doi.org/10.1055/s-0039-1692683>
- Jannetta PJ: Arterial compression of the trigeminal nerve at the pons in patients with trigeminal neuralgia. *J Neurosurg* 26: 159-162, 1967. <https://doi.org/10.3171/jns.1967.26.1part2.0159>
- Jiao L, Ye H, Lv J, Xie Y, Sun W, Ding G, Cui S: A systematic review of repeat microvascular decompression for recurrent or persistent trigeminal neuralgia. *World Neurosurgery* 158: 226-233, 2022. <https://doi.org/10.1016/j.wneu.2021.11.129>
- Kang IH, Park BJ, Park CK, Malla HP, Lee SH, Rhee BA: A clinical analysis of secondary surgery in trigeminal neuralgia patients who failed prior treatment. *J Korean Neurosurg Soc* 59:637-642, 2016. <https://doi.org/10.3340/jkns.2016.59.6.637>
- Kano H, Kondziolka D, Yang HC, Zorro O, Lobato-Polo J, Flannery TJ, Flickinger JC, Lunsford LD: Outcome predictors after gamma knife radiosurgery for recurrent trigeminal neuralgia. *Neurosurgery* 67:1637-1645, 2010. <https://doi.org/10.1227/NEU.0b013e3181fa098a>
- Katusic S, Williams DB, Beard CM, Bergstralh EJ, Kurland LT: Epidemiology and clinical features of idiopathic trigeminal neuralgia and glossopharyngeal neuralgia: Similarities and differences, Rochester, Minnesota, 1945-1984. *Neuroepidemiology* 10:276-281, 1991. <https://doi.org/10.1159/000110284>
- Kaufmann AM, Price AV: A history of the Jannetta procedure. *J Neurosurg* 132:639-646, 2019. <https://doi.org/10.3171/2018.10.JNS181983>
- Lee SH, Levy EI, Scarrow AM, Kassam A, Jannetta PJ: Recurrent trigeminal neuralgia attributable to veins after microvascular decompression. *Neurosurgery* 46:356-362, 2000. <https://doi.org/10.1097/00006123-200002000-00019>
- Liu J, Wu G, Xiang H, Liu R, Li F, Hei B, Qian W, Song H, Liu Z: Long-term retrospective analysis of microvascular decompression in patients with recurrent trigeminal neuralgia. *Front Neurol* 11:584224, 2020. <https://doi.org/10.3389/fneur.2020.584224>

27. Maarbjerg S, Di Stefano G, Bendtsen L, Cruccu G: Trigeminal neuralgia - diagnosis and treatment. *Cephalalgia* 37:648-657, 2017. <https://doi.org/10.1177/0333102416687280>
28. Masur H, Papke K, Bongartz G, Vollbrecht K: The significance of three-dimensional MR-defined neurovascular compression for the pathogenesis of trigeminal neuralgia. *J Neurol* 242: 93-98, 1995. <https://doi.org/10.1007/BF00887823>
29. Matsushima T, Yamaguchi T, Inoue TK, Matsukado K, Fukui M: Recurrent trigeminal neuralgia after microvascular decompression using an interposing technique. Teflon felt adhesion and the sling retraction technique. *Acta Neurochirurgica* 142: 557-561, 2000. <https://doi.org/10.1007/s007010050469>
30. Pamir MN, Peker S: Microvascular decompression for trigeminal neuralgia: A long-term follow-up study. *Minim Invasive Neurosurg* 49:342-346, 2006. <https://doi.org/10.1055/s-2006-960487>
31. Pollock BE, Stien KJ: Posterior fossa exploration for trigeminal neuralgia patients older than 70 years of age. *Neurosurgery* 69:1255-1260, 2011. <https://doi.org/10.1227/NEU.0b013e-31822ba315>
32. Premsagar IC, Moss T, Coakham HB: Teflon-induced granuloma following treatment of trigeminal neuralgia by microvascular decompression. Report of two cases. *J Neurosurg* 87: 454-457, 1997. <https://doi.org/10.3171/jns.1997.87.3.0454>
33. Pressman E, Jha RT, Zavadskiy G, Kumar JI, van Loveren H, van Gompel JJ, Agazzi S: Teflon™ or Ivalon®: A scoping review of implants used in microvascular decompression for trigeminal neuralgia. *Neurosurg Rev* 43:79-86, 2020. <https://doi.org/10.1007/s10143-019-01187-0>
34. Ravina K, Strickland BA, Rennert RC, Bakhsheshian J, Russin JJ, Giannotta SL: Revision microvascular decompression for trigeminal neuralgia and hemifacial spasm: Factors associated with surgical failure. *J Neurolog Surg B Skull Base* 80: 31-39, 2019. <https://doi.org/10.1055/s-0038-1661348>
35. Rogers CL, Shetter AG, Fiedler JA, Smith KA, Han PP, Speiser BL: Gamma knife radiosurgery for trigeminal neuralgia: The initial experience of The Barrow Neurological Institute. *Int J Radiat Oncol Biol Phys* 47:1013-1019, 2000. [https://doi.org/10.1016/S0360-3016\(00\)00513-7](https://doi.org/10.1016/S0360-3016(00)00513-7)
36. Sanchez-Mejia RO, Limbo M, Cheng JS, Camara J, Ward MM, Barbaro NM: Recurrent or refractory trigeminal neuralgia after microvascular decompression, radiofrequency ablation, or radiosurgery. *Neurosurg Focus* 18:e12, 2005. <https://doi.org/10.3171/foc.2005.18.5.13>
37. Sindou M, Leston JM, Decullier E, Chapuis F: Microvascular decompression for trigeminal neuralgia: the importance of a noncompressive technique--Kaplan-Meier analysis in a consecutive series of 330 patients. *Neurosurgery* 63:341-351, 2008. <https://doi.org/10.1227/01.NEU.0000327022.79171.D6>
38. Sun T, Wang W, Huang Q, He L, Su Y, Li N, Liu J, Yang C: Teflon granuloma: A common cause of recurrent trigeminal neuralgia. *World Neurosurgery* 158: e612-e617, 2022. <https://doi.org/10.1016/j.wneu.2021.11.033>
39. Tyler-Kabara, EC, Kassam AB, Horowitz MH, Urgo L, Hadjipanayis C, Levy EI, Chang YF: Predictors of outcome in surgically managed patients with typical and atypical trigeminal neuralgia: Comparison of results following microvascular decompression. *J Neurosurgery* 96:527-531, 2002. <https://doi.org/10.3171/jns.2002.96.3.0527>
40. Ugwuanyi UC, Kitchen ND: The operative findings in redo microvascular decompression for recurrent trigeminal neuralgia. *Br J Neurosurg* 24:26-30, 2010. <https://doi.org/10.3109/02688690903507489>
41. Van Hecke O, Austin SK, Khan RA, Smith BH, Torrance N: Neuropathic pain in the general population: A systematic review of epidemiological studies. *Pain* 155:654-662, 2014. <https://doi.org/10.1016/j.pain.2013.11.013>
42. Yang DB, Jiang DY, Chen HC, Wang ZM: Second microvascular decompression for trigeminal neuralgia in recurrent cases after microvascular decompression. *J Craniofac Surg* 26: 491-494, 2015. <https://doi.org/10.1097/SCS.0000000000001523>
43. Young JN, Wilkins RH: Partial sensory trigeminal rhizotomy at the pons for trigeminal neuralgia. *J Neurosurg* 79:680-687, 1993. <https://doi.org/10.3171/jns.1993.79.5.0680>
44. Zhang L, Zhang Y, Li C, Zhu S: Surgical treatment of primary trigeminal neuralgia: Comparison of the effectiveness between MVD and MVD+PSR in a series of 210 patients. *Turk Neurosurg* 22:32-38, 2012. <https://doi.org/10.5137/1019-5149.JTN.4447-11.2>