



Full-Endoscopic Lumbar Discectomy: Tips & Tricks for New Users Based on a Retrospective Observational Study of the First 100 Patients

Konstantinos PANAGIOTOPOULOS¹, Roberto GAZZERI², Santo R. PRINCIOTTO³, Giovanni PENNISI⁴, Umberto AGRILLO¹

¹San Giovanni-Addolorata Hospital, Department of Neurosurgery, Rome, Italy

²San Giovanni-Addolorata Hospital, Pain Therapy Unit Rome, Rome, Italy

³“Ospedale del Mare” Hospital, Department of Neurosurgery, Naples, Italy

⁴Catholic University School of Medicine, Department of Neuroscience, Section of Neurosurgery, Rome, Italy

Corresponding author: Giovanni PENNISI ✉ giovannipennisi91@gmail.com

ABSTRACT

AIM: To report our institutional experience with full-endoscopic lumbar discectomy (FELD) and analyzed the pertinent literature.

MATERIAL and METHODS: We retrospectively enrolled 100 patients who had undergone full-endoscopic discectomy for lumbar disc herniation using either an interlaminar (IL) or transforaminal (TF) approach. All patients underwent pre-operative imaging. Before and after surgery, patients' pain and disability levels were measured using visual analog scale (VAS) and Oswestry disability index (ODI) respectively. Clinical outcomes were assessed using the modified MacNab criteria. Patients were divided into two groups, Group 1 (cases 1-50) and Group 2 (cases 51-100), and their learning curve factors were compared using a Student's t-test.

RESULTS: Sixty-nine cases were operated via an IL approach and the remaining 31 cases using a TF approach. There were 4 early conversions in microdiscectomy. The mean operative time of the 96 procedures was 57 min. In Group 1, the mean operative time was 61.7 minutes (range: 35-110); in Group 2, it was 52.3 minutes (range: 25-75). The difference between the two groups was statistically significant ($p=0.009$). No significant differences were found in conversions, early operations, and recurrences between Groups 1 and 2. Both groups experienced a significant reduction in postoperative VAS and ODI compared to preoperative scores.

CONCLUSION: The findings support previously reported information on the safety and effectiveness of the FELD. Herein, we share some practical tips and tricks based on our initial experience and on the review of the available literature, which could facilitate new users. In experienced hands endoscopic techniques make treatment of herniated discs feasible independently of patient age, anatomy, and/or targeted pathology features. Conversely, thoughtful patient selection and careful preoperative planning are highly recommended for new users.

KEYWORDS: Full-endoscopic lumbar discectomy, Learning curve, Lumbar herniated disc, Minimally invasive spine surgery

INTRODUCTION

Full-endoscopic lumbar discectomy (FELD) has become a popular surgical choice for lumbar disc herniation in recent years due to its effectiveness (22,25,27). Clinical results were reported to be comparable with those of

microdiscectomy (12,17,25,27,30). In addition, endoscopic procedures may result in less postoperative pain, fibrosis and instability (2,16,25,27,28).

New surgical techniques and developing endoscopy technologies have made full-endoscopic surgery for herniated discs

both inside and outside the spinal canal possible by using interlaminar, transforaminal, or extraforaminal approaches. (5,11,26,33). Nevertheless, beginners need to deal with a demanding learning curve before acquiring the skills necessary to minimize the risk of complications and failures (1,19,34). Full-endoscopic procedures differ significantly from traditional microsurgery as these are truly percutaneous in-and-out approaches, requiring an initial blind puncture technique under continuous fluoroscopy to reach the targeted area, and, thus, are associated with specific technique-related complications (6,9,10,23,29). It follows that these factors, along with increased radiation exposure and possible clinical failures may discourage new users from keeping on with endoscopy (7,9,31,35).

The aim of our study was to retrospectively review the early experience of using FELD to treat lumbar herniated disc in the first 100 consecutive cases. Moreover, we reviewed similar studies dealing with the FELD learning curve to highlight debated issues and data discrepancies, and, lastly, we provided some tips and tricks for new users.

■ MATERIAL and METHODS

We conducted a retrospective review of the first 100 patients who underwent full-endoscopic discectomy for lumbar disc herniation performed by two surgeons (the first and the senior authors), previously not familiar with endoscopic lumbar surgery. Before performing endoscopic surgery, both surgeons had attended live surgery of endoscopic cases performed by expert surgeons on two occasions as well as two cadaver workshops. Both were skilled in spinal microsurgery.

Patient selection for endoscopic lumbar surgery was based on Ruetten selection/inclusion criteria (26,28). All patients underwent lumbar MRI and anterior-posterior and lateral X-rays of the spine. We favored single-level lumbar intracanalicular contained or extruded disc herniation causing persistent, predominant radicular symptomatic compression with or without back pain. An adequately wide interlaminar window and no spinal canal stenosis were present in the interlaminar approach cases (4,18,28,34). No foraminal stenosis and no high-riding iliac crest were present in the transforaminal cases (18,28).

Cases of a recurrent herniated disc or cauda equine syndrome were excluded. All patients failed standard conservative treatment (drugs, physical therapy, injections, rest etc.) of at least 6 weeks duration, excluding cases of intractable pain in which surgery was variably anticipated. All patients provided

a thoroughly informed consent for the endoscopic procedure versus standard microdiscectomy.

We performed interlaminar (IL) or transforaminal (TF) endoscopic procedures according to the technique previously described by Ruetten (26,28) using the Richard Wolf GmbH Vertebri lumbar full-endoscopic spine instrument set. All procedures were performed with the patient under general anesthesia in a prone position. Preoperative and final follow-up assessments of leg and back pain were conducted using Visual Analogue Scale (VAS) and the Oswestry Disability Index (ODI). The final assessment was done through telephone interviews or in-hospital visits. Clinical outcomes were evaluated according to the modified MacNab criteria (Table I).

To study the learning curve, patients were divided into two groups: Group 1 (cases 1-50) and Group 2 (cases 51-100). Operation time, conversions, early reoperations, and recurrences were compared between the two groups. A statistical analysis was performed using Student's t-test to compare the preoperative scores and the outcome at the final follow-up, as well as the operation times between the two groups. A p-value of <0.05 was considered significant.

Ethics Approval and Consent: Ethical approval was waived by the local Ethics Committee of Azienda Ospedaliera San Giovanni Addolorata because all the procedures performed were part of routine care. Informed consent was obtained.

■ RESULTS

From April 2013 to May 2016, 100 patients received endoscopic lumbar discectomy, including 54 women and 46 men. The patients' mean age was 44.2 years (ranging from 20 to 83 years). Sixty-nine operations were performed via an IL approach, including all 67 L5-S1 cases and 2 L4-L5 cases. In the latter cases, the L4-L5 interlaminar window was judged wide enough to allow an interlaminar approach to be performed by a beginner endoscopic surgeon. The remaining 26 L4-L5 and L3-L4 cases were operated on using a TF approach. Table II summarizes the overall Group 1 and Group 2 demographics and treated levels. There were no significant statistical differences observed between Group 1 and Group 2. Figure 1 shows the flow diagram of the results of full-endoscopic procedures. Overall, there were 4 early conversions in microdiscectomy. In one case, an incidental durotomy occurred by turning the beveled working channel to hook the nerve root, and it was directly repaired by converting the procedure to microsurgery. In 3 cases, the disc material removal was seen as insufficient or technically

Table I: Modified MacNab Criteria

| Result | Definition |
|-----------|-----------------------------------------------------------------------------------------------------|
| Excellent | No pain, no functional restrictions; able to return to normal work and original level of activities |
| Good | Occasional non-radicular pain, relief of presenting symptoms; able to return to modified work |
| Fair | Some improved overall function, permanent work and activities of daily living restrictions |
| Poor | No improvement in pain/functional level or reoperation at index level |

difficult. According to Table III, the average duration of the 96 successful procedures was 57 minutes. In Group 1, which consisted of 48 patients, the average operation time was 61.7 minutes (ranging from 35 to 110 minutes). In Group 2, which also had 48 patients, the average operation time was

52.3 minutes (ranging from 25 to 75 minutes). The difference between the two groups was statistically significant ($p=0.009$). No statistically significant differences in conversions, early operations and recurrences between Groups 1 and 2 were found.

Table II: Demographics and Levels Treated in Groups 1 and 2

| | Total (n=100) | Group 1 | Group 2 | p-value |
|------------------|---------------|--------------|--------------|---------|
| Men | 46 | 20 | 26 | >0.05 |
| Women | 54 | 30 | 24 | >0.05 |
| Mean age (range) | 44.2 (20-83) | 45.3 (22-83) | 43.0 (20-76) | >0.05 |
| L3-L4 | 5 | 2 | 3 | >0.05 |
| L4-L5 | 28 | 18 | 10 | >0.05 |
| L5-S1 | 67 | 30 | 37 | >0.05 |
| IL | 69 | 31 | 38 | >0.05 |
| TF | 31 | 19 | 12 | >0.05 |

Group 1: Cases 1-50; **Group 2:** Cases 51-100; **IL:** Interlaminar approach; **TF:** Transforaminal approach.

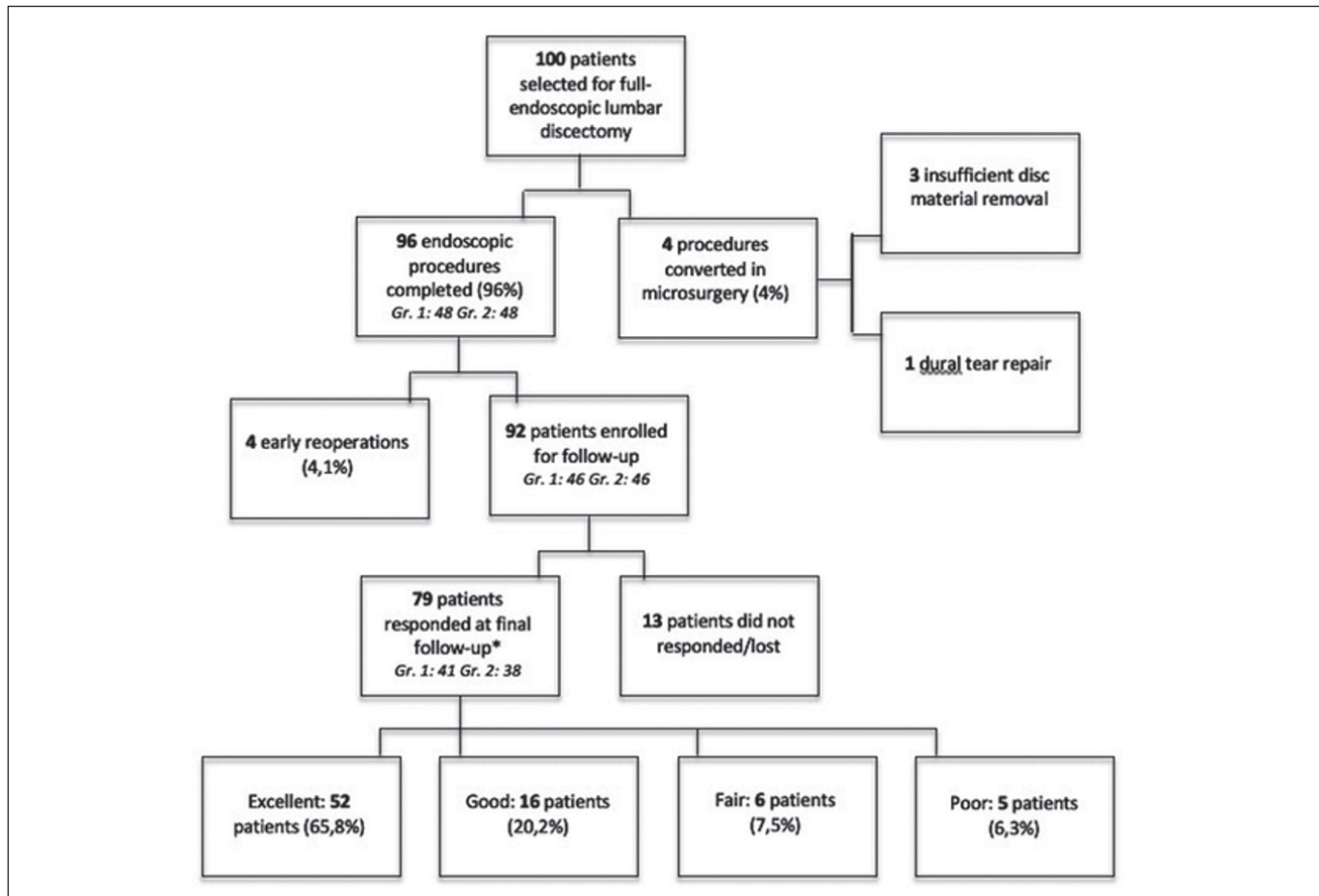


Figure 1: Flow diagram showing the results of full-endoscopic procedures. Group 1= Gr. 1 (cases 1-50); Group 2= Gr. 2 (cases 51-100).* = evaluation according to the modified MacNab criteria.

Table III: Comparison of Operation Data in Groups 1 and 2

| | Total (n=100) | Group 1 | Group 2 | p-value |
|------------------------------------|-----------------------|-----------------------|-----------------------|--------------|
| Conversions [§] | 4 | 2 | 2 | >0.05 |
| Operation time (min), mean (range) | 57.0 (n=96) | 61.7 (35-110) | 52.3 (25-75) | 0.009 |
| Early reoperations* | 4 (n=96) | 2 (n=48) | 2 (n=48) | >0.05 |
| Recurrences | 5 (n=79) [†] | 3 (n=41) [^] | 2 (n=38) ⁻ | >0.05 |

Group 1: cases 1-50; **Group 2:** cases 51-100; [§]: conversions in microdiscectomy, ^{*}: within 1 month from first surgery, [†]mean follow-up: 23,24 months; [^] mean follow-up: 28,56 months; ⁻ mean follow-up: 17,50 months.

Table IV: Changes in VAS and ODI Before Surgery and at Final Follow-up

| | Total (n=79) | | Group 1 (n=41) | | Group 2 (n=38) | |
|----------------|-----------------|---------------|-----------------|---------------|-----------------|---------------|
| | Preop | Final FU | Preop | Final FU | Preop | Final FU |
| VAS leg pain | 8.93 (1.30) | 1.74 (2.49) | 8.65 (1.51) | 1.85 (2.52) | 9.23 (0.97) | 1.63 (2.48) |
| VAS back pain | 6.97 (2.43) | 1.93 (2.34) | 6.63 (2.64) | 2.21 (2.25) | 7.34 (2.15) | 1.63 (2.43) |
| ODI | 60.12 (11.74) | 12.16 (16.12) | 58.78 (10.57) | 13.02 (15.95) | 61.57 (12.73) | 11.23 (16.25) |
| FU* | 23.24 (7.02) | | 28.56 (5.47) | | 17.50 (2.51) | |
| p-value | <0.05 | | <0.05 | | <0.05 | |

Group 1: cases 1-50, **Group 2:** cases 51-100, Values are expressed as means (SD), ^{*}FU: follow-up. **ODI:** Oswestry Disability Index, **VAS:** Visual Analog Score, **FU:** Follow-up.

There was no blood loss that could be measured and it was not necessary to place a drain in any of the cases. Eight patients (6 following TF and 2 following IL procedure) suffering from postoperative transient numbness, were treated with medical therapy. In all cases, symptoms resolved completely in a period between 3 days and 4 weeks after surgery. There was 1 case of postoperative partial L5 motor deficit in a patient with concomitant persisting leg pain following a TF procedure. A postoperative MRI showed inadequate herniated disc removal and the patient underwent early repeat surgery. Pain resolved promptly, and the patient was referred for rehabilitation of the residual motor deficit. In further 3 cases of persisting postoperative pain, in which an early MRI detected a significant residual herniated disc, a microdiscectomy was performed within 1 month from the endoscopic procedure. There were no infections in this series. Eighty patients (83%) were discharged the day after surgery. The remaining 16 patients had their hospitalization variably prolonged due to persistent radiculopathy, transient postoperative dysesthesia or back discomfort (12 patients) and for non-medical reasons (4 patients).

A total of 92 patients were enrolled for follow-up (Figure 1). Thirteen patients did not respond or were lost for the final follow-up. The mean follow-up time was 23.24 months (13-42 months). At the final follow-up, both Group 1 and 2 showed significant reductions in VAS and ODI scores compared to preoperative scores (Table IV). At final follow-up, 52 patients (65.8%) had excellent outcomes, 16 (20.2%) had good outcomes, 6 (7.5%) had fair outcomes, and 5 (6.3%) had poor outcomes according to the modified MacNab criteria (Figure 1).

■ DISCUSSION

Our results confirm the data previously reported in studies dealing with the learning curve related to the safety and efficiency of FELD. There was no significant bleeding, no infections and there was only one case of postoperative foot drop requiring rehabilitation trial. Excellent or good results were reported in 86% of cases at the final follow-up. Five recurrent herniated disc cases were observed with a mean follow-up of 23,2 months (6.3%). Recurrence rates reported in similar studies are highly variable, ranging from 0 to 27,9% (Table V). Similar discrepancies are observed in conversion rates (0-19%) and repeat surgeries (0-23,5%) (1,9,10,12,14,15,18-21,24,31,34) (Table V). A possible explanation may be the high heterogeneity in study designs and measured variables. Patient selection, population demographics, volume of procedures, study time-span and follow-up intervals, surgical target strategies, puncture techniques, recurrence management and others, are all factors variably contributing to the observed heterogeneity, making comparison between studies and conclusions subject to biases.

The learning curve of endoscopic lumbar discectomy is generally accepted as steep and demanding, compared with standard microsurgery (1,26,30). The learning curve has been grossly defined as the time taken and/or the number of procedures an average surgeon needs, to be able to perform a procedure independently, with a reasonable outcome (32). In FELD-related literature, the point in which the operative time rapidly decreases before tapering to a steady state has been considered to represent skill acquisition for a beginner (1,12,14). Yet, generally speaking, there has been no universal definition of endpoints, including patient outcome and

surgeon competency and a main issue is that few outcomes or endpoints in learning-curve studies will assess true competency (16). Likewise, it remains unclear how the “average surgeon” or “reasonable outcome” should be defined (32).

Herein, we share some practical tips and tricks based on our initial experience and on the review of the available literature, which could facilitate surgeons who are just starting to use endoscopic lumbar discectomy.

Tips & Tricks for new users:

Patient selection: Patient selection is of paramount importance for new users (1,19). Select patients without bony deformity and/or central or lateral recess stenosis. A gradual introduction of drilling in your procedures will expand the indications and the possibilities to manage anatomic diversities, but this may be challenging during an initial experience with the technique. Broad-based subligamentous retained herniated discs may be technically hard to remove. Favoring cases with small herniated discs may be safer during early experience (7,10,14). Large extruded fragments leave little space to move within the spinal canal, making navigation with the endoscope

difficult. Also, they may be related to a higher recurrence rate (15,25,34). Herniated fragments in the root axilla also may be more difficult to manage for beginners (7). Long-standing herniated discs in patients with chronic pain may reflect local inflammatory changes like adhesions or neovascularization, which may render potentially problematic the nerve root/disc fragment dissection (34). Similarly troublesome cases may be high-grade migrated herniated discs and/or calcified herniated discs (7,17,24). We believe that previous microdiscectomy in the same level may be a demanding condition for beginners although some Authors did not exclude such cases in the learning curve period (12,20,25,32).

Preoperative imaging: Consider obtaining the most recent preoperative MRI possible. Ruetten. reported 9% of cases with intraoperative findings being not congruous with the preoperative MRI, which often lead to reoperations. They found a significant relationship with complaints longer than 6 months (26). For beginners, targeted fragmentectomy is the primary goal, with canal space navigation being possibly limited because of limited technical skills. A recent MRI may let us know what we have to get and where, reducing the

Table V: Study Characteristics

| Author, year | Study design | Approaches | Number of patients | Mean age* (range) | Series time span** | Mean follow-up** (range) | Lost in follow-up (%) | Inclusion criteria | | |
|---------------------------------|--------------|------------|--------------------|-------------------|--------------------|--------------------------|-----------------------|--------------------|------------------|------------------|
| | | | | | | | | Levels treated | Multilevel cases | Recurrence cases |
| Hsu et al., 2013 (12) | Rt | TF, IL | 59 | 44.2 (n.r.) | 36 | 20.4 (12-24) | 11/57 (19.2) | L1-S1 | Yes | Yes |
| Sencer et al., 2014 (31) | Pr | TF, IL | 163 | 47 (18-78) | 29 | 12 | None | L1-S1 | Yes | Yes |
| Kong et al., 2016 (18) | Pr | EF, IL | 62 | 51.6 (18-73) | 19 | 12 | None | L3-S1 | No | No |
| Joswig, 2016 (14) | Rt | IL | 76 | 39.3 (17-62) | 60 | 3.4 (1-6)* | 21/68 (30.8) | L4-S1 | No | No |
| Hirano et al., 2012 (10) | Pr | TF, EF, IL | 37 | 42.6 (16-86) | 26 | 3 | None | L1-S1 | No | n.r. |
| Ahn et al., 2015 (1) | Rt | TF | 35 | 24.4 (n.r.) | 17 | 13.3 (12-n.r.) | None | L3-L5 | No | No |
| Lee et al., 2008 (19) | Pr | TF | 51 | 36.4 (17-55) | 12 | 12 | None | L4-S1 | No | Yes |
| Wang et al., 2011 (34) | Pr | IL | 30 | 36.1 (20-52) | 24 | 1.61* (1.2-2.0) | None | L4-S1 | No | No |
| Wu et al., 2016 (35) | Rt | TF, IL | 120 | 40.2 (n.r.) | 26 | 15.9 (12-n.r.) | None | L4-S1 | No | No |
| Fan et al., 2016 (9) | Rt | TF | 120 | 57.5 (n.r.) | 34 | 25.9 (12-n.r.) | None | L3-S1 | No | No |
| Passacantilli et al., 2015 (24) | Pr | IL | 100 | 51 (26-76) | 24 | 24 | None | L5-S1 | No | Yes |
| Mahesha, 2017 (21) | Rt | TF, IL | 100 | 40.2 (15-84) | 20 | 24 (18-36) | None | L1-S1 | Yes | No |
| Kafadar et al., 2006 (15) | Pr | TF | 42 | n.r. (18-74) | 24 | 15 (6-24) | None | L4-L5 | No | No |
| Present study | Rt | TF, IL | 100 | 44.2 (20-83) | 37 | 23.2 (13-42) | 13/92 (14.1) | L3-S1 | No | No |

Rt: Retrospective; **Pr:** prospective; **TF:** transforaminal; **EF:** extraforaminal; **IL:** interlaminar

* years, ** months, **n.r.:** not reported/unclear, **n:** number of patients-procedures, **^** conversions in microdiscectomy, **§** during the immediate postoperative period.

Table V: Cont.

| Author, year | Number of surgeons | Endoscopic system | Anesthesia | Dural tears (%) | Post-op nerve injury + irritation/n (%) | Conversions [^] - discontinued surgery (%) | Persisting pain with residual hernia ^s /n (%) | Recurrences/n (%) | Repeat surgeries/n (%) |
|---------------------------------|--------------------|-------------------|-------------------|-----------------|-----------------------------------------|-----------------------------------------------------|----------------------------------------------------------|-------------------|------------------------|
| Hsu et al., 2013 (12) | 1 | Wolf | General | None | 6/53 (11.3) | 2 (3.3) | 4/57 (7.0) | 2/53 (3,7) | 6/57 (10,5) |
| Sencer et al., 2014 (31) | n.r. | Wolf | General | 6 (3.6) | 9/163 (5.5) | None | 2/163 (1.2) | 6/163 (3,6) | 8/163 (4,9) |
| Kong et al., 2016 (18) | n.r. | Spinendos Co | Epidural | None | 6/60 (10) | 2 (3.2) | None | None | None |
| Joswig, 2016 (14) | 2 | Wolf | General | 3 (3.9) | 1/68 (1.4) | 8 (10.5) | n.r. | 19 (27.9) | 16 (23.5) |
| Hirano et al., 2012 (10) | n.r. | Wolf | Local/sedation | n.r. | None | 3 (8.1) | None | 2/34 (5.8) | 2/34 (5.8) |
| Ahn et al., 2015 (1) | 1 | n.r. | Local/sedation | n.r. | 1/35 (2.8) | None | 2/35 (5.7) | 1/35 (2.8) | n.r. |
| Lee et al., 2008 (19) | 1 | n.r. | Local | n.r. | 1/51 (1.9) | None | 4/51 (7.8) | 5/47 (10.6) | 6/51 (11.7) |
| Wang et al., 2011 (34) | 2 | Wolf | General | 2 (6.6) | 1/30 (3.3) | 2 (6.6) | None | None | None |
| Wu et al., 2016 (35) | 1 | Wolf, Joimax | Local | n.r. | 8/118 (6.7) | 2 (1.6) | 6/118 (5.0) | 5/118 (4.2) | 7/118 (5.9) |
| Fan et al., 2016 (9) | 2 | n.r. | Local | None | 1/120 (0.8) | None | 2/120 (1.6) | 3/120 (2.5) | 5/120 (4.1) |
| Passacantilli et al., 2015 (24) | n.r. | Wolf | Epidural; general | 3 (3) | 1/97 (1.0) | 3 (3) | n.r. | 5/97 (5.1) | 6/97 (6.1) |
| Mahesha, 2017 (21) | 1 | Storz | Local/sedation | 1 (1) | 1/100 (1) | None | n.r. | 2/100 (2) | 2/100 (2) |
| Kafadar et al., 2006 (15) | n.r. | Storz | Local/sedation | 1 (2.3) | 2/34 (5.8) | 8 (19.0) | 3/34 (8.8) | 4/34 (11.7) | 7/34 (20.5) |
| Present study | 2 | Wolf | General | 3 (3) | 9/96 (9.3) | 4 (4) | 4/96 (4.1) | 5/79 (6.3) | 9/79 (11.3) |

R: retrospective; **P:** prospective; **TF:** transforaminal; **EF:** extraforaminal; **IL:** interlaminar

* years, ** months, **n.r.:** not reported/unclear, **n:** number of patients-procedures, [^]conversions in microdiscectomy, ^s during the immediate postoperative period.

risk of missing pathology. Perform CT scanning when disc is hard and calcified (low signal intensity on MRI) (12,14). The interlaminar approach should be performed after careful evaluation of the interlaminar window on plain X-rays (36).

Approach to start with: It is undeniable that the transforaminal approach relies on a complex puncture technique and longer radiation exposure (18,36). The surgical route of this approach may appear unfamiliar to spine surgeons using routinely standard microsurgical techniques. However, multiple authors have discovered that the learning curve for the transforaminal approach plateaus after approximately the 10th case. This results in a steep learning curve for the surgeon and a quick acquisition of skills (1,12). Furthermore, Hirano et al. founded more demanding the extraforaminal and the interlaminar approach (10). Possibly, the most technically challenging approach is the extraforaminal, requiring a free-

hand technique to remove herniated discs situated outside the neural foramen, with few anatomic landmarks. Yue et al. suggested that surgeons should begin integrating endoscopic techniques into their practice by first performing transforaminal procedures, followed by interlaminar cases (36). Still, the interlaminar approach requires faster puncture orientation and less intraoperative radiation exposure. In accordance with other authors, we believe that the familiar surgical anatomy of the interlaminar pathway for surgeons who regularly practice microdiscectomy makes the interlaminar approach more “attractive” to deal with (18,31,36).

Operating Room Setup: Although the lateral position has been reported for the transforaminal approach (15), the standard position for opening the interlaminar space and foraminal area is prone on bolsters or a spinal frame, with the back flexed as much as safely possible (18,24,28). The position of the X-ray

c-arm and the height of the operating table must be checked for the operating team's comfort (18). We found it more comfortable for the surgeon to position himself slightly higher alongside the operating table using a platform, compared with microsurgery cases. This facilitates the endoscope handling in interlaminar approaches, by keeping the arms in a lower position compared to the shoulders. It may also be more functional for surgeons to manage the footplate of the coagulation pedal by themselves.

Anesthesia: Several studies reported reduced surgery-related morbidity under local anesthesia compared with general anesthesia (3,5,19). Local anesthesia also allows for intraoperative feedback from the patient, thus minimizing the risk of nerve damage during insertion of the working sheath (3–5,19). However, experienced surgical teams in endoscopic procedures reported large surgical series when using general anesthesia (27). During FELD, local anesthesia can potentially lead to complications such as posterior neck and thoracic back pain, headaches, and even unconsciousness. These complications may arise due to the high cervical epidural pressure on the meninges caused by the large amounts of saline irrigation fluid used (13). Notably, local anesthesia procedures are related to the risk of discontinuation of the surgery (1,10). We believe that new users might feel more comfortable during procedures under general anesthesia as in such case the procedure can be converted into microsurgery more easily, if necessary.

Technical tips: Key technical features of the endoscopic surgery include the blind puncture technique to reach the target area, the joystick-like handling of the endoscope and the inside-out orientation. Hands-on cadaver workshops, live-surgery seminars attendance, and epidural block training procedures are highly recommended for beginners (1,4,10,19,36). The joystick principle of handling the endoscope is a key feature of this technique (27). Once the surgeon becomes familiar with it, he or she may appreciate the advantage to display an all-around mobility that permits to visualize the structures from different angulations, facilitates maneuvers and allows for searching and removing the target pathology (4). Moving the endoscope outward, upward, or downward while leveraging the working channel and rotating it improves control over the instrument as well as recognition of anatomical structures (8,17). To do so, one may also use the bipolar to carefully shrink structures, although the epidural fat, acting as a natural lubricant, should be preserved (24,27,31). Moreover, the trigger-flex bipolar probe may be used not only to release adipose tissue and coagulate blood vessels but also as the tip of a dissector, without cauterizing, to palpate structures and explore “behind the angle” spaces (18). Intraoperative good-quality lateral and/or anteroposterior fluoroscopic control aims to verify the correct position of the working field and the instruments, facilitating orientation. Anyhow, a thorough understanding of the foraminal and intracanal “endoscopic” anatomy, as long as preoperative planning on CT and MRI is mandatory for a safe surgical performance (36).

Intraoperative bleeding and dural tears: Typical concerns of beginners include intraoperative bleeding and dural tears. Bleeding is usually well-controlled by continuous irrigation. The hemostasis may be boosted by increasing the pressure of fluid irrigation (15,21). Often, moving inwards the endoscope through the blurred image of blood, one may “clear” the view and detect the bleeding spot easily under higher magnification. Similarly, dural tears are rarely a problem and usually, there is no need for direct dural repair. Instead, we did so out of limited mastery of the technique, in our first case of durotomy during the endoscopic procedure. The limited surgical access creates virtually no dead space at all, and mostly, dural tears may be as large as those of external lumbar puncture. These factors virtually eliminate the risk of fistula (14,31).

We agree with other authors who suggested that mastery of open and microsurgical techniques is required before integrating endoscopic procedures into everyday practice (36). The option of conversion to an open or microsurgical procedure during surgery should be considered (28). Even though endoscopic techniques are widely used by pain management physicians, radiologists and anesthesiologists, with good results reported, we believe that endoscopic discectomy does not lie in the same area of percutaneous/needle procedures like percutaneous lumbar disc decompression, coblation, nucleoplasty etc. Instead, it constitutes a true surgical procedure, in which the targeted pathology is encountered under direct visualization and, as such, it should be performed by surgeons skilled in standard microsurgical techniques. The latter is a factor allowing to deal with inadequate fragmentectomy, difficult anatomy, spatial disorientation etc. by easily switching to microsurgical technique rather than discontinuing and planning a new operation.

The study's main limitations include a retrospective design, patient selection bias, and a series conducted by two surgeons.

■ CONCLUSION

In experienced hands, endoscopic techniques make treatment of herniated disc feasible independently of patient age, anatomy and/or targeted pathology features. Conversely, thoughtful patient selection and careful preoperative planning are highly recommended for new users.

AUTHORSHIP CONTRIBUTION

Study conception and design: KP, RG, UA

Data collection: KP, UA, RG, SP

Analysis and interpretation of results: RG, KP, GP

Draft manuscript preparation: KG, GP

Critical revision of the article: GP, UA, RG

All authors (KP, RG, SRP, GP, UA) reviewed the results and approved the final version of the manuscript.

■ REFERENCES

- Ahn SS, Kim SH, Kim DW: Learning curve of percutaneous endoscopic lumbar discectomy on the period (Early vs. Late) and technique (in-and-out vs. in-and-out-and-in): A retrospective comparative study. *J Korean Neurosurg Soc* 58:539-546, 2015. <https://doi.org/10.3340/jkns.2015.58.6.539>
- Ahn SS, Kim SH, Kim DW, Lee BH: Comparison of outcomes of percutaneous endoscopic lumbar discectomy and open lumbar microdiscectomy for young adults: A retrospective matched cohort study. *World Neurosurg* 86:250-258, 2016. <https://doi.org/10.1016/j.wneu.2015.09.047>
- Ahn Y: Transforaminal percutaneous endoscopic lumbar discectomy: Technical tips to prevent complications. *Expert Rev Med Devices* 9:361-366, 2012. <https://doi.org/10.1586/erd.12.23>
- Chen HT, Tsai CH, Chao SC, Kao TH, Chen YJ, Hsu HC, Chiung-CC, Tsou HK: Endoscopic discectomy of L5-S1 disc herniation via an interlaminar approach: Prospective controlled study under local and general anesthesia. *Surg Neurol Int* 2:93, 2011. <https://doi.org/10.4103/2152-7806.82570>
- Choi G, Lee SH, Raiturker PP, Lee S, Chae YS: Percutaneous endoscopic interlaminar discectomy for intracanalicular disc herniations at L5-S1 using a rigid working channel endoscope. *Neurosurgery* 58 ONS Suppl 1:59-68, 2006. <https://doi.org/10.1227/01.NEU.0000192713.95921.4A>
- Choi I, Ahn JO, So WS, S-j L, Choi IJ, Kim H: Exiting root injury in transforaminal endoscopic discectomy: Preoperative image considerations for safety. *Eur Spine J* 22:2481-2487, 2013. <https://doi.org/10.1007/s00586-013-2849-7>
- Choi KC, Lee JH, Kim JS, Sabal LA, Lee S, Kim H, Lee SH: Unsuccessful percutaneous endoscopic lumbar discectomy: A single-center experience of 10228 cases. *Neurosurgery* 76:372-381, 2015. <https://doi.org/10.1227/NEU.0000000000000628>
- Eun SS, Lee SH, Erken HY: Transforaminal percutaneous endoscopic lumbar discectomy for downmigrated disk herniations: Lever-up, rotate, and tilt technique. *J Neurol Surg A Cent Eur Neurosurg* 79:163-168, 2018. <https://doi.org/10.1055/s-0037-1608837>
- Fan G, Han R, Gu X, Zhang H, Guan X, Fan Y, Wang T, He S: Navigation improves the learning curve of transforaminal percutaneous endoscopic lumbar discectomy. *Int Orthop* 41:323-332, 2017. <https://doi.org/10.1007/s00264-016-3281-5>
- Hirano Y, Mizuno J, Takeda M, Itoh Y, Matsuoka H, Watanabe K: Percutaneous endoscopic lumbar discectomy - early clinical experience. *Neurol Med Chir* 52:625-630, 2012. <https://doi.org/10.2176/nmc.52.625>
- Hoogland T, Schubert M, Miklitz B, Ramirez A: Transforaminal posterolateral endoscopic discectomy with or without the combination of a low-dose chymopapain: A prospective randomized study in 280 consecutive cases. *Spine* 31:890-897, 2006. <https://doi.org/10.1097/01.brs.0000245955.22358.3a>
- Hsu HT, Chang SJ, Yang SS, Chai CL: Learning curve of full-endoscopic lumbar discectomy. *Eur Spine J* 22:727-733, 2013. <https://doi.org/10.1007/s00586-012-2540-4>
- Jho JY, Choi G, Kong BJ, Park HS, Lee SH, Chang SH: Comparative study of neck pain in relation to increase of cervical epidural pressure during percutaneous endoscopic lumbar discectomy. *Spine* 34:2033-2038, 2009. <https://doi.org/10.1097/BRS.0b013e3181b20250>
- Joswig H, Richter H, Haile SR, Hildebrandt G, Fournier JY: Introducing interlaminar full-endoscopic lumbar discectomy: A critical analysis of complications, recurrence rates, and outcome in view of two spinal surgeons' learning curves. *J Neurol Surg A Cent Eur Neurosurg* 77:406-415, 2016. <https://doi.org/10.1055/s-0035-1570343>
- Kafadar A, Kahraman S, Akboru M: Percutaneous endoscopic transforaminal lumbar discectomy: A critical appraisal. *Minim Invas Neurosurg* 49:74-79, 2006. <https://doi.org/10.1055/s-2006-932184>
- Kamson S, Trescot A, Sampson PD, Zhang Y: Outpatient, ambulatory facility: Report of 5 years of complications and risk factors. *Pain Physician* 20:E221-E231, 2017. <https://doi.org/10.36076/ppj.2017.E231>
- Kim MJ, Lee SH, Jung ES, Son BG, Choi ES, Shin JH, Sung JK, Chi YC: Targeted percutaneous transforaminal endoscopic discectomy in 295 patients: Comparison with results of microscopic discectomy. *Surg Neurol* 68:623-631, 2007. <https://doi.org/10.1016/j.surneu.2006.12.051>
- Kong W, Liao W, Ao J, Cao G, Qin J, Cai Y: The strategy and early clinical outcome of percutaneous full-endoscopic interlaminar or extraforaminal approach for treatment of lumbar disc herniation. *Biomed Res Int* 2016:4702946, 2016. <https://doi.org/10.1155/2016/4702946>
- Lee DY, Lee SH: Learning curve for percutaneous endoscopic lumbar discectomy. *Neuro Med Chir* 48:383-389, 2008. <https://doi.org/10.2176/nmc.48.383>
- Li XC, Zhong CF, Deng GB, Liang RW, Huang CM: Full-endoscopic procedures versus traditional discectomy surgery for discectomy: A systematic review and meta-analysis of current global clinical trials. *Pain Physician* 19:103-118, 2016. <https://doi.org/10.36076/ppj/2019.19.103>
- Mahesha K: Percutaneous endoscopic lumbar discectomy: Results of first 100 cases. *Indian J Orthop* 5:36-42, 2017. <https://doi.org/10.4103/0019-5413.197520>
- Pan Z, Ha Y, Yi S, Cao K: Efficacy of transforaminal endoscopic spine system (TESSYS) technique in treating lumbar disc herniation. *Med Sci Monit* 22:530-539, 2016. <https://doi.org/10.12659/MSM.894870>
- Panagiotopoulos K, Gazzeri R, Bruni A, Agrillo U: Pseudoaneurysm of a segmental lumbar artery following a full-endoscopic transforaminal lumbar discectomy: A rare approach-related complication. *Acta Neurochir* 161:907-910, 2019. <https://doi.org/10.1007/s00701-019-03876-7>
- Passacantilli E, Lenzi J, Caporlingua F, Pescatori L, Lapadula G, Nardone A, Santoro A: Endoscopic interlaminar approach for intracanal L5-S1 disc herniation: Classification of disc prolapse in relation to learning curve and surgical outcome. *Asian J Endosc Surg* 8:445-453, 2015. <https://doi.org/10.1117/ases.12214>

25. Phan K, Xu J, Schultz K, Alvi MA, Lu VM, Kerezoudis P, Maloney PR, Murphy ME, Mobbs RJ, Bydon M: Full-endoscopic versus micro-endoscopic and open discectomy: A systematic review and meta-analysis of outcomes and complications. *Clin Neurol Neurosurg* 154:1-12, 2017. <https://doi.org/10.1016/j.clineuro.2017.01.003>
26. Ruetten S, Komp M, Godolias G: An extreme lateral access for the surgery of lumbar disc herniation inside the spinal canal using the full-endoscopic uniportal transforaminal approach. Technique and prospective results of 463 patients. *Spine* 30:2570-2578, 2005. <https://doi.org/10.1097/01.brs.0000186327.21435.cc>
27. Ruetten S, Komp M, Merk H, Godolias G: Full-endoscopic interlaminar and transforaminal lumbar discectomy versus conventional microsurgical technique: A prospective, randomized, controlled study. *Spine* 33:931-939, 2008. <https://doi.org/10.1097/BRS.0b013e31816c8af7>
28. Ruetten S, Komp M, Merk H, Godolias G: Use of newly developed instruments and endoscopes: Full-endoscopic resection of lumbar disc herniations via the interlaminar and lateral transforaminal approach. *J Neurosurg Spine* 6:521-530, 2007. <https://doi.org/10.3171/spi.2007.6.6.2>
29. Sairyo K, Matsuura T, Higashino K, Sakai T, Takata Y, Goda Y, Suzue N, Hamada D, Goto T, Nishisho T, Sato R, Tsutsui T, Tonogai I, Mineta K: Surgery related complications in percutaneous endoscopic lumbar discectomy under local anesthesia. *J Med Invest* 61:264-269, 2014. <https://doi.org/10.2152/jmi.61.264>
30. Sanusi T, Davis J, Nicassio N, Malik I: Endoscopic lumbar discectomy under local anesthesia may be an alternative to microdiscectomy: A single centre's experience using the far lateral approach. *Clin Neurol Neurosurg* 139:324-327, 2015. <https://doi.org/10.1016/j.clineuro.2015.11.001>
31. Sencer A, Yorukoglu AG, Akcakaya MO, Aras Y, Aydoseli A, Boyali O, Sencan F, Sabanci PA, Gomleksiz C, Imer M, Kiris T, Heggul K, Unal OF, Izgi N, Canbolat AT: Fully endoscopic interlaminar and transforaminal lumbar discectomy: Short-term clinical results of 163 surgically treated patients. *World Neurosurg* 82:884-890, 2014. <https://doi.org/10.1016/j.wneu.2014.05.032>
32. Subramonian K, Muir G: The "learning curve": What is it, how do we measure it and can we influence it? *BJU Int* 93:1173-1174, 2004. <https://doi.org/10.1111/j.1464-410X.2004.04891.x>
33. Tsou PM, Yeung AT: Transforaminal endoscopic decompression for radiculopathy secondary to intracanal noncontained lumbar disc herniations: Outcome and technique. *Spine J* 2:41-48, 2002. [https://doi.org/10.1016/S1529-9430\(01\)00153-X](https://doi.org/10.1016/S1529-9430(01)00153-X)
34. Wang B, Lü G, Patel AA, Ren P, Cheng I: An evaluation of the learning curve for a complex surgical technique: The full endoscopic interlaminar approach for lumbar disc herniations. *Spine J* 11:122-130, 2011. <https://doi.org/10.1016/j.spinee.2010.12.006>
35. Wu XB, Fan GX, Gu X, Shen TG, Guan XF, Hu AN, Zhang HL, He SS: Learning curves of percutaneous endoscopic lumbar discectomy in transforaminal approach at the L4/5 and L5/S1 levels: A comparative study. *J Zhejiang Univ Sci B* 17:553-560, 2016. <https://doi.org/10.1631/jzus.B1600002>
36. Yue JJ, Long W: Full endoscopic spinal surgery techniques: Advancements, indications, and outcomes. *Int J Spine Surg* 9:17, 2017. <https://doi.org/10.14444/2017>