



# Computed Tomography-Based Occipital Condyle Morphometric Analysis in the Turkish Population: A Trajectory Analysis for Optimal Screw Selection

Kemal PAKSOY<sup>1</sup>, Idris AVCI<sup>1</sup>, Gulsah OZTURK<sup>2</sup>, Taha ALBAS<sup>3</sup>

<sup>1</sup>Memorial Hospital, Spine Center, Istanbul, Türkiye

<sup>2</sup>Memorial Hospital, Department of Neurosurgery, Istanbul, Türkiye

<sup>3</sup>University of Health Sciences, Bakirkoy Mazhar Osman Mental Health Training and Research Hospital, Department of Neurosurgery, Istanbul, Türkiye

Corresponding author: Idris AVCI ✉ mail.idrisavci@gmail.com

## ABSTRACT

**AIM:** To provide a comprehensive analysis for accurate screw size selection and insertion angle during surgical procedures.

**MATERIAL and METHODS:** In this retrospective study, a total of 120 patients participated, resulting in the analysis of 240 occipital condyles using coronal, sagittal, and axial planes on CT scans. Statistical evaluation was performed using the Wilcoxon rank-sum test, with  $p < 0.05$  considered statistically significant.

**RESULTS:** The mean sagittal length and height were measured at  $17.2 \pm 1.7$  mm and  $9.1 \pm 1.5$  mm, respectively. The average condyle angle, a crucial factor for screw insertion, was assessed at  $38.0 \pm 5.5$  mm in length,  $19.6 \pm 2.6$  mm in width, and  $9.5 \pm 1.0$  mm in height. Condyle height in the anterior and posterior hypoglossal canals was measured at  $10.8 \pm 1.4$  mm and  $9.0 \pm 1.4$  mm, respectively. Screw angle and condyle width were statistically smaller in females compared to the male population.

**CONCLUSION:** The OC is a significant anatomical structure in the craniocervical junction, playing a crucial role in stability. The obtained morphological values are applicable to the Turkish population and offer statistically significant findings for preoperative planning involving occipital condyle screw instrumentation.

**KEYWORDS:** Occipital condyle, Occiput-cervical junction, Morphometric trajectory analysis, Occipital condyle screws

**ABBREVIATIONS:** CT: Computed tomography, HGCH: Hypoglossal canal height, OC: Occipital condyle, OCA: Occipital condyle angle, OCH: Occipital condyle height, OCL: Occipital condyle length, OCW: Occipital condyle width, L: left, R: right

## INTRODUCTION

Occipital condyles (OC) are the undersurface protrusions of the occipital bone that act as articulating elements with the atlas. The foramen magnum is located between both condyles (20). This articulation enables the head flexion and extension movements (16). The dimensions and morphology of the OC play a pivotal role in the movement of the atlanto-occipital junction movement, functioning as a

complex dynamic joint. Restoring the integrity and stability of this region is crucial, as pathologies such as trauma, tumors, rheumatoid arthritis, infections, and congenital malformations can lead to occiputocervical instability (22). The OC instrumentation technique was initially described by Uribe et al. in 2008 and has become the gold standard in cases unsuitable for traditional instrumentation techniques (24). The stability of the occiputocervical junction relies heavily on the morphological parameters of the OC (24). The surgeon

must analyze the OC structure before initiating surgery (28). Numerous cadaveric and radiological studies have investigated OC anatomy (1,9,10,13,23). This study aimed to evaluate the morphology of the Turkish population and provide statistical standardization for length, width, and angle based on age and gender. This data is expected to offer valuable insights for accurate screw selection in OC instrumentation, which remains unreported in the literature.

## ■ MATERIAL and METHODS

This retrospective study was conducted at our clinic from January 2021 to March 2022 following the standards of the Helsinki Declaration (Memorial Bahçelievler Hospital, Date: 27.07.2022, No: 46). This study included all cervical computed tomography (CT) scans obtained at our institution during this period using 1.25 mm thin-sectioned axial, sagittal and coronal planes. Siemens Somatom Drive 256 (Siemens, Germany) was used to acquire the scans. This study excluded images displaying fractures, craniocervical anomalies, neoplastic diseases or infections. The analysis included 120 patients and 240 condyles, categorized by gender and age. We recorded the condyle length, height, width, medial angle and distance to the hypoglossal canal using the Surgimap software (Globus Medical, Methuen/MA, USA). Two separate spinal surgeons conducted all assessments, and the results were concealed to mitigate bias. The initial assessment randomly selected 50 cases for re-evaluation.

### Radiological OC assessment

1. OC length (OCL): the distance between the anterior and posterior medial points on the axial planes (Figure 1A).
2. OC width (OCW): the distance between the medial and lateral borders on the axial planes (Figure 1B).
3. OC angle (OCA): the angle from the longitudinal axis to the central vertical line on the axial planes (Figure 1C).
4. OC height (OCH): A vertical line from the hypoglossal canal to the condylar cartilage is drawn and measured on coronal planes (Figure 1D).
5. Hypoglossal canal height (HGCH): the distance between the inferior border of the condyle to the hypoglossal canal base (Figure 1E).

### Criteria for choosing the most suitable trajectory

1. The posterior wall of the outer cortex of the condyle and the anterior outer cortex were measured in the axial planes to determine the screw length.
2. A line was drawn from the median part of the hypoglossal canal junction on the sagittal plane, and the atlanto-occipital condyle joints were used to determine the craniocaudal trajectory. Screw entrance points were set 2 mm away from the C0–C1 joints with a 5° craniocaudal angle.
3. The angle from the line measured the condylar length to the midline was used to set the medial trajectory.

4. The screw size was set as 3.5 for condyles with a height of > 6.5 mm and a length of 8 mm (15).
5. The occipital condyle screw insertion points were 4–5 mm laterally from the condyle and the posteromedial border of the occipital bone (28).

### Statistical Analysis

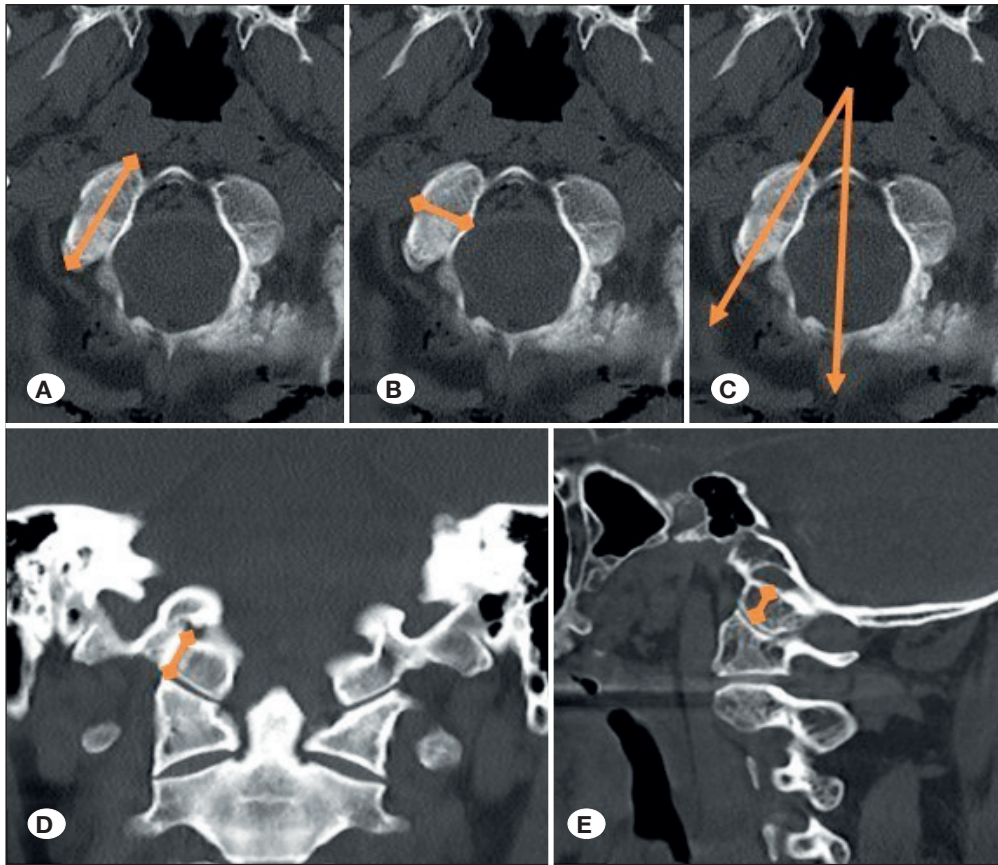
Categorical variables were presented as percentages and continuous variables were expressed as mean  $\pm$  standard deviation. Histograms and Kolmogorov–Smirnov test were used to assess the normal distribution compliance of the numerical values. Paired sample t-tests were used to compare measurements between the right and left sides. Pearson's correlation test was used to evaluate the strength of the linear relationship between variables. Student's t-test was used to compare means. We considered an overall p-value of <0.05 as statistically significant. The IBM Statistical Package for the Social Science Statistics (SPSS) for Windows, version 26 (IBM Corp., Armonk, N.Y., USA) was used for all statistical analyses.

## ■ RESULTS

This study included 120 patients (57 females [47.5%] and 63 males [52.5%]). The mean age was  $47.3 \pm 20.5$  years, ranging from 11 to 90 years. The measurements of OCL, OCW, OCA, OCH, and HGCH were  $22.2 \pm 2.2$  mm,  $10.3 \pm 1.2$  mm,  $34.5 \pm 4.2^\circ$ ,  $9.3 \pm 1.1$  mm, and  $9.1 \pm 1.3$  mm for the right side and  $22.1 \pm 1.9$  mm,  $10.2 \pm 1.1$  mm,  $34.9 \pm 4.1^\circ$ ,  $9.4 \pm 1.1$  mm, and  $8.9 \pm 1.3$  mm for the left side, respectively. No statistically significant differences were found in OC diameter between age and gender on both the right and left sides (Table I). Age correlation with any other parameters was not observed. Positive correlations were noted among combinations of ROCL, ROCW, ROCH, RHGCH, LOCL, LOCW, LOCH, and LHGCH. ROCA and LOCA demonstrated a positive connection, which did not correlate with any other parameter combination. Table II shows the association between the variables. Table 3 presents the gender-based variable comparisons. Parameters including ROCL, ROCW, ROCH, RHGCH, LOCL, LOCW, and LHGCH were statistically higher in males than in females ( $p < 0.001$ ,  $p = 0.006$ ,  $p = 0.007$ ,  $p = 0.009$ ,  $p < 0.001$ ,  $p = 0.025$ , and  $p = 0.012$ , respectively). LOCH variables were higher in males although not statistically significant ( $p = 0.063$ ).

## ■ DISCUSSION

The OC plays a pivotal role in the craniovertebral junction, which is located between the occipital bone and the atlas, and ensures craniovertebral junction stability (7). However, stabilizing the complex OC is difficult because of its proximity to vital structures. The OC is positioned anterolaterally to the foramen magnum. The lateral atlanto-occipital ligament and lateral rectus capitis muscle separate it from the jugular foramen, which houses the internal jugular vein and cranial nerves IX, X, and XI (17). OC stabilization uses two primary techniques. The La Marca technique involves setting the condylar entry point 3 mm below the condylar emissary vein foramen, using a trajectory of  $30^\circ$  caudally and  $10^\circ$  medially (13). Conversely, the Uribe technique, establishes the entry



**Figure 1:** CT-based morphological characteristics of the occipital condyle (OC). **A)** OC length (OCL), **B)** OC width (OCW), **C)** OC angle (OCA), **D)** OC height (OCH), **E)** hypoglossal canal height (HGCH).

**Table I:** Statistical Data of Right Occipital Condyle and Left Occipital Condyle

	Mean	SD	p-value
ROCL	22.2	2.2	0.201
LOCL	22.1	1.9	
ROCW	10.3	1.2	<b>0.049</b>
LOCW	10.2	1.1	
ROCA	34.5	4.2	0.060
LOCA	34.9	4.1	
ROCH	9.3	1.1	0.389
LOCH	9.4	1.1	
RHGCH	9.1	1.3	0.132
LHGCH	8.9	1.3	

**SD:** Standard deviation, **ROCL:** Right Occipital Condyle Length (mm), **ROCW:** Right Occipital Condyle Width (mm), **ROCA:** Right Occipital Condyle Angle (degrees), **ROCH:** Right Occipital Condyle Height (mm), **RHGCH:** Right Hypoglossal Channel Height (mm), **LOCL:** Left Occipital Condyle Length (mm), **LOCW:** Left Occipital Condyle Width (mm), **LOCA:** Left Occipital Condyle Angle (degrees), **LOCH:** Left Occipital Condyle Height (mm), **LHGCH:** Left Hypoglossal Channel Height (mm).

point 5 mm lateral to the posteromedial corner of the OC's posterior surface midpoint, with a trajectory of 15° medially and 5° cranially (25). Understanding the morphological structures is crucial for surgical planning in this area. Previous clinical and anatomical studies have emphasized the wide range of variations in OC diameters and phenotypic characteristics (2,4,16). Bernstein et al. conducted a study involving 500 CT scans and revealed that mean OC measurements, including length, width, height, and sagittal angle were  $18.7 \pm 1.7$  mm,  $10.5 \pm 1.2$  mm,  $11.4 \pm 1.3$  mm, and  $23 \pm 3.5^\circ$  for the right side and  $18.6 \pm 1.7$  mm,  $10.4 \pm 1.1$  mm,  $11.3 \pm 1.3$  mm, and  $24 \pm 3.5^\circ$  for the left side, respectively. Notably, the right and left OC measurements demonstrated no statistically significant difference, consistent with our findings (3). Kumar and Nagar revealed statistically higher OCL and OCW in males (12), which is similar to other publications, including ours (5,28). Gumussoy and Duman revealed no statistically significant changes between morphometric parameters and age (8). Variations in OC diameter have been observed across different ethnic groups. In particular, Saluja et al. reported an OCL of  $22.75 \pm 2.90$  mm and OCW of  $12.97 \pm 1.53$  mm in the Indian population (23). Zhou et al. documented OCL, OCW, and OCH as  $22.2 \pm 1.7$  mm,  $12.1 \pm 1$  mm, and  $9.4 \pm 1.5$  mm in the Chinese population (28). El-Gaidi et al. recorded measurements of  $24.2 \pm 3.6$  mm,  $14.2 \pm 1.9$  mm, and  $10.7 \pm 2$  mm in the Egyptian population, and Ramos-Davila et al. revealed 20.58 mm, 9.42 mm, and 9.02 mm in the Mexican population (6,21). Our study's OCL and OCH findings paralleled those of the Chinese

**Table II:** Correlations Between the Variables

	Age	ROCL	ROCW	ROCA	ROCH	RHGCH	LOCL	LOCW	LOCA	LOCH
Age	1									
ROCL	-0.081	1								
ROCW	-0.063	.362**	1							
ROCA	-0.012	0.098	-0.013	1						
ROCH	-0.070	.402**	.415**	0.035	1					
RHGCH	-0.039	.356**	.321**	0.027	.663**	1				
LOCL	-0.047	.884**	.338**	-0.010	.297**	.303**	1			
LOCW	-0.082	.275**	.827**	-0.021	.328**	.238**	.324**	1		
LOCA	0.031	0.127	0.040	.734**	0.052	0.085	0.081	0.117	1	
LOCH	-0.072	.324**	.360**	0.000	.905**	.716**	.249**	.333**	0.033	1
LHGCH	0.008	.291**	.289**	-0.023	.639**	.944**	.248**	.232*	0.006	.706**

**ROCL:** Right Occipital Condyle Length (mm), **ROCW:** Right Occipital Condyle Width (mm), **ROCA:** Right Occipital Condyle Angle (degrees), **ROCH:** Right Occipital Condyle Height (mm), **RHGCH:** Right Hypoglossal Channel Height (mm), **LOCL:** Left Occipital Condyle Length (mm), **LOCW:** Left Occipital Condyle Width (mm), **LOCA:** Left Occipital Condyle Angle (degrees), **LOCH:** Left Occipital Condyle Height (mm), **LHGCH:** Left Hypoglossal Channel Height (mm) (\* p<0.05, \*\* p<0.01).

**Table III:** Comparison of the Variables Between Genders

	Woman, n=57		Men, n=63		p-value
	Mean	SD	Mean	SD	
Age	48.9	20.7	45.8	20.4	0.405
ROCL	21.2	1.4	23.1	2.3	<0.001
ROCW	10.0	1.0	10.6	1.2	0.006
ROCA	34.3	4.2	34.6	4.1	0.737
ROCH	9.0	0.9	9.6	1.2	0.007
RHGCH	8.7	1.2	9.4	1.4	0.009
LOCL	21.3	1.3	22.9	2.1	<0.001
LOCW	9.9	0.9	10.4	1.2	0.025
LOCA	35.3	3.9	34.7	4.2	0.448
LOCH	9.1	1.0	9.5	1.2	0.063
LHGCH	8.7	1.2	9.3	1.4	0.012

**ROCL:** Right Occipital Condyle Length (mm), **ROCW:** Right Occipital Condyle Width (mm), **ROCA:** Right Occipital Condyle Angle (degrees), **ROCH:** Right Occipital Condyle Height (mm), **RHGCH:** Right Hypoglossal Channel Height (mm), **LOCL:** Left Occipital Condyle Length (mm), **LOCW:** Left Occipital Condyle Width (mm), **LOCA:** Left Occipital Condyle Angle (degrees), **LOCH:** Left Occipital Condyle Height (mm), **LHGCH:** Left Hypoglossal Channel Height (mm).

and Indian populations, although OCW was narrower in the Turkish population. Additionally, OC parameters in the Turkish population were lower than those in Egypt but higher than those in Mexico. In previous studies, Özer et al. assessed OC morphological in 144 cadavers, and reported measurements of OCL, OCW, and sagittal angles as 23.9 ± 3.4 mm (right),

24 ± 3.3 mm (left), 11.9 ± 2.3 mm (right), 10.7 ± 2.3 mm (left), 32.9 ± 7.6° (right), and 38.2 ± 7.3° (left) (19). Naderi et al. and Kızıllkanat et al. also conducted OC morphology studies on cadavers (18,11). In contrast, our study used CT findings to assess parameters, with distinct age groups and gender specifications separated. Notably, our OCL and OCW findings

were lower than those of other Turkish studies. Based on our findings, we propose that the Uribe technique is the most suitable approach for the Turkish population. Setting the entrance point 5 mm lateral to the foramen magnum on axial planes and 2 mm rostrally from the atlanto-axial joint, with a screw length of 20-24 mm, width of 3.5 mm, and a trajectory angle of 15° medially and 5° cranially, would align well with the anatomical morphology of the Turkish population (14,25,26).

Our study had limitations. All measurements were conducted within the same institution, which potentially affects the homogeneity across the entire Turkish population. Istanbul is a diverse city that represents various immigrants from across the country, but it might not fully represent the entire population. Furthermore, this study only included participants without trauma or congenital abnormalities, which potentially limits the applicability of the parameter distributions to individuals with morphological OC changes due to other pathologies. Nevertheless, we consider our findings as a valuable benchmark for future studies on OC and craniocervical junctions, which provides comprehensive insights into the morphological OC characteristics of the Turkish population.

## CONCLUSION

Our research emphasizes the significance of OC morphological parameters for the meticulous planning of craniocervical junction surgeries in the Turkish population. These variables are of paramount importance in promoting the use of OC screws as a viable alternative to traditional surgical methods that involve the atlantoaxial junction. We propose that the Uribe technique stands as the most suitable approach for stabilizing the OC in Turkish patients after evaluating the morphological structure within the Turkish population.

### AUTHORSHIP CONTRIBUTION

Study conception and design: SS

Data collection: TA, GO

Analysis and interpretation of results: KP

Draft manuscript preparation: IA

Critical revision of the article: OY

All authors (KP, IA, GO, TA) reviewed the results and approved the final version of the manuscript.

## REFERENCES

1. Avci E, Dagtekin A, Ozturk AH, Kara E, Ozturk NC, Uluc K, Akture E, Baskaya M: Anatomical variations of the foramen magnum, occipital condyle and jugular tubercle. *Turk Neurosurg* 21:181-190, 2011. <https://doi.org/10.5137/1019-5149.JTN.3838-10.1>
2. Barut N, Kale A, Suslu HT, Ozturk A, Bozbuga M, Sahinoglu K: Evaluation of the bony landmarks in transcondylar approach. *Br J Neurosurg* 23:276-281, 2009. <https://doi.org/10.1080/02688690902814725>
3. Bernstein DN, Ikpeze TC, Foxx K, Omar A, Mesfin A: Anatomical parameters for occipital condyle screws: An analysis of 500 condyles using CT scans. *Global Spine J*:2192568220983311, 2021. <https://doi.org/10.1177/2192568220983311>
4. Das S, Suri R, Kapur V: Unusual occipital condyles of the skull: An osteological study with clinical implications. *Sao Paulo Med J* 124:278-279, 2006. <https://doi.org/10.1590/S1516-31802006000500009>
5. El-Barrany UM, Ghaleb SS, Ibrahim SF, Nouri M, Ali Hassan M: Sex prediction using foramen magnum and occipital condyles computed tomography measurements in Sudanese population. *Arab J Foren Sc Foren Med* 1:414-423, 2016. <https://doi.org/10.12816/0033135>
6. El-Gaidi MA, Eissa EM, El-Shaarawy EA: Free-hand placement of occipital condyle screws: A cadaveric study. *Eur Spine J* 23:2182-2188, 2014. <https://doi.org/10.1007/s00586-014-3488-3>
7. George JR, Francis T, Francis J, Samuel JE: Morphometric study of dry human occipital bone and its clinical relevance. *Int J Anat Res* 7:6230-6233, 2019. <https://doi.org/10.16965/ijar.2018.447>
8. Gumussoy I, Duman SB: Morphometric analysis of occipital condyles using alternative imaging technique. *Surg Radiol Anat* 42:161-169, 2020. <https://doi.org/10.1007/s00276-019-02344-2>
9. Kalthur SG, Padmashali S, Gupta C, Dsouza AS: Anatomic study of the occipital condyle and its surgical implications in transcondylar approach. *J Craniovertebr Junction Spine* 5:71-77, 2014. <https://doi.org/10.4103/0974-8237.139201>
10. Kavitha S, Chandrasekaran S, Anand A, Shanthi KC: Morphometric study of occipital condyles in adult human skulls. *Int J Curr Res Rev* 5:31-34, 2013
11. Kizilkanat ED, Boyan N, Soames R, Oguz O: Morphometry of the hypoglossal canal, occipital condyle, and foramen magnum. *Neurosurgery Quarterly* 16:121-125, 2006. <https://doi.org/10.1097/01.wnq.0000214018.49915.49>
12. Kumar A, Nagar M: Human adult occipital condyles: A morphometric analysis. *JMHS* 3:112-116, 2014
13. La Marca F, Zubay G, Morrison T, Karahalios D: Cadaveric study for placement of occipital condyle screws: Techniques and effects on surrounding anatomic structures. *J Neurosurg Spine* 9:347-353, 2008. <https://doi.org/10.3171/SPI.2008.9.10.347>
14. Le TV, Dakwar E, Hann S, Effio E, Baaj AA, Martinez C, Vale FL, Uribe JS: Computed tomography based morphometric analysis of the human occipital condyle for occipital condyle-cervical fusion. *J Neurosurg Spine* 15:328-331, 2011. <https://doi.org/10.3171/2011.5.SPINE10778>
15. Lin SL, Xia DD, Chen W, Li Y, Shen ZH, Wang XY, Xu HZ, Chi YL: Computed tomographic morphometric analysis of the pediatric occipital condyle for occipital condyle screw placement. *Spine (Phila Pa 1976)* 39:E147-E152, 2014. <https://doi.org/10.1097/BRS.0000000000000105>
16. Lopez AJ, Scheer JK, Leibl KE, Smith ZA, Dlouhy BJ, Dahdeleh NS: Anatomy and biomechanics of the craniocervical junction. *Neurosurg Focus* 38:1-8, 2015. <https://doi.org/10.3171/2015.1.FOCUS14807>
17. Muthukumar N, Swaminathan R, Venkatesh G, Bhanumathy SP: A morphometric analysis of the foramen magnum region as it relates to the transcondylar approach. *Acta Neurochir* 147:889-895, 2005. <https://doi.org/10.1007/s00701-005-0555-x>

18. Naderi S, Korman E, Citak G, Guvencer M, Arman C, Senoglu M, Tetik S, Arda MN: Morphometric analysis of human occipital condyle. *Clin Neurol Neurosurg* 107:191-199, 2005. <https://doi.org/10.1016/j.clineuro.2004.07.014>
19. Ozer MA, Celik S, Govsa F, Ulusoy MO: Anatomical determination of a safe entry point for occipital condyle screw using three-dimensional landmarks. *Eur Spine J* 20:1510-1517, 2011. <https://doi.org/10.1007/s00586-011-1765-y>
20. Parvindokht B, Reza DM, Saeid B: Morphometric analysis of hypoglossal canal of the occipital bone in Iranian dry skulls. *J Craniovertebr Junction Spine* 6:111-114, 2015. <https://doi.org/10.4103/0974-8237.161591>
21. Ramos-Dávila EM, Meléndez-Flores JD, Álvarez-Pérez R, Barrera-Flores FJ, Martínez Cobos MC, Pinales-Razo R, Quiroga-Garza A, Zarate-Garza P, Sanchez-Gomez A, Guzman-Lopez S, Elizondo-Omaña RE: Occipital condyle screw fixation viability according to age and gender anatomy: A computed tomography-based analysis. *Clin Neurol Neurosurg* 200:106358, 2021. <https://doi.org/10.1016/j.clineuro.2020.106358>
22. Rassi MS, Oliveira JG, Borba LAB: The transcondylar approach to craniocervical meningiomas. *Neurosurg Focus* 43 VideoSuppl 2:V11, 2017. <https://doi.org/10.3171/2017.10.FocusVid.17366>
23. Saluja S, Das SS, Vasudeva N: Morphometric study of the occipital condyle and its surgical importance. *J Clin Diagn Res* 10:AC01-AC04, 2016. <https://doi.org/10.7860/JCDR/2016/23278.8800>
24. Smith P, Linscott LL, Vadivelu S, Zhang B, Leach JL: Normal development and measurements of the occipital condyle-C1 interval in children and young adults. *AJNR Am J Neuroradiol* 37:952-957, 2016. <https://doi.org/10.3174/ajnr.A4543>
25. Uribe, JS, Ramos, E, Vale, F: Feasibility of occipital condyle screw placement for occipitocervical fixation: A cadaveric study and description of a novel technique. *J Spinal Disord Tech* 21:540-546, 2008. <https://doi.org/10.1097/BSD.0b013e31816d655e>
26. Uribe JS, Ramos E, Youssef AS, Levine N, Turner AWL, Johnson WM, Vale FL: Craniocervical fixation with occipital condyle screws: Biomechanical analysis of a novel technique. *Spine* 35:931-938, 2010. <https://doi.org/10.1097/BRS.0b013e3181c16f9a>
27. Winegar CD, Lawrence JP, Friel BC, Fernandez C, Hong J, Maltenfort M, Anderson PA, Vaccaro AR: A systematic review of occipital cervical fusion: Techniques and outcomes. *J Neurosurg Spine* 13:5-16, 2010. <https://doi.org/10.3171/2010.3.SPINE08143>
28. Zhou J, Espinoza Orias AA, Kang X, He J, Zhang Z, Inoue N, An HS: CT-based morphometric analysis of the occipital condyle: Focus on occipital condyle screw insertion. *J Neurosurg Spine* 25:572-579, 2016. <https://doi.org/10.3171/2016.4.SPINE151431>
29. Zirahei JV, Amaza DS, Otashu KF, Nkimanya F, Gadzama NM, Mailabari HY: Sex differences in occipital condyles in Maiduguri, Northeastern Nigeria using computed tomographic scan images. *Kanem J of Med Sci* 12:73-77, 2018