



Contribution of Multilevel Transforminal Lumbar Interbody Fusion Surgery to Restoration of Lumbar Lordosis in Patients with Degenerative Spine: Comparison of Long and Short Level Fusion

Mustafa Abdullah OZDEMIR¹, Sahin KARALAR², Murat KORKMAZ², Serkan BAYRAM², Mehmet EKINCI³, Tuna PEHLIVANOGLU⁴, Turgut AKGUL²

¹Kahramanmaraş Sutcu Imam University, Faculty of Medicine, Department of Orthopaedics and Traumatology, Kahramanmaraş, Turkey

²Istanbul University, Istanbul Faculty of Medicine, Department of Orthopaedics and Traumatology, Istanbul, Turkey

³Haseki Education and Research Hospital, Department of Orthopaedics and Traumatology, Istanbul, Turkey

⁴Yeni Yuzyl University, Faculty of Medicine, Department of Orthopaedics and Traumatology, Istanbul, Turkey

Corresponding author: Mustafa Abdullah OZDEMIR ✉ drmustafaazdemir46@gmail.com

ABSTRACT

AIM: To investigate the effect of multilevel transforminal lumbar interbody fusion (TLIF) procedures in lumbar degenerative spine conditions on the restoration of lumbar lordosis (LL) in patients with short- and long-level fusion, and to examine the associated radiological results.

MATERIAL and METHODS: This retrospective study reviewed patients with degenerative spinal diseases who underwent lumbar fusion using a multilevel TLIF procedure. Patients with three or fewer segments involved in fusion were assigned to the short-level fusion group and those with more than three segments involved in fusion were assigned to the long-level fusion group. The anteroposterior and lateral spine radiographs of the patients were used to measure LL, distal lumbar lordosis and radiological parameters.

RESULTS: The study included 47 patients who met the inclusion criteria, with a mean age of 60.4 ± 12.2 years. The mean follow-up time of our patients was 18.3 ± 11 months. Thirty-five (74.5%) patients were women and 12 (25.5%) were men. Overall, 12 patients underwent 3-level and 35 patients underwent 2-level TLIF. Long-level fusion was performed in 24 patients and short-level fusion was performed in 23 patients.

CONCLUSION: Multilevel TLIF can be used to correct spinopelvic alignment when applied with the appropriate indications and techniques in patients with degenerative spinal disorders. Multilevel TLIF is associated with substantial improvements in LL, distal lumbar lordosis, and SVA (sagittal vertical axis). It also helps to correct the correlation between PI and LL.

KEYWORDS: Multilevel TLIF, Sagittal parameters, Lumbar lordosis

INTRODUCTION

Although the lumbar interbody fusion technique was first described more than 70 years ago, longer life expectancy, innovations in implant design, and the

desire for better quality of life have paved the way for the increased frequency of fusion surgery (10).

Loss of lumbar lordosis (LL) occurs due to reversal of the extensor to flexor muscle strength ratio in lumbar degener-

Mustafa Abdullah OZDEMIR  : 0000-0002-8281-3528
Sahin KARALAR  : 0000-0002-4386-9107
Murat KORKMAZ  : 0000-0003-2809-6721

Serkan BAYRAM  : 0000-0001-7651-1200
Mehmet EKINCI  : 0000-0001-5251-8280
Tuna PEHLIVANOGLU  : 0000-0001-8886-7538

Turgut AKGUL  : 0000-0002-0704-3797

ative diseases (15,39). Therefore, it is particularly important to examine the sagittal balance parameters prior to surgical treatment in patients considering fusion therapy. Biomechanical studies have reported that procedures that maintain disk height and improve LL contribute to fusion by ensuring balance of force (7,9). Owing to the transforaminal lumbar interbody fusion (TLIF) technique, sagittal alignment can be restored by achieving intervertebral fusion which can be done by maintaining disk height and foraminal area (30).

The maintenance and restoration of sagittal balance can directly affect surgical outcomes and quality of life, making it a popular topic in the field of spinal surgery. Physiological LL is important for maintaining sagittal balance, and sagittal balance impairment is closely associated with chronic low back pain and disability in patients (6). Previous studies have reported that two-thirds of total LL occur in the L4–S1 segments (2,3). Therefore, it is not surprising that the majority of spinal surgeries involve these segments (38).

The objective of surgical treatment in patients with degenerative spinal conditions is to decompress neural structures and achieve a stable spine with coronal and sagittal balance (4). Restoring balance may require surgical interventions, including fusion, decompression, and osteotomy (34). However, there is no definite consensus in the literature regarding the optimal number of fusion levels (34).

The relationship between pelvic incidence (PI) and LL is one of the primary determinative factors in the assessment of sagittal balance in the lumbar region, and is associated with positive functional outcomes (36). A difference of $>10^\circ$ between PI and LL is indicative of negative sagittal balance (35). This difference is also considered one of the main causes of postoperative chronic low back pain (24).

Only a few studies have examined the effect of multilevel TLIF procedures on overall sagittal balance and its contribution to the restoration of LL. The present study, thus, aimed to investigate the effect of multilevel TLIF procedures in lumbar degenerative spine conditions on the restoration of LL in patients with short- and long-level fusion and to examine the associated radiological results.

■ MATERIAL and METHODS

Study Design

The data of patients diagnosed with degenerative spine disease who underwent TLIF at the Orthopedics and Traumatology Department of the Istanbul Faculty of Medicine, Istanbul University, between 2016 and 2021 were retrospectively reviewed (08.03.2022-2022/3). The medical records of 145 patients were retrieved from the archives of our clinic, and 68 of them were identified as having undergone multiple-level TLIF. Of these 68 patients, 47 were included in the study as they had been regularly followed up at the outpatient department for at least 1 year, and their radiological data were accessible. Patient characteristics, including age, sex, surgical procedure, and postoperative follow-up period, were retrieved from medical records. The sagittal balance parameters of these patients

were measured and recorded preoperatively and at the last follow-up. Patients meeting the following criteria were excluded: Those who had undergone single-level TLIF; neuromuscular and inflammatory comorbidities, and had inadequate follow-up duration.

Patients undergoing 3 level fusion or less were assigned to the short-level fusion group, whereas those undergoing more than 3 level fusion were assigned to the long-level fusion group, which is in line with the literature (26,34). Short-level fusion was applied for patients with nerve compression and degeneration only in the upper and lower segments, whereas long-level fusion was applied for patients with multisegmental nerve compression, degeneration, and instability (Figure 1–4).

Surgical Procedure and Follow-Up

Multilevel TLIF was performed by a senior surgeon and their team using an interbody cage and allograft by means of multi-axis pedicle screws and posterior fixation techniques, and followed the same protocol in each case. The cage was inserted in the correct position via unilateral facetectomy and partial laminectomy using the TLIF method. None of the patients underwent osteotomy. The cage was oriented from the front to the back of all the patients. Postoperative corsets were not used, and patients were mobilized early. These patients were examined clinically and radiologically at the outpatient clinic at postoperative weeks 1, 6, and 12. Patients without complaints were requested to attend follow-up visits every 6 months.

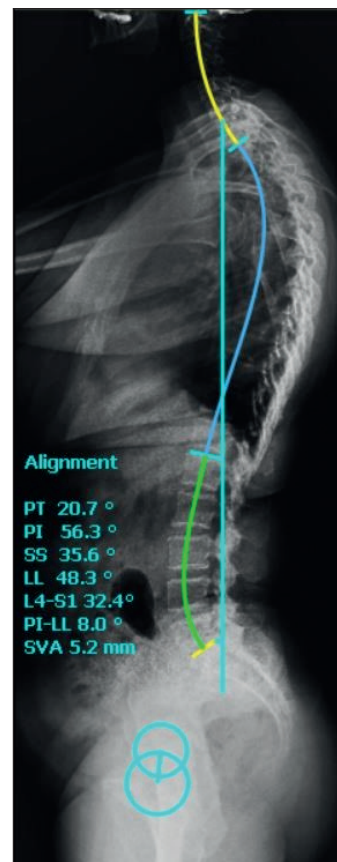


Figure 1: Preoperative lateral X-ray of the patient who underwent short-level fusion.

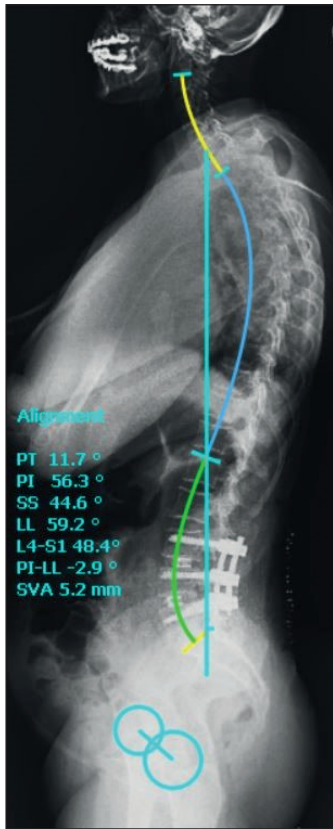


Figure 2: Postoperative lateral X-ray of the patient who underwent short-level fusion.

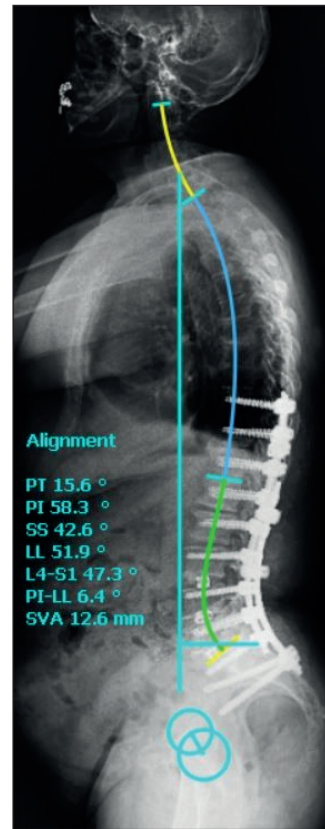


Figure 4: Postoperative lateral X-ray of the patient who underwent long-level fusion.

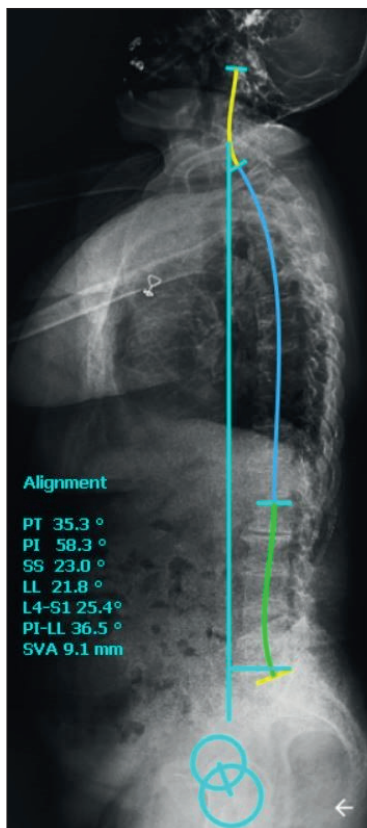


Figure 3: Preoperative lateral X-ray of the patient who underwent long-level fusion.

Statistical Analyses

IBM Statistical Package for the Social Sciences (SPSS) for Windows 25.0 was used for the analysis of the study data. Descriptive statistics of the minimum, maximum, and median values were used to analyze the data. For quantitative variables, the Wilcoxon or paired t-test was used to test whether the two dependent measurements differed, and the Mann-Whitney U or Student's t-test was used to test whether the two independent groups differed by the measurements. Pearson's chi-square test, Fisher-Freeman-Halton test, and Fisher's exact test were used to compare qualitative variables. Statistical significance was set at p value <0.05.

Radiological Evaluation

Radiographs were used to measure PI, LL, pelvic tilt (PT), sacral slope (SS), distal lumbar lordosis (DLL), thoracolumbar kyphosis (TLK), thoracic kyphosis (TK), T1 spinopelvic inclination (T1SPI), T9 spinopelvic inclination (T9SPI), and T1 pelvic angle (TPA).

The PI is the angle between the line perpendicular to the midpoint of the sacral-end upper plate and the axis of the femoral head to the midpoint. PT is the line connecting the vertical line drawn from the femoral head axis and the midpoint of the sacral-end upper plate from the femoral head axis. The SS is the angle between the line parallel to the last upper sacral plate and the horizontal line drawn from the last upper sacral plate midpoint. LL is the Cobb angle between the L1

vertebral upper endplate and S1 vertebra upper endplate, DLL is the Cobb angle between the L4 vertebra upper endplate and S1 vertebra upper endplate, and TLK is the Cobb angle between the upper endplate of the T10 vertebra and the lower endplate of the L2 vertebra. TK is the Cobb angle between the T4 vertebra upper endplate and T12 vertebra lower endplate. The T1SPI is the angle between the line drawn from the center of the T1 vertebra to the femoral head axis and the vertical plumb line. The T9SPI is the angle between the line drawn from the center of the T9 vertebra to the femoral head axis and the vertical plumb line. The TPA is the angle between the line drawn from the femoral head axis to the center of the T1 vertebra and the line drawn from the femoral head axis to the sacral-end upper plate. Sagittal balance (SB) is the distance from the vertical descending line at the center of the C7 vertebra to the posterior upper plate posterosuperior corner of the S1 vertebral body. The distance of this line from the S1 vertebral body to the final upper-plate posterosuperior corner, 2.5 cm anteriorly and posteriorly, was considered a neutral SB. A distance of >2.5 cm anteriorly was considered positive SB, and that posteriorly was considered negative SB. For PI-LL correlation, normal values between -10° and $+10^\circ$ were accepted. The patient, provided with the distance between these values, was categorized as unstable compared to patients outside of these values.

Radiographic examination was performed by two independent investigators using Surgimap spine imaging software.

RESULTS

The study included 47 patients who met the inclusion criteria, with a mean age of 60.4 ± 12.2 years. The mean follow-up time of our patients was 18.3 ± 11 months. Thirty-five (74.5%) patients were women and 12 (25.5%) were men. The TLIF cage was applied at 3 levels in 12 patients and at 2 levels in 35 patients. The age, sex, and follow-up duration by group are shown in Table I.

There was a significant difference in the postoperative LL, DLL, and TK measurements in both groups compared with the preoperative period.

There was no difference in the preoperative and postoperative T9SPI of the groups, but there was a significant increase in the postoperative T9SPI of those who underwent long-level fusion. The preoperative SVA was significantly higher in the

long-level fusion group than in the short-level fusion group. There was no difference in the postoperative SVA between the groups. The postoperative SVA significantly decreased in both groups. There were no statistical differences in the pre- and postoperative PT, PI, SS, TPA, and T1SPI between the groups (Table II).

There was a significant difference in the pre- and postoperative correlation between PI and LL in the long-level ($p < 0.05$) and short-level ($p < 0.05$) fusion groups; 33 (70.2%) patients showed no preoperative PI-LL correlation; however, 24 of these patients showed a postoperative correlation. Overall, 68.1% and 72.9% of the patients in the long- and short-level fusion groups, respectively, who showed no PI-LL correlation preoperatively, showed a correlation postoperatively. The statistical analyses of the preoperative and postoperative radiology measurements of the patients are presented in Table II.

Revision surgery was performed in 5 (20.8%) and 4 (17.3%) patients of the long- and short-level fusion groups, respectively, due to proximal junctional kyphosis (PJK) in the second year of follow-up.

DISCUSSION

The results of the present study indicate that multilevel TLIF may correct LL, DLL, and SVA in patients with long- and short-level fusion and contribute to the improvement of the PI-LL correlation.

There are few studies on multilevel TLIF in the literature. To our knowledge, this is the only study to compare long- and short-level fusions in multilevel TLIF surgery. Therefore, we believe that this study contributes to the literature.

TLIF has become the preferred interbody fusion technique because of its advantages over PLIF in terms of maintaining disk space height, less graft requirement, and lower risk of neurological and dural damage (25,30). Theoretically, TLIF contributes to the correction of LL (12). Additionally, studies have reported that TLIF combined with an appropriate procedure involving posterior instrumentation is effective in restoring global SB (14). Despite all its advantages, the success of TLIF depends on patient selection, correct indications, and appropriate surgical procedures. The present study is important because it reveals the benefits of multilevel

Table I: Age, Gender, and Follow-up Duration of Long- and Short-Level Fusion Groups

			Long-level fusion (n=4)	Short-level fusion (n=23)	X ² /Z	p
Gender	Male	n (%)	4 (16.7)	8 (34.8)	2.027 ^a	-0.193
	Female	n (%)	20 (83.3)	15 (65.2)		
Age (years)		Median (min-max)	65.50 (55-81)	64.00 (57-74)	-2.122 ^b	0.560
Follow-up duration	12-48 (months)	Median (min-max)	13.00 (6-53)	14.00 (6-48)	-0.897 ^b	0.460

^aChi-squared test; a: 0.05; *, difference by distribution between groups is statistically significant

^bMann-Whitney U test; a: 0.05; *, difference by distribution between groups is statistically significant.

Table II: Comparison of the Pre- and Postoperative Data of Patients in the Long- and Short-Level Fusion Groups

		Preoperative	Postoperative	Z ^a	p
		Median (min-max)	Median (min-max)		
PT	Long-level fusion (n=24)	20.55 (2.10-33.40)	22.00 (2.70-41.70)	-0.639	0.523
	Short-level fusion (n=23)	17.00 (5.40-39.80)	18.90 (8.00-35.00)	-0.745	0.456
Z ^b		-1.395	-0.788		
p		0.163	0.431		
PI	Long-level fusion (n=24)	53.70 (28.20-86.20)	51.25 (32.00-74.00)	-0.365	0.715
	Short-level fusion (n=23)	49.90 (32.60-85.00)	52.90 (39.00-81.00)	-0.639	0.523
Z ^b		-0.181	-0.713		
p		0.856	0.476		
SS	Long-level fusion (n=24)	32.00 (14.00-58.40)	29.50 (19.00-48.00)	-0.343	0.732
	Short-level fusion (n=23)	35.80 (17.00-74.00)	32.00 (22.00-55.90)	-0.035	0.972
Z ^b		-1.128	-1.373		
p		-0.259	0.170		
LL	Long-level fusion (n=24)	35.50 (1.00-75.90)	48.10 (31.10-57.10)	-1.372	0.020*
	Short-level fusion (n=23)	36.40 (9.00-73.60)	47.60 (18.00-82.80)	-1.932	0.018*
Z ^b		-1.064	-1.490		
p		0.287	-0.136		
DLL	Long-level fusion (n=24)	26.15 (8.70-49.70)	35.05 (17.20-52.70)	-1.856	0.027*
	Short-level fusion (n=23)	27.00 (5.00-62.00)	34.00 (13.00-62.70)	-0.852	0.038*
Z ^b		-0.490	-0.436		
p		0.624	0.663		
TLK	Long-level fusion (n=24)	13.40 (2.00-52.90)	13.50 (1.20-29.50)	-0.372	0.710
	Short-level fusion (n=23)	5.00 (0.60-41.00)	5.00 (0.10-29.00)	-0.906	0.365
Z ^b		-2.631	-2.087		
p		0.009*	0.037*		
TK	Long-level fusion (n=24)	30.00 (1.80-50.80)	36.50 (15.90-47.60)	-2.057	0.040*
	Short-level fusion (n=23)	31.00 (13.00-48.30)	33.90 (11.50-63.30)	-2.173	0.030*
Z ^b		-0.468	-0.245		
p		0.640	0.807		
T1SPI	Long-level fusion (n=24)	3.95 (0.60-9.60)	3.85 (0.10-11.20)	-0.414	0.679
	Short-level fusion (n=23)	2.00 (0.20-11.20)	3.10 (0.00-8.00)	-0.335	0.738
Z ^b		-1.269	-1.001		
p		0.205	0.317		
T9SPI	Long-level fusion (n=24)	8.80 (0.60-20.10)	10.50 (3.40-19.40)	-2.129	0.033*
	Short-level fusion (n=23)	8.70 (2.10-16.40)	11.00 (3.70-17.00)	-1.906	0.057
Z ^b		-0.149	-0.351		
p		0.882	0.725		
TPA	Long-level fusion (n=24)	20.65 (0.00-39.10)	18.95 (7.50-37.00)	-0.730	0.465
	Short-level fusion (n=23)	15.00 (2.80-32.00)	16.00 (9.60-36.90)	-2.738	0.493
Z ^b		-1.341	-0.490		
p		0.180	0.624		
SVA (mm)	Long-level fusion (n=24)	61.00 (5.00-152.70)	15.65 (0.70-110.30)	-2.229	0.026*
	Short-level fusion (n=23)	35.00 (1.70-112.60)	13.00 (2.00-82.50)	-1.004	0.037*
Z ^b		-2.139	-0.553		
p		0.032*	0.580		

^aWilcoxon test; a: 0.05; *, statistically significant difference. ^bMann-Whitney U test; a: 0.05; *, statistically significant difference

TLIF conducted by the same surgical team in the restoration of LL.

Restoration of LL is closely related to patient satisfaction (1). Doherty described symptomatic forward inclination of the trunk due to the loss of LL in patients with thoracolumbar scoliosis in 1973 (8). Loss of LL in a degenerative spine alters the center of gravity and triggers compensatory mechanisms including knee flexion, hip extension, and segment hyperextension (1). Such compensatory mechanisms may be associated with adverse effects including chronic mechanical low back pain, disability, and fatigue (1,2). Furthermore, biomechanical and clinical studies have reported that the restoration of LL was associated with reduction in adjacent segment degeneration (5,18,21). Previous studies have indicated an expected increase in LL after single-level TLIF. Hsieh et al. suggested that TLIF reduces LL (13). Other studies have reported an increase in LL between 1.5° and 17° (6,14,16,19). Jagannathan et al. investigated the effect of multi- and single-level TLIF on LL and revealed that the average improvement in LL in patients undergoing multilevel and single-level TLIF was 27.3° and 17.4°, respectively (14). These differences among the results can be accounted for by the bilateral facetectomy, higher number of grafts used, and cage position, according to the surgeon's discretion. Standard TLIF was performed in the present study. The fusion was achieved using unilateral facetectomy and multiaxis pedicle screws. Cages with a lordotic angle of 5° and allografts were used in all the patients. The results of the present study indicate an increase in LL of 12.60° and 11.20° in the long- and short-level fusion groups, respectively. This increase in both groups was significant than the preoperative values.

Studies, which investigated the relationship between the PI and LL, reported that increases in PI affect the proximal LL, and distal lordosis (DLL) remains constant between L4 and S1 levels (23,32). Another study classified the patients into two groups based on the relationship between PI and LL, and they showed that DLL was significantly higher in patients with normal limits of PI-LL relationship than in patients with impaired SB (33). A general overview of these previous studies suggests that the loss of LL in degenerative diseases mainly originates in the L4-S1 (DLL) region (32). Nevertheless, it was reported that failure to correct the DLL was associated with PJK (22). As a result, restoration of the DLL is important for ensuring the normal relationship between PI and LL, as well as for preventing PJK. According to the results of the present study, LL increased by 12.60° and 11.20° in the long- and short-level fusion groups, respectively, compared to the preoperative values. These results were statistically significant in both groups. According to the literature, a PI-LL correlation of $\pm 10^\circ$ is considered normal (27,37). Patients showing more than these values were considered to have no PI-LL correlation. Overall, 33 (70.2%) patients had no preoperative PI-LL correlation. Moreover, 24 of these patients had a postoperative PI-LL correlation. The rates of patients with no preoperative correlation but showing postoperative correlation in the long- and short-level fusion groups were 68.2% and 72.9%, respectively.

PJK was described by Glattes et al. (11), and was determined by measuring the final proximal sagittal Cobb angle (proximal junction angle) between the upper endplate of the most proximal instrumented vertebra in the sagittal plane and the upper endplate of the proximal vertebral levels (17). PJK is described as a proximal junctional angle $\geq 10^\circ$ with at least a 10° increase compared to the preoperative measurement (17). Previous studies reported that the incidence of PJK ranges from 17% to 61.7% (11,20,31). In the present study, revision surgery was performed in 5 (20.8%) patients in the long-level fusion group and in 4 (17.3%) patients in the short-level fusion groups due to PJK in the second year of follow-up.

Spinal deformities in adults are a prevalent challenge for spine surgeons. Patient satisfaction was higher in the long term in the group that underwent surgical treatment, as shown by a systematic study that compared the results of conservative and surgical treatments (29). A study published in 2014 investigated the efficacy of surgical treatment for correcting spinopelvic alignment (28). There was no restoration of the sagittal parameters, including PI-LL, SVA, and PT, in 58% of the cases. The deformity was radiologically cured in only 23% of the cases. Regarding PT, approximately 24% of the patients showed worsening of symptoms. In the present study, the SVA significantly improved postoperatively in both groups. Considering that long-level fusion was performed in patients with multisegmental degeneration and instability, the preoperative SVA was higher in the long-level fusion group, which was expected. In contrast, there was an increase of 1.45° in the PT in the long-level fusion group and 1.90° in the short-level fusion group. One study suggested that this improvement in SVA was due to a compensatory increase in PT (33).

The present study has several limitations. First, it was a retrospective study. Second, TLIF was performed at various levels; therefore, the effect of segmental lordosis could not be determined. Finally, the incidence of PJK may increase with prolonged follow-up.

■ CONCLUSION

Multilevel TLIF can be used to correct spinopelvic alignment when applied with the appropriate indications and techniques in patients with degenerative spinal disorders. Multilevel TLIF is associated with substantial improvements in LL, DLL, and SVA. It also helps to correct the correlation between PI and LL.

AUTHORSHIP CONTRIBUTION

Study conception and design: TA, MAO

Data collection: SK, MK

Analysis and interpretation of results: SB, ME

Draft manuscript preparation: MAO, SB, TA

Critical revision of the article: TP, TA

All authors (MAO, SK, MK, SB, ME, TP, TA) reviewed the results and approved the final version of the manuscript.

■ REFERENCES

- Barrey C, Darnis A: Current strategies for the restoration of adequate lordosis during lumbar fusion. *World J Orthop* 6(1):117, 2015
- Barrey C, Roussouly P, Le Huec J-C, D'Acunzi G, Perrin G: Compensatory mechanisms contributing to keep the sagittal balance of the spine. *Eur spine J* 22(6):834-841, 2013
- Bernhardt M, Bridwell KH: Segmental analysis of the sagittal plane alignment of the normal thoracic and lumbar spines and thoracolumbar junction. *Spine (Phila Pa 1976)* 14(7):717-721, 1989
- Chen PG, Daubs MD, Berven S, Raaen LB, Anderson AT, Asch SM, Nuckols TK; Degenerative Lumbar Scoliosis Appropriateness Group: Surgery for degenerative lumbar scoliosis: The development of appropriateness criteria. *Spine (Phila Pa 1976)* 41(10):910, 2016
- Chen WJ, Lai PL, Tai CL, Chen LH, Niu CC: The effect of sagittal alignment on adjacent joint mobility after lumbar instrumentation—a biomechanical study of lumbar vertebrae in a porcine model. *Clin Biomech* 19(8):763-768, 2004
- Cheng X, Zhang F, Zhang K, Sun X, Zhao C, Li H, Li YM, Zhao J: Effect of single-level transforaminal lumbar interbody fusion on segmental and overall lumbar lordosis in patients with lumbar degenerative disease. *World Neurosurg* 109:e244–251, 2018
- Cloward RB: The treatment of ruptured lumbar intervertebral discs by vertebral body fusion: I. Indications, operative technique, after care. *J Neurosurg* 10(2):154-168, 1953
- Doherty JH: Complications of fusion in lumbar scoliosis: Proceedings of the Scoliosis Research Society. *J Bone Jt Surg Am* 55:438, 1973
- Evans JH: Biomechanics of lumbar fusion. *Clin Orthop Relat Res* 193:38–46, 1985
- Fleege C, Rickert M, Rauschmann M: PLIF-und TLIF-verfahren: Indikation, technik, vor-und nachteile (Leitthema). *Orthopade* 44(2):114-123, 2015
- Glattes RC, Bridwell KH, Lenke LG, Kim YJ, Rinella A, Charles Edwards II: Proximal junctional kyphosis in adult spinal deformity following long instrumented posterior spinal fusion: incidence, outcomes, and risk factor analysis. *Spine (Phila Pa 1976)* 30(14):1643–1649, 2005
- Gum JL, Reddy D, Glassman S: Transforaminal lumbar interbody fusion (TLIF). *JBJS Essent Surg Tech* 6(2), 2016
- Hsieh PC, Koski TR, O'Shaughnessy BA, Sugrue P, Salehi S, Ondra S, Liu JC: Anterior lumbar interbody fusion in comparison with transforaminal lumbar interbody fusion: Implications for the restoration of foraminal height, local disc angle, lumbar lordosis, and sagittal balance. *J Neurosurg Spine* 7(4):379-386, 2007
- Jagannathan J, Sansur CA, Oskouian Jr RJ, Fu KM, Shaffrey CI: Radiographic restoration of lumbar alignment after transforaminal lumbar interbody fusion. *Neurosurgery* 64(5):955–964, 2009
- Jang JS, Lee SH, Min JH, Han KM: Lumbar degenerative kyphosis: Radiologic analysis and classifications. *Spine (Phila Pa 1976)* 32(24):2694–2699, 2007
- Kepler CK, Rihn JA, Radcliff KE, Patel AA, Anderson DG, Vaccaro AR, Hilibrand AS, Albert TJ: Restoration of lordosis and disk height after single-level transforaminal lumbar interbody fusion. *Orthop Surg* 4(1):15-20, 2012
- Kim HJ, Iyer S: Proximal junctional kyphosis. *JAAOS-Journal Am Acad Orthop Surg* 24(5):318–326, 2016
- Kim KH, Lee SH, Shim CS, Lee DY, Park HS, Pan WJ, Lee HY: Adjacent segment disease after interbody fusion and pedicle screw fixations for isolated L4–L5 spondylolisthesis: A minimum five-year follow-up. *Spine (Phila Pa 1976)* 35(6):625–634, 2010
- Kim SB, Jeon TS, Heo YM, Lee WS, Yi JW, Kim TK, Hwang CM: Radiographic results of single level transforaminal lumbar interbody fusion in degenerative lumbar spine disease: Focusing on changes of segmental lordosis in fusion segment. *Clin Orthop Surg* 1(4):207-213, 2009
- Kim YJ, Bridwell KH, Lenke LG, Glattes CR, Rhim S, Cheh G: Proximal junctional kyphosis in adult spinal deformity after segmental posterior spinal instrumentation and fusion: Minimum five-year follow-up. *Spine (Phila Pa 1976)* 33(20):2179-2184, 2008
- Kumar M, Baklanov A, Chopin D: Correlation between sagittal plane changes and adjacent segment degeneration following lumbar spine fusion. *Eur Spine J* 10(4):314–319, 2001
- Lafage R, Obeid I, Liabaud B, Bess S, Burton D, Smith JS, Jalai C, Hostin R, Shaffrey CI, Ames C, Kim HJ, Klineberg E, Schwab F, Lafage V; International Spine Study Group: Location of correction within the lumbar spine impacts acute adjacent-segment kyphosis. *J Neurosurg Spine* 30(1):69–77, 2018
- Li Y, Sun J, Wang G: Lumbar lordosis morphology correlates to pelvic incidence and erector spinae muscularity. *Sci Rep* 11(1):1–8, 2021
- Liow MHL, Goh GS, Chua JL, Ling ZM, Soh RCC, Guo CM, Tan SB, Chen JL: Sagittally balanced degenerative spondylolisthesis patients with increased sacral slope and greater lumbar lordosis experience less back pain after short-segment lumbar fusion surgery. *Clin Spine Surg* 33(5):E231–235, 2020
- Liu F, Cao Y, Feng Z, Zhou X, Jiang C, Li X, Chen Z, Li Z, Liang Y, Jiang X, Dong J: Comparison of three different posterior fixation techniques in transforaminal lumbar interbody fusion for two-level lumbar degenerative diseases: At a mean follow up time of 46 months. *Clin Neurol Neurosurg* 141:1-6, 2016
- Liu W, Chen X, Jia L, Song D: The clinical features and surgical treatment of degenerative lumbar scoliosis: A review of 112 patients. *Orthop Surg* 1(3):176–183, 2009
- Liu Z, Qian B, Qiu Y, Mao S, Jiang J, Wang B: Does post-operative PI-LL mismatching affect surgical outcomes in thoracolumbar kyphosis associated with ankylosing spondylitis patients? *Clin Neurol Neurosurg* 169:71-76, 2018
- Moal B, Schwab F, Ames CP, Smith JS, Ryan D, Mummaneni PV, Mundis GM Jr, Terran JS, Klineberg E, Hart RA, Boachie-Adjei O, Shaffrey CI, Skalli W, Lafage V; International Spine Study Group: Radiographic outcomes of adult spinal deformity correction: A critical analysis of variability and failures across deformity patterns. *Spine Deform* 2(3):219-225, 2014

29. Oster BA, Kikanloo SR, Levine NL, Lian J, Cho W: Systematic review of outcomes following 10-year mark of Spine Patient Outcomes Research Trial (SPORT) for degenerative spondylolisthesis. *Spine (Phila Pa 1976)* 45(12):820-824, 2020
30. Ould-Slimane M, Lenoir T, Dauzac C, Rillardon L, Hoffmann E, Guigui P, Ilharreborde B: Influence of transforaminal lumbar interbody fusion procedures on spinal and pelvic parameters of sagittal balance. *Eur Spine J* 21(6):1200-1206, 2012
31. Pehlivanoğlu T, Akgül T, Bayram S, Sarıılmaz K, Dikici F, Talu U: Prognostic criteria for post-operative success in patients undergoing surgery for adult spinal deformities. *J Turkish Spinal Surg* 32(3):131-138, 2021
32. Pesenti S, Lafage R, Stein D, Elysee JC, Lenke LG, Schwab FJ, Kim HJ, Lafage V: The amount of proximal lumbar lordosis is related to pelvic incidence. *Clin Orthop Relat Res* 476(8):1603, 2018
33. Pesenti S, Prost S, McCausland AM, Farah K, Tropiano P, Fuentes S, Blondel B: Optimal correction of adult spinal deformities requires restoration of distal lumbar lordosis. *Adv Orthop* 2021;2021
34. Phan K, Xu J, Maharaj MM, Li J, Kim JS, Di Capua J, Somani S, Tan KA, Mobbs RJ, Cho SK: Outcomes of short fusion versus long fusion for adult degenerative scoliosis: A systematic review and meta-analysis. *Orthop Surg* 9(4):342-349, 2017
35. Rothrock RJ, McNeill IT, Yaeger K, Oermann EK, Cho SK, Caridi JM: Lumbar lordosis correction with interbody fusion: Systematic literature review and analysis. *World Neurosurg* 118:21-31, 2018
36. Rubery PT, Lander ST, Mesfin A, Sanders JO, Thirukumaran CP: Mismatch between pelvic incidence and lumbar lordosis is the key sagittal plane determinant of patient outcome at minimum 40 years after instrumented fusion for adolescent idiopathic scoliosis. *Spine (Phila Pa 1976)* 2021
37. Schwab FJ, Blondel B, Bess S, Hostin R, Shaffrey CI, Smith JS, Boachie-Adjei O, Burton DC, Akbarnia BA, Mundis GM, Ames CP, Kebaish K, Hart RA, Farcy JP, Lafage V; International Spine Study Group (ISSG): Radiographical spinopelvic parameters and disability in the setting of adult spinal deformity: A prospective multicenter analysis. *Spine (Phila Pa 1976)* 38(13):E803-812, 2013
38. Sparrey CJ, Bailey JF, Safaee M, Clark AJ, Lafage V, Schwab F, Smith JS, Ames CP: Etiology of lumbar lordosis and its pathophysiology: A review of the evolution of lumbar lordosis, and the mechanics and biology of lumbar degeneration. *Neurosurg Focus* 36(5):E1, 2014
39. Takemitsu Y, Harada Y, Iwahara T, Miyamoto M, Miyatake Y: Lumbar degenerative kyphosis. Clinical, radiological and epidemiological studies. *Spine (Phila Pa 1976)* 13(11):1317-1326, 1988