



Clinical Efficacy of Intraventricular rt-PA (Actilyse®) in the Outcome of Patients with Spontaneous Intraventricular Hemorrhage

Babak ALIJANI¹, Enayat BIJANI¹, Zoheir REIHANIAN^{1*}, Mohammadreza EMAMHADI¹, Hamid BEHZADNIA¹, Muzaffar HOSSEININEZHAD², Seyed Mohsen AGHAPOUR¹, Sedighe MANSOORI³, Seifolla JAFARI¹, Hamed ANSARI¹

¹Guilan University of Medical Sciences, School of Medicine, Poursina Hospital, Department of Neurosurgery, Rasht, Iran

²Guilan University of Medical Sciences, School of Medicine, Poursina Hospital, Department of Neurology, Rasht, Iran

³Guilan University of Medical Sciences, School of Medicine, Poursina Hospital, Neuroscience Research Center, Rasht, Iran

Corresponding author: Zoheir REIHANIAN ✉ zoheir.reihanian@gmail.com

ABSTRACT

AIM: To evaluate the effectiveness of intraventricular injection of rt-PA (Actilyse®) in patients with spontaneous intraventricular hemorrhage (IVH) who had undergone external ventricular drainage (EVD).

MATERIAL and METHODS: This randomized clinical trial recruited 60 patients with spontaneous IVH who had undergone EVD due to the signs of hydrocephalus. The patients were randomly divided into two groups, including a group receiving intraventricular injection of rt-PA and the other normal saline.

RESULTS: Both groups receiving rt-PA Actilyse® (n=28) or placebo (n=32) were male by majority (58.33%). We found no difference in the prevalence of meningitis and brain infection (35.7% vs. 37.5%, p=0.665). Changes in hematoma volume at the end of the fourth day compared to the first day after EVD differed significantly between the two groups (p=0.004). The majority (64.29%) showed a decrease in the rt-PA group, but in the placebo group, the majority (53.13%) remained constant. As a result, changes in the rt-PA group were significantly higher than those in the placebo group.

Improvements in the level of consciousness (GCS) at the end of the fourth day compared to the first day after EVD implantation was 1.07 units in the Actilyse® group and -1.91 in the placebo group. As shown, the fourth day showed significant differences between the two groups (p<0.001). Improvements in the Glasgow Coma Scale (GCS) were observed at the end of the period.

CONCLUSION: It can be concluded that intraventricular injection of rt-PA (Actilyse®) can effectively reduce the volume of hematoma and improve the level of consciousness (GCS) during treatment. Intraventricular injection of 2-mg rt-PA is safe for patients and does not cause any acute complications such as cerebral hematoma expansion.

KEYWORDS: Intraventricular Hemorrhage (IVH), Recombinant Tissue Plasminogen Activator (rt-PA), External Ventricular Drainage (EVD), Glasgow Coma Scale (GCS)

Babak ALIJANI : 0000-0003-4480-6236 Hamid BEHZADNIA : 0000-0001-7067-2409 Seifolla JAFARI : 0000-0002-3218-7792
Enayat BIJANI : 0000-0002-1372-8389 Muzaffar HOSSEININEZHAD : 0000-0003-0768-0654 Hamed ANSARI : 0000-0003-0430-0134
Zoheir REIHANIAN : 0000-0001-9517-0974 Seyed Mohsen AGHAPOUR : 0000-0002-8407-8539
Mohammadreza EMAMHADI : 0000-0002-9155-2702 Sedighe MANSOORI : 0000-0002-5151-2845

■ INTRODUCTION

Among distinct types of strokes, intracranial hemorrhage (ICH) has the highest mortality rate (17). One of the main causes of nerve damage and poor prognosis in the initial stages of ICH is hematoma expansion (HE), which occurs in 38% of the patients with ICH in the early hours after the onset of symptoms (4). Studies have shown that the presence of intraventricular hemorrhage (IVH) with ICH is associated with a more severe decrease in the level of consciousness at the time of hospitalization compared to ICH without IVH (11). Some studies have also reported a mortality rate of 50% to 80% in patients with ICH and IVH (21). Patients with IVH also have higher mortality rates, coma and functional disabilities (7). Factors such as increased intracranial pressure (ICP), ischemic encephalopathy, hydrocephalus, and inflammation in response to the presence of blood in the ventricles have been reported to increase the risk of mortality and coma in patients with IVH (16,19,27). Therefore, there is a need for immediate action to direct the treatment process towards limiting the size of hematoma (10). The primary goal of treatment for patients with IVH is to reduce intravascular blood volume. The current standard for treating IVH with symptoms of hydrocephalus is external ventricular drainage (EVD). The benefits of EVD include a reduction in ICP and cerebrospinal fluid (CSF). However, the use of EVD can cause ICH, meningitis and ventriculitis, CSF leakage, high possibility of EVD displacement and the need for surgery (8,14,24). Using EVD alone to treat IVH is not always appropriate because the presence of a blood clot in the ventricle often prevents CSF and EVD catheter drainage (12). In addition, there is a disagreement among researchers on whether or not IVH improves by EVD alone (12,21,25). Research has shown that treating IVH with EVD in combination with thrombolytic medications has significant benefits for patients with IVH (2,12,16,21,22). The presence of thrombolytics in the intraventricular space leads to faster removal of potential clots, decreased ICP, reduced duration of EVD use, and reduced edema and hydrocephalus (2,12), which provides acceptable clinical results for patients with IVH (2,12,22). Bartek et al. reported the use of intrathecal alteplase for the treatment of IVH effective and safe (1). Another thrombolytic medication used to treat patients with IVH is recombinant tissue plasminogen activator (rt-PA). Vereecken et al. concluded that intraventricular injection of a thrombolytic agent such as rt-PA appears to be effective in lysis of intraventricular hematoma and improve the final clinical outcome (28). Jackson et al. also proposed that intraventricular rt-PA injection appears safe, especially when an EVD catheter is inserted into the ventricle simultaneously (9). The findings of Dharmadhikari et al. also revealed that the use of rt-PA could lead to the treatment of IVH caused by arteriovenous malformations (5).

Given the mentioned findings and the need for further clinical studies to discover the clinical outcomes of administering rt-PA for IVH, we intended to evaluate the effectiveness of intraventricular injection of rt-PA (Actilyse®) in patients with IVH.

■ MATERIAL and METHODS

Study population

In this randomized, double-blind, parallel, clinical trial, 60 consecutive patients with spontaneous IVH (with or without deep ICH less than 20 mL) (ICD-10-CM I61.5) who had undergone EVD due to the signs of hydrocephalus observed in brain CT scan were selected. Both physicians and patients were blinded in this study.

The standard treatment for hydrocephalus, EVD, was applied. It should be noted that the current standard treatment for IVH with signs of hydrocephalus is EVD, whose benefits are a reduction in ICP and CSF. All patients had the definitive diagnosis of spontaneous IVH and deep ICH of less than 20 mL. The exclusion criteria included severe and dangerous bleeding, severe hypertension, and reduced platelets count ($<100,000/\text{mm}^3$). Furthermore, patients with known bleeding disorders, patients with evidence of uncontrolled hypertension (systolic/diastolic blood pressures greater than 180/110 mmHg), patients with evidence of acute pancreatitis, patients with gastrointestinal ulcer in the past three months, esophageal varices, arterial aneurysms, venous arterial malformations, those taking oral anticoagulants such as sodium warfarin, those with severe and dangerous recent bleeding, recent delivery, recent non-compressible vascular puncture in subclavian or jugular veins for example, those with the evidence of bacterial endocarditis and pericarditis, those with neoplasms with increased risk of bleeding, patients with severe liver disease such as liver failure, liver cirrhosis, increased portal vein pressure (esophageal varices) and active hepatitis, or those with a history of major surgery or significant trauma in the past three months were all excluded.

Study Interventions and Assessments

Consents were obtained from both groups of patients or their relatives before participating in this study. The study subjects were randomly assigned into two groups using the block randomization method. The study groups included 32 patients receiving the placebo and 28 patients receiving rt-PA Actilyse®. Actilyse® 2 mg (2 mL) was administered to the ventricular space of the experimental group every 12 hours while the placebo group received 2 ml of normal saline in the same manner every 12 hours via EVD.

During the intervention, brain CT scans were performed daily to monitor asymptomatic bleeding and assess clot status.

In addition, the volume of intraventricular hematoma was assessed in the quadruple ventricles on brain CT scan after inserting EVD at the beginning of the first day of intervention compared with brain CT scan at the end of the fourth day of treatment (Figure 1).

The medication was continued every 12 hours for four days. In case of severe complications (symptomatic bleeding), the medication was discontinued immediately. Serum coagulation factors and infection markers in CSF were monitored daily. Blood pressure and body temperature were checked every eight hours during the intervention. GOS ≥ 4 was considered as favorable and GOS ≤ 3 as unfavorable at the end of the

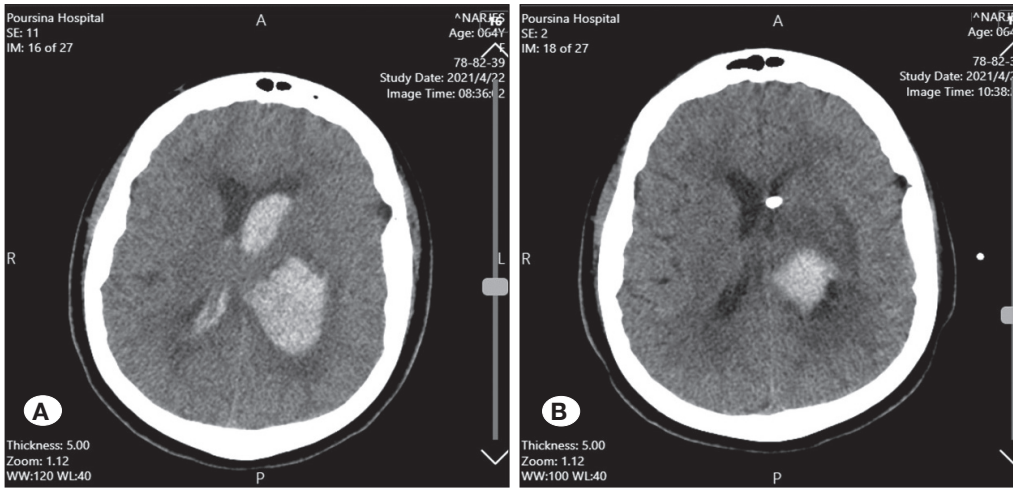


Figure 1: A) CT scan before inserting EVD. **B)** CT scan at the end of the fourth day of intraventricular rt-PA injection.

Table I: Comparison of Study Groups in Terms of Gender and Age

		Study Group						p
		Placebo Group		rt-PA Group		Total		
		Number	Percent	Number	Percent	Number	Percent	
Gender	Female	16	50.00	9	32.14	25	41.67	0.162*
	Male	16	50.00	19	67.86	35	58.33	
	Total	32	100.00	28	100.00	60	100.00	
Age	Less than sixty years	14	43.75	7	25.00	21	35.00	0.129*
	Sixty years and more	18	56.25	21	75.00	39	65.00	
	Total	32	100.00	28	100.00	60	100.00	
	Standard deviation ± Average	62.66 ± 11.26		65.46 ± 11.88		63.97 ± 11.54		
(Highest, lowest)	(40.0, 86.0)		(46.0, 93.0)		(40.0, 93.0)			

*Chi-square test.

first month after the onset of hematoma. Other secondary outcomes including reduced GCS, death, brain hematoma, ICH, hydrocephalus, ventriculitis, and brain infection were also monitored daily during hospitalization.

Statistical Analysis

The collected data was coded and then entered into SPSS version 23.0 software for analysis. The quantitative variables were presented as mean, standard deviation and median, and the qualitative variables were summarized using number and frequency (percentage).

To describe the relationship between qualitative variables in the two groups, Chi-square and Fisher’s exact tests were applied. Shapiro-Wilk test was also used to evaluate the normality of GCS quantitative variables. Shapiro-Wilk test showed that these variables did not have a normal distribution. Therefore, Mann-Whitney-U test was applied to compare the quantitative variables between the two groups and Wilcoxon Marked rank test was used to compare these scores within each group. Significance level of all tests was considered $p < 0.05$.

RESULTS

The majority of the participants were male in both groups: receiving rt-PA Actilyse® (n=28) and placebo (n=32) (58.33%).

There was no statistically significant difference between the two groups in terms of gender ($p=0.162$) and the majority of the participants (65%) were over 60 years old. There was no statistically significant difference between the two groups in terms of age ($p=0.129$). The mean age of the participants was 63.9 years old (range: 40-93 years old) (Table I).

We found no difference in the prevalence of meningitis and brain infection (35.7% vs. 37.5%, $p=0.665$), nor was there a statistically significant difference between the two groups in terms of the outcome of meningitis and infection following EVD insertion and treatment ($p=0.886$) (Table II).

A significant difference was observed between the two groups in terms of changes in hematoma volume at the end of the fourth day compared to the first day after EVD ($p=0.004$). That is, the majority in the rt-PA group (64.29%) had a decrease in hematoma volume, while it remained constant in the majority

Table II: Comparison of Study Groups in Terms of Underlying Diseases

		Study Group						p*
		Placebo Group		rt-PA Group		Total		
		Number	Percent	Number	Percent	Number	Percent	
Meningitis and brain infection	Does not have	20	62.50	18	64.29	38	63.33	0.886
	Has it	12	37.50	10	35.71	22	36.67	
	Total	32	100.00	28	100.00	60	100.00	
History of high blood pressure	Does not have	7	21.88	8	28.57	15	25.00	0.550
	Has it	25	78.13	20	71.43	45	75.00	
	Total	32	100.00	28	100.00	60	100.00	
History of diabetes	Does not have	23	71.88	18	64.29	41	68.33	0.528
	Has it	9	28.13	10	35.71	19	31.67	
	Total	32	100.00	28	100.00	60	100.00	
Previous stroke	Does not have	27	84.38	19	67.86	46	76.67	0.131
	Has it	5	15.63	9	32.14	14	23.33	
	Total	32	100.00	28	100.00	60	100.00	
History of hyperlipidemia	Does not have	24	75.00	24	85.71	48	80.00	0.301
	Has it	8	25.00	4	14.29	12	20.00	
	Total	32	100.00	28	100.00	60	100.00	
History of heart disease	Does not have	26	81.25	20	71.43	46	76.67	0.370
	Has it	6	18.75	8	28.57	14	23.33	
	Total	32	100.00	28	100.00	60	100.00	

*Chi-square test.

in the placebo group (53.13%). Therefore, the changes in the rt-PA group were significantly higher than those in the placebo group. In terms of average GCS after EVD insertion in both Actilyse® group and placebo group, it was not significantly different (p=0.274).

GCS score at the end of the fourth day increased 1.07 units in the Actilyse® group and -1.91 in the placebo group compared to the first day after EVD insertion (Figure 2). On the fourth day, GCS was significantly different between the two groups (p<0.001), as the majority in the Actilyse® group (64.29%) witnessed an increase, but the majority in the placebo group (53.13%) remained constant (Table III).

There was no statistically significant difference between the two groups in terms of GOS outcome and mortality (p>0.05). The cases of favorable optimal GOS (≥4) were higher in the Actilyse® rt-PA group than those in the placebo group one month after drug administration (four patients vs. one patient) (Table IV).

DISCUSSION

One of the main indicators for poorer outcome in patients with IVH is the volume of intraventricular hematoma; as revealed in several studies. It appears that applying minimally invasive approaches to reduce blood volume in such spaces can significantly improve clinical outcome in these patients. Several clinical trials and cohort studies have demonstrated the effectiveness of administering modest doses of intraventricular thrombolytics to eliminate clots (23,29). As similarly shown in our study, rt-PA Actilyse® could significantly reduce intraventricular blood volume as compared to placebo or EVD alone; however, Actilyse® did not affect in-hospital mortality rate. The dosage and the timing of the medication should probably be optimized, or it should be administered combined with other therapeutic approaches. As well as reducing the hematoma volume, thrombolytics such as rt-PA can significantly reduce the size of the clot. According to a report, treatment with rt-PA can result in a radiologic reduction in approximately 60% of clot size over four days of administration, which appears to be closely linked to lower mortality rates (18). Krel et al. found that transcatheter intraventricular rt-PA was truly harmless and beneficial as

Table III: Comparison of Study Groups in Terms of GCS Improvement

		Study Group			p*
		Placebo Group	rt-PA Group	Total	
GCS after EVD installation	Average	7.78	6.89	7.37	0.274
	Standard deviation	2.72	1.81	2.36	
	Middle	8.00	7.00	7.00	
	The first quarter	5.00	5.00	5.00	
	The third quarter	9.00	8.00	8.00	
GCS End of the fourth day	Average	5.88	7.96	6.85	0.001
	Standard deviation	2.57	2.47	2.72	
	Middle	6.00	8.00	7.00	
	The first quarter	3.50	6.50	5.00	
	The third quarter	7.00	9.50	8.00	
	p-value**	<0.001	0.005	0.133	
The GCS score changes on the first day compared to the fourth day	Average	-1.91	1.07	-.52	<0.001
	Standard deviation	2.04	1.72	2.40	
	Middle	-2.00	1.00	.00	
	The first quarter	-2.00	.00	-2.00	
	The first quarter	-.50	2.50	1.00	

*Mann-Whitney U test, **Wilcoxon Marked Rank Test.

Table IV: Comparison of Study Groups Based on Glasgow Outcome Scale (GOS) Status, Mortality Rate and Hematoma Volume Changes at the end of the Fourth Day Compared to the First Day After EVD Installation

		Study Group						p
		Placebo Group		rt-PA Group		Total		
		Number	Percent	Number	Percent	Number	Percent	
Glasgow Outcome Scale (GOS)	Unfavorable	31	96.88	24	85.71	55	91.67	0.175**
	Favorable	1	3.13	4	14.29	5	8.33	
	Total	32	100.00	28	100.00	60	100.00	
Mortality	Death	24	75.00	21	75.00	45	75.00	0.999*
	Live	8	25.00	7	25.00	15	25.00	
	Total	32	100.00	28	100.00	60	100.00	
Hematoma volume changes at the end of the fourth day compared to the first day after EVD implantation	Decrease	9	28.13	18	64.29	27	45.00	0.004**
	Fixed	17	53.13	10	35.71	27	45.00	
	Increase	6	18.75	0	.00	6	10.00	
	Total	32	100.00	28	100.00	60	100.00	

*Chi-square test, **Accurate Fisher test.

an adjuvant in acute spontaneous IVH with rt-PA regimen providing the greatest benefit two days after EVD insertion (13).

According to a meta-analysis performed by Shi et al., intraventricular rt-PA exhibited no significant efficacy on long-term functional recovery following aneurysmal subarachnoid hemorrhage with IVH (20).

High doses of rt-PA, on the other hand, may lower the risk of angiographic vasospasm. In their meta-analysis, Litrico et al. reported a reduction in mortality rate in the rt-PA group after 30 days (45.5% vs. 62.5%) (2013) (15), which is similar to our experience.

The clearance of the third and fourth ventricles was achieved significantly earlier in the rt-PA group (4.25 days) as compared with the control group (10.67 days).

In our investigation, the two groups did not have statistically significant differences in the occurrence of complications. Controversial results have been reported regarding the safety of different brands of rt-PA. Intraventricular rt-PA appears to be rather safe and reduce IVH burden, particularly when all EVD fenestrations are within the ventricle, as proven in numerous trials (15).

In a study by Jackson et al., IVH hematoma load fell from a median Le Roux score of ten before rt-PA injection to a score of four thereafter, with no signs of CNS bacterial infections (9). Even in some reports, increasing the dose of rt-PA could reduce IVH score with the maintenance of drug safety. According to Webb et al., increasing rt-PA dose lowered IVH score faster across all locations without causing clinical problems (26). Therefore, it appears that increasing the dose of the medication within non-toxic ranges can help treat the disease by significantly reducing the score, removing more clots and also reducing the volume of blood in the ventricles. Obviously, in our study, increasing the dose of the medication could reduce mortality.

We effectively showed that rt-PA could resolve the clot. Its mechanism of action pertains to the pathophysiology of coagulation cascade (29).

The key drivers of the response rate to rt-PA treatment have been examined in a number of studies. According to Webb et al., rt-PA therapy accelerates the resolution of IVH in a dose-dependent manner, with the impact being the strongest in the midline ventricles (26).

Fam et al. discovered that rt-PA had a positive effect on clinical outcome in the presence of a vascular lesion (6).

Therefore, the next step in evaluating the effectiveness of this treatment is a comprehensive evaluation of patient-dependent and drug-dependent factors that can affect the drug response.

A limitation of this study and also other similar studies was the exclusion of the infants with IVH at birth due to the lack of access to pediatric hospitals with the facilities for these patients.

CONCLUSION

It can be concluded that intraventricular injection of rt-PA (Actilyse®) can effectively reduce the volume of hematoma, and improve the level of consciousness (GCS) during treatment. Intraventricular injection of 2 mg rt-PA is safe for patients and does not cause any acute complications such as cerebral hematoma expansion.

However, it appears that the dose and the duration of this treatment should be optimized until IVH is completely resolved in order to reach a higher efficacy on patients' overall outcome especially death.

AUTHORSHIP CONTRIBUTION

Study conception and design: BA, EB, ZR, ME, HB, MH, SMA, SM, SJ, HA

Data collection: BA, EB, ZR, ME, HB, MH, SMA, SM, SJ, HA

Analysis and interpretation of results: BA, EB, ZR, ME, HB, MH, SMA, SM, SJ, HA

Draft manuscript preparation: BA, EB, ZR, ME, HB, MH, SMA, SM, SJ, HA

Critical revision of the article: BA, EB, ZR, ME, HB, MH, SMA, SM, SJ, HA

All authors (BA, EB, ZR, ME, HB, MH, SMA, SM, SJ, HA) reviewed the results and approved the final version of the manuscript.

REFERENCES

1. Bartek J Jr, Hansen-Schwartz J, Bergdal O, Degn J, Romner B, Welling KL, Fischer W: Alteplase (rtPA) treatment of intraventricular hematoma (IVH): Safety of an efficient methodological approach for rapid clot removal. *Acta Neurochir Suppl* 111:409-413, 2011
2. Bender M, Schwarm F, Stein M, Uhl E, Reinges MHT: Placement of external ventricular drain: Comparison of two methods. *J Neurol Surg A Cent Eur Neurosurg* 80(2):116-121, 2019
3. Bosche B, Mergenthaler P, Doepfner TR, Hescheler J, Molcanyi M: Complex clearance mechanisms after intraventricular hemorrhage and rt-PA treatment-a review on clinical trials. *Transl Stroke Res* 11(3):337-344, 2020
4. Brott T, Broderick J, Kothari R, Barsan W, Tomsick T, Sauerbeck L, Spilker J, Duldner J, Khoury J: Early hemorrhage growth in patients with intracerebral hemorrhage. *Stroke* 28(1):1-5, 1997
5. Dharmadhikari S, Mahapatra A, Tipirneni A, Yavagal D, Malik AM: Safety of intraventricular rt-PA for pan-ventricular IVH caused by a ruptured AVM: A case report. *Neurohospitalist* 7(4):NP5-NP8, 2017
6. Fam MD, Pang A, Zeineddine HA, Mayo S, Stadnik A, Jesselson M, Zhang L, Dlugash R, Ziai W, Hanley D, Awad IA: Demographic risk factors for vascular lesions as etiology of intraventricular hemorrhage in prospectively screened cases. *Cerebrovasc Dis* 43(5-6):223-230, 2017
7. Hanley DF: Intraventricular hemorrhage: Severity factor and treatment target in spontaneous intracerebral hemorrhage. *Stroke* 40(4):1533-1538, 2009

8. Hoang Ngoc N, Van Tuyen N: Using low-dose tissue plasminogen activator through external ventricular drain and Cerebrolysin for the treatment of severe intraventricular hemorrhage: A case report. *SAGE Open Med Case Rep* 8:2050313X20981464, 2020
9. Jackson DA, Patel AV, Darracott RM, Hanel RA, Freeman WD, Hanley DF: Safety of intraventricular hemorrhage (IVH) thrombolysis based on CT localization of external ventricular drain (EVD) fenestrations and analysis of EVD tract hemorrhage. *Neurocrit Care* 19(1):103-110, 2013
10. Jaffe J, Melnychuk E, Muschelli J, Ziai W, Morgan T, Hanley DF, Awad IA: Ventricular catheter location and the clearance of intraventricular hemorrhage. *Neurosurgery* 70(5):1258-1263; discussion 1263-1264, 2012
11. Keefe K, Kebriaei M, Gard A, Patil AA: Intraventricular tissue plasminogen activator for intraventricular hemorrhage caused by an arteriovenous malformation. *J Clin Neurosci* 21(3):526-529, 2014
12. Kongwad LI, Nair RP: External ventricular drain and fibrinolytics in intraventricular hemorrhage: A gain or a bane? *World Neurosurg* 127:637-639, 2019
13. Krel M, Brazdzionis J, Podkovik S, Miulli DE, Wacker MR, Beamer Y: Safety and efficacy of transcatheter administration of tissue plasminogen activating factor as adjuvant therapy for intraventricular hemorrhage. *Cureus* 11(9):e5785, 2019
14. Li M, Mu F, Han Q, Su D, Guo Z, Chen T: Intraventricular fibrinolytic for the treatment of intraventricular hemorrhage: A network meta-analysis. *Brain Inj* 34(7):864-870, 2020
15. Litrico S, Almairac F, Gaberel T, Ramakrishna R, Fontaine D, Sedat J, Lonjon M, Paquis P: Intraventricular fibrinolysis for severe aneurysmal intraventricular hemorrhage: A randomized controlled trial and meta-analysis. *Neurosurg Rev* 36(4):523-530; discussion 530-531, 2013
16. Maas MB, Nemeth AJ, Rosenberg NF, Kosteva AR, Prabhakaran S, Naidech AM: Delayed intraventricular hemorrhage is common and worsens outcomes in intracerebral hemorrhage. *Neurology* 80(14):1295-1299, 2013
17. Maegele M: Coagulopathy and progression of intracranial hemorrhage in traumatic brain injury: Mechanisms, impact, and therapeutic considerations. *Neurosurgery* 89(6):954-966, 2021
18. Naff N, Williams MA, Keyl PM, Tuhim S, Bullock MR, Mayer SA, Coplin W, Narayan R, Haines S, Cruz-Flores S, Zuccarello M, Brock D, Awad I, Ziai WC, Marmarou A, Rhoney D, McBee N, Lane K, Hanley DF Jr: Low-dose recombinant tissue-type plasminogen activator enhances clot resolution in brain hemorrhage: The intraventricular hemorrhage thrombolysis trial. *Stroke* 42(11):3009-3016, 2011
19. Rabinstein AA, Anderson CD: Time is brain also counts for ICH. *Neurology* 84(10):970, 971, 2015
20. Shi LG, Xu L, Shi LF, Brandon D, Chen S, Zhang JM: Intraventricular recombinant tissue plasminogen activator in treatment of aneurysmal intraventricular hemorrhage: A meta-analysis. *Curr Drug Targets* 18(12):1399-1407, 2017
21. Society for Maternal-Fetal Medicine (SMFM), Monteagudo A: Intracranial Hemorrhage. *Am J Obstet Gynecol* 223(6):B34-B37, 2020
22. Song P, Duan FL, Cai Q, Wu JL, Chen XB, Wang Y, Huang CG, Li JQ, He ZQ, Huang QC, Liu M, Zhang YG, Luo M: Endoscopic surgery versus external ventricular drainage surgery for severe intraventricular hemorrhage. *Curr Med Sci* 38(5):880-887, 2018
23. Sošić M, Antončić I, Tarčuković J, Dunatov S, Šustić A, Ćurko-Cofek B, Sotošek V: Effect of intra-ventricularly administered low-dose recombinant tissue plasminogen activator on interleukin 1-beta and transforming growth factor beta concentrations in cerebrospinal fluid of patients with primary intracerebral hemorrhage associated with intraventricular hemorrhage: A retrospective study. *Medicine (Baltimore)* 99(20):e19966, 2020
24. Su J, Xing Y, Liang S, Lin Q, Liu H: Transcortical approach surgery versus external ventricular drainage in treating intraventricular hemorrhage. *Medicine (Baltimore)* 100(42):e27443, 2021
25. Xia D, Jiang X, Li Z, Jin Y, Dai Y: External ventricular drainage combined with continuous lumbar drainage in the treatment of ventricular hemorrhage. *Ther Clin Risk Manag* 15:677-682, 2019
26. Webb AJS, Ullman NL, Mann S, Muschelli J, Awad IA, Hanley DF: Resolution of intraventricular hemorrhage varies by ventricular region and dose of intraventricular thrombolytic: The Clot Lysis: Evaluating Accelerated Resolution of IVH (CLEAR IVH) program. *Stroke* 43(6):1666-1668, 2012
27. Van Solinge TS, Muskens IS, Kavouridis VK, Gormley WB, Mekary RA, Broekman MLD, Arnaout O: Fibrinolytics and intraventricular hemorrhage: A systematic review and meta-analysis. *Neurocrit Care* 32(1):262-271, 2020
28. Vereecken KK, Van Havenbergh T, De Beuckelaer W, Parizel PM, Jorens PG: Treatment of intraventricular hemorrhage with intraventricular administration of recombinant tissue plasminogen activator: A clinical study of 18 cases. *Clin Neurol Neurosurg* 108(5):451-455, 2006
29. Ziai WC, Tuhim S, Lane K, McBee N, Lees K, Dawson J, Butcher K, Vespa P, Wright DW, Keyl PM, Mendelow AD, Kase C, Wijman C, Lapointe M, John S, Thompson R, Thompson C, Mayo S, Reilly P, Janis S, Awad I, Hanley DF, CLEAR III Investigators: A multicenter, randomized, double-blinded, placebo-controlled phase III study of Clot Lysis Evaluation of Accelerated Resolution of Intraventricular Hemorrhage (CLEAR III). *Int J Stroke* 9(4):536-542, 2014