



Preoperatively, Which Parameter Allows Us to Predict the C5 Palsy After Cervical Open-Door Laminoplasty?

Inan UZUNOGLU¹, Gokhan GURKAN², Ilker Deniz CINGOZ³, Murat ATAR⁴, Ismail KAYA³, Ege COSKUN⁵, Kazim Ayberk SINCI⁶, Ezgi Suat BAYRAKTAR⁶, Koray UR⁵, Hasan Emre AYDIN⁷, Ceren KIZMAZOGLU⁵, Orhan KALEMCI⁵, Murat SAYIN², Nurullah YUCEER²

¹Health Science University, Diskapi Yildirim Beyazit Training and Research Hospital, Department of Neurosurgery, Ankara, Turkey

²Katip Celebi University, Atatürk Training and Research Hospital, Department of Neurosurgery, Izmir, Turkey

³Usak University of Health Sciences, Faculty of Medicine, Department of Neurosurgery, Usak, Turkey

⁴Sultan Abdulhamid Han Training and Research Hospital, Department of Neurosurgery, Istanbul, Turkey

⁵Dokuz Eylul University, Faculty of Medicine, Department of Neurosurgery Izmir, Turkey

⁶Katip Celebi University, Atatürk Training and Research Hospital, Department of Radiology, Izmir, Turkey

⁷Kutahya Health Science University, Department of Neurosurgery, Kutahya, Turkey

Corresponding author: Inan UZUNOGLU ✉ dr_inan_uzunoglu@hotmail.com

ABSTRACT

AIM: To uncover factors that can predict the development of C5 palsy before surgery by evaluating several different parameters.

MATERIAL and METHODS: A total of 177 patients who underwent surgery between 2015 and 2020 were included in the study. In total, C5 palsy was observed in 22 (12.4%) of our patients. The radiological and clinical data of the patients were retrospectively analyzed and added to the data.

RESULTS: A total of 177 patients who satisfied the criteria were included in the study, among whom 117 (66.1%) and 60 (33.9%) were male and female, respectively. Patients with ossified posterior longitudinal ligament (OPLL) (92; 52.0%) needed surgery the most. C5 palsy developed in 16/92 (17.3%) patients who had surgery for OPLL. This result was statistically significant ($p < 0.001$). However, a significant difference in the postoperative Pavlov ratio was noted between both groups ($p = 0.027$). The foraminal dimensions for the C5 palsy group were significantly lower than those for the non-C5 palsy group.

CONCLUSION: Smaller C5 root foramina diameter measurements were the most important predictive factor for the development of C5 palsy after open-door cervical laminoplasty. Although the pathophysiology remains to be fully understood, ischemia-reperfusion injury supposedly plays a role therein.






KEYWORDS: Open-door cervical laminoplasty, OPLL, C5 palsy, Cervical spondylotic myelopathy, C4/5 foramina diameter

INTRODUCTION

Cervical spondylotic myelopathy (CSM) is one of the major causes of morbidity among middle-aged and elderly patients (6). Progressive muscle weakness, sensory deficit caudal to the level of the lesion, and incontinence are some of the possible neurological deficits (6). While several

different surgical options are available, cervical open-door laminoplasty stands out given its more physiological approach and lower risk of complications (10,19,22).

Cervical open-door laminoplasty had been first performed in 1977 by Hirabayashi et al. (4). Despite the several known complications, cervical open-door laminoplasty has now been

Inan UZUNOGLU  : 0000-0001-5859-0443
Gokhan GURKAN  : 0000-0003-1839-1014
Ilker Deniz CINGOZ  : 0000-0002-0452-7606
Murat ATAR  : 0000-0001-6047-2956
Ismail KAYA  : 0000-0002-5117-8066

Ege COSKUN  : 0000-0002-5582-9786
Kazim Ayberk SINCI  : 0000-0002-2207-5850
Ezgi Suat BAYRAKTAR  : 0000-0003-0541-984X
Koray UR  : 0000-0002-2755-5992
Hasan Emre AYDIN  : 0000-0002-8932-1542

Ceren KIZMAZOGLU  : 0000-0001-6146-0842
Orhan KALEMCI  : 0000-0002-8607-6860
Murat SAYIN  : 0000-0001-8745-2656
Nurullah YUCEER  : 0000-0003-3509-9939

widely used in the treatment of CSM given the aging society (10,22). Posterior decompression and fusion surgery has been known to promote higher C5 palsy rates compared to laminoplasty (25). Despite this knowledge, C5 palsy remains one of the most serious complications of laminoplasty, causing muscle weakness, pain, lethargy, and poor quality of life (6). In the literature, half of the patients with C5 palsy exhibited sensory impairment or excruciating pain at the C5 dermatome and 92% exhibited hemilateral palsy, with all deficits occurring within a week of surgery and having a relatively good prognosis; however, patients with severe deficits require a longer period for recovery (10). The prevalence of C5 palsy after cervical open-door laminoplasty has been reported to be approximately 5.1% (16). Several causative factors for C5 palsy have been suggested, such as iatrogenic nerve damage, thermal damage during drilling of the bone, stretching of nerve roots due to displacement of the spinal cord, compression of the root within the stenotic foramina, and ischemia-reperfusion injury of the spinal cord; however, the exact pathophysiology has not been revealed yet (3,5,14,19).

The current study aimed to review the clinical and radiological factors that may cause C5 palsy after cervical laminoplasty surgery.

■ MATERIAL and METHODS

Patient Selection and Surgical Technique

A total of 177 patients who underwent cervical open-door laminoplasty between 2015 and 2020 at our clinic were included in the study. Laminoplasty surgery was performed as described in the literature (10). Accordingly, patients were placed in the prone position with their heads fixed using a Mayfield head holder inflection. After muscle dissection, a thin laminectomy was performed via Kerrison rongeur at the side that will house the mini plates and screws. The lateral mass-spinous process junction was thinned with the help of a high-speed drill. The ligamentum flavum was excised, after which the whole bony structure was bent toward the thinner side and the other side was elevated. The elevated side is fixed to the lamina using mini plates and screws. The dominant side, for which the patients had complaints, was selected for laminectomy and miniplate insertion. None of the patients who underwent laminoplasty underwent foraminotomy for any reason (prophylactic or foraminal stenosis). All patients displayed CSM findings. Any two or all of the findings of muscle weakness, hyperreactive deep tendon reflexes, and the presence of a pathological reflex were identified during a clinical examination. Muscle weakness was evaluated using a manual muscle test (MMT). Patients with an MMT score <3 were considered to have C5 palsy on follow-up immediately after the procedure or on the second postoperative week. Patients with CSM symptoms underwent surgery due to ossified posterior longitudinal ligament (OPLL), cervical spinal stenosis (CSS), 2 or more levels of cervical disk herniation (CDH), and cervical epidural abscess. Patients who underwent surgery due to cervical intramedullary tumors and any patients who underwent laminoplasty with bilateral miniplate and screw insertion due to any reason were excluded from

the study. Concurrently, no patient with cervical instability underwent laminoplasty. Instead, they were treated with cervical posterior stabilization and fusion. Ethics committee approval was obtained from our university (24.06.2021; IRB No: 0342).

Evaluation of Results

Our patients were evaluated using preoperative and postoperative values of the Pavlov ratio (12), Modified Japanese Orthopedic Association (mJOA) classification and recovery score [(postoperative score) / (18 – preoperative score) × 100], and American Spinal Injury Association (ASIA) classification. At the C4/5 level, the anteroposterior length and length between the C4 corpus posterior margin and most anterior part of the spinal cord were measured using axial computed tomography (CT) (Figure 1). In addition, the shift difference in the cervical cord was also measured and verified (Figure 2). The C2–C7 Cobb Angle was measured from cervical lateral radiographs.

Preoperative cervical spine magnetic resonance imaging (MRI) was used to determine whether high-intensity zones existed in the spinal cord and, if present, the number of levels it covers and whether it is present cranially to the C5 root exit (Figure 3). Moreover, the axial dimensional measurements of the C5 root foramina at the side of miniplate insertion, the number of segments in which laminoplasty was performed, and the degree of laminar widening were measured using CT. All measurements were performed using surgimap spine-free software (<http://www.surgimap.com>; Nemaris Inc., New York, USA) by two different neuroradiologists who were blinded to each other's measurements after their average values were obtained. The presence of C5 palsy postoperatively was also noted. Patients who were followed up for at least 6 months and whose radiological and clinical data could be accessed in hospital information systems were included in our study. Other than this, our patients were excluded from the study. In addition, age, sex, the underlying etiology of the pathology, comorbidities, complications, and duration of follow-up were added to the data.

Statistical Evaluation

Statistical analysis was conducted using Statistical Package for the Social Sciences version 15.0 (IBM Corp., Armonk, New York, USA) program. The Chi-square test and independent-sample t-test were utilized. The value of $p < 0.05$ was considered statistically significant.

■ RESULTS

A total of 177 patients who satisfied the adequate follow-up and criteria underwent cervical open-door laminoplasty surgery at the Neurosurgery Department of Izmir Katip Çelebi University Atatürk Education and Research Hospital between 2015 and 2021 were included in our study. The mean age of our patients was 58.1 ± 11.8 . Among the included patients, 117 (66.1%) were male and 60 (33.9%) were female. Moreover, 92 (52.0%) underwent surgery due to OPLL (Figure 4), 50 (28.2%) due to CSS, 33 (18.6%) due to multi-level CDH, and 2 (1.1%)

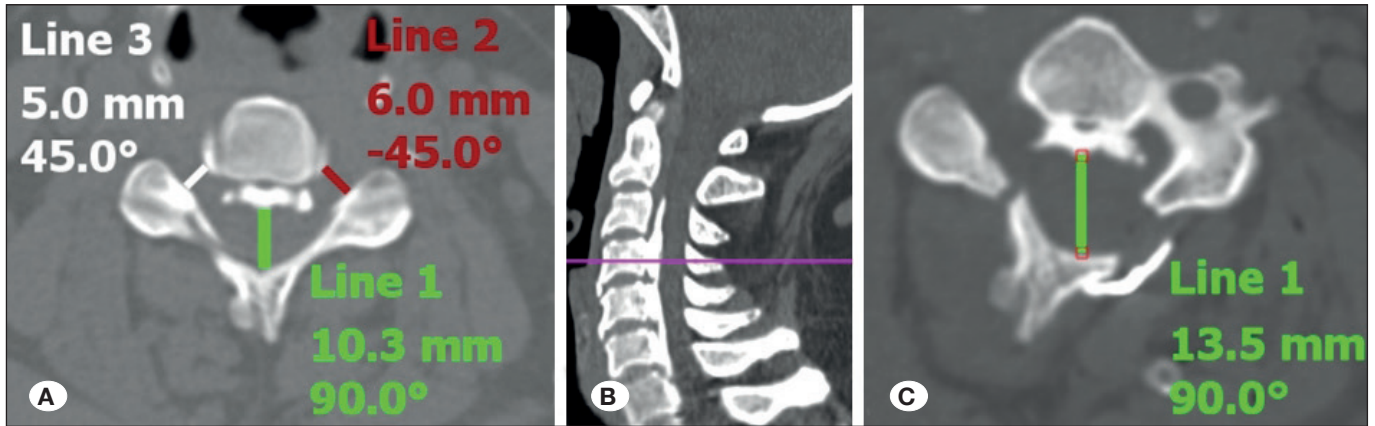


Figure 1: **A)** Preoperative axial cervical CT; Line 1 (green arrow); The anteroposterior (AP) distance of the spinal canal at the C4/C5 level. Line 2,3 (red-white arrow); The transverse distance of the C4/5 foramen. **B)** Sagittal cervical CT line demonstrate the level of figure A and C. **C)** Postoperative axial cervical CT; Line 1 (green arrow); The anteroposterior (corpus posterior-lamina anterior) distance of the spinal canal at the C4/C5 level.

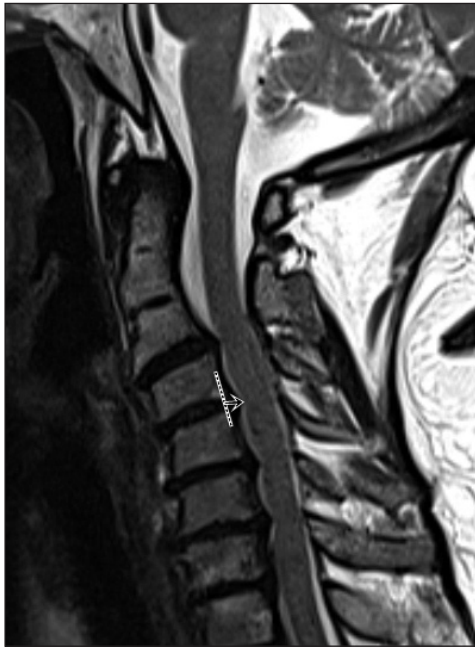

Figure 2: White Arrow: The posterior shift of the spinal cord at C4–5. The distance of the craniocaudal middle point of C4/5 disc posterior and nearest point of the anterior margin of the spinal cord.(between postoperative and preoperative distance demonstrate spinal cord shift).

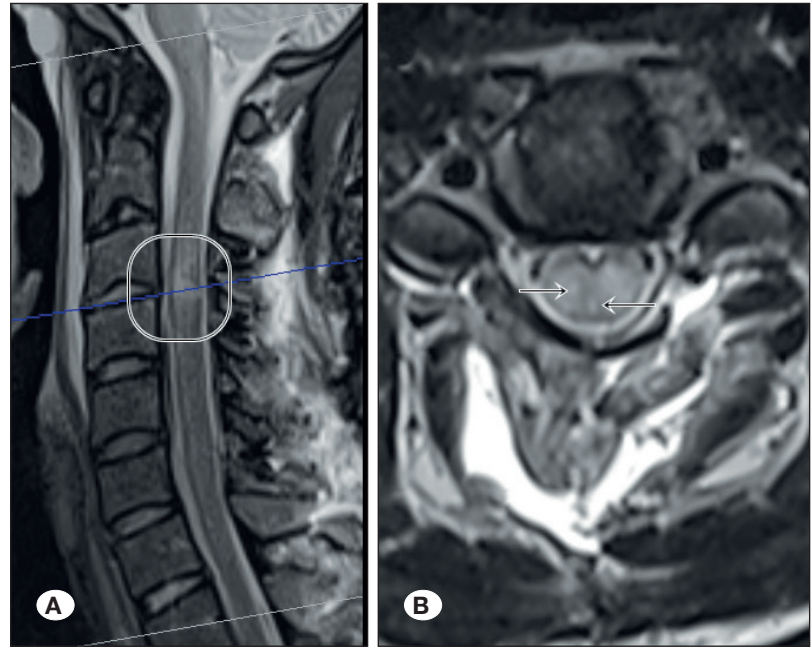


Figure 3: **A)** Cervical sagittal T2-weighted MRI high-intensity zone. **B)** Cervical axial T2-weighted MRI high-intensity zone (White arrow).

due to cervical spinal abscess. Meanwhile, 102 (57.6%) of our patients did not have any known additional diseases. However, diabetes mellitus, hypertension, coronary artery disease, cerebrovascular disease, pulmonary pathology, renal insufficiency, malignancies, and autoimmune diseases were present in our patients. Right- and left-sided instrumentation was done in 117 (66.1%) and 60 (33.9%) patients, respectively. This difference was statistically significant ($p=0.003$). Half of

the 22 patients with postoperative C5 palsy exhibited high-intensity zones on T2-weighted preoperative cervical MRI, whereas the other half did not. Meanwhile, 10 cases in the C5 palsy group showed high-intensity zones on T2-weighted MRI above the C4 pedicle, whereas 12 cases in the group showed a high-intensity zone below the C4 pedicle. No statistically significant difference between the C5 palsy group and the other group in the detection of a high-intensity zone

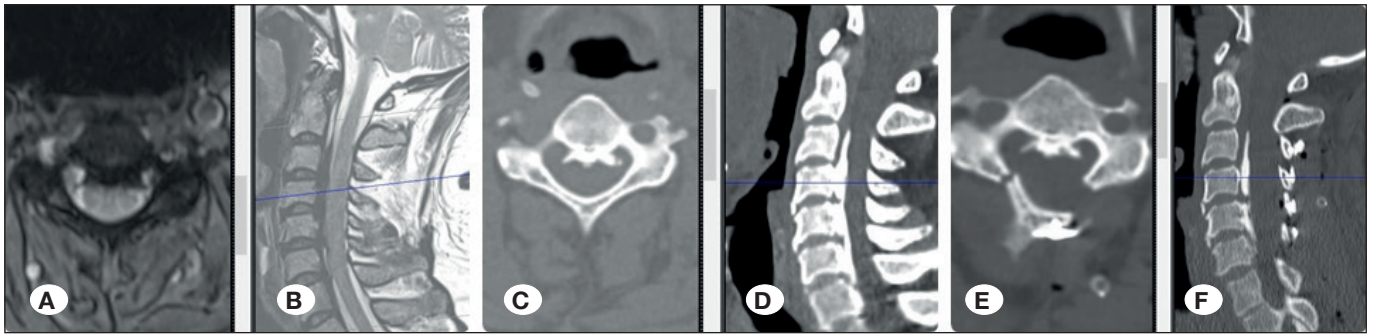


Figure 4: Preoperative cervical axial (A), sagittal (B) T2-weighted MRI with OPLL. Preoperative cervical axial (C), and (D) sagittal CT showing OPLL. Postoperative cervical axial (E), and sagittal (F) CT scans.

on T2-weighted MRI on the C4 pedicle ($p=0.530$). The number of segments operated on ranged from 2 to 6. Mini plate/screw insertion was performed in four laminae at most in a single operation. No significant difference in terms of laminar widening angle was observed between the non-C5 palsy and C5 palsy groups. Our patients' preoperative and postoperative ASIA scores were added to the data (Table I).

Whereas the postoperative Pavlov ratio averaged 0.80 ± 0.25 (1.0–1.34). No significant difference regarding the preoperative Pavlov ratios was observed between the C5 palsy and non-C5 palsy groups ($p=0.807$). However, a significant difference in the postoperative Pavlov ratio was noted between both groups ($p=0.027$). For the entire cohort, the mean preoperative and postoperative mJOA score was 16.03 ± 1.72 and 17.01 ± 1.65 , respectively. Although significant differences in postoperative mJOA scores and recovery rates were observed between groups, no significant difference in preoperative mJOA scores was noted (Table II).

The mean preoperative and postoperative anteroposterior dimension of the spinal canal was 11.12 ± 1.64 and 13.82 ± 0.44 , respectively, with no significant difference between the two groups. The shifting of the spinal cord was measured on T2-weighted MRI. No significant difference was found between the C5 palsy and non-C5 palsy groups ($p=0.128$). Additionally, no significant difference in preoperative and postoperative Cobb angle measurements was observed for both groups ($p=0.441$ and 0.349). Dimensions of C5 root foramina on both sides and the distance between the corpus and facet joint on the instrumented side were measured from the axial cervical CT.(8) The foraminal dimensions in the C5 palsy group were significantly lower than that in the non-C5 palsy group (Table III).

After adequate rehabilitation, five of our 22 patients who underwent cervical open-door laminoplasty and then developed C5 palsy were able to recover their muscle strength. However, although the remaining 17 patients achieved partial improvement, the loss of muscle strength continued to affect their daily lives. In addition to patients with C5 palsy, revision surgery or additional procedures were needed due to surgical wound site problems in four patients, one of whom required wound site exploration due to a local infection. A cerebral spinal fluid fistula was detected due to

dural tear in three patients, which was controlled after short-term lumbar drainage application, after which patients were discharged. Moreover, two patients who had severe CSS developed paraplegia postoperatively. During perioperative examinations, no data could be produced to explain this clinical condition (bleeding, instability, dural tear, epidural hematoma, etc.). However, with the current national health insurance system, neuromonitorization was not being paid back to caregiver institutions for these types of diseases (CSS and OPLL, etc.). Thus, given the absence of clear data regarding the procedures causing neurological impairment, such as intubation, positioning, or intraoperative period, these patients were excluded from the C5 palsy group.

DISCUSSION

C5 palsy, which may develop after cervical open-door laminoplasty, is a complication that cannot be predicted with existing preoperative data, with studies showing incidence rates of up to 13.6% (7). In the current study, an incidence rate of 12.4% had been observed. This may be more clearly explained by the theory of nerve root injury, which states that the root of C5 is shorter than that of other nerves after leaving the dura mater until it exits through the foramen. Additionally, the C4–C5 foramen is narrower than other cervical foramina, and the posterior ramus is also shorter on the C4–C5 nerves (4,10,15). These findings suggest that the development of C5 palsy may be a multi-factorial process (8). For this reason, we sought to evaluate the radiological and clinical findings that can help us predict preoperative C5 palsy risk.

Although studies have emphasized that C5 palsy may occur due to the shifting of the spinal cord (13, 20), other studies have failed to demonstrate any significant correlation (8). In some studies, C5 palsy has micro miniaturization been reported to occur at a higher rate in patients who underwent surgery due to OPLL (10). Evidence has highlighted the role of increased spinal cord shifting and further stretching of the C5 root in the development of OPLL (1,8). A meta-analysis by Shou F et al. on a total of 79 studies and 704 cases showed no significant difference in the development of postoperative C5 palsy between patients who underwent surgery due to OPLL (5.8%) and CSS (4.5%) (16). Similarly, Nakajima et al. found no significant difference but also indicated that they

Table I: Distribution of Patients according to Preoperative Data

	C5 palsy(+)	C5palsy(-)	p
Age	61.63 ± 13.43 (35-86)	57.58 ± 11.49 (19-90)	0.234
Gender	22 (12.4%)	155 (87.6%)	0.645
Male	15 (8.4%)	102 (57.6%)	
Female	7 (4.0%)	53 (30.0%)	
Disease			
OPLL	16 (9.1%)	76 (43.0%)	<0.001
CSS	4 (2.3%)	46 (25.9%)	<0.001
CDH	2 (1.2%)	31 (17.5%)	0.905
Epidural Abscess	0	2 (1.2%)	0.162
Predisposing Disease			
None	13 (7.3%)	89 (50.2%)	
DM	3 (1.7%)	23 (12.9%)	
HT	4 (2.2%)	20 (11.3%)	
CAD	1 (0.5%)	1 (0.5%)	
CVD	1 (0.5%)	8 (4.5%)	
Pulmonary Disease	0	6 (3.3%)	
Renal Disease	0	1 (0.5%)	
Malignancy	0	6 (3.3%)	
Autoimmune disease	0	1 (0.5)	
Side			
Right	17 (9.6%)	100 (56.5%)	0.003
Left	5 (2.8%)	55 (31.1%)	
T2 hyperintensity on sagittal MRI			
(+)	11 (6.2%)	54 (30.5%)	0.467
(-)	11 (6.2%)	101 (57.1%)	
T2 hyperintensity on sagittal MRI			
0	11 (6.3%)	101 (57.1%)	
1	2 (1.1%)	16 (9.1%)	
2	7 (4.3%)	21 (11.9%)	
3	1 (0.5%)	10 (5.8%)	
4	1 (0.5%)	6 (3.6%)	
5	0	1 (0.5%)	
T2 hyperintensity on sagittal MRI			
Up to C4 pedicle	10 (5.7%)	33 (18.6%)	0.530
Down the C4 pedicle	12 (6.8%)	122 (68.9%)	
No. of Lamina			
2	0	3 (1.6%)	
3	4 (2.2%)	26 (14.8%)	
4	14 (7.9%)	113 (63.9%)	
5	3 (1.6%)	11 (6.4%)	
6	1 (0.5%)	2 (1.1%)	
Preoperative/Postoperative Asia score(No. of patients)			
A	0	0	
B	1/1	0	
C	3/8	11/3	
D	14/13	47/31	
E	4/0	97/121	
Lamina opening angle(°)	33.31 ± 7.77 (21.3-49.7)	32.1 ± 9.2 (14.2-62.0)	0.522

OPLL: Ossified posterior longitudinal ligament, **CSS:** Cervical spinal stenosis, **CDH:** Cervical disc hernia, **Dm:** Diabetes mellitus, **HT:** Hypertension, **CAD:** Coronary artery disease, **CVD:** Cerebrovascular disease.

Table II: Data of Our Patients According to Pavlov Ratio and m(JOA) Scores

	C5 palsy (+)	C5 palsy (-)	p
Preoperative Pavlov ratio	0.63 ± 0.13 (0.33-0.83)	0.63 ± 0.14 (0.23-1.08)	0.807
Postoperative Pavlov ratio	0.82 ± 0.12 (0.53-0.98)	0.80 ± 0.27 (0.18-1.34)	0.027
Preoperative mJOA Score	14.95 ± 1.73 (11-17)	16.18 ± 1.67 (8-17)	0.329
Postoperative mJOA Score	14.27 ± 2.02 (9-17)	17.40 ± 1.15 (11-18)	0.000
mJOA recovery rate (%)	-26.27 ± 80.05	77.82 ± 34.56	0.000

Table III: Distribution of Patients According to Preoperative and Postoperative Radiological Data

	C5 palsy (+)	C5 palsy (-)	p
Preoperative APD (mm)#	11.35 ± 1.80 (7.7-14.5)	11.08 ± 1.67 (5.9-15.4)	0.407
Postoperative APD (mm)#	14.38 ± 3.58 (1.6-19.6)	13.73 ± 4.53 (10.3-20.5)	0.261
Δ APD (mm)#	3.75 ± 2.04 (0.2-9.4)	4.10 ± 1.83 (0.2-9.0)	0.796
Spinal cord Shift (mm)	2.73 ± 1.19 (0.5-4.9)	3.36 ± 1.68 (0.2-9.8)	0.128
Preoperative Cobb Angle°	13.76 ± 4.76 (11.6-21.8)	12.96 ± 5.06 (6.7-24.1)	0.441
Postoperative Cobb Angle°	21.55 ± 7.89 (7.7-30.4)	20.22 ± 8.84 (12.2-34.2)	0.349
Transverse Diameter of C4/5 foramen (mm)			
Right	3.11 ± 0.89 (1.3-4.8)	3.70 ± 1.58 (1.4-7.2)	0.028
Left	3.46 ± 0.83 (2.2-5.8)	3.63 ± 1.60 (1.0-7.5)	0.006

C4-5 Axial CT scan, spinal canal anterior-posterior diameter.

performed surgery on cases with severe OPLL and kyphosis with anterior cervical surgical options (10). The current study found no significant association between cord shift and the presence of C5 palsy ($p=0.128$). C5 palsy developed in 16/92 (17.3%) patients who underwent surgery due to OPLL. This result was statistically significant ($p<0.001$). However, no correlation was found between cases with OPLL and spinal cord shift ($p=0.503$). In 4/50 (8.0%) cases who underwent surgery due to CSS, C5 palsy appeared to be significant ($p<0.001$). In addition, spinal cord shift was found to be more common in those cases ($p=0.011$). One possible reason may be larger free space for spinal cord movement postoperatively in patients who underwent surgery for CSS. Accordingly, only anterior compression is present in OPLL, whereas additional compression posteriorly due to the presence of ligamentous and bony structure in is present CSS. After the removal of posterior structures, a larger space would be available, allowing the spinal cord to be freed further.

Some studies have proposed a lamina widening angle between 15°–30° and 45°–60° as a factor preventing C5 palsy. Some authors have stated (26) off values such as 53.5° or 60° to prevent C5 palsy (19,20). In our study, lamina widening angles between 14.2° and 62.0° were obtained. We did not observe a significant correlation between the lamina widening angle and the risk of C5 palsy ($p=0.522$). In addition, several studies have indicated male sex as an independent risk factor

for the development of postoperative C5 palsy (23). In our study, 64.4% (117/177) of the total number of patients were male, with the number of male patients with C5 palsy being approximately twice that of female patients. However, these findings were not significant ($p=0.645$).

Reports have shown that C5 palsy may occur due to C4–C5 foraminal stenosis preoperatively (6,7). The literature showed that the average foramen diameter of C4–C5 foramen was 2.3 and 3.3 mm for the C5 palsy and normal groups, respectively (8). Another study found that a foramen diameter of <2.57 mm promoted a 66-fold increase in the risk of C5 palsy (24). In similar studies reported that a C4–C5 foramen diameter of <2.7 mm may increase the risk of C5 palsy postoperatively, whereas another study showed a foraminal diameter (10). In our study, C5 palsy was observed in cases with a foramen diameter of fewer than 3.11 mm on the right side and <3.46 mm on the left. Both values were significant ($p=0.028$, $p=0.006$, respectively). Some studies recommended prophylactic foraminotomy in cases with preoperative foraminal stenosis, whereas others reported that prophylactic foraminotomy may cause C5 palsy (8,10). Our group has never included foraminotomy in any of our cases. Although foraminal stenosis itself is not considered a primary cause of postoperative C5 palsy, it may cause several different pathological processes that could eventually cause damage to sensitive nerve tissue (8). Some studies have concluded that high-intensity zones on T2-weighted MRI may

be associated with C5 palsy (2,13,20). However, Imagama et al. found no relationship between these two (6). In the current study, no significant correlation had been found between the presence of a high-intensity zone above the C4 pedicle level on preoperative T2-weighted MRI and postoperative C5 palsy ($p=0.530$). Furthermore, the mechanism for unilateral neuronal damage caused by the presence of a high-intensity zone on T2-weighted MRI has yet to be clarified.

Wang et al. stated that a preoperative Pavlov ratio of <0.65 or postoperative Pavlov ratio of >1.01 may increase the incidence of postoperative C5 palsy (21). Although our study did not obtain statistically significant results, postoperative Pavlov ratio values were greater compared to preoperative values in all our patients. The mean postoperative Pavlov ratio was found to be higher in the C5 palsy group than in the non-C5 palsy group. Thus, the risk of C5 palsy development was associated with the postoperative Pavlov ratio ($p=0.027$).

Published studies have stated that C5 palsy may develop after direct nerve damage due to the thermal effect resulting from the use of high-speed drills during laminectomy (6,10). However, simultaneous irrigation with warm saline has been found to reduce the risk (17). Given that we used Kerrison rongeur during the laminectomy, none of our cases developed C5 palsy due to the thermal effect.

As stated previously, we were unable to use neuromonitorization during surgery due to the failure of social security reimbursements. Although publications have indicated that C5 palsy, which occurs immediately after surgery, can be detected through intraoperative neuromonitorization, others have indicated the opposite (11,18,19). However, evidence has suggested that C5 palsy, which appeared a few days after surgery, could not be detected via intraoperative neuromonitorization (19). In all of our patients with C5 palsy, the deficit appeared in the early postoperative period.

CONCLUSION

Numerous studies have attempted to use clinical and radiological data to determine the etiology of C5 palsy, which develops after cervical open-door laminoplasty. Notably, reports have shown that cervical posterior and anterior surgical approaches when treating cervical spondylosis promoted higher rates of C5 palsy than cervical open-door laminoplasty (9). In the current study, C4–C5 foraminal diameter was the only important parameter that could predict the development of postoperative C5 palsy. Given our detailed examinations with prospective and experimental studies, clear results could be obtained. However, when compared to other studies in the literature, our C5 palsy rate was at the upper limit. This could have been caused by our inability to use neuromonitorization to detect damages that may have occurred during the positioning of the patients owing to reimbursement failures because of current social security policies.

AUTHORSHIP CONTRIBUTION

Study conception and design: IU, KU

Data collection: ESB, KAS

Analysis and interpretation of results: HEA, CK

Draft manuscript preparation: OK, MS, NY

Critical revision of the article: GG, IDC, MA,

Other (study supervision, fundings, materials, etc...): IK, EC

All authors (IU, GG, IDC, MA, IK, EC, KAS, ESB, KU, HEA, CK, OK, MS, NY) reviewed the results and approved the final version of the manuscript.

REFERENCES

- Chen Y, Chen D, Wang X, Guo Y, He Z: C5 palsy after laminectomy and posterior cervical fixation for ossification of posterior longitudinal ligament. *J Spinal Disord Tech* 20:533-535, 2007
- Chiba K, Toyama Y, Matsumoto M, Maruiwa H, Watanabe M, Hirabayashi K: Segmental motor paralysis after expansive open-door laminoplasty. *Spine (Phila Pa 1976)* 27:2108-2115, 2002
- Cho SK, Kim JS, Overley SC, Merrill RK: Cervical laminoplasty: Indications, surgical considerations, and clinical outcomes. *J Am Acad Orthop Surg* 26:e142-e152, 2018
- Hirabayashi S, Kitagawa T, Yamamoto I, Yamada K, Kawano H: Postoperative C5 palsy: Conjectured causes and effective countermeasures. *Spine Surg Relat Res* 3:12-16, 2019
- Hosono N, Miwa T, Mukai Y, Takenaka S, Makino T, Fuji T: Potential risk of thermal damage to cervical nerve roots by a high-speed drill. *J Bone Joint Surg Br* 91:1541-1544, 2009
- Imagama S, Matsuyama Y, Yukawa Y, Kawakami N, Kamiya M, Kanemura T, Ishiguro N, Nagoya Spine G: C5 palsy after cervical laminoplasty: A multicentre study. *J Bone Joint Surg Br* 92:393-400, 2010
- Katsumi K, Yamazaki A, Watanabe K, Ohashi M, Shoji H: Analysis of C5 palsy after cervical open-door laminoplasty: Relationship between C5 palsy and foraminal stenosis. *J Spinal Disord Tech* 26:177-182, 2013
- Lee HJ, Ahn JS, Shin B, Lee H: C4/5 foraminal stenosis predicts C5 palsy after expansive open-door laminoplasty. *Eur Spine J* 26:2340-2347, 2017
- Li FH, Qiao HH, Yang YC, Du JP, Jin XS, Wang B: Incidence and outcomes of C5 palsy and axial pain after open-door laminoplasty or laminectomy and fusion: A meta-analysis. *World Neurosurg* 128:e1002-e1009, 2019
- Nakajima H, Kuroda H, Watanabe S, Honjoh K, Matsumine A: Risk factors and preventive measures for C5 palsy after cervical open-door laminoplasty. *J Neurosurg Spine*, 2019 (Online ahead of print)
- Nassr A, Eck JC, Ponnappan RK, Zanon RR, Donaldson WF 3rd, Kang JD: The incidence of C5 palsy after multilevel cervical decompression procedures: A review of 750 consecutive cases. *Spine (Phila Pa 1976)* 37:174-178, 2012
- Pavlov H, Torg JS, Robie B, Jahre C: Cervical spinal stenosis: Determination with vertebral body ratio method. *Radiology* 164:771-775, 1987

13. Sasai K, Saito T, Akagi S, Kato I, Ohnari H, Iida H: Preventing C5 palsy after laminoplasty. *Spine (Phila Pa 1976)* 28:1972-1977, 2003
14. Satomi K, Nishu Y, Kohno T, Hirabayashi K: Long-term follow-up studies of open-door expansive laminoplasty for cervical stenotic myelopathy. *Spine (Phila Pa 1976)* 19:507-510, 1994
15. Shinomiya K, Okawa A, Nakao K, Mochida K, Haro H, Sato T, Heima S: Morphology of C5 ventral nerve rootlets as part of dissociated motor loss of deltoid muscle. *Spine (Phila Pa 1976)* 19:2501-2504, 1994
16. Shou F, Li Z, Wang H, Yan C, Liu Q, Xiao C: Prevalence of C5 nerve root palsy after cervical decompressive surgery: A meta-analysis. *Eur Spine J* 24:2724-2734, 2015
17. Takenaka S, Hosono N, Mukai Y, Tateishi K, Fuji T: Significant reduction in the incidence of C5 palsy after cervical laminoplasty using chilled irrigation water. *Bone Joint J* 98-B:117-124, 2016
18. Tanaka N, Nakanishi K, Fujiwara Y, Kamei N, Ochi M: Postoperative segmental C5 palsy after cervical laminoplasty may occur without intraoperative nerve injury: A prospective study with transcranial electric motor-evoked potentials. *Spine (Phila Pa 1976)* 31:3013-3017, 2006
19. Tsuji T, Matsumoto M, Nakamura M, Ishii K, Fujita N, Chiba K, Watanabe K: Factors associated with postoperative C5 palsy after expansive open-door laminoplasty: Retrospective cohort study using multivariable analysis. *Eur Spine J* 26:2410-2416, 2017
20. Uematsu Y, Tokuhashi Y, Matsuzaki H: Radiculopathy after laminoplasty of the cervical spine. *Spine (Phila Pa 1976)* 23:2057-2062, 1998
21. Wang B, Liu W, Shao Z, Zeng X: The use of preoperative and intraoperative pavlov ratio to predict the risk of postoperative c5 palsy after expansive open-door laminoplasty for cervical myelopathy. *Indian J Orthop* 53:309-314, 2019
22. Wang MY, Shah S, Green BA: Clinical outcomes following cervical laminoplasty for 204 patients with cervical spondylotic myelopathy. *Surg Neurol* 62:487-492; discussion 492-483, 2004
23. Wang T, Wang H, Liu S, Ding WY: Incidence of C5 nerve root palsy after cervical surgery: A meta-analysis for last decade. *Medicine (Baltimore)* 96:e8560, 2017
24. Wu FL, Sun Y, Pan SF, Zhang L, Liu ZJ: Risk factors associated with upper extremity palsy after expansive open-door laminoplasty for cervical myelopathy. *Spine J* 14:909-915, 2014
25. Yamasaki Y, Takeuchi K, Numasawa T, Wada K, Itabashi T, Kumagai G, Kudo H, Tanaka S, Asari T, Yokoyama T, Ishibashi Y: Can prophylactic C4/5 foraminotomy prevent C5 palsy after cervical laminoplasty with and without posterior instrumented fusion with maximal expansion? *Eur J Orthop Surg Traumatol* 31:1037-1046, 2021
26. Zhang H, Lu S, Sun T, Yadav SK: Effect of lamina open angles in expansion open-door laminoplasty on the clinical results in treating cervical spondylotic myelopathy. *J Spinal Disord Tech* 28:89-94, 2015