



Endoscopic Endonasal Pituitary Hemi-Rotation Approach to the Upper Clivus: Anatomical Study and Clinical Report

Pierlorenzo VEICESCHI^{1,3}, Alberto D. AROSIO², Edoardo AGOSTI¹, Gianluca AGRESTA¹, Fabio POZZI¹, Sergio BALBI¹, Paolo CASTELNUOVO², Davide LOCATELLI¹

¹University of Insubria, Department of Biotechnology and Life Sciences, Division of Neurosurgery; Ospedale di Circolo e Fondazione Macchi, Varese, Italy

²University of Insubria, Department of Biotechnology and Life Sciences, Division of Otorhinolaryngology; Ospedale di Circolo e Fondazione Macchi, Varese, Italy

³University of Pavia, Scuola di Specializzazione in Neurochirurgia, Pavia, Italy

Corresponding author: Edoardo AGOSTI ✉ edoardo_agosti@libero.it



To watch the surgical videoclip, please visit <http://turkishneurosurgery.org.tr/uploads/jtn-34228-video.mp4>

ABSTRACT

AIM: To report on the endoscopic endonasal pituitary hemi-rotation approach (EPHRA) in a preclinical setting and in a preliminary clinical experience.

MATERIAL and METHODS: EPHRA was performed in five fresh-frozen head and neck specimens (a total of 10 sides) and in a selected case of a right-sided dorsum sellae chordoma.

RESULTS: The approach described allowed exposure of the lateral part of the upper clivus in all the specimens and in the case reported. To evaluate the maximum possible degree of hypophyseal hemi-rotation, the hemi-rotation angle (HRA) of the approach was measured and reported for all sides of the specimens. In 9 out of 10 cadaver head sides, and in the clinical case, it was possible to avoid sectioning of the inferior hypophyseal artery. No complications occurred during or after the procedure.

CONCLUSION: EPHRA represents an addition to the techniques already described and finds indications in case of non-massive neoformations of the lateral upper clivus. Clinical applications and limitations still need to be clarified in further clinical studies.




KEYWORDS: Pituitary, Clivus, Endoscopic endonasal approach, Chordoma


ABBREVIATIONS: **CT:** Computed tomography, **DICOM:** Digital imaging and communications in medicine, **EPHRA:** Endoscopic endonasal pituitary hemi-rotation approach, **HRA(s):** Hemi-rotation angle(s), **HNS&FDRc:** Head and neck surgery & forensic dissection research centre, **ICA:** Internal carotid artery, **IHA:** Inferior hypophyseal artery, **MRI:** Magnetic resonance imaging

INTRODUCTION

In recent years, endoscopic endonasal approaches have become part of the head and neck surgeon armamentarium, supporting or replacing microsurgical transcranial ap-

proaches. The upper clivus remains one of the most difficult regions to access surgically, as critical anatomical structures are present in its surrounding area. Opinions are conflicting on which approach is preferable to reach the upper clivus, al-

Pierlorenzo VEICESCHI  : 0000-0002-0906-8712
Alberto D. AROSIO  : 0000-0002-8916-6562
Edoardo AGOSTI  : 0000-0002-6463-5000

Gianluca AGRESTA  : 0000-0002-3715-1318
Fabio POZZI  : 0000-0001-6016-0573
Sergio BALBI  : 0000-0002-8391-0434

Paolo CASTELNUOVO  : 0000-0002-5184-6140
Davide LOCATELLI  : 0000-0003-1163-9611

though some preclinical anatomical comparison studies have shed more light on this topic (2,5,13). Among the different surgical corridors proposed, the endoscopic endonasal route offers a direct corridor to the clivus without encountering major neurovascular structures. Nevertheless, the pituitary gland is an important anatomical barrier that prevents unhampered access to the interpeduncular cistern and upper clivus, and it must be preserved both anatomically and functionally during endoscopic transnasal surgery. The gland is moderately tolerant to mobilization, and several authors have proposed techniques that entail pituitary dislocation to increase visibility and surgical maneuverability to access the upper clivus (7,12,18). In this study, we described the endoscopic endonasal pituitary hemi-rotation approach (EPHRA), as a modification of the pituitary transposition proposed by Kassam et al. (12), defining for the first time the hemi-rotation angle (HRA) based on both a preclinical experience with five head and neck specimens (ten sides) and a clinical experience of a selected right-sided dorsum sellae chordoma. This study aimed to test EPHRA in preclinical and clinical settings and to share our preliminary experience.

■ MATERIAL and METHODS

This study was performed according to the ethical standards of our institutional review board. All human cadaveric studies were performed according to the ethical standards stated in the 1964 Declaration of Helsinki and its later amendments.

Preclinical Study

Specimens: Endoscopic endonasal dissection was performed on five fresh-frozen head specimens (10 sides). The specimens were injected via common carotid and vertebral arteries with a silicone rubber composed of a base and a catalyst (Xiameter® RTV rubber base and curing agent, Dow Corning®, Midland, MI, USA) colored with red-stained silicon Pintasol® (Mixel® Red E-L3mix, Kirchheim unter Teck, Germany). Each specimen underwent a computed tomography (CT) scan using a multidetector 128-slice scanner (Somatom Definition Flash®, Siemens, Forchheim, Germany). Acquisition was conducted from the vertex to the fifth cervical vertebra. CT parameters included the following: tube tension, 120 kV; tube current, 280 mAs (with dose modulation); and collimation, 0.6 mm. Images were reconstructed at 1 mm (increment: 0.7 mm) with a soft-tissue kernel. Subsequently, each specimen's CT scan was rectified manually using the CT machinery workstation by rotating CT scans on a coronal plane to maintain a parallelism between the two internal acoustic canals, glossopharyngeal canals, and hypoglossal canals. CT scan files were recorded on a digital imaging and communications in medicine (DICOM) format.

Dissection technique: Anatomical dissections were performed at the Head and Neck Surgery & Forensic Dissection Research Centre (HNS&FDRc) of Varese, Italy. A high-definition endoscopic camera with 4-mm 0° Hopkins rod lens endoscopes and a complete set of instruments for endoscopic endonasal skull base surgery (Karl Storz®, Tuttlingen, Germany) was employed.

EPHRA was reproducible in all of the specimens. A transnasal binostril approach via bilateral paraseptal sphenoidotomy was performed, enlarged laterally and rostrally with minimally invasive posterior ethmoidectomy and resection of the superior turbinate tails. Sphenoidal septectomy and mucosectomy were performed, and the bone over the sellar region was drilled out to expose rostrocaudally the superior and inferior intercavernous sinuses and laterally the medial portions of each cavernous sinus. The dural layers overlying the pituitary gland anteriorly were opened without transgressing the pituitary capsule. Once the plane of dissection was reached, the access was widened on the side of interest with a blunt dissection of the lateral sellar compartment, removing the pituitary ligaments connecting the gland to the medial wall of the cavernous sinus. During this step, an inferior hypophyseal artery (IHA) was encountered. Once freed from the ligaments, the gland was gently rotated contralaterally, respecting the integrity of the IHA. The ipsilateral posterior clinoid process was exposed, the interclinoid and petroclinoid ligaments were dissected, and the posterior clinoid was drilled out. Finally, the dura was opened, gaining access to the main neurovascular structures of the interpeduncular and prepontine cistern: basilar artery, posterior cerebral artery, posterior communicating artery, and the interpeduncular segment of the oculomotor nerve (Figure 1A-D) (Video 1).

Measurements: To anatomically evaluate the maximum possible degree of hypophyseal hemi-rotation allowed by an endonasal route (i.e., EPHRA), we introduced a new parameter called HRA, which was identified on the axial CT plane tangent to the cranial margin of the upper clivus and anterior nasal spine. This angle is defined by two lines bounded by the following anatomical landmarks: line A, from the inferolateral limit of the pyriform opening to the posterior clinoid process lateral edge on the side of interest of the specimen; line B, from the contralateral inferolateral limit of the pyriform opening to the median point of the dorsum sellae. The HRA was formed at the posterior crossing point of these two lines. This angle was computed bilaterally in every specimen using the Horos software (Horos Project 2019) on axial CT scan with bone window visualization. The EPHRA depth was defined as the distance between the middle portion of the exposed hemi-upper clivus and the midpoint of the pyriform opening on the same axial plane of the HRA (Figure 2A-C). Finally, HRA degree values and EPHRA depth measurements were recorded in Microsoft Excel 16.16.1®.

Clinical Experience

A 62-year-old woman presented with diplopia associated with right VIth cranial nerve palsy for six months. Given the progressive worsening of symptoms (i.e., deficit of right eye abduction), the patient was referred to our center. Head CT showed lysis of the right half of the dorsum sellae, with loss of cortical bone continuity in the superior-right margin of the upper clivus. Meanwhile, the head magnetic resonance imaging (MRI) revealed the presence of a solid expansive mass (17 mm LL × 18 mm CC × 10 mm AP) characterized by regular margins, with the epicenter at the right side of the dorsum sellae. The mass was pseudocapsulated, homogeneously

hypointense in T1, and in T1 sequence with suppression of the adipose signal, and homogeneously hyperintense in T2, partially suppressed in T2 FLAIR, with ADC values higher than the encephalic parenchyma. After injection of the contrast agent, irregular enhancement was observed. The mass produced a mass effect on the posterolateral side of the adenohypophysis and on the posterior knee of the right cavernous internal carotid artery (ICA) C4 segment, with

minimal dislocation of the neurohypophysis towards the left side. All these radiological features were compatible with chordoma (Figure 3A-H).

After careful discussion with the patient, removal of the lesion through EPHRA was proposed and accepted. The patient was placed in the supine position, with the head fixed in a radiolucent Mayfield head-holder. Surgery was performed under general

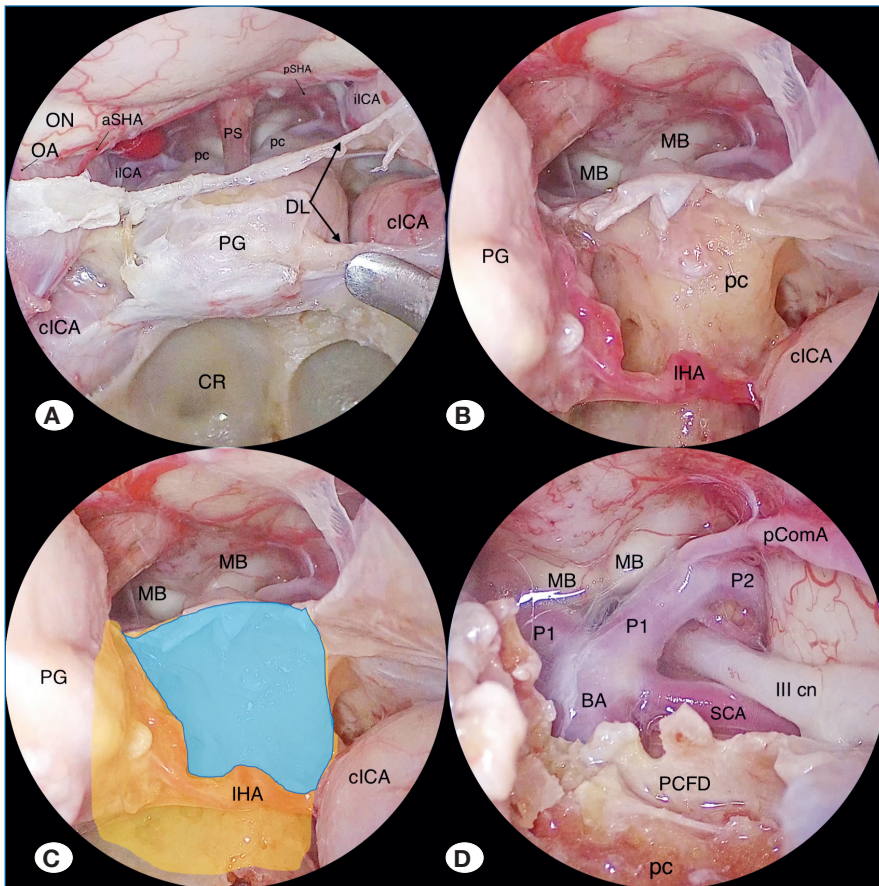


Figure 1: Anatomical study.

A) Pituitary gland and parasellar and suprasellar structures are clearly visualized; **B)** inferior hypophyseal artery is encountered and spared, allowing access to the posterior clinoid region; **C)** area of exposure proven by the EPHRA approach is highlighted (light blue), compared to the wider area of exposure provided by pituitary transposition (orange); **D)** after posterior cranial fossa dura opening, neurovascular structures in pre-pontine cistern are exposed. Legend: aSHA, anterior superior hypophyseal artery; BA, basilar artery; cICA, cavernous internal carotid artery; CR, clival recess; DL, dentate ligaments; IHA, inferior hypophyseal artery; iICA, intracranial internal carotid artery; III cn, oculomotor nerve; MB, mammillary body; OA, ophthalmic artery; OC, optic chiasm; ON, optic nerve; pc, posterior clinoid; P1, P1 tract of posterior cerebral artery; P2, P2 tract of the posterior cerebral artery; PCFD, posterior cranial fossa dura; pComA, posterior communicating artery; PG, pituitary gland; PS, pituitary stalk; pSHA, posterior superior hypophyseal artery; SCA, superior cerebellar artery; SD, sellar diaphragm.

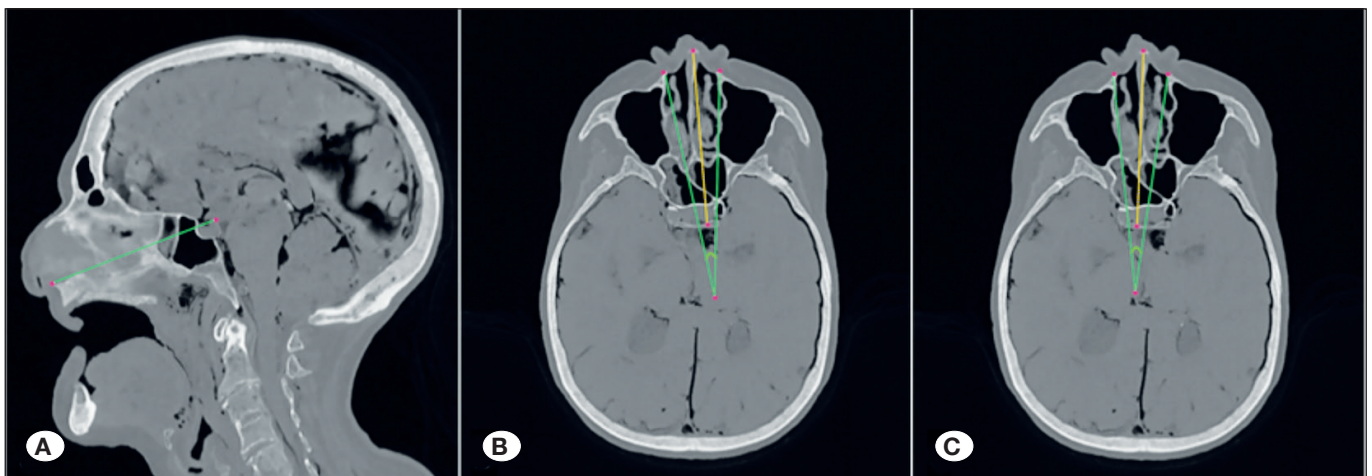

Figure 2: Preclinical measurements. Graphical representation of the EPHRA depth **(A)**, left HRA **(B)**, and right HRA **(C)** on axial CT scan with bone window visualization.

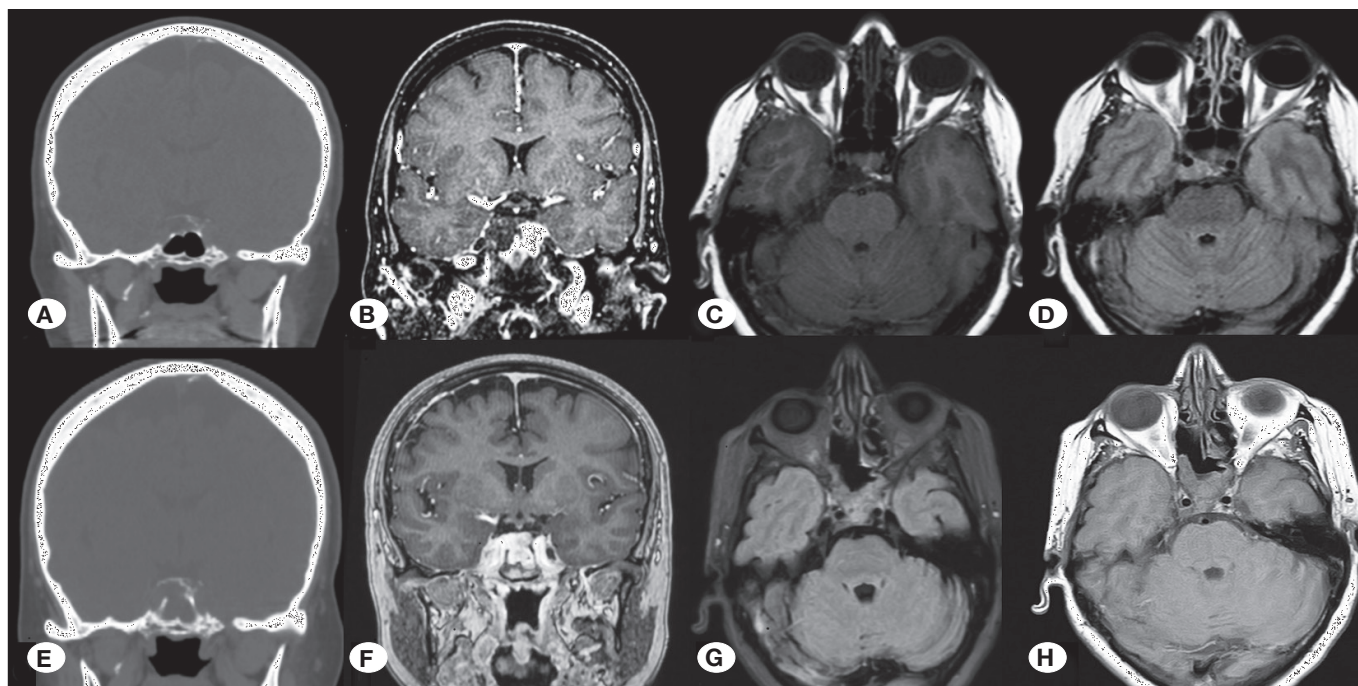


Figure 3: Preoperative and postoperative radiological evaluation. Preoperative CT scan (A) showed the lysis of the right half of the dorsum sellae, with loss of cortical bone continuity in the superior-right margin of the upper clivus. Preoperative MRI showed a contrast-enhanced mass (B), homogeneously hypointense in T1-W images (C), partially suppressed in T2 FLAIR (D), with ADC values higher than the brain parenchyma. A mass effect on the right side of the pituitary gland and on the posterior knee of the right cavernous internal carotid artery (C4), with inferior extension to the middle third of the clivus, was observed. Postoperative CT (E) and magnetic resonance imaging (MRI) (F, G, H) showed complete excision of the neof ormation with no sign of complications or recurrence.

anesthesia. The whole procedure was conducted under endoscopic view (Karl Storz®, Tuttlingen, Germany) using an optic neuronavigation image-guidance system (Medtronic Navigation, Inc. Louisville, CO, USA). The surgery started with the packaging of the nasal cavities with pledges soaked in 2% oxymetazoline, 1% oxybuprocaine, and adrenaline (1/100,000) solution for 10 min. After harvesting a rescue flap on the right side, EPHRA was performed as previously described. After incising the sellar dura, the pituitary gland was dissected from the sellar floor using an intradural technique (12) and gently rotated on the left side. During this maneuver, a long loopy IHA was observed, allowing its preservation during the approach. As a result, the whole preservation of hypophyseal blood supply and the pituitary gland's integrity were achieved, with minimal manipulation of the pituitary gland. The lesion was exposed and appeared as a cystic mass with gelatinous consistency, conditioning the complete replacement of the right posterior clinoid. It was then removed extradurally using curettes and suction instruments. "Endoscopic Diving Technique" (14) was performed in the surgical cavity after tumor resection to check for the complete removal of the lesion, which helped in controlling local bleeding. Satisfying hemostasis was achieved using bipolar forceps, warm water, and hemostatic agents (Flo seal matrix, Baxter Healthcare Corporation, Deerfield, IL, USA). Skull base reconstruction was not performed as the diaphragm sellae and the posterior cranial fossa dura remained intact, and no CSF leak was observed throughout the procedure (Figure 4A-H).

RESULTS

Preclinical Evaluation

In all five specimens, we hemi-rotated the pituitary gland, providing complete exposure of the ipsilateral portion of the upper clivus. Moreover, in 9 out of 10 sides, it was possible to hemi-rotate the pituitary gland to avoid IHA sectioning, while in one case, IHA was not identified.

To define the maximum working space of the EPHRA surgical corridor on the axial plane, we evaluated the following parameters on preoperative CT scans: HRA and EPHRA depth. HRA represents the maximum possible degree of hypophyseal hemi-rotation allowed by an endonasal route with complete exposure of the ipsilateral upper clivus, while EPHRA depth represents the distance of the surgical target (i.e., the superior aspect of the upper clivus) from the pyriform opening.

The values of the 10 HRAs and EPHRA depths calculated on the axial CT scan are listed in Table I. Among HRAs, the minimum value is 13.50°, the maximum value is 14.30°, and the mean value is 13.85° ($\pm 0.39^\circ$); among the EPHRA depths, the minimum value is 7.3 cm, the maximum value is 9.8 cm, and the mean value is 8.36 cm (± 0.63 cm).

Clinical Evaluation

A definitive histological examination was compatible with chordoma. Immunohistochemical staining revealed diffuse

Table I: Left and Right HRAs and EPHRA Depths Measurements

	Left HRA	Right HRA	Left EPHRA depth	Right EPHRA depth
Specimen #1	13.5°	13.6°	8.5 cm	8.6 cm
Specimen #2	14.3°	14.5°	7.3 cm	7.5 cm
Specimen #3	13.4°	13.3°	7.9 cm	8.0 cm
Specimen #4	14.2°	14.0°	8.2 cm	8.1 cm
Specimen #5	14.2°	13.5°	9.7 cm	9.8 cm

HRA: Hemi-rotation angle, **EPHRA:** Endoscopic endonasal pituitary hemi-rotation approach.

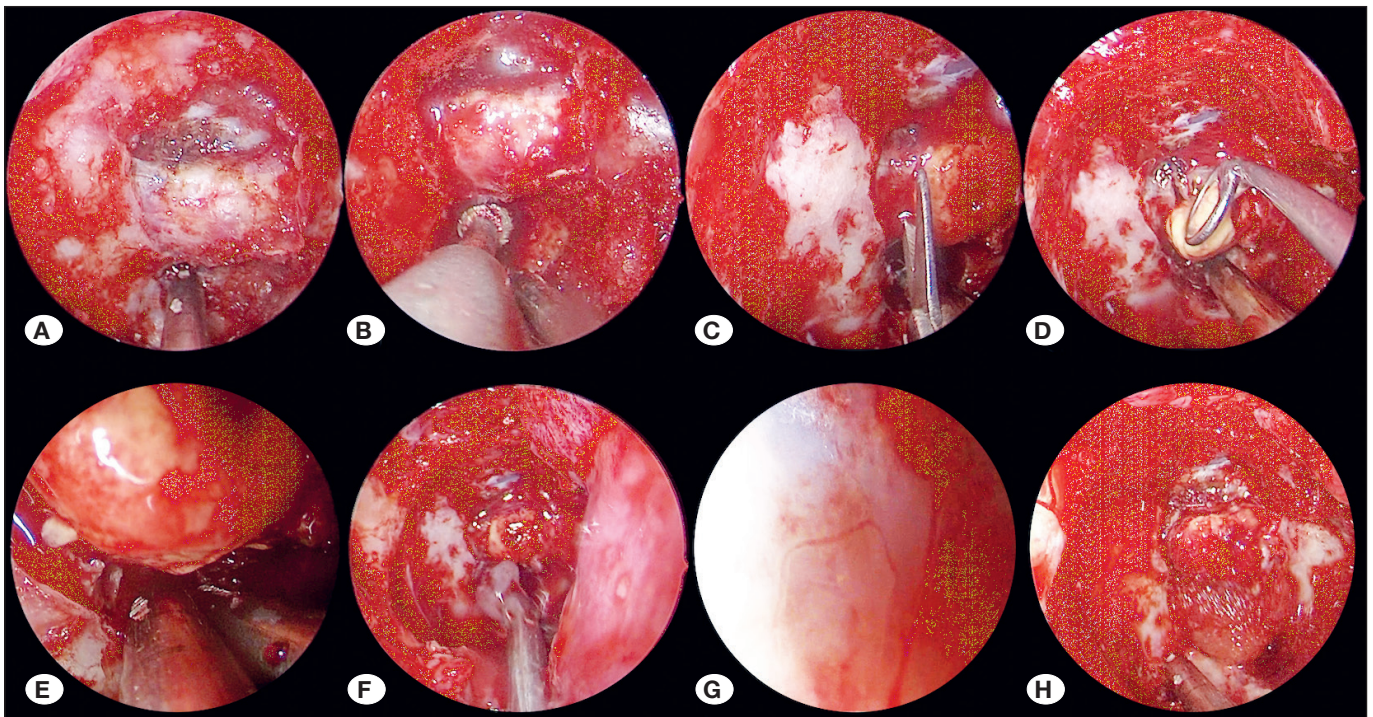


Figure 4: Surgical intervention – step by step. Exposing the pituitary gland (A); drilling the upper clivus (B); cutting the pituitary ligaments (C); pituitary hemi-rotation using blunt curettes (D); visualizing and sparing the inferior hypophyseal artery, white asterisk (E); removing the chordoma (F); endoscopic diving technique allowing the hydro-dissection of tumor remnants and finally visualizing the posterior fossa dura at the level of the posterior clinoid process, proving dural integrity (G); no CSF leak occurs; thus, reconstruction is performed only with fibrin glue.

positive reactions for CKAE1/AE3, CK8/18/19, and S-100. The Ki-67 labeling index was found to be 1%. In addition, the postoperative course was unremarkable. A basal brain CT scan documented regular surgical results without perioperative complications. Serial endoscopic evaluations performed during the postoperative period also documented the absence of bleeding or rhinoliquorrhea. The patient was discharged on the 6th post-operative day.

The clinical evaluation performed after 12 months confirmed the positive result obtained through the surgery: the patient reported clinical well-being, with complete recovery of the right ocular movements and consequent resolution of the diplopia. No diabetes insipidus or pituitary deficits were observed. Follow-up MRI at 12 months showed complete resection of the lesion (Figure 3A-H).

DISCUSSION

Critical anatomical structures interpose between the surgeon and the upper clivus, regardless of the approach chosen, making this region one of the most difficult areas to access. Several transcranial approaches have been described (6,16,17,23), but they often require modified or large craniotomies, brain retraction, and manipulation of neurovascular structures; thus, these approaches entail a considerably high risk of approach-related complications (1). The endoscopic endonasal transsphenoidal route takes advantage of the natural midline corridor to approach this anatomical region, avoiding the oculomotor nerve and the posterior communicating artery during dissection (8-13). Moreover, the binostriil-four hands technique offers an excellent capacity to perform the endoscopic endonasal surgery, with no conflicts between surgeons (3).

Table II: Comparison of Endoscopic Transsphenoidal Approaches to Upper Clivus Reported in Literature

	Kassam (12)	Silva (18)	Fernandez-Miranda (7)	EPHRA
Number of cases	10 patients	5 cadaver heads	10 cadaver heads, 12 patients	5 specimens
Corridor	Intradural	Extradural	Interdural (transcavernous)	Intradural
IHA Section	Bilateral	NA	Unilateral	None / unilateral
Bleeding	++	NA	++++	++
Functional damage*	12.5%	NA	0%	0%

* Permanent hypopituitarism or diabetes insipidus

IHA: Inferior hypophyseal artery; **NA:** not applicable.

The pituitary gland represents an anatomical barrier that prevents full access to the upper clival region (4,8). Hypophysis can tolerate a delicate mobilization; thus, many authors have described various techniques to access this region, foreseeing a certain dislocation of the gland itself (Table II). These techniques vary according to the corridor used with regard to the dural layers lining the sellar region (12). The two dura layers (meningeal and periosteal) cover the pituitary gland anteriorly and separate from each other at the lateral margin of the sella. The outer layer covers the anterior or sphenoidal wall of the cavernous sinus, and the inner layer runs backward to the posterior clinoid and dorsum sellae to form the medial or sellar wall of the cavernous sinus (15). The superior, inferior, and posterior intercavernous sinuses are spaces enveloped by the meningeal and periosteal layers of the dura, thus explaining the copious venous bleeding that occurs when dissecting between these layers (22).

Kassam et al. were the first to describe the intradural pituitary transposition to reach the interpeduncular cistern area through a transdorsum sellae and posterior clinoidectomy approach (12). This elegant and technically challenging surgical maneuver has been widely used and has been providing good access to this region. However, it requires the bilateral manipulation of the pituitary gland with the risk of disruption of its venous drainage, as well as the bilateral sacrifice of the inferior hypophyseal arteries. Silva et al. proposed an extradural route to access the area with superior mobilization of the gland while still covered by both dural layers (19); with respect to the intradural variant, dural layers in this case are used as a natural protector of neurovascular structures of the sellar and parasellar regions. This technique might therefore be less invasive than the intradural approach, but it might also provide limited access to the dorsum sellae and posterior clinoids (7), sometimes requiring conversion into an intradural approach (19).

Fernandez-Miranda et al. described another surgical variant for endonasal posterior clinoidectomy, which does not require intradural pituitary rotation, and found that this technique is more effective than the extradural approach in exposing the interpeduncular cistern area (7). This variant takes advantage of the natural corridor represented by the cavernous sinus to access the posterior clinoid and mobilize the pituitary gland in an interdural fashion. Unfortunately, it entails the main disadvantage of a copious blood loss due to the direct

transcavernous approach; therefore, great endoscopic surgical expertise and familiarity with hemostatic agents are absolutely unavoidable to perform this type of surgical approach. Moreover, the authors observed that the cavernous ICA might occasionally be adherent to the medial wall of the cavernous sinus, which poses more difficulties in adopting the transcavernous corridor.

In this study, we described and performed EPHRA preclinically and clinically, defining and measuring the HRA and surgical corridor width for the first time in a preclinical setting. This approach represents a formal modification of the technique described originally by Kassam et al. involving the same corridor and providing unilateral exposure of the upper clivus (12). However, the hemi-rotation technique, compared to the classic pituitary transposition, reduces the intraoperative surgical manipulation of the pituitary gland, which seems to be the factor that most affects postoperative pituitary functionality (21). However, this entails a reduced exposure of the upper clivus, which demands a careful preoperative evaluation to adopt EPHRA; for lesions located in the lateral portion of the upper clivus, the gland is unilaterally freed from the parasellar ligaments and is then rotated and moved contralaterally, exposing the ipsilateral posterior clinoid and the lateral portion of the dorsum sellae. In this area, the main vascular structure encountered is the IHA, which is usually sacrificed during endoscopic endonasal approaches with upper exposure and removal (Table II). Although a clinical study highlighted that the bilateral coagulation of IHAs does not cause pituitary dysfunction in most patients (21), some cases of anterior and posterior hypopituitarism can be found (20,21). It is possible to assume that the association of less mobilization of the pituitary gland with the preservation of both IHAs can lead to a further reduction in postoperative hypopituitarism.

During the anatomical dissection, we were able to preserve 9 out of 10 IHAs, achieving in all cases an adequate exposure of the retrosellar region, as demonstrated in the surgical video. Obviously, validation on a larger scale is necessary to evaluate the actual benefits. Nonetheless, EPHRA opens a surgical window on the upper clivus ipsilateral to the hemi-rotated pituitary. In cases of lesions with contralateral or complete extension to the dorsum sellae, it is always possible to convert EPHRA into a standard hypophysiopexy approach at any time of the surgical procedure, according to need.

CONCLUSION

Modern skull base neurosurgery is rapidly evolving, and surgical approaches are now progressively tailored for each patient. The technique proposed here represents a less invasive variant than the ones already described in the literature and finds indications in cases of non-massive neoformations of the lateral retrosellar area. In these selected cases, a unilateral approach between the pituitary gland and lateral sellar wall can be feasible, avoiding complete pituitary transposition and reducing the possible risk of postoperative hypophyseal functional damage. Clinical applications and limitations still need to be clarified in further clinical studies.

ACKNOWLEDGEMENTS

We thank the Research Center for Pituitary Adenomas and Sellar Pathology and the Head and Neck Surgery & Forensic Dissection Research Centre (HNS&FDRc) for their support to the realization of this study.

AUTHORSHIP CONTRIBUTION

Study conception and design: PV, ADA, EA, PC, DL

Data collection: PV, ADA, EA

Analysis and interpretation of results: PV, ADA, EA, GA

Draft manuscript preparation: PV, ADA, EA

Critical revision of the article: PV, ADA, EA, GA, FP, SB, PC, DL

All authors (PV, ADA, EA, GA, FP, SB, PC, DL) reviewed the results and approved the final version of the manuscript.

REFERENCES

- Abuzayed B, Tanriverdi N, Gazioglu N, Kafadar AM, Akar Z: Endoscopic anatomy of the oculomotor nerve: Defining the blind spot during endoscopic skull base surgery. *Childs Nerv Syst* 26(5):689–696, 2010
- Agosti E, Saraceno G, Qiu J, Buffoli B, Ferrari M, Raffetti E, Belotti F, Ravanelli M, Mattavelli D, Schreiber A, Hirtler L, Rodella LF, Maroldi R, Nicolai P, Gentili F, Kucharczyk W, Fontanella MM, Doglietto F: Quantitative anatomical comparison of transnasal and transcranial approaches to the clivus. *Acta Neurochir (Wien)* 162(3):649–660, 2020
- Castelnuovo P, Pistochini A, Locatelli D: Different surgical approaches to the sellar region: Focusing on the “two nostrils four hands technique”. *Rhinology* 44(1):2-7, 2006
- Cavallo LM, Messina A, Cappabianca P, Esposito F, de Divitiis E, Gardner P, Tschabitscher M: Endoscopic endonasal surgery of the midline skull base: Anatomical study and clinical considerations. *Neurosurg Focus* 19(1):E2, 2005
- Doglietto F, Ferrari M, Mattavelli D, Belotti F, Rampinelli V, Kheshaifati H, Lancini D, Schreiber A, Sorrentino T, Ravanelli M, Buffoli B, Hirtler L, Maroldi R, Nicolai P, Rodella LF, Fontanella MM: Transnasal endoscopic and lateral approaches to the clivus: A quantitative anatomical study. *World Neurosurg* 113:e659–e671, 2018
- Dolenc VV, Škrap M, Šušteršič J, Škrbec M, Morina A: A transcavernous-transsellar approach to the basilar tip aneurysms. *Br J Neurosurg* 1(2):251-259, 1987
- Fernandez-Miranda JC, Gardner PA, Rastelli MM, Peris-Celda M, Koutourousiou M, Peace D, Snyderman CH, Rhoton AL: Endoscopic endonasal transcavernous posterior clinoidectomy with interdural pituitary transposition. *J Neurosurg* 121(1):91-99, 2014
- Gunaldi O, Kina H, Tanriverdi O, Erdogan U, Postalci LS: Endoscopic endonasal transclival resection of the upper clival meningioma. *Türk Neurosurg* 28(3):505-509, 2018
- Kahilogullari G, Eroglu U, Yakar F, Beton S, Mecoc C, Caglar YS: Endoscopic endonasal approaches to craniovertebral junction pathologies: A single-center experience. *Türk Neurosurg*, 2018 (Online ahead of print)
- Kassam A, Snyderman CH, Mintz A, Gardner P, Carrau RL: Expanded endonasal approach: The rostrocaudal axis. Part I. Crista galli to the sella turcica. *Neurosurg Focus* 19(1):E3, 2005
- Kassam A, Snyderman CH, Mintz A, Gardner P, Carrau RL: Expanded endonasal approach: The rostrocaudal axis. Part II. Posterior clinoids to the foramen magnum. *Neurosurg Focus* 19(1):E4, 2005
- Kassam AB, Prevedello DM, Thomas A, Gardner P, Mintz A, Snyderman C, Carrau R: Endoscopic endonasal pituitary transposition for a transdorsum sellae approach to the interpeduncular cistern. *Neurosurgery* 62(3):ONS57–ONS74:57–72; discussion 72, 2008
- Kilinc MC, Basak H, Coruh AG, Mutlu M, Guler TM, Beton S, Comert A, Kahilogullari G: Endoscopic anatomy and a safe surgical corridor to the anterior skull base. *World Neurosurg* 145:e83–e89, 2021
- Locatelli D, Canevari FR, Acchiardi I, Castelnuovo P: The endoscopic diving technique in pituitary and cranial base surgery: Technical note. *Neurosurgery* 66(2):E400-401; discussion E401, 2010
- Peker S, Kurtkaya-Yapici O, Kiliç T, Pamir MN: Microsurgical anatomy of the lateral walls of the pituitary fossa. *Acta Neurochir (Wien)* 147(6):641-648; discussion 649, 2005
- Salma A, Wang S, Ammirati M: Extradural endoscope-assisted subtemporal posterior clinoidectomy: A cadaver investigation study. *Neurosurgery* 67(3):ons43-48; discussion ons48, 2010
- Seoane E, Tedeschi H, de Oliveira E, Wen HT, Rhoton AL: The pretemporal transcavernous approach to the interpeduncular and prepontine cisterns: Microsurgical anatomy and technique application. *Neurosurgery* 46(4):891-898; discussion 898, 2000
- Silva D, Attia M, Kandasamy J, Alimi M, Anand VK, Schwartz TH: Endoscopic endonasal posterior clinoidectomy. *Surg Neurol Int* 3(1):64, 2012
- Silva D, Attia M, Schwartz TH: Endoscopic endonasal posterior clinoidectomy. *J Neurosurg* 122(2):478-479, 2015
- Taussky P, Kalra R, Coppens J, Mohebbi J, Jensen R, Couldwell WT: Endocrinological outcome after pituitary transposition (hypophysopexy) and adjuvant radiotherapy for tumors involving the cavernous sinus. *J Neurosurg* 115(1):55-62, 2011

21. Truong HQ, Borghei-Razavi H, Najera E, Igami Nakassa AC, Wang EW, Snyderman CH, Gardner PA, Fernandez-Miranda JC: Bilateral coagulation of inferior hypophyseal artery and pituitary transposition during endoscopic endonasal interdural posterior clinoidectomy: Do they affect pituitary function? *J Neurosurg* 131(1):141-146, 2018
22. Truong HQ, Lieber S, Najera E, Alves-Belo JT, Gardner PA, Fernandez-Miranda JC: The medial wall of the cavernous sinus. Part 1: Surgical anatomy, ligaments, and surgical technique for its mobilization and/or resection. *J Neurosurg* 131(1):122-130, 2019
23. Youssef AS, van Loveren HR: Posterior clinoidectomy: Dural tailoring technique and clinical application. *Skull Base* 19(3):183-191, 2009