

Distal Posterior Cerebral Artery (Calcarine) Aneurysm

NUR ALTINÖRS, ZAFER KARS, CENGİZ ÇEPOĞLU, LEVENT GÜRSES

Department of Neurosurgery, Social Security Hospital, Ankara, Türkiye

Abstract : A patient harboring a distal posterior cerebral artery aneurysm is presented. The aneurysm located on the right calcarine artery was totally excised. So far only two cases with such a distal

aneurysm of PCA have been published. This very rare anatomic site for an aneurysm and the related literature are reviewed.

Key words : Aneurysm, posterior cerebral artery

INTRODUCTION

Posterior cerebral artery aneurysms are rare. They comprise 0.6 to 2.2 % of all intracranial and 7 to 15 % of all vertebro-basilar aneurysms (12,15,20,24). Aneurysms arising from the distal portion of this artery represent even a more rare pathologic condition. Only 13 % of all PCA aneurysms are considered to be distal to the posterior temporal branch or the P3 segment (26).

CASE REPORT

This 18-year-old girl was admitted to our clinic because of a sudden and severe headache followed by bouts of vomiting. Lumbar puncture performed by the first consulting physician on the same day of the attack revealed bloody CSF with moderately increased pressure. Her medical history included attacks of rheumatic fever treated with penicilline.

A pansystolic 3/6 grade murmur was heard on physical examination. Neurologic examination revealed (+++++) neck stiffness and left homonymous hemianopsia. Laboratory findings were as follows: ESR 30mm/hr, ASO 400 Todd Units, CRP (+++). Latex, Rheumatoid factor and ANA were negative. Throat, blood, CSF and urine cultures were negative. ECG was normal.

CT (Fig.1) showed hemorrhage in the lateral, third and fourth ventricles and also in the subependyma.

Distortion of the right lateral ventricle was noted. A hyperdense lesion suggesting hematoma and measuring 44x50 mm could be followed from the occipital horn of the right ventricle up to the vertex. A right carotid arteriography (Fig.2A and 2B) revealed an

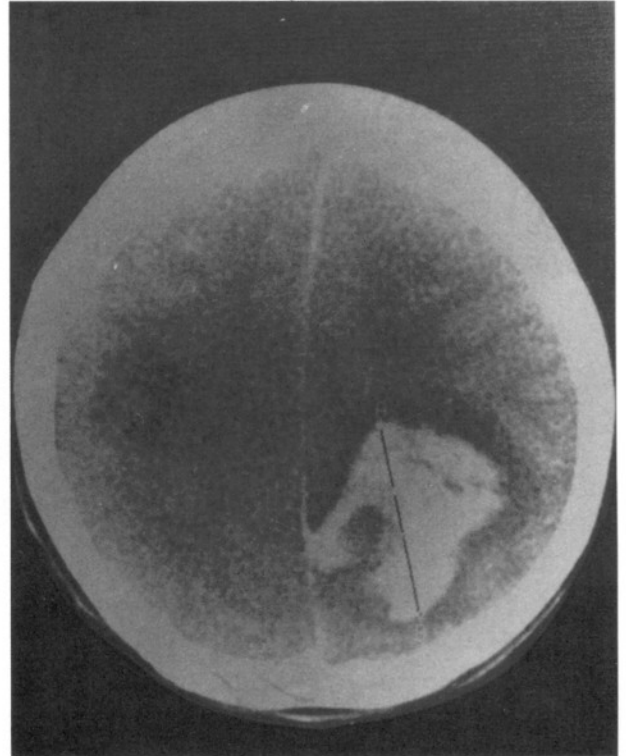


Fig. 1 : CT photo showing a large right occipital hematoma.

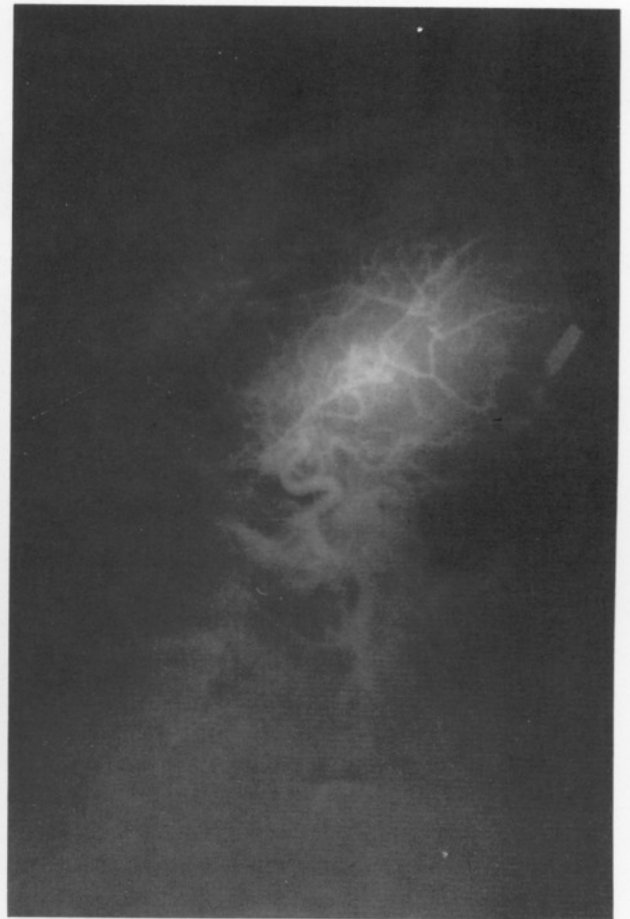
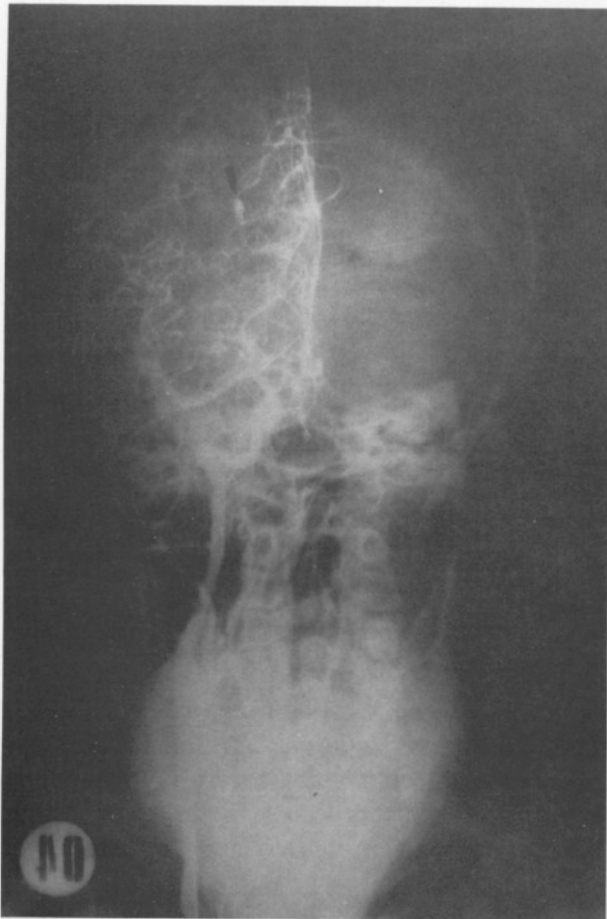


Fig. 2a, b : A-P and lateral photos of the right carotid arteriography showing an aneurysm on the final distal branch of the PCA (arrow).

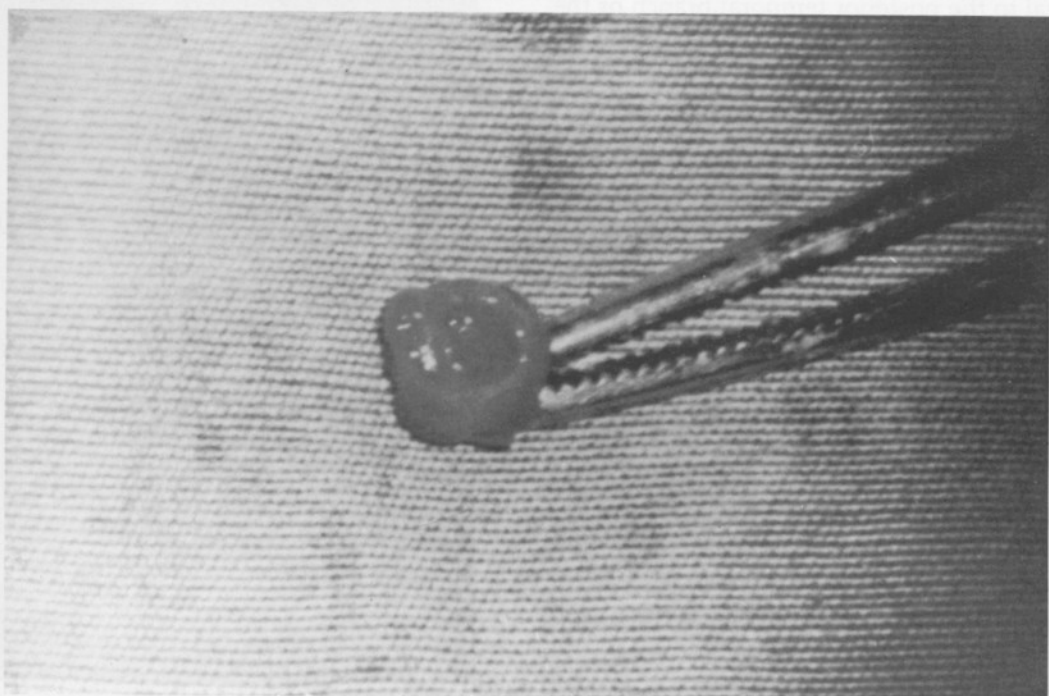


Fig. 3 : The aneurysmal sac after its total excision. The ruptured area on the wall is noted.

aneurysm distal to the last bifurcation of the posterior cerebral artery. The aneurysm was a terminal one located on the calcarine artery. Occipital craniotomy was performed. Interhemispheric and suboccipital extramedullary exploration revealed no pathology. A cortical incision 2 cm. above the tentorium and 2 cm. off the midline was made. Hematoma was reached within 5-6 mm. and was totally evacuated. After a very limited occipital lobe resection, the aneurysm was identified, dissected and totally excised (Fig.3). The histopathologic evaluation of the aneurysm sac showed no inflammation on the wall. The patient did well postoperatively. No neurologic deficit was added. She was discharged on the tenth postoperative day and control four-vessel angiography 40 days after discharge was completely normal.

DISCUSSION

PCA aneurysms are classified into four subdivisions with regard to the segment of the PCA from which they arise. P4, the most distal segment, represents the final bifurcation of the PCA into its parietal and calcarine branches (18,25).

Pia (19,20) has proposed a more detailed classification for the aneurysms of PCA. It includes six anatomical sites. P5 represents aneurysms located on the bifurcation of the PCA (internal occipital/posterior temporal), posterior pericallosal/internal occipital and internal occipital/posterior posterolateral choroidal. P6 includes aneurysms located on the calcarine/parieto-occipital arteries.

Our case belongs to subgroup P6 according to the above mentioned classification and the review of the literature has revealed only two previously described similar cases in this very unusual site (13,20). Some authors have published their surgical experience and the results of PCA aneurysms (5-7,12,13,17,20-23,25). Several surgical techniques have been employed in the treatment of PCA aneurysms. Clipping of the saccular, trapping and proximal ligation of the fusiform or giant aneurysms and muscle wrapping in others have been the preferred surgical techniques. Simple excision of the terminal artery aneurysm (13) and excision followed by end-to-end anastomosis of P2 aneurysm (5) have also been reported. Congenital saccular aneurysms constitute the majority of the distal PCA aneurysms. Mycotic, traumatic and aberrant vestigial anastomoses have been encountered as less frequent responsible pathologies (4,8,14).

Attacks of rheumatic fever, a pansystolic murmur and localization of the aneurysm in the present case may raise the suspicion of a mycotic aneurysm. On the other hand splenomegaly, petechiae, microscopical hematuria and fever, all of which should be searched for a diagnosis of endocarditis (3,21), were not present in our case. All cultures were negative and leucocytosis was not present. Moreover, pathologic examination of the excised aneurysm did not confirm an inflammatory process which led us to accept this aneurysm as a congenital one. Bingham (1) has drawn attention to the fact that not all distal aneurysms, not even multiple peripheral lesions, are necessarily mycotic.

Even assuming our case as a mycotic aneurysm would not have changed the decision for surgery, because there is consensus about the surgical therapy of ruptured mycotic aneurysms. Mortality rates of 53 and 75 % have been mentioned respectively in mycotic aneurysms treated only with antibiotics and which have finally ruptured (2,9). Similar experience was shared by other authors as well (1,11,16). The rationale for antibiotic therapy alone stems from angiographic demonstration of either diminishing or complete resolving of some bacterial aneurysms (2). Overall surgical mortality in bacterial aneurysms is 26.5 % and it drops to 6.25 % in elective surgical cases (10). The standard surgical approach for P1 and P2 aneurysms is via subtemporal route while occipital craniotomies are needed for more distal P3 and P4 aneurysms (25).

When we compare our patient with the other two examples of P6 aneurysm (Pia classification) we notice that all of them have ruptured. Pia's patient was in a worse neurologic condition in contrast to our case and Ishikawa's, both presenting with hemianopsia as the only neurologic finding. No mention of CT is made in those other two cases. CT is valuable only in showing the presence of hematoma as in our patient, but fails to detect bacterial aneurysms. Endocarditis was diagnosed in Ishikawa's patient. The surgical therapy in that case consisted of hematoma evacuation and aneurysm resection which was also accomplished in our patient. In Pia's patient only occipital lobe resection was performed. In cases of failure to clip or to excise such distal PCA aneurysms, sacrificing the parent vessel seems less hazardous with respect to postoperative neurologic complications mainly due to the rich blood supply of the area for which the PCA is the principal feeder.

Correspondence : Dr. Nur Altınörs
Kızılırmak Sokak, 17/9
Bakanlıklar 06640 Ankara, Türkiye
Tel : 90 312 425 24 41

REFERENCES

1. Bingham WF: Treatment of mycotic aneurysms. *J Neurosurg* 46:428-437, 1977
2. Bohmfalk GL, Story JL, Wissinger JP, Brown WEB: Bacterial intracranial aneurysm. *J Neurosurg* 48:369-382, 1978
3. Brackett CE, Morantz RA: Mycotic aneurysms. Youmans JR (Ed), in *Neurological surgery*. Vol 3, Philadelphia: WB Saunders, 1982, 1812-1814
4. Burton C, Velasco F, Dorman J: Traumatic aneurysm of a peripheral cerebral artery. Review and case report. *J Neurosurg* 28:468-474, 1968
5. Chang HS, Fukushima T, Miyazaki S, Tamagawa T: Fusiform posterior cerebral artery aneurysm treated with excision and end-to-end anastomosis. *J Neurosurg* 64:501-504
6. Chou SN, Ortiz-Suarez HJ: Surgical treatment of arterial aneurysms of the vertebrobasilar circulation. *J Neurosurg* 41:671-680, 1974
7. Drake CG, Amacher AL: Aneurysms of the posterior cerebral artery. *J Neurosurg* 30:468-474, 1969
8. Drennan AM: Aneurysms of the larger cerebral vessels. *NZ Med J* 20:324-349, 1921
9. Frazee JG, Cahan LD, Winter J: Bacterial intracranial aneurysms. *J Neurosurg* 53:633-641, 1980
10. Frazee JG: Inflammatory intracranial aneurysms. Wilkins RH, Rengachary SS (eds), in *Neurosurgery*. Vol 2, New-York: McGraw-Hill, 1985:1440-1443
11. Hourihane JB: Ruptured mycotic intracranial aneurysm. A report of three cases. *Vasc Surg* 4:21-29, 1970
12. Hunt WE, Hess RM: Aneurysm of the posterior cerebral artery with unexpected postoperative neurologic deficit. Case report. *J Neurosurg* 26:633-635, 1967
13. Ishikawa M, Wega S, Moritake K, Handa H: Cerebral bacterial aneurysms, report of three cases. *Surg Neurol* 2:257-261, 1974
14. Lemmen LJ, Scheider RC: Aneurysms in the third ventricle. *Surg Neurol* 2:257-261, 1974
15. Locksley HB: Report of the Cooperative study of Intracranial Aneurysms and Subarachnoid Hemorrhage. Section V, Part 1. Natural history of subarachnoid hemorrhage, intracranial aneurysms and arterio-venous malformations based on 6368 cases in the Cooperative Study. *J Neurosurg* 25:219-239, 1966
16. Morin MA, Talalla A: Angiography for mycotic aneurysm. *N Eng J Med* 281:1249-1250, 1969 (letter)
17. Obrador S, Dierssen G, Hernandez JR: Giant aneurysm of the posterior cerebral artery. *J Neurosurg* 26:413-416, 1967
18. Peerless SJ, Drake CG: Posterior circulation aneurysms. Wilkins RH, Rengachary SS (eds), in *Neurosurgery*. Vol 2, New-York: McGraw-Hill, 1985:1422-1439
19. Pia HW, Fontana H: Aneurysm of the posterior cerebral artery. Locations and clinical pictures. *Acta Neurochir* 38:13-35, 1977
20. Pia HW: Classification of vertebro-basilar aneurysms. *Acta Neurochir* 47:3-30, 1979
21. Roach MR, Drake CG: Ruptured cerebral aneurysms caused by micro-organisms. *N Eng J Med* 273:240-244, 1965
22. Schaeffer HR: Aneurysms of the posterior cerebral artery. *Med J Austr* 1:632-633, 1964
23. Simpson RK JR, Parker WD: Distal posterior cerebral artery aneurysm. Case report. *J Neurosurg* 64:669-672, 1986
24. Suzuki J, Hori S, Sakurai Y: Intracranial aneurysms in the neurosurgical clinics in Japan. *J Neurosurg* 35:34-39, 1971
25. Yasargil MG: Posterior cerebral artery aneurysms. Vol 2 *Microneurosurgery*. Georg Thieme Verlag, 1984:260-269
26. Zeal AA, Rhoton AL Jr: Microsurgical anatomy of the posterior cerebral artery. *J Neurosurg* 48:534-559, 1978