



Long-Term Outcomes of Pediatric Meningioma Surgery: Single Center Experience with 23 Patients

Ilkay ISIKAY¹, Sahin HANALIOGLU¹, Firat NARIN², Ibrahim BASAR³, Burcak BILGINER¹

¹Hacettepe University School of Medicine, Department of Neurosurgery, Ankara, Turkey

²Van Yuzuncuyil Training and Research Hospital, Neurosurgery Clinic, Van, Turkey

³Dicle University School of Medicine, Department of Neurosurgery, Diyarbakir, Turkey

This study has been presented at the 43rd Annual Meeting of the ISPN between 4 and 8 October 2015 at Izmir, Turkey

Corresponding author: Ilkay ISIKAY ✉ isikay@hacettepe.edu.tr

ABSTRACT

AIM: To evaluate the long-term outcomes and prognostic variables in a surgical cohort of pediatric meningiomas treated in a single institution.

MATERIAL and METHODS: Medical records and follow-up notes of 23 pediatric patients aged <18 years (12 male and 11 female; mean age on presentation, 13.1 ± 4.4 years) harboring 27 meningiomas operated between 1994 and 01/2019 at Hacettepe University Ihsan Dogramaci Children's Hospital were evaluated.

RESULTS: One patient had neurofibromatosis (NF) type 1, and five patients had NF2. Tumors were most commonly located in the convexity (n=6) and parasagittal or falx (n=6). Gross total resection was performed in 70.4% of cases. WHO grade I tumors accounted for 56% of all cases, whereas high-grade meningiomas accounted for 44% (33% grade II, 11% grade III). The mean follow-up duration was 10.3 ± 7.7 years. Three patients (13%) died during follow-up, and 76.2% of the patients had favorable outcome (Glasgow Outcome Scale > 3) during the last follow-up assessment. Ten patients (43.5%) had relapse. In univariate analysis, low histological grade (p=0.030) and gross total resection (p=0.024) were associated with favorable outcome. The 10-year overall survival rate was 86%.

CONCLUSION: Meningiomas in the pediatric age group are surgically treatable tumors with fairly good outcomes. However, relapses are common even for low-grade tumors; therefore, long-term surveillance and aggressive treatment are needed.

KEYWORDS: Meningioma, Childhood, Surgery, Outcome, Recurrence

ABBREVIATIONS: CNS: Central nervous system, DWI: Diffusion-weighted imaging, GOS: Glasgow Outcome Scale, ICP: Intracranial pressure, NF: Neurofibromatosis, WHO: World Health Organization

INTRODUCTION

Meningiomas are a relatively rare tumor type in pediatric and adolescent patients. In adults, meningiomas are the most common primary intracranial tumors that constitute approximately 30% of the cases, whereas it only makes up 0.4%–4.6% cases in the pediatric or adolescent

age group (15). Because of its rarity, knowledge about this tumor type is derived mostly from small case series and individual reports. A systematic review of published series identified epidemiologic features, clinical characteristics, survival outcomes, and main differences of this rare tumor type from its adult counterparts (15).

Ilkay ISIKAY : 0000-0001-7790-4735
Sahin HANALIOGLU : 0000-0003-4988-4938
Firat NARIN : 0000-0002-5985-4460

Ibrahim BASAR : 0000-0003-3674-4864
Burcak BILGINER : 0000-0001-9667-3709

In contrast to other childhood central nervous system (CNS) tumors (3,13), prognosis and survival are better for pediatric or adolescent meningiomas (10,15,18). There is paucity of reports on pediatric meningioma cases that report long-term survival data in the magnetic resonance imaging (MRI) era. Thus, this study aimed to identify epidemiological and clinicoradiological features, short- and long-term outcomes, as well as prognostic factors affecting favorable results in pediatric meningioma based on a 25-year experience of a single center.

■ MATERIAL and METHODS

Admission and discharge notes of pediatric patients (patient age less than 18 years at the time of first admission) with intracranial or spinal meningiomas who were surgically treated at Department of Neurosurgery, Hacettepe University Ihsan Dogramaci Children's Hospital between 1994 and 01/2019 were reviewed, and follow-up visit notes were evaluated. The variables analyzed were age, sex, clinical presentation, as well as association with neurofibromatosis, extent of resection, and tumor histology or grade. Simpson grades I-III were accepted as gross total resection, whereas Simpson grade IV was deemed subtotal resection. Radiological workup, particularly the MRI scans of these patients, was reassessed in terms of tumor location, size, and enhancement pattern. For patients whose final follow-up assessments were done in outside centers, the Ministry of Health web-based patient registry and telephone interview were utilized. Final outcome of patients were categorized according to Glasgow Outcome Scale (GOS).

SPSS software (IBM SPSS Statistics for Macintosh, version 23.0; IBM Corp., Armonk, NY, USA) was used for statistical analysis. Descriptive statistics included means and standard deviation for parametric data, median and range for nonparametric, as well as counts and percentages for categorical data. Two group comparisons were performed using Student's t-test for parametric, Mann-Whitney U test for nonparametric, and Chi-square and Fisher's exact tests for categorical variables. Logistic regression was used to assess factors affecting favorable outcome. $p < 0.05$ was considered statistically significant.

■ RESULTS

During the specified time period, 27 meningiomas either intracranial or spinal in nature in 23 patients were operated. Four spinal meningiomas in three patients and 23 intracranial meningiomas in 20 patients were detected. The total number of pediatric intracranial tumors operated between 1994 and 01/2019 was 913; thus, the incidence for intracranial meningiomas in pediatric age group was 2.5%. The total number of intracranial meningiomas during the same period was 1533; therefore, study cohort made up 1.7% of all meningioma cases.

There were 12 male and 11 female patients (Table I). Mean ages \pm SD upon diagnosis for the whole study group, male subgroup, and female subgroup were 13.1 ± 4.4 , 13.9 ± 3.9 , and 12.2 ± 4.9 years, respectively. The age at presentation between different sex groups did not differ significantly.

Table I: Characteristics of Study Population

Category	Value
Number of patients (%)	
Male	12 (52.2)
Female	11 (47.8)
Mean age at presentation \pm SD (years)	
Male	13.9 ± 3.9
Female	12.2 ± 4.9
Neurofibromatosis (NF) (%)	
NF type 1	1 (4.3)
NF type 2	5 (21.7)
Tumor location (%)	
Superficial	13 (48.2)
<i>Convexity</i>	6
<i>Parasagittal</i>	6
<i>Peri-sylvian</i>	1
Deep	3 (11.1)
<i>Pineal</i>	1
<i>Mesencephalo-thalamic (ambient cistern)</i>	1
<i>Lateral ventricle</i>	1
Skull base	7 (25.9)
<i>Foramen magnum</i>	2
<i>Retro-orbital</i>	3
<i>Anterior cranial fossa</i>	2
Spinal	4 (14.8)
Extent of resection (%)	
Gross total	19 (70.4)
Subtotal	8 (29.6)
Histologic grade (%)	
Grade I	15 (55.6)
Grade II	9 (33.3)
Grade III	3 (11.1)
Mean follow up \pm SD (years)	
Outcome (%)	
GOS 1	7 (33.3)
GOS 2	9 (42.9)
GOS 3	2 (9.5)
GOS 4	-
GOS 5	3 (14.3)

SD: Standard deviation, **GOS:** Glasgow outcome scale.

Presentation

The presentation patterns of patients were related to tumor locations. The most common presenting symptom was headache (n=6); followed by seizure (n=5); motor weakness in the form of lower extremity monoparesis, paraparesis, or hemiparesis (n=4); proptosis (n=3); imbalance (n=2); extrapyramidal symptoms (n=1), and scalp mass (n=2). Six patients (26%) had associated neurofibromatosis (NF); one patient had NF1, and five patients had NF2. None of the patients had history of irradiation, but one patient had a concomitant hemophagocytic syndrome and hepatoblastoma.

Tumor Location and Size

Most of the tumors had superficial locations; six (22%) were located in cerebral convexity, six (22%) in parasagittal, and one (4%) in perisylvian regions (Figure 1A-F), which accounted for 13 (48%) of the 27 meningiomas in 23 patients. Skull base tumors were observed in seven (26%) patients. Tumor invaded the orbita and retro-orbital space extending into the cavernous sinus in three (11%) patients. Three of the tumors were located deep in the cerebral hemispheres, namely, the pineal region, adjacent to the midbrain and thalamus (perimesencephalic

cistern), and the lateral ventricle. The brainstem was displaced due to juxtaposing tumors (foramen magnum and petroclival meningioma) in two (7%) patients. Overall, five (19%) tumors were infratentorial. Finally, there were four (15%) tumors that originated from the spinal intradural space in three patients. One patient presented with T1-3 meningioma and four years later de novo T12-L1 meningioma (both papillary type). Remaining two patients presented with T3-6 and T7-8 meningiomas (both psammomatous type) respectively. Out of 23 intracranial tumors, 15 (65%) were larger than 4 cm in diameter. The mean tumor size (maximal diameter) was 5.2 ± 1.9 cm (median 5 cm; range 2.5–10 cm). The mean tumor volume was 59 ± 71 cm³ (median 31.4 cm³; range 3–293 cm³).

Extent of Resection

Gross total resection was performed in 19 (70.4%) of the meningiomas at initial surgery. Only a subtotal resection could be achieved in eight (29.6%) tumors. All convexity or parasagittal tumors could be excised completely (Simpson grade I-III). The reasons for subtotal resection (Simpson grade IV) were orbital tumors that extended from the bony orbit to retro-orbital space invading the cavernous sinus in three

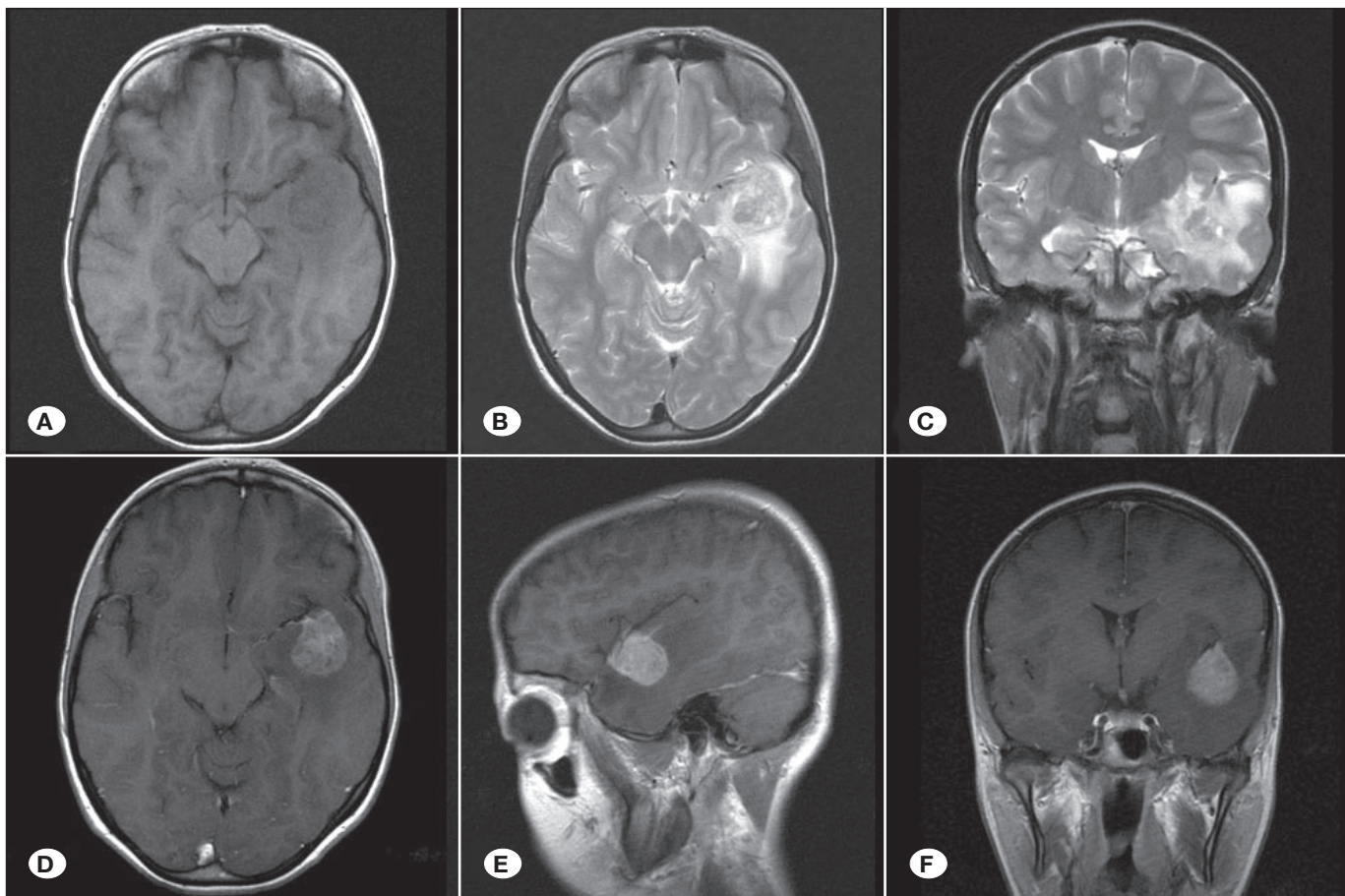


Figure 1: Cranial magnetic resonance image of a 17-year-old girl who presented with seizure shows a left temporal and intrasylvian mass (A). Surrounding tissue exhibits marked edema particularly in the external capsule, posterior limb of internal capsule, and periventricular white matter (B, C). In postcontrast images (D, E, F), enhancement of pia-arachnoid indicates tumoral infiltration. Histopathological examination of the lesion suggested atypical meningioma WHO grade II.

patients; World Health Organization (WHO) grade II tumors that invaded the brain stem in two patients; WHO grade III tumors that invaded the spinal cord in one patient (two separate tumors located in the thoracic and lumbar dura); and one giant tumor in the frontal basal area.

Surgical Complications

No operative mortality was observed in this series. Perioperative complications occurred in four patients (17%). Slight right hemiparesis developed in one patient who had a convexity meningioma over the motor cortex. In a patient with thoracic spinal meningioma, paraparesis worsened postoperatively. Postoperative third nerve palsy developed in a patient who had a tumor originating from tentorial incisura extending to ambient cistern, which displaced the mesencephalon and thalamus. Another patient required ventriculoperitoneal shunting due to hydrocephalus that developed after resection of a skull base meningioma.

Histological Types

The distribution of WHO grade I, grade II, and grade III meningiomas were 15 (56%), 9 (33%), and 3 (11%), respectively. Overall, there were 12 (44%) high-grade tumors. The most common initial histological tumor type was atypical meningioma (n=8), followed by transitional (n=6), meningothelial (n=4), psammomatous (n=2), fibroblastic (n=2), papillary (n=2), rhabdoid (n=1), and clear cell (n=1). One specimen showed both fibroblastic and meningothelial meningioma features. One NF2 patient, who was operated for left frontoparietal convexity meningioma had transitional histologic type; the same patient was operated after three years for de novo right parietal convexity meningioma which turned up to be rhabdoid type.

Follow-up and Outcome

Two patients were lost to follow-up immediately after operation. The mean follow-up duration for the remaining

21 patients was 10.3 ± 7.7 years (median 9 years; range 0.5–25 years). During the follow-up period, four patients who underwent gross total resection of the original tumor had recurrences after a mean of 3.8 years. Of the tumors that had been resected subtotally, six had residual tumor progression with a mean duration of 4.0 years (Table II). Relapses (n=10; 43.5%) occurred in 33.3% of WHO grade I (n=5) and in 41.7% of WHO grade II or III (n=5) meningiomas. Mean latencies to relapse for WHO grade I and grade II or III meningiomas were 5.0 ± 2.9 years and 2.2 ± 2.1 years, respectively ($p=0.067$). Six patients were reoperated (two of them three times) due to tumor relapse. During the last follow-up, GOS scores were distributed as follows: GOS=5 in seven patients, GOS=4 in nine patients, GOS=3 in two patients, and GOS=1 in three patients. Two patients died due to brain stem invasion and secondary complications (8 and 11 months postoperatively). One patient died because of a concomitant hemophagocytic syndrome and hepatoblastoma (16 months postoperatively). When GOS scores were dichotomized into favorable (GOS>3) and unfavorable (GOS≤3), 16 (70%) had favorable outcome and seven (30%) had unfavorable outcome. Six patients had reoperation, and five of those had favorable outcome after a mean follow-up of 8.6 years. Based on the univariate analysis, low histological grade ($p=0.030$) and gross total resection ($p=0.024$) were associated with favorable outcome. In addition, superficial location of tumor ($p=0.08$) was a marginally significant variable for favorable outcome (Table III). One- and 10-year overall survival rates were 91% and 86%, respectively.

Case Illustration 1

A 7-year-old girl was brought to the Emergency Department with complaints of headache and somnolence. Cranial MRI revealed a T2-hyperintense, 49×52×53 mm mass lesion located in the pineal region that was consistent with a meningioma (Figure 2A-C). Tumor displaced both lateral ventricles laterally. A right-sided posterior interhemispheric

Table II: Characteristics of Patients with Tumor Relapses

EOR at first operation	Location	Time to recurrence/ progression (year)	Histology/Grade	Total follow-up (years)
Gross total	Convexity	5	Transitional/I	25.3
Gross total	Convexity	4	Transitional/I	18.3
Gross total	Mesencephalo-thalamic	1	Atypical/II	17.4
Gross total	Parasagittal	5	Atypical/II	4.3
Subtotal	Retro-orbital	4	Transitional/I	21.7
Subtotal	Spinal	3	Papillary/III	2.8
Subtotal	Retro-orbital	3	Transitional/I	3.3
Subtotal	Anterior cranial fossa	9	Meningothelial/I	15.3
Subtotal	Foramen magnum	1	Atypical/II	0.7
Subtotal	Foramen magnum	1	Clear cell/II	0.9

EOR: Extent of resection.

transfalcine approach is utilized. Due to increased intracranial pressure (ICP), an external ventricular catheter was placed through the Frazier's point to facilitate brain retraction. Histological examination revealed a WHO grade II atypical meningioma. Postoperative MRI shows gross total resection of the tumor. Despite the restricted diffusion in the left thalamus

based on the postoperative diffusion-weighted imaging (DWI), the outcome of patient was excellent at 6-month follow-up assessment.

Case Illustration 2

A 16-year-old boy was admitted to our clinic with complaints of

Table III: Distribution of Dichotomized Outcomes and Their Relation to Patient and Tumor Characteristics. Data Represent Percentage [95% Confidence Interval]

Variable	Favorable	Unfavorable	p
Sex (%)			0.538
Male	83.3 [33.7-75.4]	72.7 [24.6-66.3]	
Female	16.7 [11.8-76.9]	27.3 [23.1-88.2]	
Mean age at presentation (years)	12.4 [10.1-14.7]	15.5 [12.1-18.9]	0.172
Neurofibromatosis (%)			0.292
Present	40.0 [21.9-61.3]	16.7 [3.0-56.4]	
Absent	60.0 [38.7-78.1]	83.3 [43.6-97.0]	
Tumor volume (cm³)	71.8 [26.2-117.3]	28.2 [1.8-34.7]	0.300
Tumor location (%)			0.080
Superficial	92.3 [36.5-75.5]	64.3 [24.6-66.3]	
Other	7.7 [3.0-56.4]	35.7 [23.1-88.2]	
Extent of resection (%)			0.024
Gross total	89.5 [68.6-97.1]	50.0 [21.5-78.5]	
Subtotal	10.5 [2.9-31.4]	50.0 [21.5-78.5]	
Histologic grade (%)			0.030
Grade I	66.7 [24.6-66.3]	16.7 [24.6-66.3]	
Grade II, III	33.3 [24.6-66.3]	83.3 [24.6-66.3]	

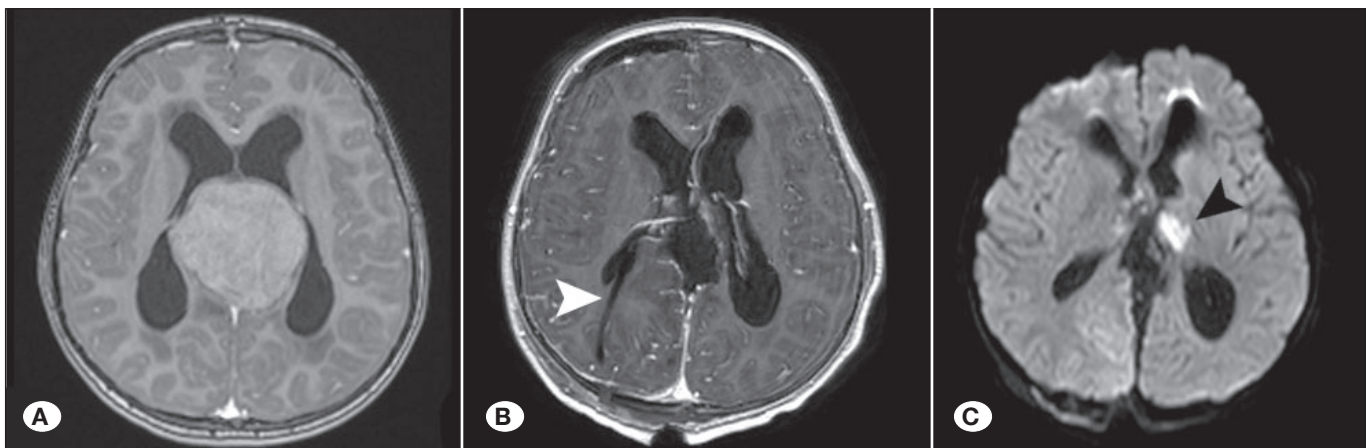


Figure 2: Preoperative contrast-enhanced axial (A), postoperative contrast-enhanced axial (B), and postoperative diffusion-weighted (C) images (DWI) of a 7-year-old girl. In order to facilitate posterior interhemispheric approach an external ventricular drainage catheter was introduced prior to retractor placement (white arrow head). Patient's outcome was excellent although DWI shows restricted diffusion in the left thalamus (black arrow head).

headache and disfiguring calvarial thickening. On inspection, he had extensive hyperostosis from the forehead to the lambdoid suture. Cranial MRI revealed a giant (100×67×50 mm) bifrontal parasagittal meningioma (Figure 3A-G), which compressed the cerebral sulci and displaced the corpus callosum inferiorly. The mass was associated with an extensive calvarial hyperostosis. Presence of bilateral vestibular schwannomas was consistent with NF2. After bicoronal skin incision, high-speed drill was utilized to mobilize the entire calvarial vault that incorporated the hyperostotic region. Bifrontal mass was excised gross totally together with the convexity dura, whereas the involved superior sagittal sinus segment was preserved. Histological examination revealed a meningothelial meningioma WHO grade I, with low mitotic index. After complete tumor excision and duraplasty with artificial dural substitute, the cranial vault was reconstructed using methyl methacrylate. The patient's neurological function was excellent with no recurrence or cosmetic deformity at 5-year follow-up.

Case Illustration 3

A 16-year old male admitted with nausea, vomiting and night sweats. The patient had history of hemophagocytic syndrome, CD19 deficiency and X-linked lymphoproliferative disease, which were diagnosed when he was 8-year old. On his last admission a hepatic ultrasound demonstrated three mass lesions, the biggest measuring 100x57 mm, which contained patchy necrotic areas. Excisional biopsy revealed hepatoblastoma and the patient received 4 cycles of chemotherapy. Due to progressive hepatic disease, liver transplantation was planned and during his routine pre-operative work up, a right parietal, lobulated, extra-axial mass lesion which measured 24x15 mm in maximal diameter (Figure 4A-D) suggestive of a metastatic lesion was demonstrated in cranial MRI. The tumor was excised totally, and the peri-operative period was unremarkable. Histological examination of the tumor revealed meningothelial type meningioma WHO Grade I. Unfortunately, the patient died in 16th month of follow due to febrile neutropenia.

DISCUSSION

Only 1.5%–1.8% of all meningiomas are pediatric meningiomas (20,24). According to the Central Brain Tumor Registry of the United States, 2.5% of all primary pediatric CNS tumors originate from the meninges; however, this rate is 22% when all age groups are considered (20). A recent systematic review of pediatric meningioma similarly revealed that they represent 2.2% of all pediatric CNS tumors and 2.5% of all meningiomas (15). As our cohort constituted 2.5% of all pediatric CNS tumors and 1.7% of meningiomas in all age groups, the presented data is also in line with the reported literature confirming the rarity of these tumors during childhood.

Although meningiomas can be seen in all age groups, including the fetal period, its frequency increases after 20 years of age. When the population under 18 years is considered, the mean age at presentation for pediatric meningiomas is reported to be 8.1–13.7 years (6,22,24,25). In our cohort, the mean presenting age (13.1 years) was similar to that of the general literature.

While adult meningiomas are seen predominantly in females, pediatric meningiomas have an opposite sex predilection (i.e., slightly more common in males). Differential expression of sex hormones or other pathogenetic processes may underlie this difference. However, no difference was observed in our series.

Family history, neurofibromatosis, and previous irradiation are considered as main risk factors for the development of meningioma. In our series, no patients had a history of cranial or spinal irradiation. However, nearly one-third of the patients had neurofibromatosis (one NF1, five NF2). In a meta-analysis including 677 patients from 35 series of pediatric and adolescent meningiomas, the prevalence of neurofibromatosis was 14.5%, of which NF2 accounted for 10.2% and NF1 for 3.4%; the type of neurofibromatosis of the remaining 0.9% was not documented. Meningioma associated with meningioangiomas occurred in three patients (15). Actually, we encountered one case of meningioangiomas in our database that was not associated with a meningioma.

The most common clinical feature for pediatric meningiomas is the presence of headache. Headache has been reported in up to 62% of patients (14,18). With decreasing order of frequency, other presenting signs and symptoms include papilledema (55%) and nausea and vomiting (53%), which are, along with headache, indicative of increased ICP. Less commonly encountered signs and symptoms are cranial nerve deficits, visual disturbances, seizures, motor weakness, and scalp masses (18,22). Similar to the literature, our patients mostly had signs of increased ICP, followed by seizures. Increased ICP is possibly due to fast-growing tumors in this age group.

Pediatric meningiomas tend to occur in atypical locations as compared with its adult counterparts. Although cerebral convexity (29.8%) was the most common location, intraventricular meningiomas are far more common in children (11%) than in adults (1%–2%). Other common supratentorial locations included parafalcine or parasagittal (8.6%), anterior and middle cranial fossa (7.2%), and orbital and optic nerve sheath (4.9%). Infratentorial (11.3%) and spinal (5.6%) meningiomas are relatively less common (15). In line with the literature, meningiomas in our cohort are most commonly located in the cerebral convexity (25.0%) followed by the parasagittal region (21.4%), whereas intraventricular meningioma (3.6%) was less frequent compared with the results of other series (15,18). Nevertheless, we have encountered meningiomas in other rare locations such as the pineal region or sylvian fissure.

Pediatric meningiomas usually present with larger sizes in comparison with its adult counterparts possibly due to rapid growth and/or delayed manifestation owing to developmental features (tolerability of cranial vault or inability to express symptoms). The mean tumor diameter was found to be 5.48 cm in 156 cases reviewed in a meta-analysis (15), and more than 45% of the pediatric meningiomas was reported to be bigger than 5 cm in another literature review (18). Similarly, out of 23 intracranial tumors in our series, 15 (65%) were larger than 4 cm in diameter, and the mean maximal tumor diameter was 5.2 ± 1.9 cm (median, 5 cm; range 2.5–9.5 cm). Although

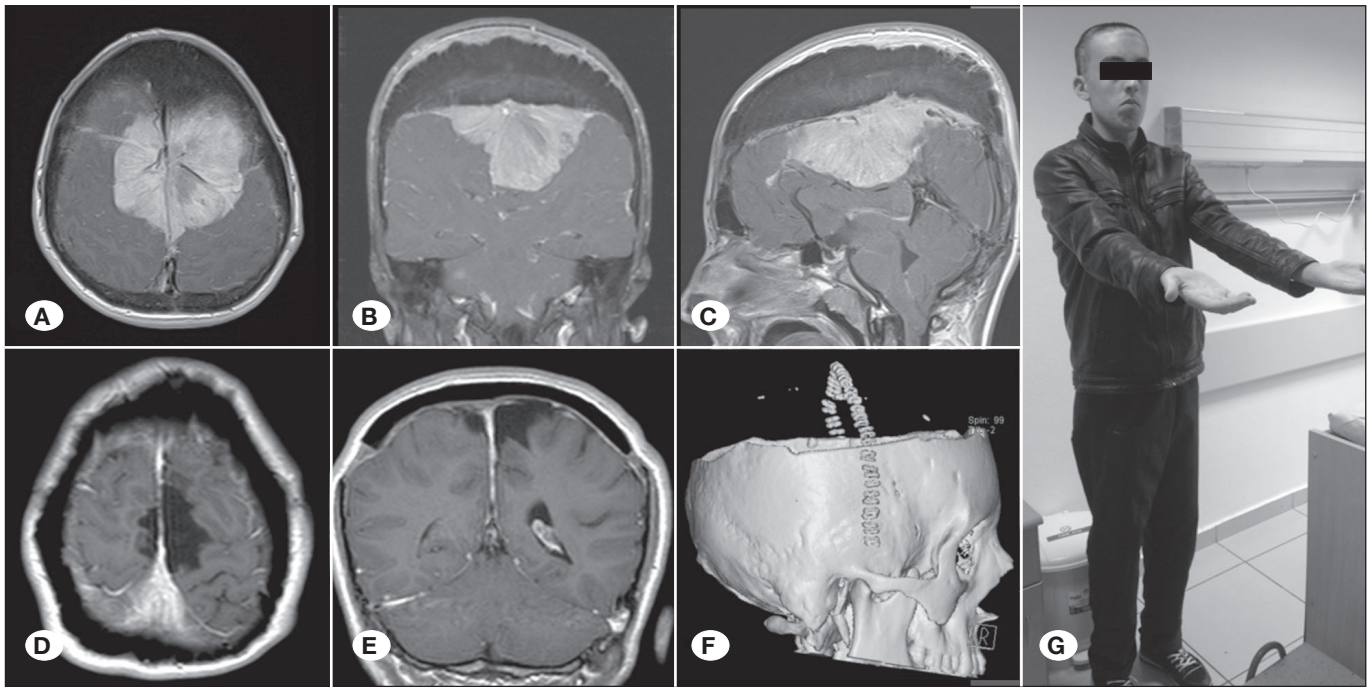


Figure 3: Patient with bifrontal meningioma with accompanying extensive hypersosteosis. T1-weighted axial (A), coronal (B), and sagittal (C) images show strong enhancement of 100x67x50 mm tumor as well as effacement of cerebral sulci and cerebellar folia. Postoperative images (D, E) show gross total resection of tumor that turned out to be meningotheelial meningioma. Cranial vault had been reconstructed using methyl methacrylate, which is translucent in computed tomography images (F). Patient was without neurological deficit and displayed a good cosmetic result (G).

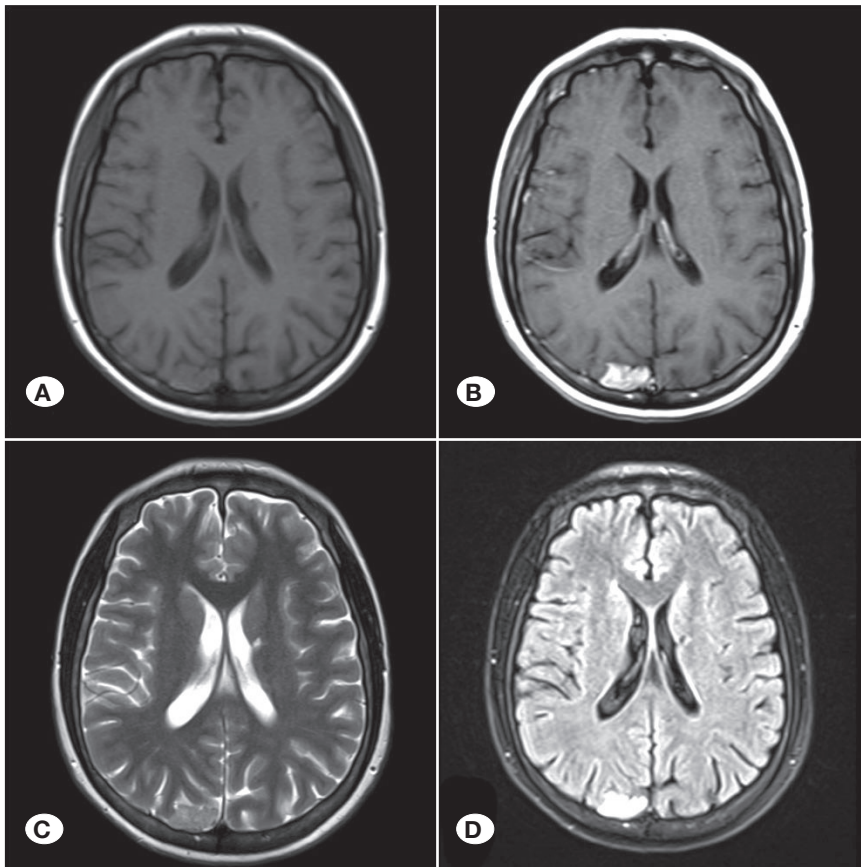


Figure 4: Axial T1-weighted (A), contrast enhanced T1-weighted (B), T2-weighted (C) and FLAIR (D) cranial magnetic resonance images of the patient described in Case Illustration 3. The lesion in right posterior parietal lobe is iso-intense with cortex in T2 and hypo-intense in T1-weighted images. There is strong contrast enhancement without dural tail sign; however, brain parenchyma that surrounds the lesion does not show any sign of edema in T2 and FLAIR images. Radiological differential diagnosis included metastasis of the primary lesion and solitary fibrous tumor of dural origin. The imaging characteristics are very atypical for classical meningioma.

other MRI characteristics of adult and pediatric meningiomas were generally similar, dural tail sign is less and intratumoral cysts are more common in pediatric meningiomas (2,7,12).

It is a well-known fact that higher-grade (II or III) meningiomas occur more frequently in children and young male adults than in older adults (26). A meta-analysis of published pediatric meningioma series showed that although WHO grade I meningiomas comprised 79% of them, WHO grade II (10%) and grade III (9%) were also relatively common. In our series, the distribution of grades I (55.5%), II (33.3%), and III (11.2%) meningiomas confirmed much higher rates of advanced grade in pediatric meningiomas as in some other recently published series (7,10,11).

Surgical resection is the mainstay of meningioma management with complete tumor excision being the best first-line treatment option to achieve favorable short- and long-term prognosis. Although common principles of meningioma surgery apply to childhood meningiomas in general, several features make them more challenging compared with adult meningiomas. First, they tend to occur in atypical locations, usually deep-seated and adjacent to critical structures. Second, they tend to present with larger tumors. Third, histologically aggressive forms are more common in children. Fourth, diffuse and anatomically aggressive or invasive forms are also more common as noted in our series. An important and well-known feature of meningiomas is associated reactive hyperostosis. Notably, the hyperostosis and its consequences are seldom reported in recent literature (1,12). In our experience, those tumors are technically challenging due to bone anatomy, sinus invasion, tumor vascularity, and pial adherence or brain invasion. Fifth, pediatric meningiomas require aggressive surgical treatment taking into account longer life expectancy, higher recurrence risk, and detrimental effects of other treatment modalities (radiotherapy, chemotherapy). In addition, although meningioma is better than other childhood tumors, surgery is not without morbidity. Hence, careful preoperative planning with different imaging modalities (MRI, computed tomography, angiography); technical preparation and intraoperative adjunct use (preoperative embolization if feasible, neuronavigation, intraoperative neuromonitoring); meticulous surgical technique including appropriate bone drilling, use of cavitron ultrasonic surgical aspirator, and careful microsurgical dissection yield complete resection with low morbidity and excellent long-term outcomes in those technically challenging tumors.

Adjuvant treatment is not considered a good option in most pediatric meningiomas. Although some pediatric oncology guidelines recommend radiotherapy for grade III meningiomas, upfront radiotherapy has not been found to provide significant survival benefit in pediatric meningioma cases among similar subgroups of tumor grade or initial resection status (15). Although more aggressive when compared with adult forms, survival with these tumors are long with radical surgery; radiotherapy is usually delayed until repeated surgeries fail to be beneficial in order to avoid long-term consequences since these patients are in childhood age. In our experience, only five patients with subtotally removed,

higher-grade, and recurrent tumors received radiotherapy. We believe that early aggressive surgical excision must be the primary treatment option for pediatric meningiomas of all grades; and even residual progression or recurrences should be treated with surgery (five out of six patients with repeat surgery had favorable long-term outcomes in the present series). Radiotherapy should be reserved only for those patients with rapidly progressing or recurring higher-grade (II or III) meningiomas (4). Moreover, chemotherapy is not an effective treatment option for meningiomas, and experience with chemotherapy in pediatric meningiomas is extremely limited in the literature.

An average follow-up period between 2.8 and 8.5 years for pediatric meningiomas has been reported in the literature (1,6,8,9,16,17,19,20,22,25). In this regard, the present study is among the few studies with a long-term follow-up (mean, 10.3 ± 7.7 years; median, 9 years). We observed three patients expired and two lost to follow-up in that period. In general, meningioma progression is relatively slow. Therefore, it is imperative to have longer follow-up to establish functional status data of these children in adult life and identify relapses properly. In addition long-term sequelae of pediatric meningioma survivors should not be overlooked, which include visual deficits, neuropsychological abnormalities, developmental delay, CNS palsies, motor deficits, seizure disorders, and sensory deficits (14).

Low- or high-grade pediatric meningiomas are not exempt from relapses. Indeed, five (33.3%) of 15 WHO grade I and five (41.7%) of 12 WHO grade II or III meningioma patients in our study experienced relapses. Latencies for relapses in low- and high-grade groups were 5.0 ± 2.9 years and 2.2 ± 2.1 years, respectively. Similarly, Grossbach et al. reported that in their 39-patients series with WHO grade I tumors, the recurrence rate was 42% (10 of 24); this rate was not significantly different from the recurrence rate among patients with WHO grade II or III pathology (10). Presented data in line with their findings suggest that even WHO grade I meningiomas in children may behave more like adult atypical meningiomas than classic adult meningothelial meningiomas, indicating different biological behavior pattern.

In the present series, we identified WHO grade I, convexity or parasagittal location, and gross total resection as favorable prognostic factors. Risk of tumor recurrence and, thus, poor outcomes increase with histological grade both in adults and children. Interestingly, children and adolescents with meningioma have better progression-free and overall survival rates than adults despite the fact that they harbor more aggressive tumors based on WHO grading (15). This fact implies that WHO grade alone is not sufficient in determining biological behavior of pediatric meningiomas and that they may have different molecular characteristics from adult meningiomas. The extent of resection has also been a well-established independent prognostic factor of meningiomas (23). However, with regard to the location, literature is controversial. On one hand, Celtikci et al. suggested that convexity or nonskull base meningiomas are more frequently associated with higher grades, tumor recurrence, progression,

and worse prognosis in adults (5). On the other hand, skull base or deep meningiomas are associated with higher surgical morbidity and lower complete excision rates even though they may have less aggressive behavior, thus yielding similar recurrence and long-term outcomes (21). Likewise, a meta-analysis of pediatric meningiomas did not find a relationship between tumor location and progression-free or overall survival (15).

Herein, we have presented a study describing various characteristics in 23 patients harboring one or more meningioma. We sought to define variables that are associated with favorable outcome. Although we have shown that both extent of resection and histological grade are related to better outcomes and a marginal advantage of convexity and parasagittal tumors in univariate analysis is noted, the relatively small number of cases in our study precluded a multivariate analysis, which we believe is one of the most important weaknesses of our study. Nevertheless, our series is one of the largest cohorts with long-term follow-up data in the MRI era. Another drawback of our study is its retrospective design; however, the reader would admit the difficulty in collecting prospective data, which is due to the rarity of the disorder within a relatively long duration. It is possible that the higher recurrence rates we observed are in fact related to the extent of initial resection and actually represent tumor progression. This is especially relevant with regard to the earlier cases from the pre-MRI era in which verification of the extent of resection was extremely limited. Thus, it is difficult to distinguish true recurrence from progression in this series (10).

CONCLUSION

Meningiomas in pediatric age group have important differences from its adult counterparts such as higher incidence of atypical locations, grade II or III, and larger tumors that pose challenges in terms of management. Nevertheless, prognosis of meningiomas, even of higher grades, is relatively better when compared with other high-grade pediatric tumors. Early aggressive surgical resection is the best treatment option and yields favorable early and long-term outcomes. Recurrences should also be treated with surgery if possible, and radiotherapy should only be reserved for rapidly progressive or recurrent high-grade meningiomas for which surgical treatment fails to achieve optimal disease control.

REFERENCES

- Alexiou GA, Mpairamidis E, Psarros A, Sfakianos G, Prodromou N: Intracranial meningiomas in children: Report of 8 cases. *Pediatr Neurosurg* 44:373-375, 2008
- Arivazhagan A, Devi BI, Kolluri SV, Abraham RG, Sampath S, Chandramouli BA: Pediatric intracranial meningiomas-do they differ from their counterparts in adults? *Pediatr Neurosurg* 44:43-48, 2008
- Bilginer B, Hanalioglu S, Turk CC, Narin F, Oguz KK, Soylemezoglu F, Akalan N: Is the knowledge pertaining to adult glioblastomas enough for pediatric cases? prognostic factors in childhood. *Turk Neurosurg* 27:279-288, 2017
- Bilginer B, Turk CC, Narin F, Hazer B, Hanalioglu S, Oguz KK, Soylemezoglu F, Akalan N: De novo formation of brain tumors in pediatric population following therapeutic cranial irradiation. *Childs Nerv Syst* 31:893-899, 2015
- Celtikci E, Kaymaz AM, Akgul G, Karaaslan B, Emmez OH, Borcek A: Retrospective analysis of 449 intracranial meningioma patients operated between 2007 and 2013 at a single institute. *Turk Neurosurg* 28:1-6, 2018
- El Beltagy MA, Enayet AE, Atteya MME, Reda M, Refaat A, Taha H, Ahmed S, Abdelaziz A: Management of pediatric CNS meningiomas: CCHE-57357 experience in 39 cases. *Childs Nerv Syst* 35:1323-1331, 2019
- Fan MC, Fang W, Liu K, Wang C, Deng WS, Sun P, Tang WZ: Paediatric intracranial meningiomas: Eight-year experience with 32 cases. *Chinese Neurosurgical Journal*, 2017
- Gao X, Zhang R, Mao Y, Wang Y: Childhood and juvenile meningiomas. *Childs Nerv Syst* 25:1571-1580, 2009
- Greene S, Nair N, Ojemann JG, Ellenbogen RG, Avellino AM: Meningiomas in children. *Pediatr Neurosurg* 44:9-13, 2008
- Grossbach AJ, Mahaney KB, Menezes AH: Pediatric meningiomas: 65-year experience at a single institution. *J Neurosurg Pediatr* 20:42-50, 2017
- Huntoon K, Pluto CP, Ruess L, Boue DR, Pierson CR, Rusin JA, Leonard J: Sporadic pediatric meningiomas: A neuroradiological and neuropathological study of 15 cases. *J Neurosurg Pediatr* 20:141-148, 2017
- Im SH, Wang KC, Kim SK, Oh CW, Kim DG, Hong SK, Kim NR, Chi JG, Cho BK: Childhood meningioma: Unusual location, atypical radiological findings, and favorable treatment outcome. *Childs Nerv Syst* 17:656-662, 2001
- Isikay I, Hanalioglu S, Basar I, Narin F, Bilginer B: Survival benefit with gross total resection and adjuvant radiotherapy in childhood atypical teratoid/rhabdoid tumors: Results of a single-center cohort of 27 cases. *Turk Neurosurg* 29:689-697, 2019
- Kotecha RS, Junckerstorff RC, Lee S, Cole CH, Gottardo NG: Pediatric meningioma: Current approaches and future direction. *J Neurooncol* 104:1-10, 2011
- Kotecha RS, Pascoe EM, Rushing EJ, Rorke-Adams LB, Zwerdling T, Gao X, Li X, Greene S, Amirjamshidi A, Kim SK, Lima MA, Hung PC, Lakhdar F, Mehta N, Liu Y, Devi BI, Sudhir BJ, Lund-Johansen M, Gjerris F, Cole CH, Gottardo NG: Meningiomas in children and adolescents: A meta-analysis of individual patient data. *Lancet Oncol* 12:1229-1239, 2011
- Lakhdar F, Arkha Y, El Ouahabi A, Melhaoui A, Rifi L, Derraz S, El Khamlichi A: Intracranial meningioma in children: different from adult forms? A series of 21 cases. *Neurochirurgie* 56:309-314, 2010
- Li X, Zhao J: Intracranial meningiomas of childhood and adolescence: Report of 34 cases with follow-up. *Childs Nerv Syst* 25:1411-1417, 2009
- Liu Y, Li F, Zhu S, Liu M, Wu C: Clinical features and treatment of meningiomas in children: Report of 12 cases and literature review. *Pediatr Neurosurg* 44:112-117, 2008
- Mehta N, Bhagwati S, Parulekar G: Meningiomas in children: A study of 18 cases. *J Pediatr Neurosci* 4:61-65, 2009

20. Menon G, Nair S, Sudhir J, Rao BR, Mathew A, Bahuleyan B: Childhood and adolescent meningiomas: A report of 38 cases and review of literature. *Acta Neurochir (Wien)* 151:239-244; discussion 244, 2009
21. Nanda A, Vannemreddy P: Recurrence and outcome in skull base meningiomas: Do they differ from other intracranial meningiomas? *Skull Base* 18:243-252, 2008
22. Santos MV, Furlanetti L, Valera ET, Brassesco MS, Tone LG, de Oliveira RS: Pediatric meningiomas: A single-center experience with 15 consecutive cases and review of the literature. *Childs Nerv Syst* 28:1887-1896, 2012
23. Simpson D: The recurrence of intracranial meningiomas after surgical treatment. *J Neurol Neurosurg Psychiatry* 20:22-39, 1957
24. Stanuszek A, Piatek P, Kwiatkowski S, Adamek D: Multiple faces of children and juvenile meningiomas: A report of single-center experience and review of literature. *Clin Neurol Neurosurg* 118:69-75, 2014
25. Thuijs NB, Uitdehaag BM, Van Ouwkerk WJ, van der Valk P, Vandertop WP, Peerdeman SM: Pediatric meningiomas in The Netherlands 1974-2010: A descriptive epidemiological case study. *Childs Nerv Syst* 28:1009-1015, 2012
26. Zhou P, Ma W, Yin S, Li Y, Jiang S: Three risk factors for WHO grade II and III meningiomas: A study of 1737 cases from a single center. *Neurol India* 61:40-44, 2013