



Use of Muscle Graft versus Fascia Flap as Interpositional Material in Prevention of Reossification in a Rat Model of Skull Bone Defect

Ayhan OKUMUS^{1*}, Erdem GUVEN^{1**}, Ismail ERMIS¹, Vakur OLGAC², Murat TOPALAN^{1**}, Metin ERER^{1***}

¹Istanbul University Istanbul Faculty of Medicine, Department of Plastic Surgery, Istanbul, Turkey

²Istanbul University Oncology Institute, Division of Tumor Pathology, Istanbul, Turkey

Corresponding author: Ayhan OKUMUS ✉ ayhan@ayhanokumus.com.tr

ABSTRACT

AIM: To investigate the utility of two different interpositional materials (muscle graft vs. fascia flap) for preventing the osseous reunion of skull bone defect including the coronal suture line in rats.

MATERIAL and METHODS: A total of 32 male Sprague-Dawley rats were divided into 2 groups (n=16 for each) after the formation of bilateral coronal bone defect, based on the interpositional materials used to prevent re-ossification; the rats were divided into the muscle graft (MG) group and the fascial flap (FF) group. In each group, the other side of the coronal suture served as the control. The rats were sacrificed at postoperative 4 weeks or 8 weeks for histopathological, radiological, and microbiologic investigations.

RESULTS: At postoperative 8 weeks, there was partial reunion in the defects with bony tissue in both the groups; no obvious differences were noted between the groups on radiological examination. The defect content involved bone and fibrous tissue in the MG group and bony bridges and loose connective tissue in the FF group. New bone formation was moderate, marked, and extreme and the reduction in defect size was marked, moderate, and extreme in the MG, FF, and control groups, respectively.

CONCLUSION: Our findings revealed that neither the temporal MG nor the temporal FF were able to achieve complete prevention of re-ossification of the skull bone defects including the coronal suture line; further, neither material was superior to the other.

KEYWORDS: Skull bone defects, Craniosynostosis, Muscle graft, Fascial flap, Rat

INTRODUCTION

Achievement of re-ossification is the main goal of treatment in most clinical conditions with bone defects, especially in bone surgery. However, the prevention of new bone formation is critical in certain clinical settings, such as premature epiphyseal fusion of long bones (10,11), and after the craniosynostosis surgery (5,14,16).

Suboptimal treatment of craniosynostosis increases the risk of aesthetic deformities in later life, while re-operation after primary craniosynostosis surgery may also be required in cases of recurrence of craniofacial deformity with secondary coronal synostoses or craniocerebral disproportion (3,7,9,18,19).

Therefore, certain surgical techniques, such as covering of the craniectomy margins with a plastic film (8), and dural split (17), have been described in the initial studies to prevent early re-ossification at the suturectomy site after craniosynostosis surgery. Thereafter, the placement of various types of absorbable and non-absorbable materials between the bone edges as interpositional materials has been investigated in terms of their potential role in preventing early re-ossification as a useful adjunct for the treatment of craniosynostosis (1,2,4,6,13,15). These materials include polyethylene films, pericranial grafts, interpositioned biodegradable polyglycolic acid (PGA) membrane, interposed silicon membrane or expanded polytet-

Ayhan OKUMUS  : 0000-0002-2238-8398
Erdem GUVEN  : 0000-0002-7608-6088
Ismail ERMIS  : 0000-0002-7786-7337

Vakur OLGAC  : 0000-0003-0497-0314
Murat TOPALAN  : 0000-0002-8339-0846
Metin ERER  : 0000-0002-8100-3072

rafluoroethylene (ePTFE) membrane as a barrier to calvarial reclosure, as well as dura and muscle graft (MG), and free fat tissue transplants (1,2,4,6,13,15). Polyethylene films are non-biological materials, and pericranial grafts have potential osteogenic capacity. The use of free fat tissue transplants has been considered useful not only for correcting premature epiphyseal fusion of long bones by preventing re-ossification after bone bridge resection, but also for preventing osseous reunion of the calvarial bone defects (6,13,15). However, early re-ossification at the suturectomy site after craniostylosis surgery remains challenging given the lack of convincing scientific evidence obtained for any material (1,2,4).

This study was designed to investigate the utility of two different interpositional materials (MG vs. fascia flap) in the prevention of osseous reunion of skull bone defect, including the coronal suture line in rats.

■ MATERIAL and METHODS

Animals

Total 32 male Sprague-Dawley rats (body weight 300–350 grams) were kept in a light- and temperature-controlled room with a 12-hour light-dark cycle at a temperature of $22^{\circ}\text{C} \pm 0.5^{\circ}\text{C}$ and relative humidity of $45.0\% \pm 10.0\%$. The animals were fed standard rat pellets and provided with water ad libitum. The study was approved by the Scientific and Ethics Committee of Istanbul University Istanbul Faculty of Medicine Experimental Animals Research and Application Center.

Study Protocol

The rats were separated into the MG group and the fascial flap (FF) group ($n=16$ for each) after the formation of bilateral coronal bone defects, as per the interpositional materials used for preventing re-ossification. In each group, the gap on one randomly chosen side was filled with interpositional material, while the other side of the coronal suture was left open to serve as a control. Half of the rats in each group were sacrificed 4 weeks postoperatively, while the remaining half were sacrificed 8 weeks postoperatively for histopathological,

radiological, and microbiologic investigations. The specimens were also examined macroscopically.

Skull Bone Defect Including the Coronal Suture Line

The surgeries were performed under the intraperitoneal ketamine hydrochloride (Ketalar flacon; Pfizer Inc., Istanbul, Turkey) anesthesia. A sagittal incision was performed to expose not only the coronal suture, but also the temporal muscle and parietal bones (Figure 1A). Under “ $\times 4$ ” magnification, a 2-mm gap was made using a fine-tipped dental bur inserted through the right and left coronal sutures of the rats (Figure 1B). The dura was preserved during the operation. The field was meticulously irrigated with saline solution to clean the bony particles.

Interpositional Materials

In the MG group, the gap on one randomly chosen side of the coronal suture was filled with a MG obtained from the temporal muscle (Figure 2A). The other side of the coronal suture was left without interpositional material to act as the control. In the FF group, the defect on one randomly chosen side of the coronal suture was filled with a pedicled temporal FF (Figure 2B). The other side was left untreated and used as the control.

Histopathological Analyses

Tissue samples collected for histopathological analyses were fixed in 10% buffered formalin and embedded in paraffin for serial sectioning. Longitudinal $5\text{-}\mu\text{m}$ sections were stained with hematoxylin and eosin and examined under a light microscope (Nikon ECLIPSE 80i, Japan, $\times 200$ augmentation) to identify the defect content and evaluate new bone formation, inflammatory cell infiltration, necrosis, and decrease in defect size based on a scale [none, mild (+), moderate (++)], marked (+++), and extreme (++++)].

Radiology and Tissue Cultures

For radiologic examinations, CT was used to detect any changes in the calvarial specimens. Cultures were performed on samples taken from each animal to reveal any infections.

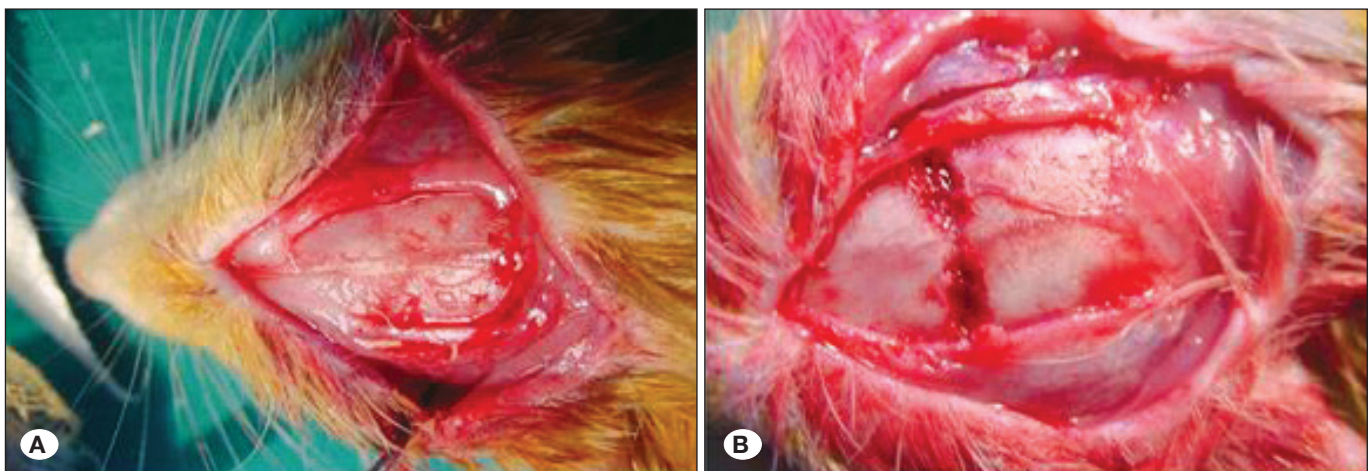


Figure 1: A) Coronal suture in a rat. B) Formation of bilateral skull bone defects including the coronal suture line.

RESULTS

Macroscopic Findings

At postoperative week 4, macroscopic observation of the MG and FF groups showed that the defects were filled with whitish fibrous tissue, and there was no reunion.

At postoperative week 8, the defects were filled with a bony fibrous tissue in the control sides, while no sign of reunion was observed in the MG and FF groups.

Microbiological Findings

There was no bacterial growth in the cultures obtained at postoperative week 4 and 8 in any group.

Radiological Findings

At postoperative week 4, there was no re-ossification, and the defect size had remained unchanged at 2 mm in both the groups; however, there was partial re-ossification and closure of the defects in the control group.

At postoperative week 8, the defects were fully re-ossified and had disappeared in the control groups. However, in the MG and FF groups, there was partial reunion in the defects with bony tissue, and radiological examination showed no obvious differences between the two groups.

Histopathological Findings

The results of the histopathology examination are depicted in detail in Table I. At the assessment performed after 8 weeks of the surgery, the defect content involved the bone and the fibrous tissue in the MG group, bony bridges and loose connective tissue in the FF group, and bone and mixed connective tissue in the control group. At the 4th week, new bone formation was absent in the MG and FF groups, while there was moderate formation in the control group. At postoperative week 8, new bone formation was moderate, marked, and extreme, and decrease in defect size was marked, moderate, and extreme in the MG, FF, and control groups, respectively (Table I, Figure 3).

DISCUSSION

Our findings at postoperative 8-week revealed that although no sign of reunion was evident macroscopically with the use of MG or FF as compared with the defects left untreated that were filled with bony fibrous tissue. Partial reunion in the defects with bony tissue was evident in both interpositional material groups on radiological examination. In addition, histopathological analyses revealed that the defect content involved the bone and fibrous tissue in the MG group and bony bridges and loose connective tissue in the FF group along with

Table I: Histopathologic Examination Findings

	Temporal muscle graft		Temporal fascial flap		Control	
	4 th week	8 th week	4 th week	8 th week	4 th week	8 th week
Defect content	Muscle, fibrous tissue	Bone and fibrous tissue	Vascularized fibrous tissue	Bony bridges, loose connective tissue	Fibrous tissue, bone trabeculae	Bone and mixed connective tissue
New bone formation	None	++	None	+++	++	++++
Inflammatory cell infiltration	++	+	+	None	++	None
Necrosis	None	None	None	None	None	None
Decrease in defect size	None	+++	+	++	++	++++

mild (+), moderate (++) , marked (+++) , extreme (++++)

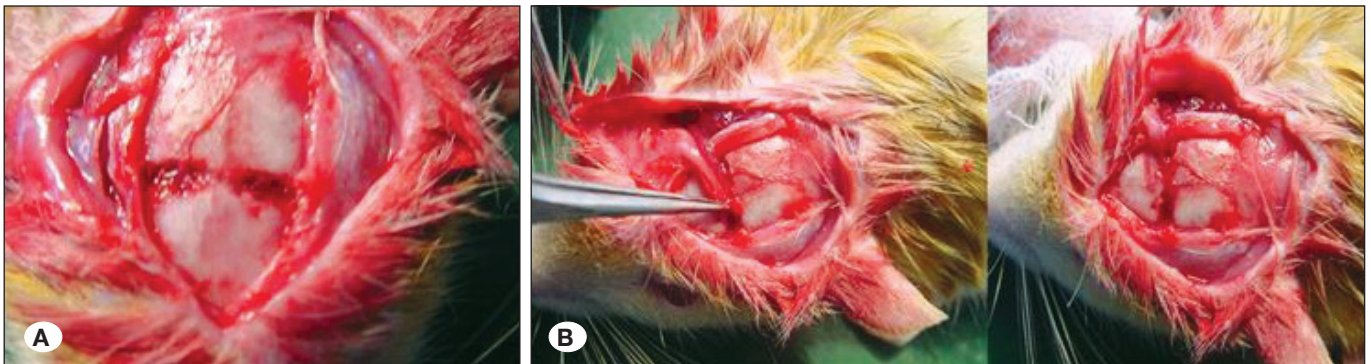


Figure 2: A) Muscle graft on the right side. B) Temporal fascia flap on the right side.

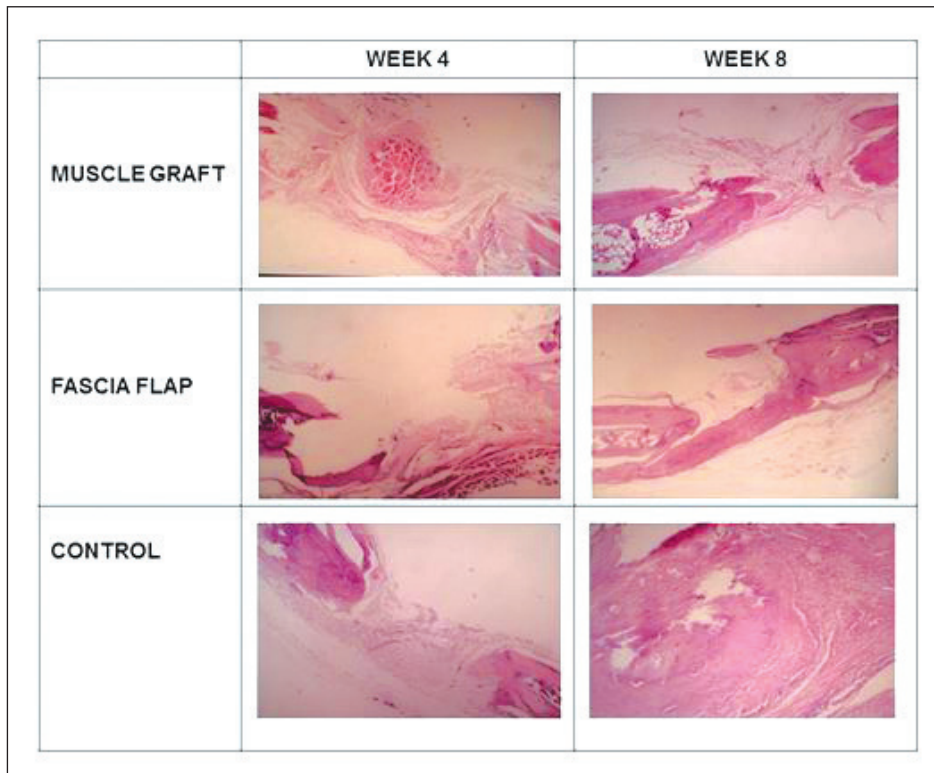


Figure 3: Histological findings at the 4th weeks and 8th weeks in the temporal muscle graft group, temporal fascial flap group, and control groups.

moderate new bone formation and marked decrease in the defect size in the MG group and marked new bone formation and moderate decrease in defect size in the FF group.

Past experimental studies have revealed successful outcomes with the use of several interpositional materials in terms of prevention of early re-ossification of skull bone defects. Use of an autologous free fat graft is reportedly associated with total prevention of calvarial bone regeneration after 10 weeks after the formation of parietal bone defects (15), or 8 months after the formation of temporal bone defects in rabbits (13). Authors have noted that the use of free fat tissue transplant can be a useful alternative, serving as a biological interposition material in the surgical treatment of craniosynostosis (13,15).

Use of interpositioned biodegradable PGA membrane (2), or a silicon membrane (1) in two experimental craniosynostosis studies with unilateral resection of the coronal suture in newborn rabbits were reportedly successful in terms of prevention of the formation of a skull deformity at 6 months of age (1,2).

In another experimental study, the use of ePTFE membrane as a barrier to calvarial reclosure after craniosynostosis surgery in rats was reported to prevent early re-ossification and was associated with lesser amount of fibrosis and no bone bridging between the edges at the suturectomy site as compared with that in controls at postoperative 4 months (4).

In another study, the effect of guided tissue regeneration (GTR) alone, implantation of demineralized bone matrix (DBM) alone and of the combined treatment was compared in terms of the healing of craniectomy defects involving the sagittal cranial

suture in rats (12). Authors have reported predictable osseous healing including the formation of a sagittal suture to be accomplished in craniectomy defects with GTR in association with undisturbed cranial growth, while the treatment of the defects with DBM alone or DBM combined with GTR resulted in craniosynostosis and reduced cranial growth (12).

In our study, while the use of MG or FF as interpositional materials for skull bone defects including the coronal suture line seems to be a more advantageous technique when compared to no treatment in terms of a lower degree of new bone formation and defect closure (moderate-to-marked vs. extreme). Neither material appeared to achieve complete prevention of re-ossification of the skull bone defects, at least in terms of radiological and histopathological findings. Accordingly, our findings indicate that neither the FF nor the MG revealed outcomes sufficient to justify their use as alternative interpositional materials in the prevention of the reunion of skull defects in rats. Neither the MG nor the FF was found to be superior in preventing re-ossification, and both delayed the decrease in defect size but could not stop re-ossification.

The interpositional materials used in the current study to prevent re-ossification were autogenous materials derived from the MG and the FF that are in close proximity to the primary operative field and can be similarly used in synostosis cases in humans because of this advantage and lack of aesthetic or functional deficit problems in the patient following their preparation. Moreover, the temporal muscle and temporal fascia are easy-to-access anatomic structures with rich blood supply that are frequently used in craniofacial reconstruction.

Blood supply from the deep and superficial temporal artery enables the preparation of the axial and free muscle, muscle plus fascial, or FFs. However, our findings have revealed failure of muscle or FF per se in preventing re-ossification; therefore, their use for therapeutic purposes does not seem rational unless combined with other methods. Nonetheless, the use of a FF to surround non-autogenous materials that are to be placed into the defect may be a new model for studies on the prevention of reunion. Hence, our findings indicate the success of neither MG nor FF for preventing reunion, each of which otherwise would be an ideal alternative as an interpositional material with close proximity to the primary operative field and lack of subsequent aesthetic and functional deficit risk.

Early re-ossification at the suturectomy site after craniosynostosis surgery is a challenge for neurosurgeons, with lack of convincing evidence in the favor of any material (1,2,4). Hence, by providing data on two interpositional materials that, to our knowledge, have not been studied or compared, our findings are a valuable contribution to the current literature regarding the development of an ideal method for preventing reunion after craniosynostosis in neurosurgery.

CONCLUSION

Our findings revealed that neither the temporal MG nor the temporal FF could achieve complete prevention of re-ossification of the skull bone defects including the coronal suture line with no superiority of one material over the other. Although both the materials enabled lesser degree of new bone formation and delayed defect closure than that in control defects that were left untreated, they could not prevent the re-ossification completely. Hence, the outcomes were insufficient to justify the use of MG or FF as alternative interpositional materials for preventing the union of skull defects in rats. A deeper understanding about the regulation of a complex array of factors that underlie the maintenance of suture patency and dynamics of membranous bone growth at the suture may help develop optimal interpositional materials in the future as useful adjuncts in the treatment of craniosynostosis.

ACKNOWLEDGEMENTS

The current addresses for the authors with asterisk(s) are as follows:

*Private Aesthetic Plastic and Reconstructive Surgery Office, Bursa, Turkey

**Private Aesthetic Plastic and Reconstructive Surgery Office, Istanbul, Turkey

***Retired Senior Faculty Member of Istanbul University Istanbul Faculty of Medicine, Istanbul; Turkey

REFERENCES

- Antikainen T: Silicon membrane interpositioning for the prevention of skull deformity following experimental craniosynostosis. *Childs Nerv Syst* 9:321-324, 1993
- Antikainen T, Kallioinen M, Pohjonen T, Törmälä P, Waris T, Serlo W: Polyglycolic acid membrane interpositioning for the prevention of skull deformity following experimental craniosynostosis. *Pediatr Neurosurg* 21:77-82, 1994
- Arnaud E, Capon-Degardin N, Michienzi J, Di Rocco F, Renier D: Scaphocephaly part II: Secondary coronal synostosis after scaphocephalic surgical correction. *J Craniofac Surg* 20 Suppl 2:1843-1850, 2009
- Calisaneller T, Bavbek M, Demirhan B, Caner H, Altinors N: The value of expanded polytetrafluoroethylene in preventing early re-ossification after craniosynostosis surgery: An experimental animal study in the rat. *Acta Neurochir (Wien)* 146:279-283, 2004
- Durham EL, Howie RN, Cray JJ: Gene/environment interactions in craniosynostosis: A brief review. *Orthod Craniofac Res* 20 Suppl 1:8-11, 2017
- Fatah MF, Ermis I, Poole MD, Shun-Shin GA: Prevention of cranial reossification after surgical craniectomy. *J Craniofac Surg* 3:170-172, 1992
- Foster KA, Frim DM, McKinnon M: Recurrence of synostosis following surgical repair of craniosynostosis. *Plast Reconstr Surg* 121:70-76, 2008
- Ingraham FD, Alexander E Jr, Matson DD: Clinical studies in craniosynostosis analysis of 50 cases and description of a method of surgical treatment. *Surgery* 24:518-541, 1948
- Joly A, Paré A, Sallot A, Arsène S, Listrat A, Travers N, Goga D, Laure B: Long-term assessment of suturectomy in trigonocephaly and anterior plagiocephaly. *J Craniofac Surg* 27:627-630, 2016
- Langenskiöld A: Surgical treatment of partial closure of the growth plate. *J Pediatr Orthop* 1:3, 1981
- Langenskiöld A: The possibility of eliminating premature partial closure of an epiphyseal plate caused by trauma or disease. *Acta Orthop Scand* 38:267, 1967
- Mardas N, Kostopoulos L, Karring T: Bone and suture regeneration in calvarial defects by e-PTFE-membranes and demineralized bonematrix and the impact on calvarial growth: An experimental study in the rat. *J Craniofac Surg* 13:453-462, 2002
- Merikanto JE, Alhopuro S, Ritsilä VA: Free fat transplant prevents osseous reunion of skull defects. A new approach in the treatment of craniosynostosis. *Scand J Plast Reconstr Surg Hand Surg* 21:183-188, 1987
- Opperman LA: Cranial sutures as intramembranous bone growth sites. *Dev Dyn* 219:472-485, 2000
- Rachmiel A, Sugihara T, Jackson IT, Izhak OB: The use of autologous free fat tissue in prevention of calvarial bone regeneration: An experimental study. *Eur J Plastic Surg* 18:27-31, 1995
- Sivakumar W, Goodwin I, Blagg R, Johns D, Riva-Cambrin J, Siddiqi F, Gociman B: Pancraniosynostosis following endoscopic-assisted strip craniectomy for sagittal suture craniosynostosis in the setting of poor compliance with follow-up: a case report. *J Med Case Rep* 9:64, 2015
- Van der Werf AJ: Craniosynostosis: A new operative technique. *Clinic Neurol Neurosurg* 80:70-81, 1977
- Wagner JD, Cohen SR, Maher H, Dauser RC, Newman MH: Critical analysis of results of craniofacial surgery for nonsyndromic bicoronal synostosis. *J Craniofac Surg* 6:32-37, 1995
- Wall SA, Goldin JH, Hockley AD, Wake MJ, Poole MD, Briggs M: Fronto-orbital re-operation in craniosynostosis. *Br J Plast Surg* 47:180-184, 1994