

LYMPHANGIOMA OF THE SCALP

Servet İnci, M.D., Murad Bavbek, M.D., Osman Ekin Özcan, M.D., Behsan Önel, M.D., Gökhan Gedikoğlu, M.D.

Hacettepe University, School of Medicine, Department of Neurosurgery (Sİ, MB, OEÖ) and Pathology (BÖ, GG), Ankara - TÜRKİYE

Turkish Neurosurgery 2: 203 - 206, 1992

SUMMARY:

Lymphangiomas are benign, congenital lesions that develop from sequestered lymphatic sacs. They usually occur in the neck and axilla. In this paper, we report a case of lymphangioma of the scalp on extremely rare location.

KEY WORDS:

Lymphangioma, Scalp

INTRODUCTION

Lymphangiomas are rare benign lesions which are characterized by proliferating lymph vessels (1). These congenital tumors develop from sequestered lymphatic sacs (10,14). Although lymphangioma is a benign tumor, its infiltrative character complicates removal and contributes to postoperative recurrence (1). The majority of lymphangiomas occur in the neck and the axilla. To our knowledge, this is the first report of a scalp lymphangioma.

CASE REPORT:

A 16 year-old female patient was admitted to hospital with the chief complaint of right frontal subcutaneous swelling. This lesion was present at birth and has grown slowly since then. Her complaint was only cosmetic. At physical examination, there was a rubbery, painless mass, 4x3x2cm in size, under the scalp in the right frontal region (Fig.1). Neurological examination was within normal limits. The lesion was excised totally under general anesthesia. During the operation, minimal destruction was seen on the external table. Histopathological diagnosis revealed cavernous lymphangioma (Fig.2) (6). Follow up period of 4 years showed no signs of recurrence.

DISCUSSION

Lymphangiomas are slowly enlarging, well circumscribed, soft, cystic tumors. They are accepted as congenital malformation/tumor like lesions or vascular hamartomas rather than neoplasm (3,15). About 75% of lymphangiomas occur in the neck and 20% in the axillary region (1,7,13,14). In a small number of cases other locations including the mediastinum, retroperitoneum, oral cavity, mesentery, bones and orbit have been reported ((2,4,7,8,11,13). The sexes are affected equally (7). Usually these tumors present as easily compressible, painless enlargements that transilluminate well (5,8). At birth 50% are present and 90% are evident by two years of age(1,4,13). Clinically, they may rarely bleed spontaneously (2). Although lymphangioma is a benign tumor, its infiltrative tendency enables it to grow along tissue planes (1). It is usually fluctuant, lobulated and not attached to the skin but fixed to the deep tissues. Lymphangiomas consist of endothelial-lined spaces supported by a thin connective tissue base. These lesions often contain a thin, clear or straw coloured fluid, unless infected (1,2). If the space is contaminated by blood cells, the lesions can easily be mistaken fo

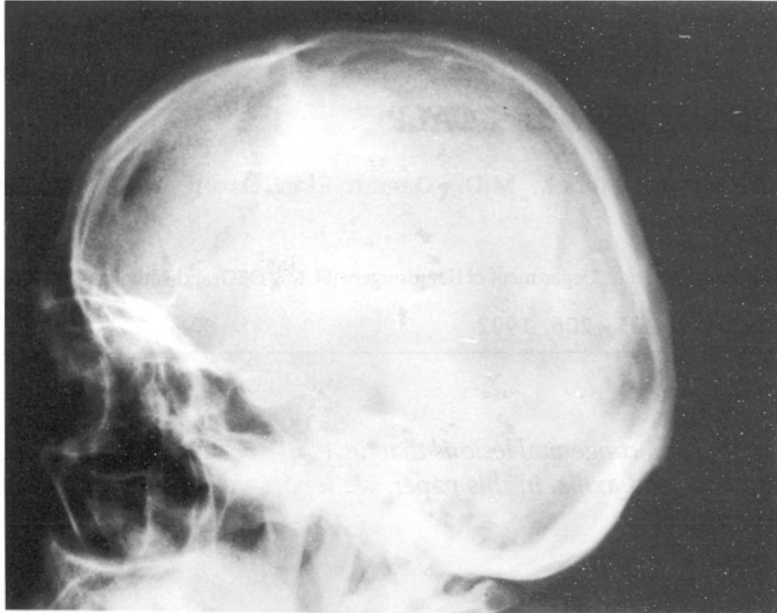


Fig. 1 : Lateral plain x-ray radiolucent area in the frontal region.

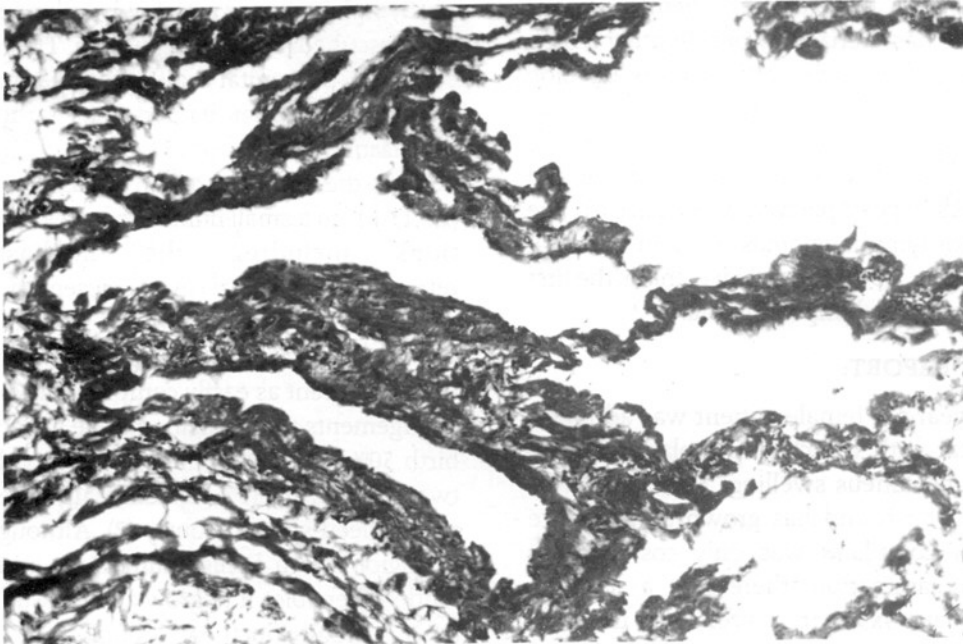


Fig. 2 : Irregularly shaped cystic spaces lined by a single layer of endothelium. Periendothelial connective tissue shows invariable collagen. (H.E., x30)

hemangioma. The mass may remain the same size or enlarge slowly but spontaneous remission is very rare (7,8). Histologically, lymphangiomas have been classified into three types: lymphangioma circumscriptum (papular angiokeratoma), classical lymphangioma circumscriptum (angiokeratoma circumscriptum) and cavernous lymphangioma (hygroma or cavernous hemangioma) (1,5,6,9,13). In the past, different kinds of therapy, such as aspiration and injection of sclerosing agents were applied to these tumors (4,8). Radiotherapy is unsatisfactory and is no longer used because of its failure to completely damage the tumor, but if total removal fails, radiation may be indicated (4,13).

Total surgical excision is the treatment of choice for lymphangiomas and offers the best chance of cure (1,4,5,7,8,12,13). Surgery is advised sooner rather than later, as excision is technically easier before the tumor has invaded normal tissue, further and before infection has occurred and causing fibrosis and scarring. Recurrence of lymphangioma following subtotal excision is generally said to occur within one year (4).

For correspondence: Servet İnci
Emek Mah. 4. Cad. 70/8 Ankara
06510 TÜRKİYE

REFERENCES

1. Brown L, Reiman H, Rosonow EC.III, et al. Intrathoracic Lymphangioma. Mayo Clin Proc 61:882-892, 1986
2. Coll GE, Goldberg RA, Krauss H, et al. Concomitant lymphangioma and arteriovenous malformation of the orbit. Am J Ophthal 112:200-205, 1991
3. Cotran RS, Kumar V, Robbins SL: Robbins pathologic basis of disease. 4th ed., W.B. Saunders, Philadelphia, 1989 p.538.
4. Emery PJ, Bailey CM and Evans JNG. Cystic hygroma of the head and neck. J Laryngol Otol 98:613-619, 1984
5. Kittredge RD, Fihby N. The many facets of lymphangioma. Am J Roentgenol 95:56-66, 1965
6. Lever WF, Schaumberg-Lever G: Histopathology of the skin. Lippincott, 6th ed., Philadelphia, pp. 631-3, 1983
7. Nanson EM. Lymphangioma (Cystic Hygroma) of mediastinum. J Cardiovasc Surg 9:447-452, 1968
8. Osborne TE, Levin LS, Tilghman DM, et al. Surgical correction of mandibulofascial deformities secondary to large cervicalcystic hygromas. J Oral Maxillofacial Surg 45:1015-1020, 1987
9. Paletta FX. Lymphangioma. Plast Reconst Surg 37:269-279, 1966
10. Poslethwaite KR. Lymphangiomas of the tongue. Br J Oral and Maxillofacial Surgery. 24:63-68, 1986
11. Rosenquist CJ, Wolfe DC. Lymphangioma of bone. J Bone and Joint Surg 50:158, 1968
12. Scally CM, Black JHA. Cystic Hygroma: Massive recurrence in adult life. J Laryngol Otol 104:908-910, 1990.
13. Siegel MJ, Glazer HS, Amour TE, et al. Lymphangiomas in children: MR imaging. Radiology 170:467-470, 1989.
14. Singh S, Baboo ML, Pathak IC. Cystic lymphangioma in children: Report of 32 cases including lesions at rare sites. Surgery 69:947-951, 1971
15. Walter JB, Israel MS: General Pathology. 6th ed., Churchill Livingstone, Edinburgh, 1987 pp.377-379