



# Use of Spongostan™ for Prevention of Cranial Subdural Adhesions Following Craniotomy in an Experimental Rabbit Model

## *Deneysel Tavşan Modelinde Kraniyotomi Sonrası Kraniyal Subdural Adezyonların Önlenmesinde Spongostan™ Kullanımı*

Cagatay OZDOL<sup>1\*</sup>, Fatih ALAGOZ<sup>2\*</sup>, Ali Erdem YILDIRIM<sup>2</sup>, Murat KORKMAZ<sup>3</sup>, Ergun DAGLIOGLU<sup>2</sup>, Pergen ATILLA<sup>4</sup>, Sevda MUFTUOGLU<sup>4</sup>, Ahmet Deniz BELEN<sup>2</sup>

<sup>1</sup>*Antalya Education and Research Hospital, Department of Neurosurgery, Antalya, Turkey*

<sup>2</sup>*Ankara Numune Education and Research Hospital, Department of Neurosurgery, Ankara, Turkey*

<sup>3</sup>*Kutahya Evliya Celebi Education and Research Hospital, Department of Neurosurgery, Kutahya, Turkey*

<sup>4</sup>*Hacettepe University of Medical School, Department of Histology and Embryology, Ankara, Turkey*

*\*The authors contributed this study equally.*

**Corresponding Author: Ergun DAGLIOGLU** / E-mail: ergundaglioglu@gmail.com

### ABSTRACT

**AIM:** Spongostan™ is a sterile, water-insoluble, porcine gelatin absorbable sponge, which is widely used as a hemostatic material. The aim of this study is to test the anti-fibrotic capacity of Spongostan™, using a craniotomy model in an experimental rabbit model.

**MATERIAL and METHODS:** Eighteen rabbits were divided into two groups: Each group consisted of 9 rabbits, duratomy plus Spongostan™ (group 1), and duratomy without Spongostan™ (group 2). Right parietal bone was removed via trephine and low speed drill and dura was opened. On the group 1 rabbits, an appropriate piece of Spongostan™ was meticulously placed under dural layer. On group 2 rabbits, same procedures were repeated without Spongostan™. Histological sections were taken from each group and evaluated for degree of fibrosis and collagen fibers.

**RESULTS:** There was marked increase in number of fibroblasts and collagen fibers in group 2 rabbits, however most of the rabbits in Spongostan™ group demonstrate scarce histopathological findings for fibrosis.

**CONCLUSION:** We conclude that an appropriately placed subdural Spongostan™ over cerebral tissue may prevent postoperative surgical adhesions after neurosurgical operations.

**KEYWORDS:** Craniotomy, Rabbits, Spongostan™, Subdural fibrosis, Surgery

### ÖZ

**AMAÇ:** Yaygın olarak hemostatik amaçla kullanılan Spongostan™, steril, suda çözünen bir süngerdir. Çalışmanın amacı deneysel tavşan kraniyotomi modelinde Spongostan™'in fibrozisi önleme kapasitesini incelemektir.

**YÖNTEM ve GEREÇLER:** On sekiz tavşan 2 gruba ayrıldı: Her grup 9 tavşan içermektedir: Grup 1: duratomi yapıp Spongostan™ konulan grup ve Grup 2: Spongostan™ kullanılmadan duratomi yapılan grup. Düşük hızlı drill ile sağ parietal kemik çıkarıldı ve dura açıldı. Grup 1 tavşanlarına, uygun parça Spongostan™ dural tabakanın altına yerleştirildi. Grup 2 tavşanlarına aynı işlem yapıldı ancak Spongostan™ konulmadan dura kapatıldı. Her gruptan histolojik kesitler alındı, fibrozis derecesi ve kollajen lifler yönünden incelendi.

**BULGULAR:** Spongostan™ konulmadan durası kapatılan tavşanlarda fibroblast ve kollajen lif miktarında anlamlı artış gözlenmiştir ancak diğer grupta histopatolojik olarak fibrozis çok seyrek görülmüştür.

**SONUÇ:** Serebral dokunun üzerine uygun şekilde yerleştirilmiş subdural Spongostan™, nörocerrahi sonrası postoperatif cerrahi yapışıklıkları engelleyebilir.

**ANAHTAR SÖZCÜKLER:** Kraniyotomi, Tavşanlar, Spongostan™, Subdural fibrozis, Cerrahi

### INTRODUCTION

Reoperations in neurosurgical practice pose a significant risk due to adhesions developed after primary surgery. This fact should be taken into account particularly in patients who might necessitate reoperations due to recurrence of tumor

or spinal operations. In fact, prevention of epidural fibrosis is significantly associated with postoperative reduced pain after spinal procedures. Numerous reported studies address to importance of decreased epidural fibrosis after spinal operations (4, 6, 13, 21). Thus, the scope of many current

clinical and experimental reports is mainly prevention of epidural fibrosis (2, 5, 8, 10, 19, 23, 27). Fibrosis is not only a problem in spinal operations but also a problem in cranial operations like cerebellopontine angle and posterior fossa tumors, cranioplasty or treatment of intracranial infections (12, 14, 16).

In fact, the main concept regarding fibrosis is decreased microvasculature and less permeability for agents like antibiotics and anti-inflammatory drugs. Accordingly, studies towards decreased fibrosis point to an improved healing process (25,26). Furthermore, subdural adhesions and bands that include vascular adhesions to cortical arteries and veins usually create a problem in patients previously operated for intracranial tumors. Dural opening and subarachnoid dissection of brain-arachnoid membrane might increase the surgical risk and length of operation. Up to date, there was not any report pointing to the prevention of subdural adhesions after cranial approaches, nevertheless there are several reports which pointed to the reactive potential of the dural and arachnoid membrane (3, 7, 13, 24).

Spongostan™ (Absorbable Haemostatic Gelatin Sponge, Johnson and Johnson Ethicon Inc, USA) is a sterile, water-insoluble, malleable, porcine gelatin absorbable sponge intended for hemostatic use by applying locally to the bleeding surface. It is a widely used hemostatic material in many fields of surgery. The present experimental study in rabbits focuses on the use of Spongostan™ as a preventive measure for dural or arachnoidal adhesions to cortex. To our knowledge this is the first study that investigates the Spongostan™ to prevent fibrous adhesions after cranial surgery.

## **MATERIAL and METHODS**

### **Experimental Protocol**

Study guidelines and experimental protocol was approved by Ethical Committee of Ankara State Hospital (May 2012/102) and all experimental procedures were performed at Animal Laboratory of the same hospital. Eighteen New Zealand rabbits (2.45 kg mean weight) were used in this study and randomized into two groups: group 1: duratomy plus Spongostan™ patch group and group 2: standard duratomy group.

### **Experimental Procedure and Tissue Preparation**

After induction of intramuscular anesthesia with a mixture of intraperitoneal ketamine (80 mg/kg) and xylazine (10 mg/kg), all rabbits were placed at prone position. Scalp was prepared with polyvinylpyrrolidone iodine (Polyod®, 10% solution, Drogan Pharm. Company, Ankara, Turkey). Incision was made at the midline to prepare both parietal regions similar to report described by Alberius et al. (1). Preparation of craniotomy flaps was performed using a diamond wheel (may produce bone defects as small as 4 mm) and a trephine (4 mm in diameter) mounted on a low-speed drill under irrigation of physiological saline to avoid thermal injury. The cranium piece removed via this drill may easily be removed with a simple

microdissector. Every effort was done to avoid perforation of dura mater. The procedure was performed on right parietal regions. A "C" shaped incision was used for dural opening and Spongostan™ patch (size wider than dural incision, prepared just before procure under sterile conditions) was properly positioned into subdural space of right parietal region. Similar procedure was repeated in Group 2 rabbits except insertion of Spongostan™ under dura mater.

An ultrathin and adequate piece of Spongostan™ material was carefully implanted under the dura mater in group 1, and dura mater closure was performed meticulously in both group 1 and 2. Dura was closed by primary interrupted a few single suture similar to procedures during neurosurgical interventions. Rabbits were kept in separate cages after the experiment and fed with standard diet for 3 months.

All rabbits were sacrificed 90 days after procedure with a lethal dose of anesthesia. The samples for histological examination were removed as single layer of brain, dura mater and cranium in such a manner that the dural samples were successfully obtained from areas at least 5 mm away from the experimental zone of both parietal regions of group 1 (9).

### **Histological Examination**

Histopathologists that are blind to the experimental protocol examined all histopathological preparations. The brain samples including the meninges were fixed in 8 mL (10% buffered formaldehyde) for 4 days and decalcified in Shanden TBD-2 solution. Milimetric sections were processed and washed for 3 hours for deacidification process. The sections were subjected to series of formaldehyde, alcohol and xylene solutions in accordance with the procedure described by Nordstrom et al. (17). The stained specimens were thoroughly examined for collagen fibers and fibroblasts. Processed samples were embedded in paraffin and 5-micrometer thick sections were stained with hematoxylin-eosin. Stained sections were examined with Leica DM6000B light microscope and digital micrographs are captured to computer by Leica DC 500 digital camera.

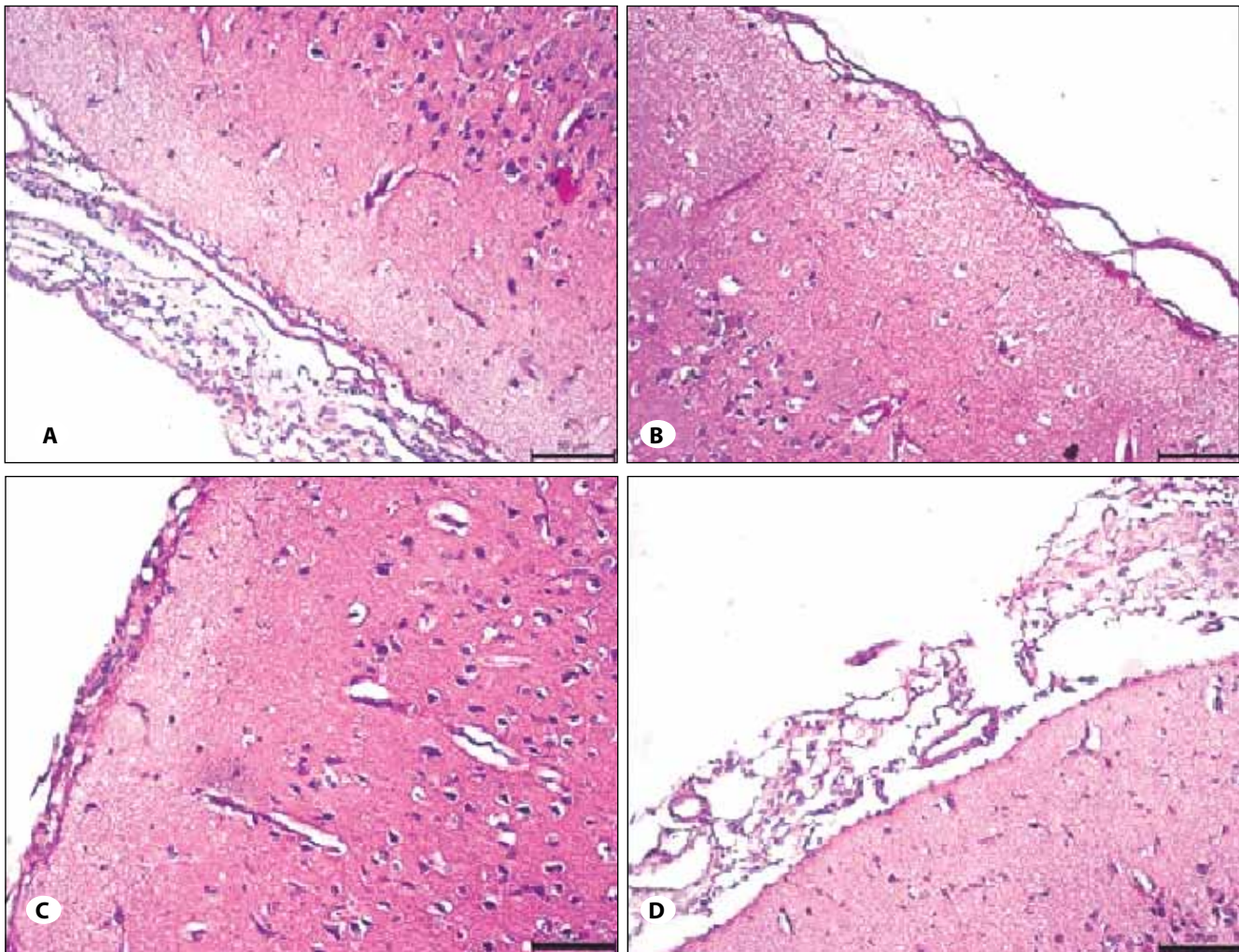
### **Statistical Analysis**

Statistical analysis was performed using NCSS (Number Cruncher Statistical System) 2007 Statistical Software (Utah, USA) program. Chi-square test - Fischer's exact test was used for comparison of quantitative data between groups. P value <0.05 was considered significant.

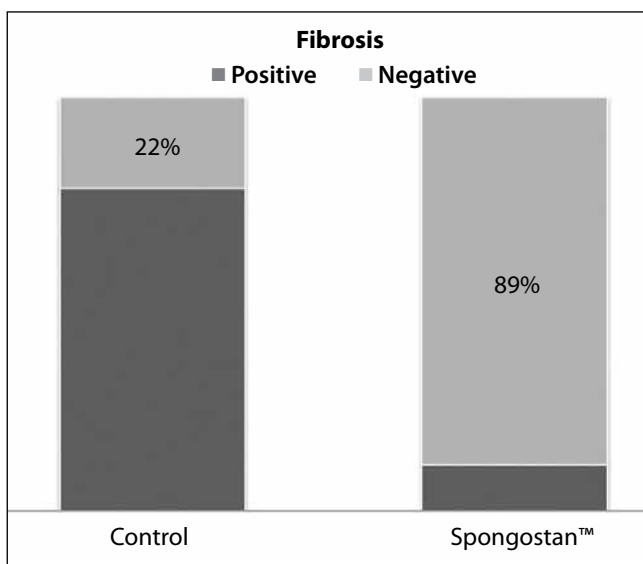
## **RESULTS**

In most of the samples of control group (group 2) localized fibrosis were observed (77.7%). Collagen fibers were scattered irregularly and fibroblasts were present in between the collagen fibers (Figure 1A). In two of the samples of control group the thicknesses of the meningeal layers (pia mater, arachnoid and dura mater) were normal and fibrosis was not reported (Figure 1B).

In the Spongostan™ group (group 1) there was no fibrosis in most of the samples (Figure 1C) but in one of the sample



**Figure 1:** Histopathological demonstrations of brain samples (Control group A&B: Localized intensive fibrosis in most of the control group samples (A), and a sample without fibrosis (B). Spongostan™ group C&D: Dura mater, arachnoid and pia mater are in normal thickness (C). A sample characterized with mild fibrosis (D). (Hematoxylin-EosinX200).



**Figure 2:** Comparison of fibrosis rates according to groups.

mild fibrosis was observed (11.1%) ( $p=0.015$ ). When the fibrotic tissue was compared with the control group, there was a looser connective tissue in the Spongostan™ group with irregularly arranged thin collagen fibers and fibroblasts (Figure 1D).

Percentage of fibrosis prevalence according to groups was demonstrated in Figure 2, which showed significant lower rates of fibrosis in Spongostan™ group.

#### DISCUSSION

Spongostan™ is a sterile porcine gelatin absorbable sponge mostly intended for haemostatic use. It is a widely used hemostatic material used in many fields of surgery usually by insertion to bleeding surfaces. This experimental study in rabbits focuses on the use of Spongostan™ as a preventive measure for dural or arachnoidal adhesions to cortex. To our knowledge this is the first experimental study that demonstrated the local use Spongostan™ to prevent arachnoid or fibrous adhesions after cranial surgery.



Local inflammation after craniotomy starts with hemostasis and provisional wound matrix followed by inflammatory and regenerative phases. An important pioneer phase in the process of wound healing is the proliferative phase, which appears 3 to 10 days after initial inflammatory phase. Nevertheless the critical phase of wound healing in terms of adhesions and fibrosis is proliferative phase and last step of this phase is characterized by development of the acute granulation tissue. Fibroblast is typical precursor of the provisional wound matrix. Remodeling phase might produce a scar characterized by fibrosis at the local area of dura, bone and cerebral tissue (22). Previous studies with dural substitutes resulted in fibrosis. It might be stated that a defect in restoration of the vascular network at the area of injury and granulation tissue may result in less adhesions between dura-arachnoid membrane and cerebral cortical tissue. We conclude that an inert barrier between dura and cerebral tissue may aid in decreasing adhesions during healing process.

Efforts for searching methods for preventing the postoperative adhesions between the dura mater and the cortex date back to 1976. Meskhiia reported an experimental study article in Russian and stated that the adhesive process after wound healing depends on the presence and intensity of brain and meningeal injuries (15). It is clear that the healing process is also related with the tension around the wound edges and tight closure may be associated with increased fibrosis or separation of the wound edges. Efforts to decrease inflammation also include the suture material or graft type used at the site of craniotomy (11, 18). Nevertheless factors decreasing inflammation during healing clearly aid in reduction of fibrosis. Ideal material between dura-arachnoid membrane and cerebral pial cortex has to be inert and create minimal tissue reaction or inflammatory process. In addition, the material should also be thin in order not to create tension between dural edges. There were interesting reports pointing to prevention of adhesions in cranial or spinal epidural layer (3, 4, 6, 13, 20). In the present study, no fibrosis was observed in most of the samples of the Spongostan™ group and looser connective tissue dominates the field of study with irregularly arranged thin collagen fibers and fibroblasts. This denotes to decreased fibrosis, which probably is associated with less meningocortical adhesions.

We conclude that a regularly shaped and thin piece of Spongostan™ placed between dura-arachnoid layers may prevent arachnoid adhesions to cortical gray matter. This may be effective procedure which may support an improved healing process as well as decreased risk of reoperations.

#### REFERENCES

1. Alberius P, Klinge B, Isaksson S: Management of craniotomy in young rabbits. *Lab Anim* 23:70-72, 1989
2. Andrychowski J, Frontczak-Baniewicz M, Sulejczak D, Kowalczyk T, Chmielewski T, Czernicki Z, Kowalewski TA: Nanofiber nets in prevention of cicatrization in spinal procedures. *Experimental study. Folia Neuropathol* 51:147-157, 2013
3. Barbolt TA, Odin M, Léger M, Kangas L, Hoiste J, Liu SH: Biocompatibility evaluation of dura mater substitutes in an animal model. *Neurol Res* 23:813-820, 2001
4. Geisler FH: Prevention of epidural fibrosis: Current methodologies. *Neurol Res* 21:9-22, 1999
5. Häckel M, Masopust V, Bojar M, Ghaly Y, Horínek D: The epidural steroids in the prevention of epidural fibrosis: MRI and clinical findings. *Neuro Endocrinol Lett* 30:51-55, 2009
6. Haq I, Cruz-Almeida Y, Siqueira EB, Norenberg M, Green BA, Levi AD: Postoperative fibrosis after surgical treatment of the porcine spinal cord: A comparison of dural substitutes. *J Neurosurg Spine* 2:50-54, 2005
7. Huang YH, Lee TC, Chen WF, Wang YM: Safety of the nonabsorbable dural substitute in decompressive craniectomy for severe traumatic brain injury. *J Trauma* 71:533-537, 2011
8. Ismailoglu O, Albayrak B, Gulsen I, Tanriover G, Demir N: Topical application of tacrolimus prevents epidural fibrosis in a rat postlaminectomy model: Histopathological and ultrastructural analysis. *Turk Neurosurg* 21:630-633, 2011
9. Kadioglu HH, Takci E, Arik M, Gundogdu C, Aydin IH: Immune response to dehydrated human dura mater: Evaluation in a rabbit model. *Neurology India* 3:256-261, 2002
10. Karatay M, Erdem Y, Koktekir E, Erkok YS, Caydere M, Bayar MA: The effect of bevacizumab on spinal epidural fibrosis in a postlaminectomy rat model. *Turk Neurosurg* 22:753-757, 2012
11. Kim DW, Eum WS, Jang SH, Park J, Heo DH, Sheen SH, Lee HR, Kweon H, Kang SW, Lee KG, Cho SY, Jin HJ, Cho YJ, Choi SYJ: A transparent artificial dura mater made of silk fibroin as an inhibitor of inflammation in craniotomized rats. *J Neurosurg* 114:485-490, 2011
12. Kroin JS, Buvanendran A, Cochran E, Tuman KJ: Characterization of pain and pharmacologic responses in an animal model of lumbar adhesive arachnoiditis. *Spine (Phila Pa 1976)* 30:1828-1831, 2005
13. Kurt G, Cemil B, Celik B, Durdag E, Erdem O, Ceviker N: Comparison of Oxiplex and Gore-Tex effectivity in an experimental peridural fibrosis model. *Neurocirugia (Astur)* 20:360-366, 2009
14. Lara-de-la-Fuente R, Alanís-Cruces JM: Postoperative fibrosis after lumbar surgery. *Acta Ortop Mex* 23:90-93, 2009
15. Meskhiia NSh: Meningo-cerebral adhesions and the possibility of prevention during plastic replacement of meningeal defects (experimental study). *Vopr Neurokhir* 4:37-41, 1976
16. Nakano M, Matsui H, Miaki K, Yamagami T, Tsuji H: Postlaminectomy adhesion of the cauda equina. Changes of postoperative vascular permeability of the equina in rats. *Spine (Phila Pa 1976)* 22:1105-1114, 1997
17. Nordstrom MR, Wang TD, Neel III HB: Dura mater for soft tissue augmentation: Evaluation in a rabbit model. *Arch Otolaryngol Head Neck Surgery* 119:208-214, 1993
18. Palm SJ, Kirsch WM, Zhu YH, Peckham N, Kihara S, Anton R, Anton T, Balzer K, Eickmann T: Dural closure with nonpenetrating clips prevents meningoneural adhesions: An experimental study in dogs. *Neurosurgery* 45:875-882, 1999

19. Park JO, Lee BH, Kang YM, Kim TH, Yoon JY, Kim H, Kwon UH, Lee KI, Lee HM, Moon SH: Inflammatory cytokines induce fibrosis and ossification of human ligamentum flavum cells. *J Spinal Disord Tech* 26:E6-12, 2013
20. Preul MC, Bichard WD, Spetzler RF: Toward optimal tissue sealants for neurosurgery: Use of a novel hydrogel sealant in a canine durotomy repair model. *Neurosurgery* 53:1189-1199, 2003
21. Preul MC, Campbell PK, Garlick DS, Spetzler RF: Application of a new hydrogel dural sealant that reduces epidural adhesion formation: Evaluation in a large animal laminectomy model. *J Neurosurg Spine* 12:381-390, 2010
22. Reinke JM, Sorg H: Wound repair and regeneration. *Eur Surg Res* 49:35-43, 2012
23. Robertson JT, Soble-Smith J, Powers N, Nelson PA: Prevention of cerebrospinal fistulae and reduction of epidural scar with new surgical hemostat device in a porcine laminectomy model. *Spine (Phila Pa 1976)* 28:2298-2303, 2003
24. Sato M, Kuwana N, Kojima Y, Tanaka N, Kitamura H: Chronic subdural hematoma with a markedly fibrous hypertrophic membrane. Case report. *Neurol Med Chir (Tokyo)* 30:838-841, 1990
25. Wagner KJ, Sprenger T, Pecho C, Kochs EF, Tölle TR, Berthele A, Gerdesmeyer L: Risks and complications of epidural neurolysis: A review with case report. *Anesthesiol Intensivmed Notfallmed Schmerzther* 41:213-222, 2006
26. Warnke JP, Mourgela S: Adhesive lumbar arachnoiditis. Endoscopic subarachnoepidurostomy as a new treatment. *Nervenarzt* 78:1182-1187, 2007
27. Zeinalizadeh M, Miri SM, Ardalan FA, Maleki F, Zakeri M, Aghajanzadeh E, Habibi Z: Reduction of epidural fibrosis and dural adhesions after lamina reconstruction by absorbable cement: An experimental study. *Spine J* 14:113-118, 2014