

# Sagittal Balance in the Spine

## Omurgada Sagittal Denge

Ali Fahir OZER<sup>1</sup>, Tuncay KANER<sup>2</sup>, Çağlar BOZDOĞAN<sup>2</sup>

<sup>1</sup>Koc University, Faculty of Medicine, Department of Neurosurgery, Istanbul, Turkey

<sup>2</sup>Istanbul Medeniyet University, Faculty of Medicine, Department of Neurosurgery, Istanbul, Turkey

Corresponding Author: Ali Fahir OZER / E-mail: alifahirozer@gmail.com

### ABSTRACT

This chapter explains the significance of the sagittal balance of the spine and spinal and pelvic parameters associated with sagittal balance of the spine. Herein the parameters related to spinal sagittal balance are C7 plumb line, gravity line, pelvic incidence, sacral slope, pelvic tilt and spino-sacral angle (SSA).

**KEYWORDS:** Sagittal balance, Pelvic incidence, Sacral slope, C7 plumb line

### ÖZ

Bu makalede omurgada sagittal dengenin önemi ve sagittal denge ile bağlantılı olan spinal ve pelvik parametrelerden bahsedilmektedir. Omurgadaki sagittal denge ile ilişkili anlatılan parametreler C7 plumb çizgisi, gravity çizgisi, pelvik insidans, sakral eğim, pelvik tilt ve spino-sakral açıdır.

**ANAHTAR SÖZCÜKLER:** Sagittal denge, Pelvik insidans, Sakral eğim, C7 plumb çizgisi

### SAGITTAL BALANCE

In a normally balanced spine, when someone is standing, the vertical line drawn downwards is the Sagittal Vertical Axis (SVA), i.e., the C7 plumb line that passes through the posterior upper side of the sacrum. Likewise, when someone is standing, the center of mass is on the front side of the thoracic spine and is close to the lumbar region. The vertical line drawn downwards from this point passes through the center of the femur head in parallel with the sacral second spine, and touches the ground at the heel (gravity line). This is how a human being can stand up straight by taking support from the ground. In people who have normally balanced spines, these two lines are in harmony with each other. As a result of this harmony between the two lines, when we look at a normal person from above, we observe that the projection of the head remains within the outline of the pelvis. Compensation of the sagittal balance indicates the effort required by the body to retain the harmony between these two lines in case of any pathological incidences. When this harmony cannot be maintained, the incidence comes is considered a sagittal imbalance.

The most commonly observed cause of imbalance in the spine is a deformation of the waist, which should not be surprising because the waist is a mobile organ with the greatest weight burden.

The relation of the lumbar region to the pelvis was defined first by Jackson (1) using the "Pelvis Radius" technique. However, these parameters did not to always reflect actual alignment. Moreover, this measurement was criticized for not reflecting the balance of the entire spine by including the thoracic and

cervical regions and for leading to a number of measurement errors.

Baupere (2) defined another important method relating to the pelvic parameters: the Duval-Baupere method and the pelvic incidence. This measurement method also does not fully show the balance of the spine; however, this method more clearly indicates how much the pelvis and spine move in harmony with each other and whether there is any spinal imbalance. By drawing a line from the center of the sacral plateau to the femur head, the pelvic width can be determined.

This helps to understand the type of pelvis being examined. When we add a vertical line to the center of the sacral plateau, the angle it makes with the line reaching here from the femur head provides information on the pelvis width; this angle is called the "sacral incidence".

Sacral incidence equals the sum of the angle that identifies the status of the pelvis, which is called "pelvic tilt", and the sacral slope angle measuring the tilt in sacrum ("sacral slope"). The angle that describes the status of the pelvis ("pelvic tilt") is the angle that is formed by the vertical line passing through the femur head and the line linking to the center of the sacral plateau. Contrarily, the sacral slope angle ("sacral slope") is the angle between the line drawn tangent to the sacral plateau and the vertical line passing through the center of the sacral plateau (Figure 1). In summary, the sacral incidence is a meaningful parameter that provides information on the geometry of the pelvis and its orientation in space. If the pelvic incidence is 40, the pelvis in question is narrow; however, if the pelvic incidence is 70, the pelvis in question is broad.

The pelvis might perform ante- or retro-versions to adjust its balance with the spine. Retro-version is much more limited and can achieve a compensation of 10 with the deflection of the hip joints.

Pelvic incidence is 52.6 with +/- 10.4; pelvic tilt is 13 with +/- 6.8; and the sacral slope is 39.6 with +/- 7.9. In short, the pelvic tilt should be less than the half of the pelvic incidence value, and the sacral slope should be greater than the half of the pelvic incidence value to maintain balance in the spine.

Roussouly (3) stated in 2006 that the gravity line and the plumb line of a standing person might not match but that the person could still maintain a balanced state. The plumb line or the standard sagittal balance means that the vertical line tangential to the C7 spine in a balanced state extends downwards by passing through the back of the sacral plateau (Figure 2). Roussouly indicated that a large fraction society had variations of the shape of the spine, and emphasized the significance of having a posture (stance) with optimal harmony between the pelvis and spine. He stated that sagittal balance with a normal harmony, which demonstrates the harmony between the spine and pelvis, was the unique arrangement that enabled the spine array to spend the least amount of energy while standing.

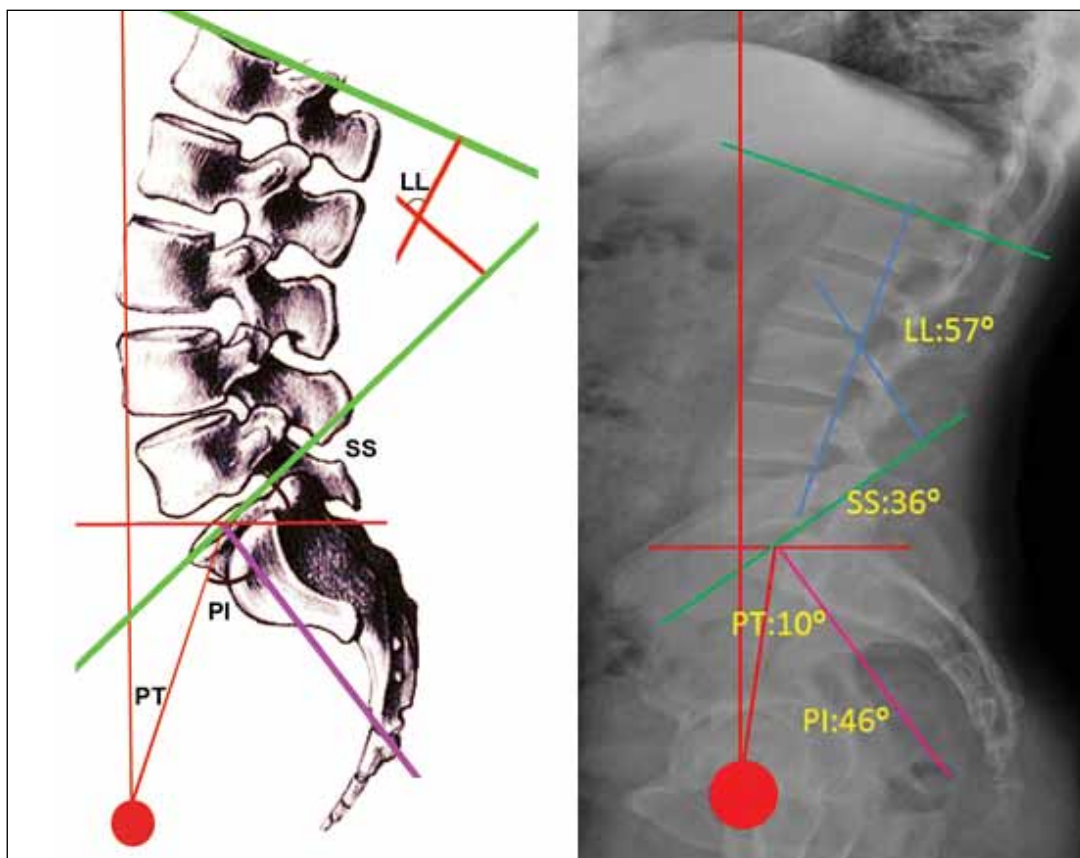
The plumb line is in an "ideal" status with a sacral incidence of approximately 50. The analysis on the lumbar lordosis showed that participation to the lumbar lordosis value was

3% for the L1-L2 segment, 12% for the L2-L3 segment, 18% for the L3-L4 segment, 27% for the L4-L5 segment, and 48% for the L5-S1 segment. These results indicate that lumbar lordosis is supplied mostly by the two lower segments. The practical result of this analysis is that failure to provide these two segments with lumbar lordosis during a surgical operation will cause a straight back deformity.

Concerning studies conducted with volunteers, Schwab showed how the gravity line affected the pelvic parameters (4,5). In addition, Roussouly (3) developed a new method to evaluate the sagittal balance of the spine. Thus, Roussouly defined the sagittal balance of the entire spine by including the thoracic and cervical regions and characterized their relation to each other.

Roussouly evaluated the shape and angles of the spines of 709 asymptomatic volunteers. Roussouly specified four different types of spinal alignment within the framework of his categorization of the human spine (Figure 3). Of these different types, lumbar lordosis is formed based on the sacral slope. Roussouly indicated that he observed 5% of Type I, 23% of Type II, 47% of Type III, and 25% of Type IV spine shapes (3).

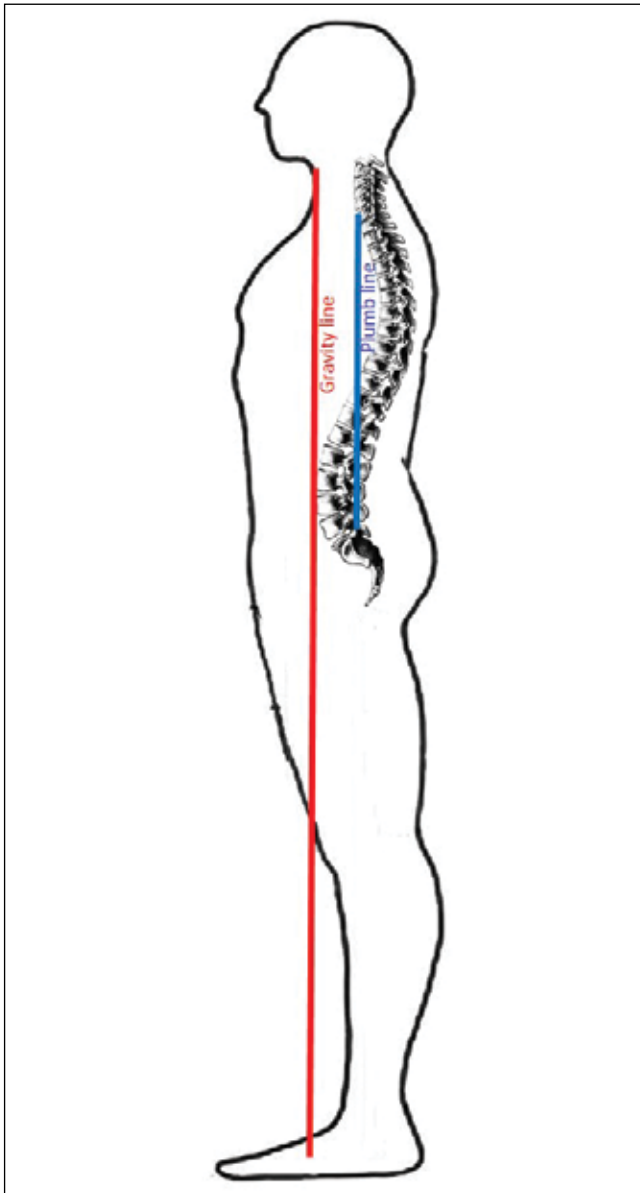
The findings of the above-mentioned analysis follow: In Type I, the lumbar apex is in the middle of L5, and the sacral slope (SS) angle in the spine is <35°; in Type II, the lumbar apex is inferior to the L4, and the SS angle is <35° and superior; in Type III, the lumbar apex is in the middle of L4, and the SS



**Figure 1:** Pelvic incidence measured using the Duval-Beaupere method (SS=Sacral Slope, PI= Pelvic Incidence, PT= Pelvic Tilt).

angle is  $35 < SS < 45$ ; and with the Type IV, the lumbar apex is at the bottom of L3, and the SS angle is  $> 45$  (Figure 4).

The Roussouly measurement method makes it possible to measure the whole spine on a sagittal plane. Knowing the shape and location of the pelvis and the morphology of the lumbar lordosis is the key to treating backaches. Because lumbar lordosis is determined by the last three levels and 80%



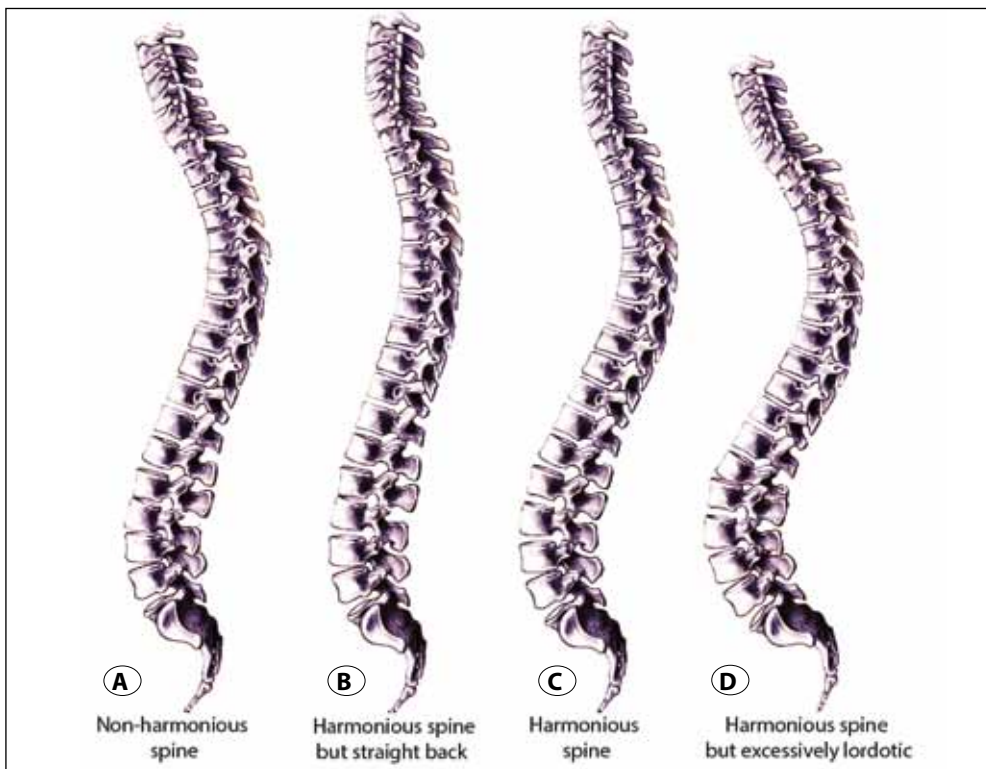
**Figure 2:** The center of mass of the human body is located in front of the thoracic spine and is close to the lumbar region. The vertical line drawn downwards from the center of mass is known as the “gravity line”. Passing through the femoral capitula, this line follows the legs and reaches the ground at the feet, regarded as the point of support. Whereas the plumb line, is the vertical line slightly touching the C7 in a balanced spine in the sagittal plane that passes through the posterior side of the sacral plateau. Normally, the gravity line is always in front of the plumb line.

of the backaches are caused by the disk degeneration between the fourth and fifth lumbar (L4-L5) spine and between the fifth lumbar and first sacral (L5-S1), these measurements are of critical importance for treating patients suffering from backaches. If the patient is not provided with sufficient lumbar lordosis during a surgical operation, the body will move forth; consequently, the patient will experience screw crashes, pseudoarthrosis, straight back formation and will suffer from backaches.

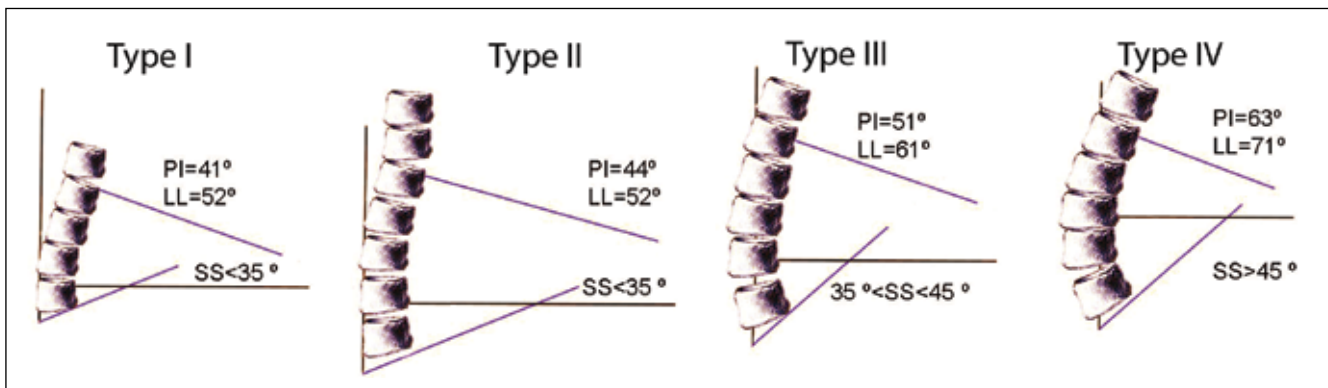
Clinical practices correspond to the relative measurement values of the patient and the data collected in this analysis. Based on the above-mentioned analysis, it is possible to predict the type of diseases that will form in different spine types. For instance, Roussouly called the Type I spine “the spine with no harmony”. In this spine type, posterior constituents are under high pressure in the lumbar region, and it is possible to observe the spinous processes in contact with each other.

These changes eventually increase the risk of spondylolisthesis formation due to hyperextension. Furthermore, the risk of thoracolumbar discopathy formation is much higher in this spine type. Type II spine has a harmonious array, but the patient experiences the straight back syndrome. In this spine type, disks are under great pressure and there is a risk of early degeneration (and disk herniation). Type III spine represents the most harmonious array. However, the disk tissue collapses with increasing age and a number of changes in the shape of the spine occur. Type III spine can evolve into Type I or Type II over time. Type IV spine also has a harmonious array and is arranged in an excessively lordotic form. With this type of spine, pressure is mostly on the main facet joints. Therefore, this spine type is prone to experience early facet arthropathies. Likewise, this spine type confers a higher risk of lumbar stenosis and spondylolisthesis formation compared to the other spine types.

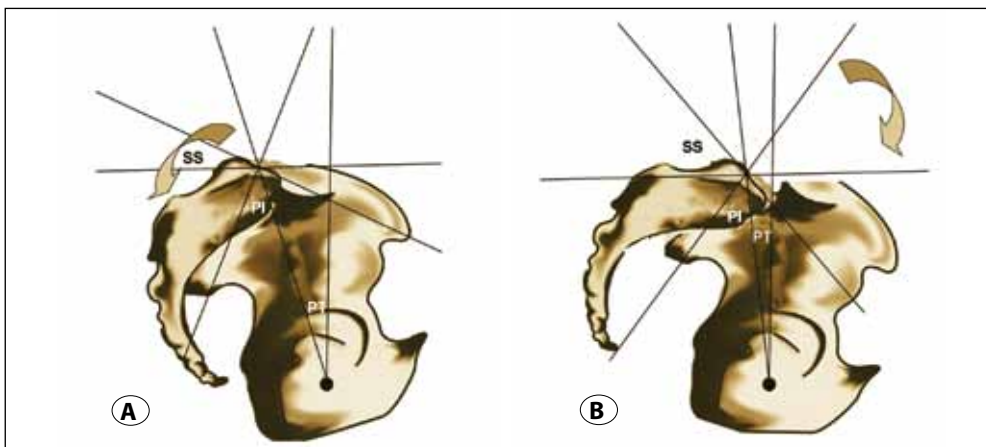
The relationship of the pelvis to the spine can easily be determined by adapting Duval-Beaupere’s pelvic incidence method into this system. As a result of the straight back deformity, which is formed due to the degenerative disk disease in the spine, the pelvis slowly begins to make a backward angle; at the same time, the pelvic tilt increases, the pelvic incidence decreases, and the sacral slope angle increases (Figure 5 A, B). By following Roussouly’s method, we can move beyond the evaluation of the relation between the pelvic parameters and the lumbar spine and can assess the relationship of the pelvic parameters with the whole body stance as well as to the thoracic and lumbar spine. If C7 is in the correct position, cervical lordosis is followed by thoracic kyphosis and lumbar lordosis, and the latter two are followed by normal pelvic parameters (Figure 6). The relation of the pelvis to the spine has been evaluated by means of the spinosacral angle and pelvic tilt. The “spinosacral angle” is the angle between the line drawn from the front side of T1 to the middle of the sacral plateau, and the line slightly touching the sacral plateau (Figure 7).



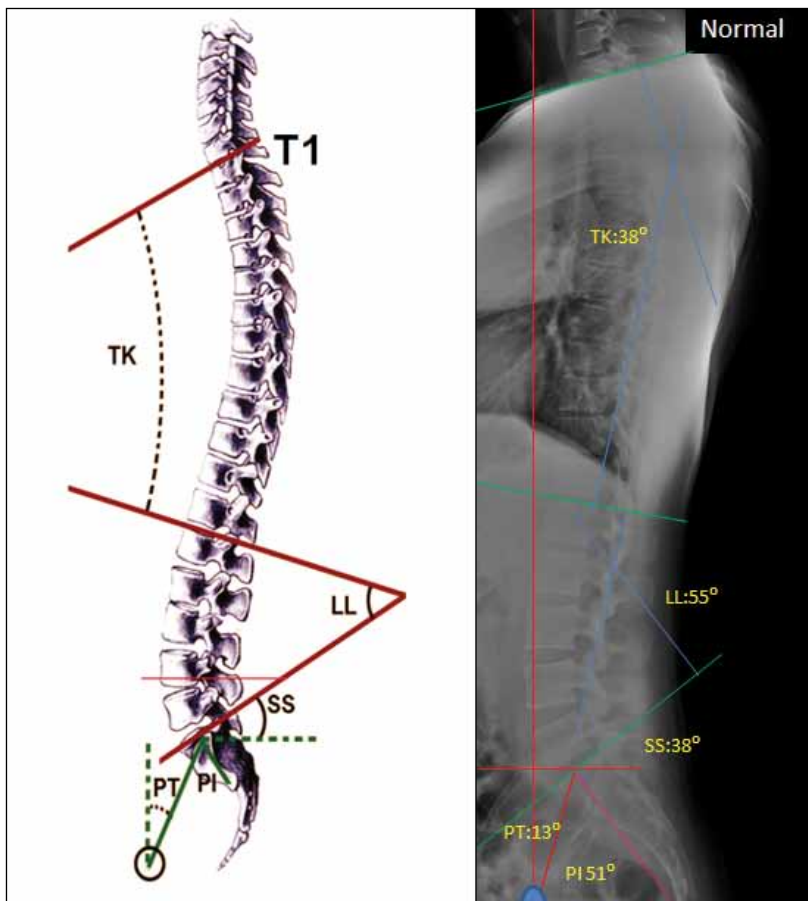
**Figure 3:** Roussouly's categorization of the spine: **A)** Type I: Non-harmonious spine; **B)** Type II: Harmonious spine, but straight back **C)** Type III: Harmonious spine **D)** Type IV: Harmonious spine, but excessively lordotic.



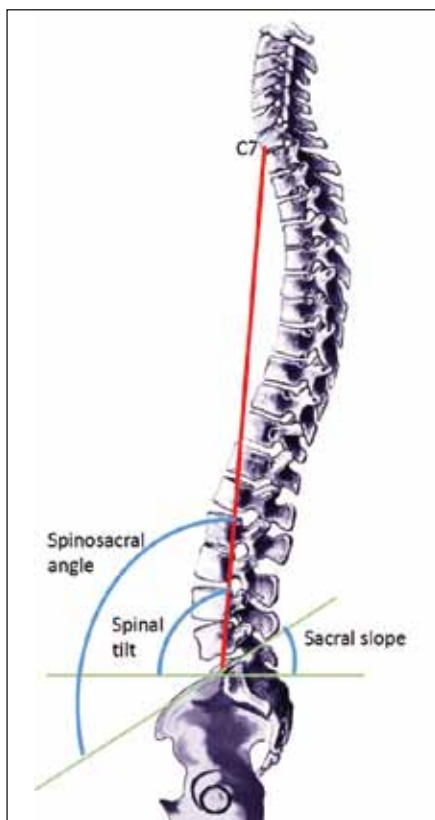
**Figure 4:** Diagram of Roussouly's categorization of spine shapes, the pelvic incidence (PI), lumbar lordosis (LL), and sacral slope (SS) angles are depicted.



**Figure 5: A)** The PI is large; the plumb line is behind the gravity line and within the gravity area. The spine compensation mechanism is balanced. **B)** The PI is small; therefore, the plumb line cannot be retained in the gravity area, the compensation mechanism becomes insufficient, and the sagittal balance is distorted. Fix sagittal balance is developed.



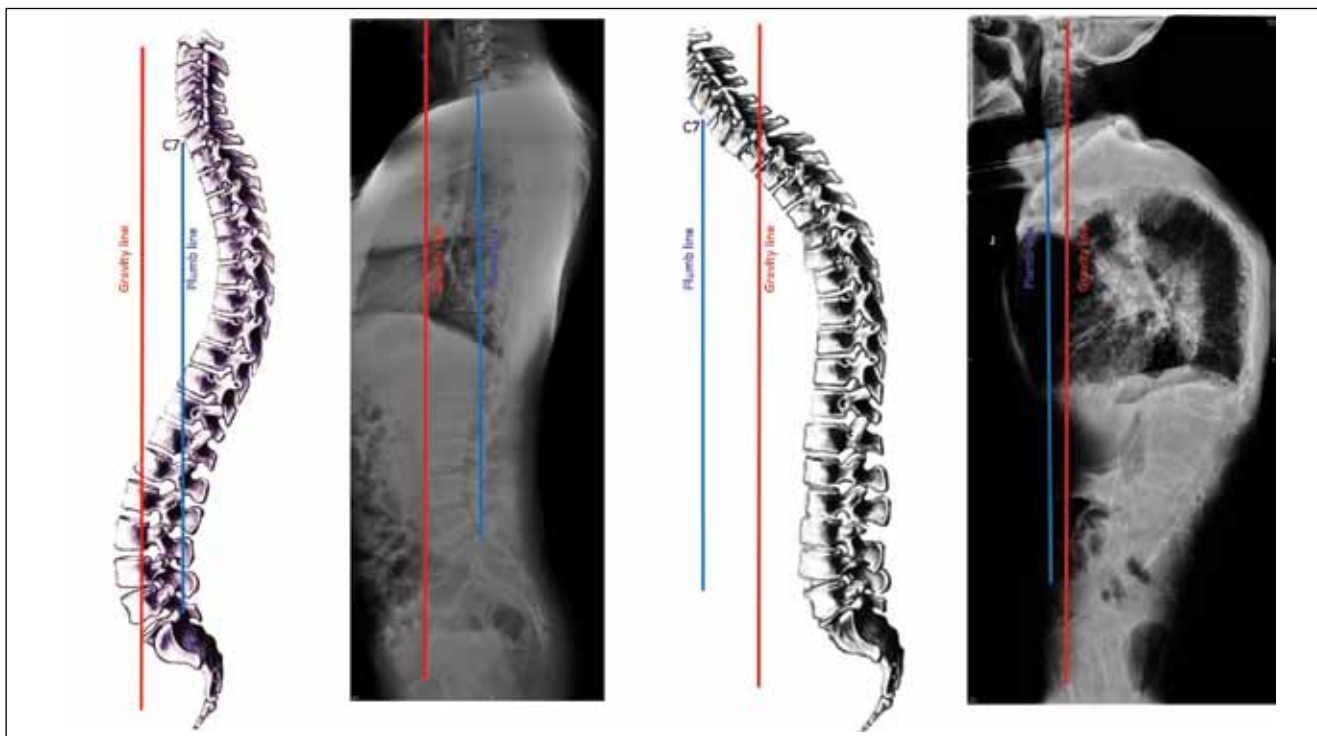
**Figure 6:** If the C7 is at the correct position, cervical lordosis is followed by the thoracic kyphosis and lumbar lordosis, and the latter two are followed by normal pelvic parameters.



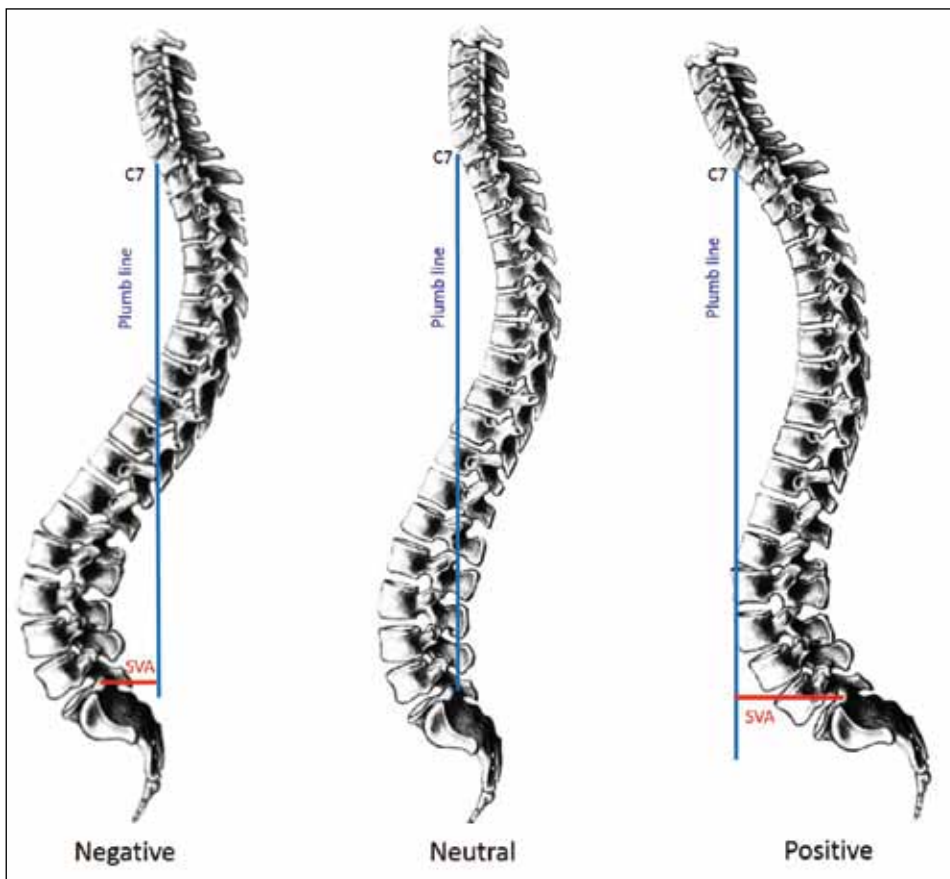
**Figure 7:** One of the parameters that describes the relation of the pelvis to the spine is the spinosacral angle (SSA), which is the angle formed between the line drawn from the front side of T1 to the middle of sacrum and the line passing through the sacral plateau.

Global evaluation of the thoracic and lumbar spine is provided by the spinosacral angle. This angle is related to the whole spine and is closely linked with the sacral slope. When the spine bends forward with the increasing age, the pelvis tilts backwards to compensate; as the spinosacral angle decreases, even the sacral slope (SS) angle decreases, but the pelvic tilt increases. The body adapts to maintain the pelvic parameters within the normal limits. The knee joints flex to provide compensation and keep the spine straight. However, due to the straight back formation stemming from the degeneration in the lumbar region, the thoracic region begins to bend forward; consequently, C7 moves forward and because the compensation mechanisms are no longer sufficient, the plumb line moves in front side of the gravity line and leads to sagittal imbalance (Figure 8). The patient can stand up and walk without any support; however, the patient's head and body bend forward (Figure 8).

SVA (sagittal vertical axis) is the simplest way to assess the "global spinal sagittal balance" on a standing lateral full-length X-ray image (Figure 9). The C7 plumb line normally passes from posterosuperior corner of S1 (neutral balance). The distance between C7 plumb line and this corner is used to determine the global spinal balance. If C7 plumb line falls posterior of this corner, this is a negative imbalanced spine and seen in hyperlordotic patients. However, if plumb line



**Figure 8:** The backward tilt of the pelvis is a compensation mechanism. The PI angle and the PT increase, whereas the SS decreases. Lumbar lordosis of the back increases, and the thoracic kyphosis decreases. The main objective is to retain the sagittal balance within the gravity area of the body.



**Figure 9:** Schematic description of sagittal vertical axis (SVA). The neutral balance, positive and negative imbalance of the spine.

falls anterior of this corner, this is a positive imbalanced spine and means hypolordotic spine (flat back) or kyphosis.

In summary, the C7 parameters are important for spinal balance, the gravity line affects all balance, the sacral slope angle influences lumbar lordosis, and the spinosacral (SS) angle is important for the holistic evaluation of sagittal balance.

#### REFERENCES

1. Jackson RP, Peterson MD, McManus AÇ, Hales C: Compensatory spinopelvic balance over the hip axis and better reliability in measuring lordosis to the pelvic radius on standing lateral radiographs of adult volunteers and patients. *Spine* 23(16):1750-1767, 1998
2. Legaye J, Duval-Beaupere G, Hecquet J, Marty C: Pelvic incidence: A fundamental pelvic parameter for three-dimensional regulation of spinal sagittal curves. *Eur Spine J* 7(2):99-103, 1998
3. Roussouly P, Gollogly S, Berthonnaud E, Labelle H, Weidenbaum M: Sagittal alignment of the spine and pelvis in the presence of L5-S1 isthmic lysis and low-grade spondylolisthesis. *Spine* 31(21):2484-2490, 2006
4. Schwab F, Lafage V, Shaffrey C, et al: Pre-operative pelvic parameters must be considered to achieve adequate sagittal balance after lumbar osteotomy. *IMAST 2009*. Vienna, Austria, 2009
5. Schwab F, Lafage V, Boyce R, Skalli W, Farcy JP: Gravity line analysis in adult volunteers: Age-related correlation with spinal parameters, pelvic parameters and foot position. *Spine* 31(25):959-967, 2006