



# Subdural Hematoma Associated with Skull and Dural Metastasis of Gastric Carcinoma: A Case Report

## *Gastrik Karsinomun Kafatası ve Dural Metastazıyla İlişkili Subdural Hematom: Bir Olgu Sunumu*

Tseng KUAN-YIN, Hueng DUENG-YUAN, Ma HSIN-I

*Tri-Service General Hospital, Department of Neurological Surgery, Taipei City, Taiwan, Province of China*

Corresponding Author: Ma HSIN-I / E-mail: neuronsugery@hotmail.com

### ABSTRACT

Skull bone metastasis from the gastric cancer is a rare. We reported a 52-year-old male proven to have stomach cancer and who underwent subtotal gastrectomy 5 months previously. Within the past 2 weeks, he experienced headache and dizziness followed by weakness of the left lower limb. A diagnosis of right chronic subdural hematoma (SDH) was made, and a burr hole was performed for drainage of the hematoma. However, 5 days later, the patient had sudden loss of consciousness without external evidence of trauma to the head. An emergency computed tomography (CT) scan revealed a high-density lesion consistent with an acute SDH on the right side. Histologically, metastasis of gastric adenocarcinoma was detected in both the dura mater and skull. It is suggested that the SDH was caused by the rupture of vessels in the metastasis or rupture of the inner dural vessels, possibly resulting from congestion of the outer vessels.

**KEYWORDS:** Gastric carcinoma, Calvarial metastasis, Dural metastasis, Subdural hematomas

### ÖZ

Gastrik kanserden kafatası metastazları nadirdir. Gastrik kanseri olduğu gösterilmiş ve 5 ay önce subtotal gastrektomi yapılmış 52 yaşında bir erkeği sunuyoruz. Son iki hafta içinde baş ağrısı ve baş dönmesi ve sonrasında sol alt uzuv zayıflığı yaşamıştır. Sağ kronik subdural hematom (SDH) tanısı konmuş ve hematom drenajı için bir burr deliği açılmıştır. Ancak 5 gün sonra hastada kafa travması için harici bir bulgu olmadan ani bir bilinç kaybı olmuştur. Acil bilgisayarlı tomografi (BT) taraması sağ tarafta akut subdural hematomla tutarlı yüksek dansiteli bir lezyon göstermiştir. Histolojik olarak hem dura mater hem kafatasında gastrik adenokarsinom metastazı bulunmuştur. Subdural hematomun nedeninin muhtemelen dış damarlarda konjesyon nedeniyle iç dural damarların rüptürü veya metastazdaki damarların rüptürü olduğu düşünülmektedir.

**ANAHTAR SÖZCÜKLER:** Gastrik karsinom, Kalvariyal metastaz, Dural metastaz, Subdural hematomlar

### INTRODUCTION

Metastases to the dura mater constitute one of the least frequent and least studied patterns of neoplastic spread to the craniospinal axis (5). Rarer still is the occurrence of subdural hematomas (SDHs) associated with the dural metastasis of a malignant tumor (8). Here, we report a case of a subdural hematoma caused by tumor located on the skull bone and dura mater. Furthermore, we review here the proposed mechanisms of induction of subdural hematoma with calvarial and dural metastatic neoplasm in the light of analysis of our own patient.

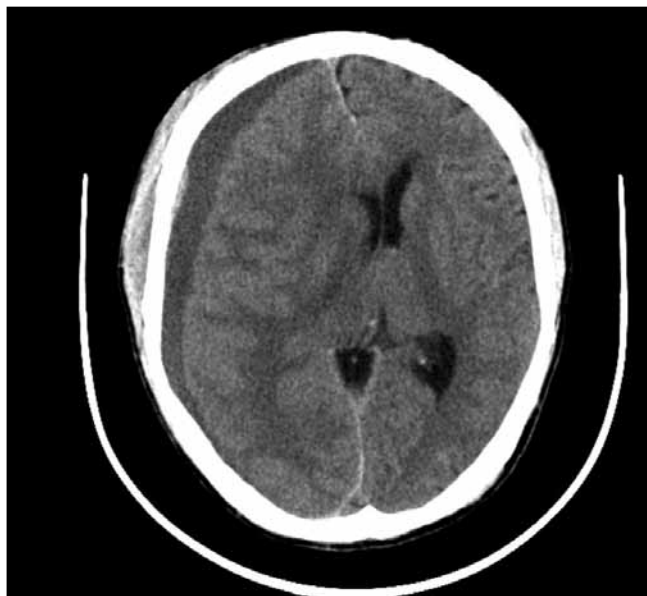### CASE REPORT

A 52-year-old male has a history of adenocarcinoma of the stomach and underwent subtotal gastrectomy, Roux-en-Y gastrojejunostomy anastomosis, cholecystectomy, and D2 lymph node dissection. The resected specimen showed type IV advanced cancer at the pylorus. It was histopathologically classified as adenocarcinoma with signet-

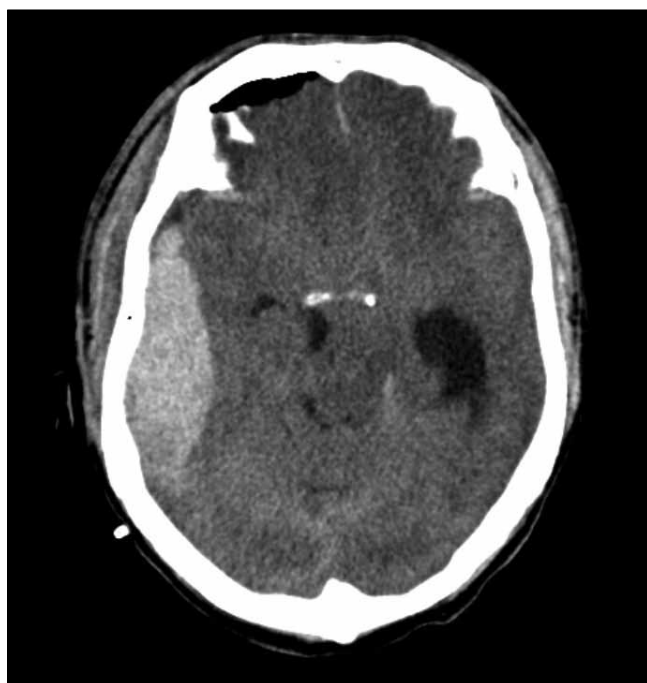ring cell differentiation, which invaded to deep muscle and the serosal layer. Lymphovascular space invasion was noted. Postoperative adjuvant chemotherapy was administered using oral tegafur/gimeracil/oteracil, and follow-up computed tomography (CT) of the abdomen revealed no recurrence.

During November 2009, he began suffering from occasional headache and dizziness. Later he had weakness of the left lower limb. The brain CT revealed a chronic subdural hematoma along the right cerebral convexity which caused mass effect with left-sided cerebral midline shift and mild uncal herniation (Figure 1). He was hemiplegic on the left side and had hyperesthesia along the left trunk. Prothrombin time and partial thromboplastin time were normal. He was diagnosed with right chronic SDH, and a burr hole was performed for evacuation of the hematoma. During the operation, the chronic SDH was drained and irrigated with warm normal saline until the effluent was clear. Biopsies of dural mater and skull bone were carried out. After the operation, weakness of left limbs improved gradually and

the JP drain was removed smoothly. However, 5 days later, the patient had a sudden change in consciousness. On examination, the Glasgow coma scale (GCS) score was 5. Both pupils were dilated (right, 7 mm; left, 5 mm) and nonreactive to light. There was no external evidence of trauma to the head. Emergent brain CT scans revealed an acute SDH along the right cerebral convexity which caused uncal herniation

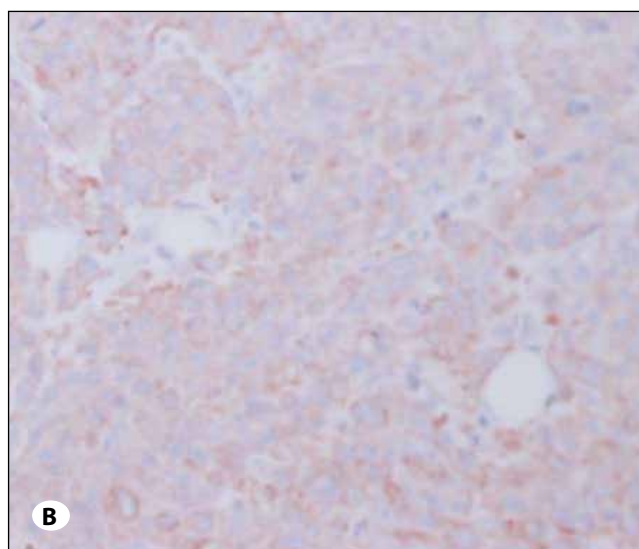
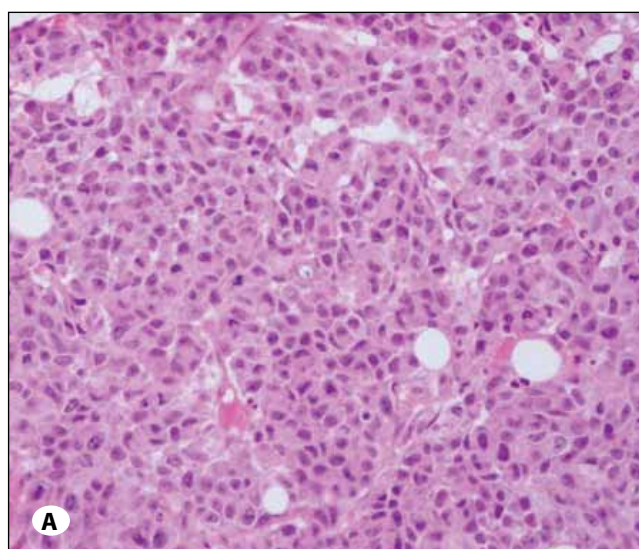


**Figure 1:** Computed tomographic scan of head reveals a right chronic subdural hematoma with midline shift to the left side.



**Figure 2:** Computed tomographic examination of head shows high-density lesions on the right side consistent with an acute subdural hemorrhage: there is considerable midline displacement and uncal herniation.

with upper brainstem compression (Figure 2). Subsequently, a large acute SDH was evacuated through a right frontoparietal craniectomy. The skull bone and underlying dura mater were excised for histological examination. After the operation, slow neurological recovery was noted; however, left hemiplegia persisted. Three days later, severe gastrointestinal hemorrhage flared up. Upper gastrointestinal endoscopy was performed and it revealed two huge ulcerative masses with multiple bleeding sites. Microscopically, the sections showed a picture of some solid tumor cell nests with focally glandular differentiation infiltrated in bony and dural fragments (Figure 3 A,B). Histologically, metastasis of adenocarcinoma was detected in the dura mater and skull, which was quite similar to the gastric endoscopic biopsy specimens. The



**Figure 3:** The results of skull bone biopsy shows some solid tumor cell nests (shown by an arrow head) with focal glandular differentiation infiltrated in bony fragments (A), while immunohistochemical staining was cytokeratin (CK)-positive for adenocarcinoma (shown by an arrow head) (B) ( $\times 400$  original magnification).

diagnosis of recurrent gastric carcinoma with metastasis of adenocarcinoma of the dura mater and skull was made, and conservative treatment was provided. His general condition progressively deteriorated and he died 14 days after the operation from the complication of acute disseminated intravascular coagulopathy (DIC).

### DISCUSSION

Metastatic bone disease can originate from almost any malignancy, but the most common primary foci are breast and prostate cancer (3). Skull metastasis demonstrates the same characteristic. In the past literatures, skull metastasis from stomach cancer demonstrates one of the least frequent incidences (15). The mechanism of the peculiar metastasis in these cases is difficult to elucidate. Multiple metastases were found at the terminals of branches of the external carotid artery, so the usual hematogenous circulation is the most likely (3, 9). Nevertheless, in our case, the skull metastasis was located at the right calvarias and directly invaded to the dura. This mode of tumor spread to the dura has been seen with lung, cervical, prostatic, and breast carcinomas (9). In breast carcinomas such bone-to-dura spread has been hypothesized by Tsukada et al to arise from dissemination of tumor cells from bony metastases with retrograde reflux of tumor cells into veins and venous plexus and subsequently into the dura. It often results in carcinomatous meningitis, multiple cranial nerve palsies and non-obstructive hydrocephalus (13). Worth of being noted, our case manifested as subdural hematomas. This association of bone metastatic disease with a SDH is a rare event, occurring with a frequency of only 0.4 to 5% in autopsy studies of metastatic neoplasms involving the intracranial compartment (8, 11). The most widely accepted explanation is the theory of Russel et al. which suggests that tumor emboli occlude the dural veins without bone-based metastases, thereby causing the dilation and breakdown of capillary vessels, resulting in chronic SDH (1, 4, 12). Furthermore, an angiodesmoplastic response to the dural metastasis would cause chronic subdural hematoma (7). However, prostate cancer with bone-based metastases and secondary dural involvement has been reported to be associated with SDH (2). We suspected that the calvarial metastatic deposit, in the course of time, may have eroded the inner table and dura mater. During the process of erosion of the dura, meningeal vessels may rupture into subdural space causing an acute SDH (14). The clinical progression in such instances may be rapid and dramatic (6). The neurological status may deteriorate into a syndrome of uncal herniation within minutes to hours (10). Therefore, in patients with such subdural hematoma, the anticipated life expectancy at the time of diagnosis is obviously shorter than those with metastasis of gastric cancer to the meninges and others. Treatments of subdural hematoma, especially surgical treatment, have been controversial, and it is considered that surgery should be indicated on an exact basis in patients with a tendency to bleed (1).

### CONCLUSION

Primary gastric cancer presenting with concomitant skull bone and dural metastasis resulting in subdural hemorrhage has

rarely reported before in the literature. It is highly malignant and its prognosis is very poor. We stress the importance of early postoperative CT scanning and avoidance of coagulopathy or thrombocytopenia triggered by the surgical therapy-associated consumption to minimize the occurrence of a large acute subdural hemorrhage.

### ACKNOWLEDGMENT

This study was supported by grants TSGH-C99-149, TSGH-C100-047, TSGH-C100-071, TSGH-C100-113, and TSGH-C100-122 from the Tri-Service General Hospital, Taipei, Taiwan, ROC.

### REFERENCES

1. Bergmann M, Puskas Z, Kuchelmeister K: Subdural hematoma due to dural metastasis: Case report and review of the literature. *Clin Neurol Neurosurg* 94:235–240, 1992
2. Cheng YK, Wang TC, Yang JT, Lee MH, Su CH: Dural metastasis from prostatic adenocarcinoma mimicking chronic subdural hematoma. *J Clin Neurosci* 16:1084–1086, 2009
3. Hirai O, Kikuchi H, Hashimoto N: Skull base metastasis from gastric cancer--case report. *Neurol Med Chir (Tokyo)* 32: 908–910, 1992
4. Katsube T, Kikuchi T, Konno S, Murayama M, Kobayashi R, Kuhara K, Yoshimatsu K, Shiozawa S, Shimakawa T, Naritaka Y, Ogawa K, Hagiwara S, Aiba M: Subdural hematoma associated with dural metastasis of gastric carcinoma: Report of two cases. *Anticancer Res* 27:4339–4344, 2007
5. Kleinschmidt-DeMasters BK: Dural metastases. A retrospective surgical and autopsy series. *Arch Pathol Lab Med* 125:880–887, 2001
6. Kurabayashi T, Isii K, Suzuki M, Takakuwa K, Shibazaki Y, Ozawa T, Narisawa R, Sekizuka N, Tanaka K: Advanced gastric cancer and a concomitant pregnancy associated with disseminated intravascular coagulation. *Am J Perinatol* 21:295–298, 2004
7. Leech RW, Welch FT, Ojemann GA: Subdural hematoma secondary to metastatic dural carcinomatosis. Case report. *J Neurosurg* 41:610–613, 1974
8. McKenzie CR, Rengachary SS, McGregor DH, Dixon AY, Suskind DL: Subdural hematoma associated with metastatic neoplasms. *Neurosurgery* 27:619–624; discussion 624–625, 1990
9. Mimori K, Fukagawa T, Kosaka Y, Kita Y, Ishikawa K, Etoh T, Inuma H, Sasako M, Mori M: Hematogenous metastasis in gastric cancer requires isolated tumor cells and expression of vascular endothelial growth factor receptor-1. *Clin Cancer Res* 14:2609–2616, 2008
10. Rogers LR: Cerebrovascular complications in cancer patients. *Neurol Clin* 21:167–192, 2003
11. Shamim MS, Bari ME, Enam SA: Dural metastases presenting as an extradural hematoma: A rare presentation. *J Pak Med Assoc* 55:509–510, 2005
12. Sugawara A, Miura S, Suda Y, Ohmi T, Tanaka T, Tateoka H: Chronic subdural hematoma secondary to metastasis of adenocarcinoma of the dura mater and skull--a case report. *Gan No Rinsho* 32:190–195, 1986

13. Tsukada Y, Fouad A, Pickren JW, Lane WW: Central nervous system metastasis from breast carcinoma. Autopsy study. *Cancer* 52:2349–2354, 1983
14. Turner DM, Graf CJ: Nontraumatic subdural hematoma secondary to dural metastasis: Case report and review of the literature. *Neurosurgery* 11:678–680, 1982
15. Wong AL, Chou N, Lee KM, Ang BW, Cheng CL, Lee SC: Subdural collections arising from calvarial metastases following discontinuation of anti-angiogenic therapy. *Ann Oncol* 20:1605–1606, 2009