



# Efficacy and Safety Assessment of LVIS Jr Device in Treating Wide-Neck Aneurysms: A Comprehensive Systematic Review and Single-Arm Meta-Analysis

Marcelo Porto SOUSA<sup>1</sup>, Guilherme Nunes MARQUES<sup>1</sup>, Livia Viviani de ABREU<sup>1</sup>, Filipi Fim ANDREÃO<sup>1</sup>, Leonardo de Barros OLIVEIRA<sup>2</sup>, Gabriel VERLY<sup>1</sup>, Sávio BATISTA<sup>1</sup>, Guilherme Melo SILVA<sup>1</sup>, Raphael Muszkat BESBORODCO<sup>3</sup>, Raphael BERTANI<sup>4</sup>

<sup>1</sup>Federal University of Rio de Janeiro, Faculty of Medicine, Rio de Janeiro - Rio de Janeiro, Brazil

<sup>2</sup>State University of Ponta Grossa, Faculty of Medicine, Ponta Grossa - Paraná, Brazil

<sup>3</sup>Rusk Rehabilitation, NYU Langone Health, New York - New York, United States

<sup>4</sup>University of São Paulo, Department of Neurosurgery, São Paulo - São Paulo, Brazil

**Corresponding author:** Marcelo Porto SOUSA ✉ mportosousa@gmail.com

## ABSTRACT

**AIM:** To evaluate the usage and the effectiveness of LVIS Jr device technology in managing wide-neck intracranial aneurysms.

**MATERIAL and METHODS:** PubMed, Embase, and Web of Science databases, comprising studies with outcomes related to LVIS Jr use in wide-neck intracranial aneurysms were searched systematically. Data was extracted from the selected articles and subjected to statistical analysis.

**RESULTS:** Among 886 initially identified articles, 20 studies met our inclusion criteria, comprising a total of 557 patients. Our analysis revealed a 96% final occlusion rate under common effects and 93% under random effects, with substantial heterogeneity ( $I^2 = 69\%$ ). Good clinical outcomes were observed in 99% of cases with low heterogeneity ( $I^2 = 27\%$ ). Mortality rates were extremely low, with only one reported death out of 499 patients across 18 studies, resulting in a 0% mortality rate for common and random effects and no heterogeneity ( $I^2 = 0$ ). Complications occurred in 44 of 482 patients, yielding a 6% rate in the common effect model and 6% in the random effects model, with nonsignificant heterogeneity ( $I^2 = 25\%$ ).

**CONCLUSION:** LVIS Jr observed a favorable rate of final occlusion and good clinical outcomes, and the low mortality and complication rates highlight its safety in the treatment of wide-neck aneurysms.

**KEYWORDS:** Wide-neck, Aneurysm, Stent, LVIS Jr

## INTRODUCTION

While endovascular techniques have gained significant attention in recent decades, the management of wide-neck aneurysms remains a formidable clinical challenge when juxtaposed with their narrow-neck counterparts (4,35). This can be attributed to the increased incidence of incomplete occlusion when employing endovascular

approaches, which in turn restricts the understanding of the long-term implications and outcomes (37).

Meanwhile, intracranial stents serve as neck-bridging tools, preventing coil prolapse into the parent artery during the treatment of wide-neck aneurysms (6,38). Challenging anatomic features such as larger neck sizes and bifurcation locations may need the use of multiple stents in diverse configurations

Marcelo Porto SOUSA : 0009-0006-4418-4894  
Guilherme Nunes MARQUES : 0009-0007-3575-9489  
Livia Viviani de ABREU : 0009-0004-5704-8571  
Filipi Fim ANDREÃO : 0000-0002-5961-4520  
Leonardo de Barros OLIVEIRA : 0009-0009-5612-556X

Gabriel VERLY : 0009-0008-1043-6402  
Sávio BATISTA : 0000-0002-6861-0505  
Guilherme Melo SILVA : 0000-0002-7700-5251  
Raphael Muszkat BESBORODCO : 0000-0003-4745-5021  
Raphael BERTANI : 0000-0001-6546-2634

for effective neck bridging (7,17). The most prevalent multi-stent approach, known as Y-stenting, was introduced by Chow et al. in 2004 for managing wide-neck bifurcation aneurysms. It involves deploying stents from the parent artery into each bifurcation artery, with the second stent passing through the first openings (11).

The Low-profile Visualized Intraluminal Support Junior device (LVIS Jr; MicroVention-Terumo, Tustin, California, USA) has emerged as a feasible option for treating wide-neck cerebral aneurysms (4,37,38). Braided stents like the LVIS Jr possess a flexible closed-cell design that adapts its cell size based on the applied force along its length. This characteristic of braided stents can be harnessed to form a protective “shelf” using a single stent at the wide neck of a bifurcation aneurysm, eliminating the need for Y-stenting (16). This is relevant due to the potential drawbacks of the Y-stenting technique, such as prolonged procedure durations, elevated radiation exposure, and a seemingly heightened periprocedural risk (31).

The authors undertook a systematic review and meta-analysis to assess the existing body of evidence regarding the safety and efficacy of LVIS Jr. in the management of wide-neck intracranial aneurysms.

## ■ MATERIAL and METHODS

### Eligibility Criteria

In this systematic review, all studies that documented the deployment of the LVIS Jr device for the treatment of wide-necked intracranial aneurysms were incorporated. To mitigate the potential for bias, studies with fewer than four patients, those lacking the outcomes of interest, as well as letters, comments, and reviews were excluded. If the study reported other types of aneurysms or devices, the outcomes of LVIS Jr and wide-necked aneurysms had to be available separately. An aneurysm with a wide neck is characterized by a neck diameter exceeding 4 mm or dome-to-neck ratios of less than 2.

### Search Strategy and Data Extraction

A systematic search across several databases, including PubMed, Embase, and Web of Science, was conducted. The following search strategy was employed. The data extraction was performed collaboratively by two authors (G.N.M and M.P.S), following pre-established search criteria.

### Endpoints

The data extraction process concentrated on a range of critical outcomes, including final occlusion, clinical results, total mortality, related mortality, and procedural complications. Final occlusion was categorized using the Raymond-Roy Occlusion Classification (RROC) system. Complications and related mortality were specifically scrutinized if they were directly linked to the procedure, ensuring a comprehensive assessment of the treatment’s safety and efficacy.

### Statistical Analysis

This systematic review and meta-analysis strictly adhered to

the guidelines set forth by the Cochrane Collaboration and followed the Preferred Reporting Items for Systematic Reviews and Meta-Analysis (PRISMA) statement recommendations (39). To evaluate heterogeneity, the Cochran Q test and  $I^2$  statistics were employed considering p-values less than 0.05 and  $I^2$  values above 35% as indicative of significant heterogeneity. Statistical analysis was carried out using R software (version 4.2.3, R Foundation for Statistical Computing, Vienna, Austria).

## ■ RESULTS

### Study Selection

A total of 886 articles were found by querying three databases: 201 in PubMed, 210 in Web of Science, and 475 in Embase. Of these, 234 had to be discarded after being detected as duplicates. Subsequently, 547 were excluded after title and abstract screening. One hundred five articles underwent full-text review, of which 20 studies were selected for the final analysis; more information is in Figure 1.

### Study and Patient Characteristics

Twenty studies were selected for analysis, involving a total of 557 patients. Eighteen of these studies (90%), had a retrospective design. The total sample included 549 aneurysms, reported on nineteen studies. 447 of these aneurysms were reported as ruptured or unruptured. 121 out of 447 (27%) were ruptured at presentation, while 326 out of 447 (72.9%) were reported as unruptured. The three most commonly mentioned aneurysm locations were the ACM (143), followed by the ACoMA (119), and the basilar artery (87), accounting for 349 out of 497 (70%) of the locations described. Three cases had undergone previous treatments, including coiling, stent-assisted coiling, and clipping. Sixteen studies reported mean ages of

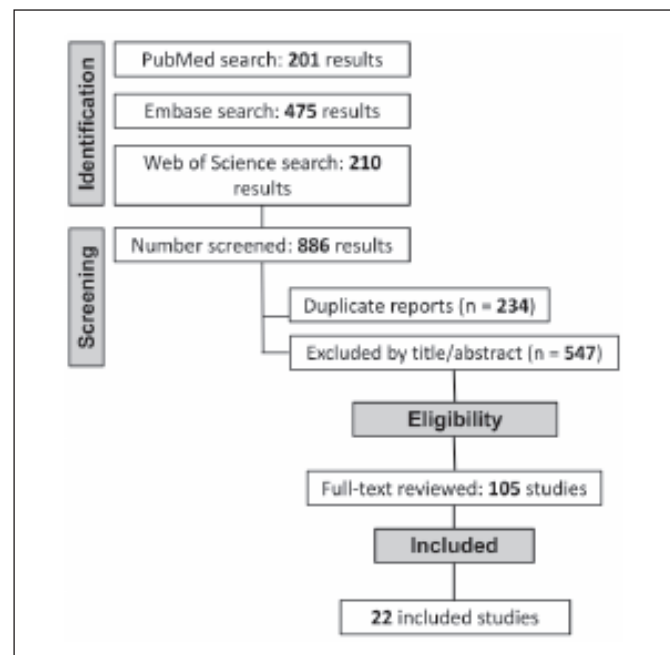


Figure 1: PRISMA diagram of study screening and selection.

patients, the median of these ages is 59.85 years. Additional information on the fundamental characteristics of patients can be found in Table I.

There was mention of the need for adjacent treatment alongside LVIS Jr - in all sixteen studies - with coil embolization being the most commonly utilized method. The median follow-up duration across these 13 studies was 12 months, underlining a notable consistency in the length of follow-up observed throughout the study sample. This implies a substantial and recurring timeframe for monitoring. The majority of these studies also administered aspirin and clopidogrel as pre-procedural medications. For additional information, such as the number and size of LVIS Jr devices, MRS scores, and further details regarding follow-up, early medications, and adjacent treatments, please refer to Table II.

**Outcomes**

The final occlusion analysis considered the Raymond-Roy Occlusion Classification (RROC) in its classes I (complete obliteration) and II (residual neck). In this context, 395 of 443 aneurysms were classified in these categories after the procedure. It represented a rate of 96% (95% CI 0.94-0.98) in common effects and 93% (95% CI 0.88-0.97) in random effects models. Heterogeneity was considered substantial ( $I^2 = 69\%$ ,  $\tau^2 = 0.0050$ ,  $p < 0.01$ ), Figure 2.

In this study, good clinical outcomes were assessed using the modified Rankin scale (mRS), considering a favorable outcome as a mRS  $\leq 2$ . It was present in 304 of 317 patients, with a 99% (95% CI 0.97-1.00) rate in both common and random effects models. Furthermore, the heterogeneity level was considered low ( $I^2 = 27\%$ ,  $\tau^2 < 0.0001$ ,  $p = 0.17$ ), Figure 3.

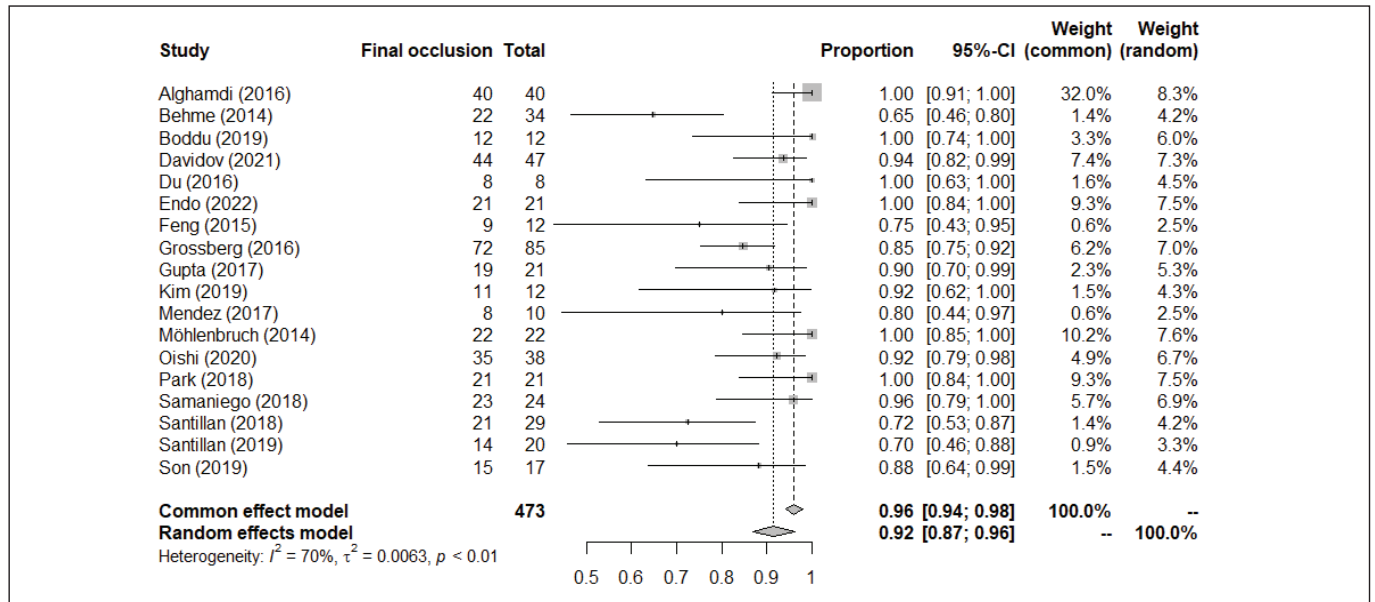


Figure 2: Final occlusion.

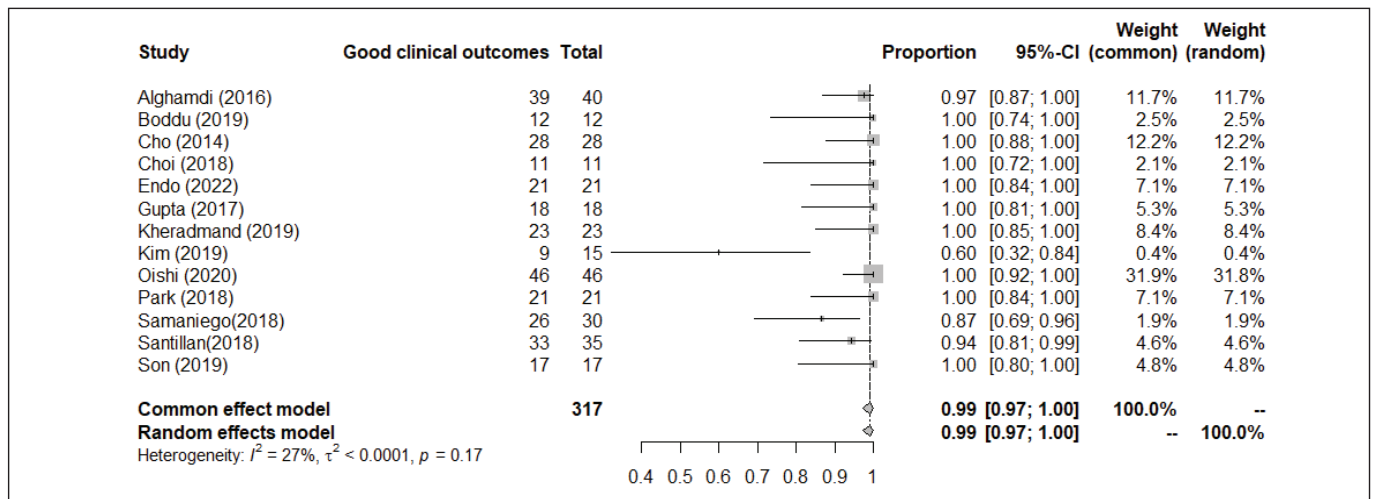


Figure 3: Good clinical outcomes.

Table I: Patients Baseline Characteristics

Author	Type of Study	Patients (n)	Mean age (yrs)	Aneurysm (n)	Ru : UnR	Aneurysm Location	Mean aneurysm Size (mm)	Previous Treatment
Alghamdi et al. (2016), (1)	R	40	55	43	22:18	MCA bifurcation (8), AComA (17), pericallosal (1), basilar Artery (10), superior cerebellar artery (6), PICA (1)	Diameter = 5.6; neck size = 3.8	N/A
Behme et al. (2014), (4)	R	32	54	34	12:22	Anterior circulation (26) posterior circulation (8)	Size = 7; Median neck size = 4	N/A
Boddu et al. (2019), (5)	R	12	60 ± 11	12	2:10	AComA (4), PICA anastomosis (1), M1 bifurcation (3), basilar termination (2), M2 bifurcation (1), ICA terminus (1)	Diameter = 8 ± 3.4; Dome/Neck ratio = 1.6 ± 0.4	N/A
Cho et al. (2014), (9)	P	28	N/A	28	0:28	N/A	N/A	N/A
Choi et al. (2018), (10)	R	11	N/A	12	N/A	AComA	N/A	N/A
Davidov et al. (2021), (15)	R	47	N/A	47	N/A	N/A	N/A	N/A
Du and Shankar (2016), (17)	R	8	N/A	8	2:6	Left ICA tip (1), basilar tip (3), AComA (3), right paraophthalmic (1)	Diameter= 7.7; neck= 5.5	N/A
Endo et al. (2022), (18)	R	21	63.9	22	0:22	MCA (8), AComA (7), Tip of the basilar artery (7)	Size = 6.0; neck length = 4.1	Coiling (4)
Feng et al. (2015), (20)	R	18	54.3	18	5:13	M1 (5), M2 (4), MCA bifurcation (9)	Diameter = 4.8	N/A
Grossberg et al. (2016), (21)	R	85	60.5±12.7	85	17:68	AComA (31), MCA bifurcation (19), basilar artery terminus (13), ICA terminus (5), PICA (4), distal ACA (4), PCA (2), anterior choroidal artery (1), AICA (1), distal MCA (1), ophthalmic artery (1), PComA (1), superior cerebellar artery (1), vertebral artery (1)	Diameter = 6.1	N/A
Gupta et al. (2017), (22)	R	18	55	21	8:13	ICA (3), ACA (2), MCA (4), AComA (3), PComA (2), PCA (1), basilar tip (4), PICA (2)	Diameter range = 2-25; Median size = 5.8	Coiling or clipping (4)
Kheradmand et al. (2019), (27)	R	23	60 ± 8.2	N/A	13:0	AComA (12), basilar tip (7) MCA (4)	N/A	N/A
Kim et al. (2019), (28)	R	15	58.1	15	15:0	Basilar artery bifurcation (3), AComA (6), left PComA (2), right PComA (1), right MCA (2), Left A1 (1)	Size = 9.2	N/A
Möhlenbruch et al. (2014), (37)	R	22	55	22	N/A	MCA (5), AComA (9), SCA (1), BA (5), ICA T (1), PComA(1)	N/A	N/A
Oishi et al. (2020), (38)	R	46	61.5	47	0:47	MCA (47)	Size = 4.5;; neck width = 3.0	N/A

Table I: Cont.

Author	Type of Study	Patients (n)	Mean age (yrs)	Aneurysm (n)	Ru: UnR	Aneurysm Location	Mean aneurysm Size (mm)	Previous Treatment
Park et al. (2018), (40)	R	21	60	21	0:21	Basilar (9), AComA (6), MCA (4), ICA (1), vertebrabasililar fenestration aneurysm (1)	Size = 7.9; neck size = 5.7	N/A
Samaniego et al. (2018), (44)	R	30	63	30	6:24	Basilar Tip (15), MCA (8), AComA (4), pericallosal (1), PICA (2)	Size = 11; neck ratio = 1.3	Coiling (1)
Santillan et al. (2018), (45)	R	35	59.7	35	10:25	AComA (14) Proximal ACA (4) distal ACA (2), MCA (11), basilar Tip (2)	Size = 2.2	N/A
Son et al. (2019), (47)	R	17	63.4	18	9:9	AComA (11), basilar (7)	Width = 4.39; length = 4.37	N/A
Takano et al. (2017), (48)	R	28	60.8	31	N/A	AComA (15), ICA(3), MCA (13).	N/A	N/A

**N/A:** Non Available, **R:** Retrospective, **P:** Prospective, **IAs:** Ischemic attack, **EVT:** Endovascular treatment, **SAH:** Subarachnoid hemorrhage, **TIA:** Transient ischemic attack, **WFNS:** World Federation of Neurosurgical Societies Grading Scale, **PICA:** Posterior Inferior Cerebellar Artery, **HH:** Hunt-Hess Scale, **MCA:** Middle cerebral artery, **AComA:** Anterior communicating artery, **ICA:** Internal carotid artery, **M1:** Sphenoidal or horizontal segment of MCA, **M2:** Insular segment of MCA, **ACA:** Anterior cerebral artery, **PCA:** Posterior cerebral artery, **AICA:** Anterior inferior cerebellar artery, **PCoMA:** Posterior communicating artery, **SCA:** Superior cerebellar artery, **BA:** Basilar artery, **Ru:** Ruptured, **UnR:** Unruptured, **mRS:** Modified Rankin-Scale, **A1:** Horizontal or pre-communicating segment.

One death was reported in 499 total patients and was related to the procedure. These findings were reiterated by the statistical analysis, with a rate of 0% (95% CI 0.00-0.01) common and random effects models and no heterogeneity ( $I^2 = 0$ ,  $\tau^2 = 0$ ,  $p=1.00$ ) in both situations, Figure 4 and Figure 5.

Complications occurred in 44 from a sample of 482 patients. Also, the statistical analysis showed a rate of 6% in the common effects model (95% CI 0.04-0.08) and 6% in the random effects model (95% CI 0.04-0.09), with low heterogeneity ( $I^2 = 25\%$ ,  $\tau^2 = 0.0004$ ,  $p=0.16$ ), Figure 6. More detailed information about complications can be found in Table III.

## DISCUSSION

This systematic review and meta-analysis was designed to comprehensively evaluate the safety, efficacy, and outcomes associated with using LVIS Jr to treat wide-neck aneurysms. By systematically reviewing a diverse range of studies, the objective of this study was to gain a thorough understanding of the clinical utility of LVIS Jr in diverse patient populations and under varying clinical scenarios. Furthermore, the review encompassed both anterior and posterior circulation aneurysms and aimed to not only assess the device's technical success rate but also to identify potential complications, long-term benefits, and any nuances in patient outcomes.

The standout characteristic of the LVIS Jr device is its ability to be introduced via a 0.017-inch luminal microcatheter, which is also suitable for coil deployment, enabling easier navigation through smaller and more winding vessels compared to previous stent technologies (22). The device is crafted from nitinol wire measuring 0.056 mm and boasts enhanced radiopaque markers when contrasted with the Enterprise and Neuroform stents. Additionally, it offers the advantage of being retrievable even after 80% deployment (5). While the standard LVIS stent is usually suggested for vessel diameters ranging from 3 to 4.5 mm, the LVIS Jr. is better suited for vessel diameters between 2 and 3.5 mm and offers surface area coverage between 12% and 21% (4,9).

Recent findings have further underscored that the presence of a stent plays a pivotal role in minimizing angiographic recurrence (29). Moreover, stent-assisted coiling correlates with a greater likelihood of complete occlusion, even in more complicated cases (13,36,42). It is important to emphasize that coiling procedures can be aided by either a stent or a balloon. In their study, Wallace et al. found that there is no significant difference between the two techniques in achieving immediate occlusion (50). However, during follow-up assessments, particularly in achieving final occlusion, the utilization of a stent for assisted coiling showed noteworthy advantages. In assessing the final occlusion rate, we employed the Raymond-Roy scale. Our analysis revealed an occlusion rate of 93% (95% CI 0.88-0.97). Our findings align with the reviewed literature, wherein the immediate outcomes for LVIS Jr span from 47% to 91%. Subsequent follow-up results range between 78% and 100% (2,4,24,40). It is important to point out that, for prior generation stents, like Neuroform and Enterprise, immediate complete occlusion rates are seen between



31% and 88%. On follow-up, these rates stand between 49% and 74% (8,25,29,34). Furthermore, studies have indicated that the immediate angiographic occlusion rates (classified as Raymond-ROy Occlusion Classification I or II) when using Y-stent-assisted coiling vary between 71% and 92% (19,32,40,51).

In the context of wide-necked bifurcation aneurysms spanning both anterior and posterior circulations, the utilization of dual-layered stent-assisted coil embolization (DSCE) with LVIS Jr. stents proves to be practicable, secure, and efficacious, resulting in good clinical outcomes (5). Additionally, other techniques, such as barrel or Fred combined with LVIS also have the potential to achieve satisfactory results (14,23). In this

study, the clinical outcome was measured using the modified Rankin scale (mRS), with a favorable outcome delineated as mRS ≤ 2. Based on our comprehensive evaluation, our analysis revealed a high rate of favorable clinical outcomes, with a rate of 99% (95% CI 0.97-1.00) of patients achieving a good outcome. This data highlights the potential benefits and efficacy of the treatment approach studied. It is important to point out that nine out of fifteen studies in the analysis of good clinical outcomes showed a full patient with good clinical outcomes, meaning all patients in these studies with mRS ≤ 2.

Thromboembolic events leading to iatrogenic brain ischemia stand as the predominant factors influencing the morbidity and mortality rates associated with endovascular procedures (39).

**Table II:** Treatment and Follow-up. The table below depicts the early drug and type of endovascular technique elected, functionality after procedure and follow-up characteristics.

Study	LVIS Jr (N)	Early drug	Adjacent Treatment	Final mRS/GOS	Follow-up (months)
Alghamdi et al. (2016), (1)	43	Asa + clop	Coiling	MRS= 0 (38); MRS 1 (1); MRS 5 (1)	(27)12; (11) 6
Behme et al. (2014), (4)	32	Asa + clop	Coiling	N/A	4.4
Boddu et al. (2019), (5)	12	Asa + plavix	Coiling	MRS= 0 (4); MRS 1 (8)	12 ± 6
Cho et al. (2014), (9)	28	Asa + clop	N/A	MRS= 0 (27); 1(1)	6
Choi et al. (2018), (10)	12	Asa + clop	N/A	MRS= 1(1); MRS 0 (10)	Median: 25.9
Davidov et al. (2021), (15)	47	N/A	Coiling	N/A	10.1
Du and Shankar (2016), (17)	8	Asa + clop	None	N/A	Range: 3–15
Endo et al. (2022), (18)	22	Asa + clop	Coiling	MRS= 0 (21); 1 (1)	43.5
Feng et al. (2015), (20)	18	Heparin + asa + clop	Coiling	N/A	6.3
Grossberg et al. (2016), (21)	85	Dual antiplatelet therapy + heparinization	Coiling	N/A	6
Gupta et al. (2017), (22)	21	Heparin +asa + clop	Coiling	MRS ≤ 2 (18)	Median: 8
Kheradmand et al. (2019), (27)	23	N/A	Coiling	MRS= 0 (20); 1 (3)	12
Kim et al. (2019), (28)	15	Asa + clop	Coiling	GOS= 2(2); 4(3); 5 (9)	341 days
Möhlenbruch et al. (2014), (37)	22	Asa + clop	N/A	N/A	6
Oishi et al. (2020), (38)	47	Heparin + asa + clop	Coiling	MRS 0 (45); 1 (1)	27.4
Park et al. (2018), (40)	21	Asa + clop	Coiling	MRS= 0 (20); 2 (1)	12
Samaniego et al. (2018), (44)	30	Asa + clop/ticagrelor	Coiling	MRS= 0 (22); 1 (2), 2 (2), 4 (1), 6 (3)	5.2
Santillan et al. (2018), (45)	35	Asa + clop/ticagrelor	Coiling	MRS= 0 (25); 1 (7); 2 (1); 3 (1)	9.4
Son et al. (2019), (47)	18	Asa + clop	Coiling	MRS= 0 (13); 1 (3); 2 (1)	N/A
Takano et al. (2017), (48)	31	N/A	N/A	N/A	N/A

**N/A:** Non Available, **LVIS:** , **AComA:** Anterior communicating artery, **mRS:** Modified rankin-scale, **GOS:** Glasgow Outcome Scale, **FU:** Follow-up, **ASA:** Acetylsalicylic acid, **Clop:** Clopidogrel.

**Table III:** Descriptive Analysis of Complications. This Table Displays a Thorough Description of the Reported Complications in Each Study, Such as Stent Thrombosis, Ischemia, Rupture, Thromboembolism, and Delayed Complications

Study	Events	Complications
Alghamdi et al. (2016), (1)	3	Stent thrombosis (1); ruptures (2)
Behme et al. (2014), (4)	5	In-stent thrombosis (2)
Boddu et al. (2019), (5)	3	Transient in-stent thrombus (2); iatrogenic rupture (1)
Cho et al. (2014), (9)	1	Infarction (1)
Choi et al. (2018), (10)	2	Thromboembolism (2)
Du and Shandar (2016), (17)	2	N/A
Endo et al. (2022), (18)	1	Delayed (1)
Feng et al. (2015), (20)	1	Acute in-stent thrombosis (1)
Grossberg et al. (2016), (21)	8	Intraprocedural rupture (1); aneurysm rebleed (1); intraprocedural rupture (2), iatrogenic vertebral artery dissection (2); GP2b3a inhibitor (1); coil herniation requiring placement of 2nd stent (1)
Gupta et al. (2017), (22)	0	0
Kheradmand et al. (2019), (27)	1	Stents were closed by thrombosis
Kim et al. (2019), (28)	0	0
Möhlenbruch et al. (2014), (37)	2	Transient ischemic (2)
Oishi et al. (2020), (38)	2	Acute in-stent thrombosis (1); subacute in-stent thrombosis (1)
Park et al. (2018), (40)	2	Perforator infarction (1); rupture (1)
Samaniego et al. (2018), (44)	6	Small temporal stroke (1); posterior cerebral artery infarct (2); retroperitoneal hematomas (2); intravascular coagulopathy (1);

N/A: Non Available

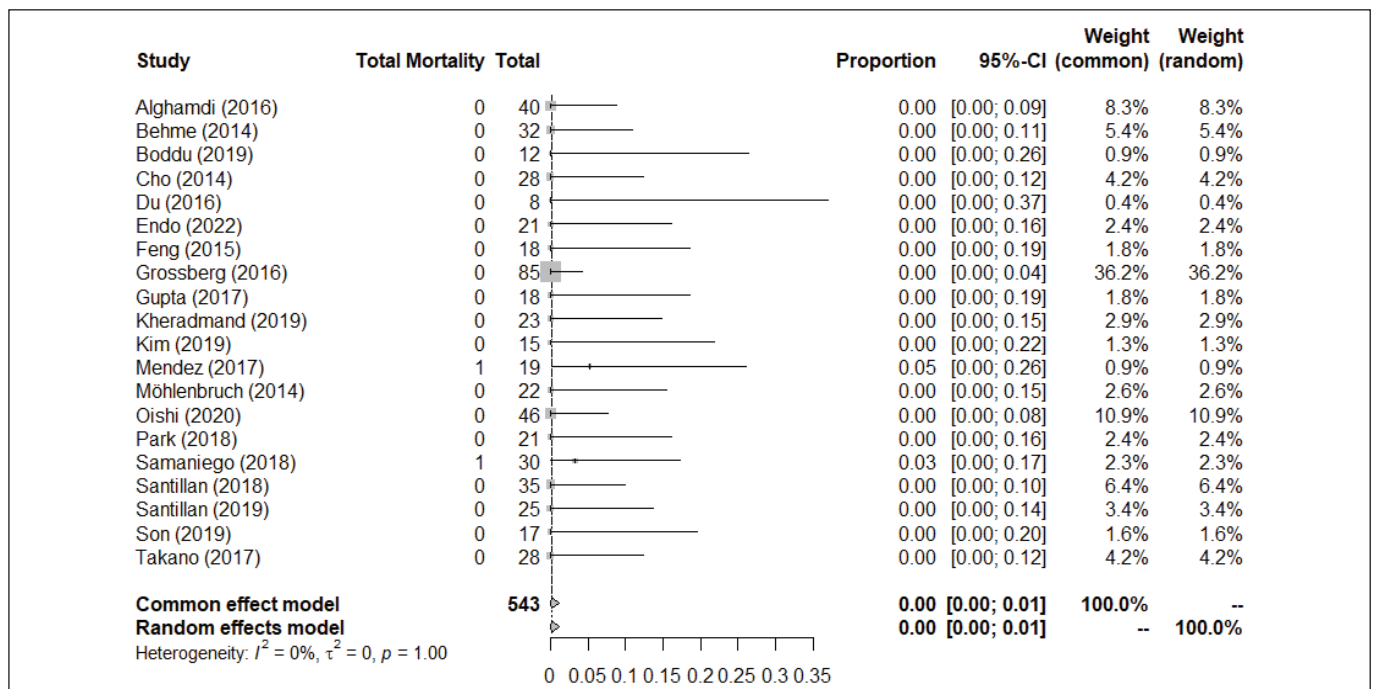


Figure 4: Total mortality.

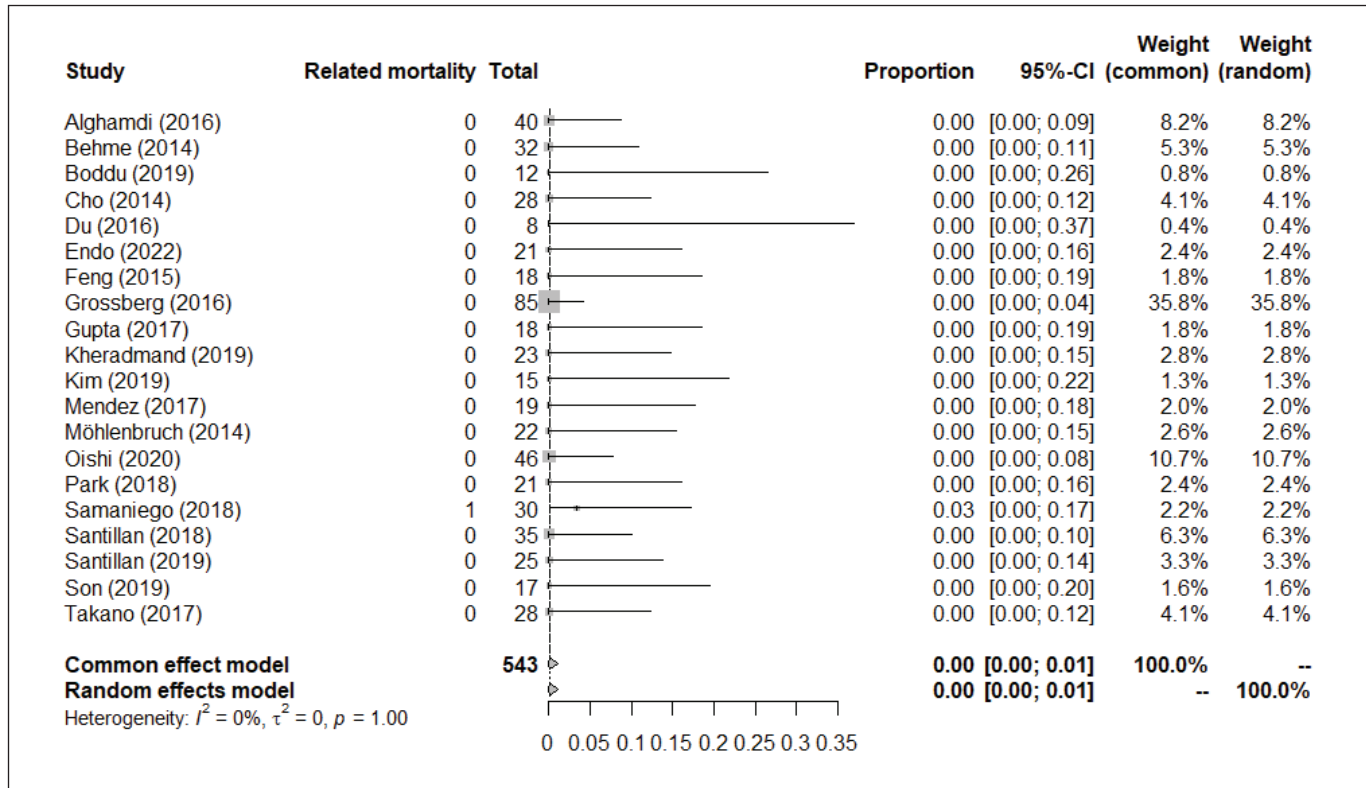


Figure 5: Procedure-related mortality.

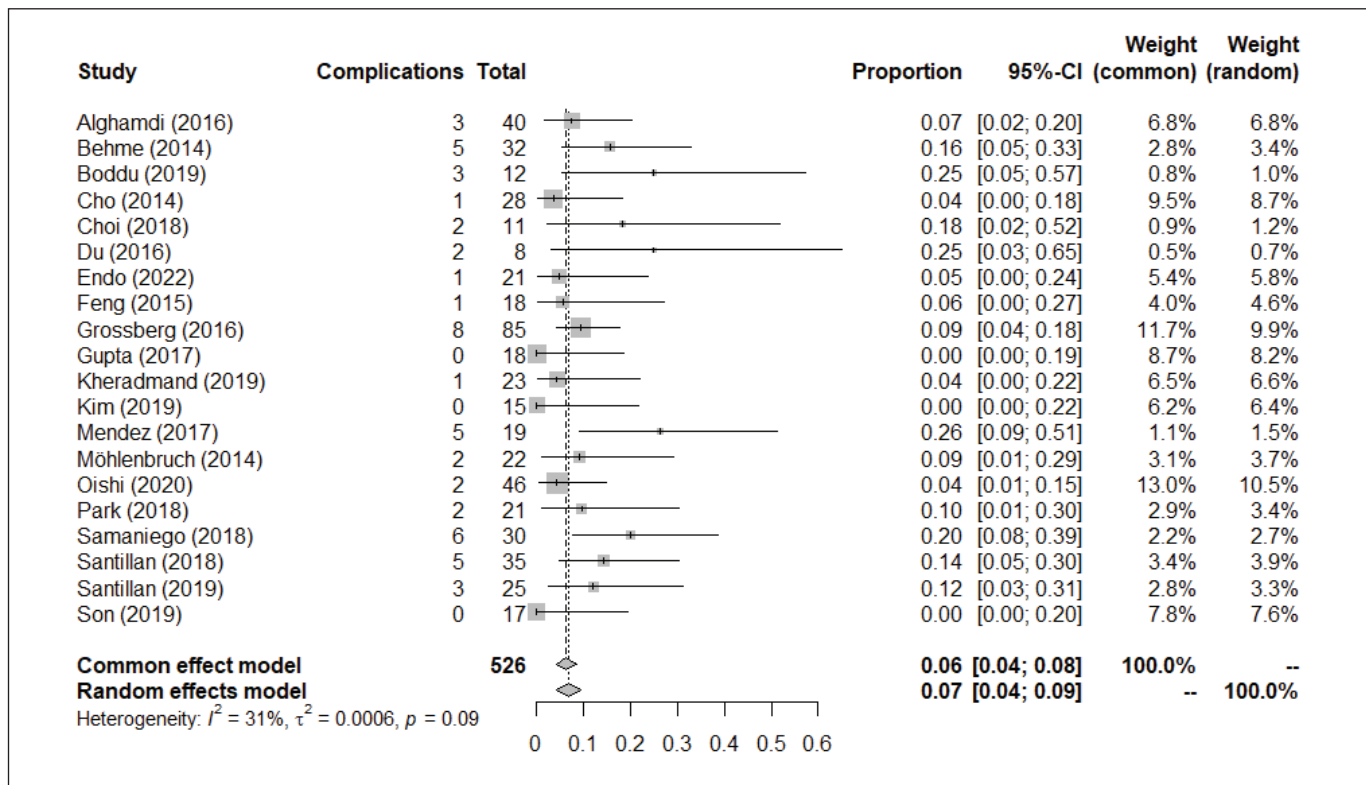


Figure 6: Total occurrence of complications.



In terms of mortality, our findings are particularly encouraging. We observed a mortality rate of 0% (95% CI of 0.00-0.01), underscoring the intervention's safety and potentially life-saving benefits. This result is comparable to known literature; for example, a previous study that investigated the effects of "Y" and "X" Stent-Assisted Coiling in treating Complex and Wide-Neck Intracranial Bifurcation Aneurysms documented a mortality rate of 1.0% regarding 105 patients evaluated (3). This mortality rate of 1% was attributed to the notable occurrence of aneurysms in locations such as the ACOM and MCA bifurcations in that study. The effectiveness of the LVIS devices, in general, has been comparable to other stents, especially concerning primary endpoints like patient mortality and aneurysm sealing (15). Its reliability has been affirmed in individual studies across the literature (28,41). Earlier research emphasizing the occurrence of complications with LVIS Jr that led to morbidity or mortality demonstrated rates ranging from 2.3% to 5.6% (4,21,24,30,43,46). This data is notably corroborated by large-scale investigations, like the Canadian CARLA registry and the TRIAL study. It's crucial to mention that these research endeavors, akin to our review, specifically focused on the utilization of LVIS Jr for managing wide-necked cerebral aneurysms.

Endovascular procedures have occasionally been linked with certain complications. During stent deployment, the "shelf" technique allows the stent to extend into the aneurysm neck for optimal neck coverage. This method is particularly useful for wide-necked bifurcation aneurysms, potentially negating the necessity for intricate stent configurations and thereby decreasing angiographic complications (46). Complications such as internal carotid artery dissection by the guide catheter and stent opening should be mentioned (37). In a previous study that analyzed 100 patients treated with the LVIS Jr stent, there was a 14% occurrence rate of thromboembolic complications (46). In contrast, our findings indicate a complication rate of 6% (95% CI 0.04-0.08).

Various stents have demonstrated differing complication rates in previous studies. The LEO Baby stent showed a 17% rate of complications, while the Acclino stent registered a rate range of 18%-33% complications (26,33,49). A previous study using the Neuroform Atlas stent on 36 aneurysms resulted in a 5.5% complication rate, with incidents including an aneurysm and vessel perforation during implantation. In contrast, the LVIS Jr device, with its 1.5 mm cell size, offers potential flow diversion benefits and protection against coil protrusion (9,12). Its full visibility under fluoroscopy, thanks to three radiopaque helical strands, ensures accurate placement and easy post-deployment checks (44). In conclusion, the LVIS Jr stent plays an important role in the landscape of endovascular interventions. The critical need for tailored decision-making, which integrates broad research findings with individual patient characteristics, is evident in ensuring optimal clinical outcomes with such advanced tools at our disposal.

### Limitations

This meta-analysis, while comprehensive, carries some inherent limitations. The ever-present risk of publication bias exists, where studies with positive findings are more likely to

be published, potentially skewing our overall interpretation. Moreover, the studies incorporated display heterogeneity in terms of design, methodologies, and patient demographics. Although specific models to offset this diversity have been employed, they cannot completely negate the differences across these studies. Another challenge faced was basing the analysis on published outcomes rather than on individual patient data. With raw data, the potential analysis might have been even more nuanced. Potential confounding variables not identified in every study, which could influence the aggregated results, also have to be taken into account. Lastly, the general applicability of the findings might be constrained, especially in areas or among populations not well-represented in our selected studies. Therefore, while this meta-analysis offers substantial insights, it is imperative to approach the results with a discerning eye, especially when translating them to individual clinical scenarios. Given these considerations, it becomes evident that further studies, with refined methodologies and broader populations, are essential to validate and expand upon our findings, ensuring more comprehensive and universally applicable results in the future.

### CONCLUSION

In this systematic review and meta-analysis, the efficacy and safety of the LVIS Jr in treating wide-necked cerebral aneurysms were closely examined. The findings revealed a significant final occlusion rate and favorable clinical outcomes. These results, paired with a low mortality rate, emphasize the potential advantages of the LVIS Jr in endovascular procedures. Although the primary focus of the study was directed towards LVIS Jr, discussions around its potential benefits frequently alluded to its comparative advantages over other stents. Nevertheless, any intervention should be contextualized, with decisions tailored based on the device's merits and the specificities of the individual patient and clinical scenario. Given the insights and challenges encountered in this study, it is evident that future research is needed to further validate and expand on these observations, ensuring the continued refinement of interventions for patients with wide-necked cerebral aneurysms.

#### Declarations

**Funding:** This research did not receive any specific grant from funding agencies in the public, not-for-profit, or commercial sectors.

**Availability of data and materials:** Not applicable

**Disclosure:** The authors declare that there are no conflicts of interest related to this study.

#### AUTHORSHIP CONTRIBUTION

Study conception and design: MPS, RB, SB

Data collection: GNM, LVA, MPS

Analysis and interpretation of results: GV, GMS, LBO, FFA

Draft manuscript preparation: LBO, RB, MPS, RMB, SB

Critical revision of the article: RMB, RB, SB, FFA

Other (study supervision, fundings, materials, etc...): LVA, GNM

All authors (MPS, GNM, LVA, FFA, LBO, GV, SB, GMS, RMB, RB) reviewed the results and approved the final version of the manuscript.

## ■ REFERENCES

- Alghamdi F, Mine B, Morais R, Scillia P, Lubicz B: Stent-assisted coiling of intracranial aneurysms located on small vessels: Midterm results with the LVIS Junior stent in 40 patients with 43 aneurysms. *Neuroradiology* 58:665-671, 2016. <https://doi.org/10.1007/s00234-016-1668-z>
- Aydin K, Arat A, Sencer S, Barbuoglu M, Men S: Stent-assisted coiling of wide-neck intracranial aneurysms using low-profile LEO Baby stents: Initial and midterm results. *AJNR Am J Neuroradiol* 36:1934-1941, 2015. <https://doi.org/10.3174/ajnr.A4355>
- Bartolini B, Blanc R, Pistocchi S, Redjem H, Piotin M: "Y" and "X" stent-assisted coiling of complex and wide-neck intracranial bifurcation aneurysms. *AJNR Am J Neuroradiol* 35:2153-2538, 2014. <https://doi.org/10.3174/ajnr.A4060>
- Behme D, Weber A, Kowoll A, Berlis A, Burke TH, Weber W: Low-profile Visualized Intraluminal Support device (LVIS Jr) as a novel tool in the treatment of wide-necked intracranial aneurysms: Initial experience in 32 cases. *J Neurointerv Surg* 7:281-285, 2015. <https://doi.org/10.1136/neurintsurg-2014-011157>
- Boddu SR, Link TW, Santillan A, Sax-Bolder A, Lin N, Gobin P, Patsalides A, Knopman J: Double stent-assisted (Y and X) coil embolization of unruptured intracranial saccular aneurysms using the low-profile visualized intraluminal support device-single center experience. *J Vasc Interv Neurol* 10:1-9, 2019
- Cagnazzo F, Limbucci N, Nappini S, Renieri L, Rosi A, Laiso A, Tiziano di Carlo D, Perrini P, Mangiafico S: Y-Stent-assisted coiling of wide-neck bifurcation intracranial aneurysms: A meta-analysis. *AJNR Am J Neuroradiol* 40:122-128, 2019. <https://doi.org/10.3174/ajnr.A5900>
- Cekirge HS, Yavuz K, Geyik S, Saatci I: A novel "Y" stent flow diversion technique for the endovascular treatment of bifurcation aneurysms without endosaccular coiling. *AJNR Am J Neuroradiol* 32:1262-1268, 2011. <https://doi.org/10.3174/ajnr.A2475>
- Chalouhi N, Jabbour P, Singhal S, Drueding R, Starke RM, Dalyai RT, Tjoumakaris S, Gonzalez LF, Dumont AS, Rosenwasser R, Randazzo CG: Stent-assisted coiling of intracranial aneurysms: Predictors of complications, recanalization, and outcome in 508 cases. *Stroke* 44:1348-1353, 2013. <https://doi.org/10.1161/STROKEAHA.111.000641>
- Cho YD, Sohn CH, Kang HS, Kim JE, Cho WS, Hwang G, Kwon OK, Ko MS, Park NM, Han MH: Coil embolization of intracranial saccular aneurysms using the Low-profile Visualized Intraluminal Support (LVIS™) device. *Neuroradiology* 56:543-551, 2014. <https://doi.org/10.1007/s00234-014-1363-x>
- Choi HH, Cho YD, Yoo DH, Ahn SJ, Cho WS, Kang HS, Kim JE, Lee JJ, Moon JH, Han MH: Stent-assisted coil embolization of anterior communicating artery aneurysms: Safety, effectiveness, and risk factors for procedural complications or recanalization. *J Neurointerv Surg* 11:49-56, 2019. <https://doi.org/10.1136/neurintsurg-2018-013943>
- Chow MM, Woo HH, Masaryk TJ, Rasmussen PA: A novel endovascular treatment of a wide-necked basilar apex aneurysm by using a Y-configuration, double-stent technique. *AJNR Am J Neuroradiol* 25:509-512, 2004.
- Ciccio' G, Smajda S, Robert T, Blanc R, Redjem H, Takezawa H, Sasannejad P, Piotin M: Abstract WP89: Preliminary single-center experience with Neuroform atlas Stent-assisted coiling for unruptured intracranial aneurysms. *Stroke* 48: Suppl 1, 2017. [https://doi.org/10.1161/str.48.suppl\\_1.wp89](https://doi.org/10.1161/str.48.suppl_1.wp89)
- Conrad MD, Brasiliense LB, Richie AN, Hanel RA: Y stenting assisted coiling using a new low profile visible intraluminal support device for wide necked basilar tip aneurysms: A technical report. *J Neurointerv Surg* 6:296-300, 2014. <https://doi.org/10.1136/neurintsurg-2013-010818>
- Darflinger RJ, Chao K: Using the barrel technique with the LVIS Jr (Low-profile Visualized Intraluminal Support) stent to treat a wide neck MCA bifurcation aneurysm. *J Vasc Interv Neurol* 8:25-27, 2015
- Davidov V, Sadrameli S, Desai V: Feasibility and efficacy of low-profile visual intraluminal support device: A single-center five-year experience. *Curr Neurovasc Res* 18:279-286, 2021. <https://doi.org/10.2174/1567202618666210910123134>
- Dayawansa S, Sulhan S, Huang JH, Noonan PT: Endosurgical remodeling of wide-necked bifurcation aneurysms. *Front Neurol* 10:245, 2019. <https://doi.org/10.3389/fneur.2019.00245>
- Du EHY, Shankar JJS: LVIS Jr 'shelf' technique: An alternative to Y stent-assisted aneurysm coiling. *J Neurointerv Surg* 8:1256-1259, 2016. <https://doi.org/10.1136/neurintsurg-2015-012246>
- Endo H, Mitome-Mishima Y, Suzuki K, Yatomi K, Teranishi K, Oishi H: Long-term outcomes of Y-stent-assisted coil embolization using Low-profile Visualized Intraluminal Support Junior (LVIS Jr) for intracranial bifurcation aneurysms. *Clin Neurol Neurosurg* 217:107275, 2022. <https://doi.org/10.1016/j.clineuro.2022.107275>
- Fargen KM, Mocco J, Neal D, Dewan MC, Reavey-Cantwell J, Woo HH, Fiorella DJ, Mokin M, Siddiqui AH, Turk AS, Turner RD, Chaudry I, Kalani MY, Albuquerque F, Hoh BL: A multicenter study of stent-assisted coiling of cerebral aneurysms with a Y configuration. *Neurosurgery* 73:466-472, 2013. <https://doi.org/10.1227/NEU.0000000000000015>
- Feng Z, Li Q, Zhao R, Zhang P, Chen L, Xu Y, Hong B, Zhao W, Liu J, Huang Q: Endovascular treatment of middle cerebral artery aneurysm with the LVIS Junior Stent. *J Stroke Cerebrovasc Dis* 24:1357-1362, 2015. <https://doi.org/10.1016/j.jstrokecerebrovasdis.2015.02.016>
- Grossberg JA, Hanel RA, Dabus G, Keigher K, Haussen DC, Sauvageau E, Linfante I, Gonsales D, Aguilar Salinas P, Bouslama M, Mayich M, Nogueira RG, Lopes DK: Treatment of wide-necked aneurysms with the Low-profile Visualized Intraluminal Support (LVIS Jr) device: A multicenter experience. *J Neurointerv Surg* 9:1098-1102, 2017. <https://doi.org/10.1136/neurintsurg-2016-012687>
- Gupta M, Cheung VJ, Abraham P, Wali AR, Santiago-Dieppa DR, Gabel BC, Almansouri A, Pannell JS, Khalessi AA: Low-profile visualized intraluminal support junior device for the treatment of intracranial aneurysms. *Cureus* 9:e1037, 2017. <https://doi.org/10.7759/cureus.1037>
- Housley SB, Cappuzzo JM, Waqas M, Monteiro A, Levy EI, Siddiqui AH: FRED flow diversion with LVIS protection of large posterior communicating artery aneurysm: The "FRELVIS" technique. *Neurosurg Focus Video* 7:V4, 2022. <https://doi.org/10.3171/2022.7.FOCVID2262>

24. Iosif C, Piotin M, Saleme S, Barreau X, Sedat J, Chau Y, Sourour N, Aggour M, Brunel H, Bonafe A, Machi P, Riquelme C, Costalat V, Pierot L, Blanc R, Mounayer C, TRAIL Investigators: Safety and effectiveness of the Low Profile Visualized Intraluminal Support (LVIS and LVIS Jr) devices in the endovascular treatment of intracranial aneurysms: Results of the TRAIL multicenter observational study. *J Neurointerv Surg* 10:675-681, 2018. <https://doi.org/10.1136/neurintsurg-2017-013375>
25. Izar B, Rai A, Raghuram K, Rotruck J, Carpenter J: Comparison of devices used for stent-assisted coiling of intracranial aneurysms. *PLoS One* 6:e24875, 2011. <https://doi.org/10.1371/journal.pone.0024875>
26. Kabbasch C, Liebig T, Faymonville A, Dorn F, Mpotsaris A: Initial clinical experience with a new self-expanding nitinol microstent for the treatment of wide-neck intracranial cerebral aneurysms: The acandis Acclino Stent. *J Vasc Interv Neurol* 8:1-6, 2015
27. Kheradmand D, Sasannejad P, Zabihiyan S, Etemadrezaie H, Fazeli F, Humain B: Y stent technique for treatment of wide-based neck cerebral aneurysm. *J Neurol Sci* 405:147-148, 2019. <https://doi.org/10.1016/j.jns.2019.10.720>
28. Kim SS, Park H, Lee KH, Jung S, Yoon CH, Kim SK, Ryu KH, Baek HJ, Hwang SH, Kwon OK: Utility of low-profile visualized intraluminal support junior stent as a rescue therapy for treating ruptured intracranial aneurysms during complicated coil embolization. *World Neurosurg* 135:e710-e715, 2020. <https://doi.org/10.1016/j.wneu.2019.12.110>
29. King B, Vaziri S, Singla A, Fargen KM, Mocco J: Clinical and angiographic outcomes after stent-assisted coiling of cerebral aneurysms with Enterprise and Neuroform stents: A comparative analysis of the literature. *J Neurointerv Surg* 7:905-909, 2015. <https://doi.org/10.1136/neurintsurg-2014-011457>
30. Koch MJ, Stapleton CJ, Raymond SB, Williams S, Leslie-Mazwi TM, Rabinov JD, Patel AB: LVIS Blue as a low porosity stent and coil adjuvant. *J Neurointerv Surg* 10:682-686, 2018. <https://doi.org/10.1136/neurintsurg-2017-013608>
31. Lauzier DC, Root BK, Chatterjee AR, Osburn JW, Moran CJ, Kansagra AP: Need for Y-stenting in stent-assisted coiling of wide-neck bifurcation aneurysms. *Clin Neurol Neurosurg* 229:107748, 2023. <https://doi.org/10.1016/j.clineuro.2023.107748>
32. Limbucci N, Renieri L, Nappini S, Consoli A, Rosi A, Mangiafico S: Y-stent assisted coiling of bifurcation aneurysms with Enterprise stent: Long-term follow-up. *J Neurointerv Surg* 8:158-162, 2016. <https://doi.org/10.1136/neurintsurg-2014-011483>
33. Machi P, Costalat V, Lobotesis K, Ruiz C, Cheikh YB, Eker O, Gascou G, Danière F, Riquelme C, Bonafé A: LEO baby stent use following balloon-assisted coiling: Single- and dual-stent technique--immediate and midterm results of 29 consecutive patients. *AJNR Am J Neuroradiol* 36:2096-2103, 2015. <https://doi.org/10.3174/ajnr.A4413>
34. Maldonado IL, Machi P, Costalat V, Mura T, Bonafé A: Neuroform stent-assisted coiling of unruptured intracranial aneurysms: Short- and midterm results from a single-center experience with 68 patients. *AJNR Am J Neuroradiol* 32:131-136, 2011. <https://doi.org/10.3174/ajnr.A2245>
35. Mascitelli JR, Lawton MT, Hendricks BK, Nakaji P, Zabramski JM, Spetzler RF: Analysis of wide-neck aneurysms in the barrow ruptured aneurysm trial. *Neurosurgery* 85:622-631, 2019. <https://doi.org/10.1093/neuros/nyy439>
36. Mine B, Aljishi A, D'Harcour JB, Brisbois D, Collignon L, Lubicz B: Stent-assisted coiling of unruptured intracranial aneurysms: Long-term follow-up in 164 patients with 183 aneurysms. *J Neuroradiol* 41:322-328, 2014. <https://doi.org/10.1016/j.neurad.2014.01.001>
37. Möhlenbruch M, Herweh C, Behrens L, Jestaedt L, Amiri H, Ringleb PA, Bendszus M, Pham M: The LVIS Jr. microstent to assist coil embolization of wide-neck intracranial aneurysms: clinical study to assess safety and efficacy. *Neuroradiology* 56:389-395, 2014. <https://doi.org/10.1007/s00234-014-1345-z>
38. Oishi H, Fujii T, Yatomi K, Teranishi K, Suzuki K, Mishima Y, Nakajima S: Stent-assisted coil embolization of unruptured middle cerebral artery aneurysms using LVIS Jr. stents. *J Clin Neurosci* 80:87-91, 2020. <https://doi.org/10.1016/j.jocn.2020.07.070>
39. Page MJ, McKenzie JE, Bossuyt PM, Boutron I, Hoffmann TC, Mulrow CD, Shamseer L, Tetzlaff JM, Akl EA, Brennan SE, Chou R, Glanville J, Grimshaw JM, Hróbjartsson A, Lalu MM, Li T, Loder EW, Mayo-Wilson E, McDonald S, McGuinness LA, Stewart LA, Thomas J, Tricco AC, Welch VA, Whiting P, Moher D: The PRISMA 2020 statement: An updated guideline for reporting systematic reviews. *Pan Am J Public Health* 46:e112, 2022. <https://doi.org/10.1136/bmj.n71>
40. Park KY, Kim BM, Kim DJ, Chung J, Lee JW: Y-configuration stenting for coiling of wide-neck bifurcation aneurysms using Low-profile Visualized Intraluminal Support Junior. *J Neurointerv Surg* 11:400-404, 2019. <https://doi.org/10.1136/neurintsurg-2018-014128>
41. Pelz DM, Lownie SP, Fox AJ: Thromboembolic events associated with the treatment of cerebral aneurysms with Guglielmi detachable coils. *AJNR Am J Neuroradiol* 19:1541-1547, 1998
42. Piotin M, Blanc R, Spelle L, Mounayer C, Piantino R, Schmidt PJ, Moret J: Stent-assisted coiling of intracranial aneurysms: Clinical and angiographic results in 216 consecutive aneurysms. *Stroke* 41:110-115, 2010. <https://doi.org/10.1161/STROKEAHA.109.558114>
43. Pencyljusz W, Biliński P, Safranow K, Baron J, Zbrozarczyk M, Jaworski M, Bereza S, Burke TH: The LVIS/LVIS Jr. stents in the treatment of wide-neck intracranial aneurysms: Multicentre registry. *J Neurointerv Surg* 7:524-529, 2015. <https://doi.org/10.1136/neurintsurg-2014-011229>
44. Samaniego EA, Mendez AA, Nguyen TN, Kalousek V, Guerrero WR, Dandapat S, Dabus G, Linfante I, Hassan AE, Drofa A, Kouznetsov E, Leedahl D, Hasan D, Maud A, Ortega-Gutierrez S: LVIS Jr device for Y-stent-assisted coil embolization of wide-neck intracranial aneurysms: A multicenter experience. *Intervent Neurol* 7:271-283, 2018. <https://doi.org/10.1159/000487545>
45. Santillan A, Boddu S, Schwarz J, Lin N, Gobin YP, Knopman J, Patsalides A: LVIS Jr. stent for treatment of intracranial aneurysms with parent vessel diameter of 2.5 mm or less. *Intervent Neuroradiol* 24:246-253, 2018. <https://doi.org/10.1177/1591019918759307>

46. Shankar JJS, Quateen A, Weill A, Tampieri D, Del Pilar Cortes M, Fahed R, Patro S, Kaderali Z, Lum C, Lesiuk H, Ahmed U, Peeling L, Kelly ME, Iancu D: Canadian Registry of LVIS Jr for Treatment of Intracranial Aneurysms (CaRLA). *J Neurointerv Surg* 9:849-853, 2017. <https://doi.org/10.1136/neurintsurg-2016-012611>
47. Son C, Page P, Niemann D: Cerebral aneurysms treated with low-profile visualized intraluminal support device (LVIS Jr) Y-stent constructs: Technical experience with a single microcatheter technique. *Intervent Neuroradiol* 26:156-163, 2020. <https://doi.org/10.1177/1591019919880420>
48. Takano N, Suzuki M, Irie R, Yamamoto M, Teranishi K, Yatomi K, Hamasaki N, Kumamaru KK, Hori M, Oishi H, Aoki S: Non-contrast-enhanced silent scan MR angiography of intracranial anterior circulation aneurysms treated with a low-profile visualized intraluminal support device. *AJNR Am J Neuroradiol* 38:1610-1616, 2017. <https://doi.org/10.3174/ajnr.A5223>
49. Tureli D, Sabet S, Senol S, Andac N, Donmez H, Geyik S, Baltacioglu F, Cekirge S: Stent-assisted coil embolization of challenging intracranial aneurysms: Initial and mid-term results with low-profile ACCLINO devices. *Acta Neurochirurgica* 158:1545-1553, 2016. <https://doi.org/10.1007/s00701-016-2839-8>
50. Wallace AN, Kayan Y, Delgado Almandoz JE, Fease JL, Milner AA, Scholz JM: Endovascular treatment of wide-necked intracranial aneurysms with the scepter XC balloon catheter, with low-profile visualized intraluminal support (LVIS) Jr. deployment as a “bailout” technique. *World Neurosurg* 121:e798-e807, 2019. <https://doi.org/10.1016/j.wneu.2018.09.226>
51. Zhao KJ, Yang PF, Huang QH, Li Q, Zhao WY, Liu JM, Hong B: Y-configuration stent placement (crossing and kissing) for endovascular treatment of wide-neck cerebral aneurysms located at 4 different bifurcation sites. *AJNR Am J Neuroradiol* 33:1310-1316, 2012. <https://doi.org/10.3174/ajnr.A2961>