



Neglected Case of Cervical Meningocele in an Adult

Ismail BOZKURT^{1,2}, Afife DURLANIK³, Suat CANBAY⁴

¹Medical Park Ankara Hospital, Department of Neurosurgery, Ankara, Türkiye

²Yuksekk Ihtisas University, School of Medicine, Department of Neurosurgery, Ankara, Türkiye

³Electro neurophysiology Technician, Ankara, Türkiye

⁴Suat Canbay Clinic, Ankara, Türkiye

Corresponding author: Ismail BOZKURT ✉ ibozkurt85@gmail.com

ABSTRACT

Neural tube defects (NTD), caused by a disturbance in the neurulation process, are easily diagnosed and treated in the early years of life. Although early repair of NTD is advocated, there is lacking information on its natural course. There are only 11 cases, including this one, reported in literature of a cervical meningocele diagnosed and treated in an adult. A 64-year-old male patient was aware of a skin lesion on his neck but had not consulted a physician until 3 years ago when he started experiencing neuropathic pain in his arms. Cervical MRI revealed a posterior arch fusion defect, a syrinx cavity between the C2-C6 levels with a tethering meningocele at the C6 level. He was operated on with the excision of the skin tag and connecting stalk. During prone positioning and neck flexion, intraoperative neuromonitorization indicated a loss in MEP values; thus, flexion was reduced. Intradural adhesiolysis of the connecting bands around the spinal cord was performed, and dura was sutured. The patient recovered uneventfully, but he still had neuropathic pain in his left arm aggravated by straining. Histological analysis revealed meningothelial cells and psammoma bodies. Postoperative MRI revealed the untethering of the spinal cord with relative reduction in the syrinx cavity. NTD can be easily detected and treated early in life to prevent neurological deterioration, to decrease the rate of infection, and to improve cosmetic appearance. However, because they are mostly treated during childhood, their natural course in adulthood remains unknown. There are only a handful of case reports of cervical meningoceles in adults. Pathological analysis suggestive of a meningioma may also shed light on the theory of "cutaneous meningioma." In addition, the loss of MEP values in neck flexion should caution surgeons in avoiding hyperflexion, especially in cases of spinal cord tethering.

KEYWORDS: Meningocele, Neural tube defect, Adult, Meningioma, Neuromonitorization

ABBREVIATIONS: NTD: Neural tube defect, CSF: Cerebrospinal fluid, IONM: Intraoperative neuro monitorization, SSEP: somatosensory evoked potentials, MEP: Motor evoked potentials

INTRODUCTION

Caused by a disturbance in the neurulation process, neural tube defects (NTD) have a worldwide incidence of 1-10 per 1,000 births. A meningocele is a type of NTD in which the meninges and cerebrospinal fluid (CSF) protrude into the subcutaneous tissue through a spinal defect with overlying intact skin. Although it is also a neural tube defect, cervical meningoceles should not be confused with occipital encephaloceles as they are the herniation of cranial contents and require urgent intervention (12). The

precise etiology remains unknown, but folate deficiency, genetic, and environmental risk factors are blamed. Most meningoceles are asymptomatic, but their size, location, and relation to the surrounding neurological structures may cause back pain, bladder symptoms, paresthesia, and paresis. Meningocele, like any other NTDs, are surgically treated after diagnosis. Although their timing and relation to preventing further neurological compromise are debatable, neurological deterioration, prevention of infection, and cosmetic correction are aimed (9).

The literature review yielded very few cases of adult cervical meningoceles as these entities are usually treated during childhood. Knowledge of the course of meningocele development during adulthood is limited. Thus, we present an extremely rare case of cervical meningocele in a 64-year-old man and discuss the clinical features, surgical treatment and outcome with possible clues to the natural history of its pathology.

■ CASE PRESENTATION

A 64-year-old male patient presented to our clinic complaining of numbness, weakness, and pain bilaterally distributed to the forearms with right predominance. He had been diagnosed with insulin resistance 6 years ago and was prescribed metformin HCl 1000 mg daily. He was also diagnosed with COVID-19 pneumonia 7 months ago and was treated by the outpatient department. The patient had a swelling on his neck, which he stated was congenital. There was no soreness over the lesion and no discharge. He was diagnosed with meningocele approximately 7 years ago, and numerous neurosurgical evaluations advised a conservative approach. He was diagnosed with left cubital tunnel syndrome 3 years ago and received 14 sessions of physical therapy. He was also prescribed gabapentin 600mg twice daily and duloxetine 60mg daily for his pain. A year ago, he was diagnosed with right carpal tunnel syndrome and received 15 sessions of physical therapy. Pregabalin 75mg twice daily was added to his treatment regimen. During this period, he also had a history of chronic constipation, a colonoscopy was performed but revealed no abnormality, and he was prescribed lactulose. None of the treatments proved to be effective.

Upon examination, the patient had a motor strength of 4-/5 in the right elbow and wrist flexion, 4/5 in the left elbow and wrist flexion, and 4/5 in the right thumb opposition. Right-sided thenar atrophy was noted. He had wide hypoesthesia with distributions in the C5-T1 dermatomes. Deep tendon reflexes were normal, and there were no pathological reflexes. No neurological dysfunction was observed in the lower extremities, and normal bladder function was present. The visual analog scale score of the pain in the right upper extremity was 7/10. A nontender skin lesion covered with a dysplastic skin was noted at the C6 midline level (Figure 1).

Upon radiological evaluation, a posterior arch fusion defect was observed in the C5 and C6 vertebrae and a floating C6 accessory spinous process (Figure 2). Noncontrast enhanced cervical MRI (Figure 3A) revealed a syrinx cavity extending from the C2 to C6 levels with a tethering meningocele at the C6 level. Brain and spinal MRI revealed no other pathological findings. The patient was subsequently operated on.

Under general anesthesia and intraoperative neuromonitorization (IONM), the patient was intubated in the supine position. The head was fixated using a Mayfield skull clamp. After obtaining the baseline values for posterior tibial and median nerve somatosensory evoked potentials (SSEP) and motor evoked potentials (MEP), the patient was placed in the prone position and the surgical table was set to the Concorde posi-

tion. However, upon flexion of the neck, the MEP values dramatically decreased in all four extremities (Figure 4). The neck was brought to a relative extension position, and the values normalized after 5 min.

With a midline incision at the C3-7 levels and a circumferential incision at the skin tag, the paravertebral muscles were dissected subperiosteally. The dural connection was used as a guide to perform bilateral laminectomies at the C4-5-6 levels. Dura was opened in the midline, and the subarachnoid adhesions in the posterolateral areas were dissected. The stalk connecting the meningocele to the posterior of the spinal cord was fibrotic and hard with a gliotic and soft surrounding at the base. Then, using a nerve probe, the stalk was tested to recognize any nerve structures that may have extended into the tethering. With no positive results from the IONM, the meningocele was first incised to visualize its contents and excised after no nerve structures were observed, confirming the preoperative MRI images with intraoperative findings and classifying the pathology as a type 3 cystic spinal dysraphism (13). The remaining stump was lightly cauterized. The spinal cord was confirmed to be loose of any tethering in the posterolateral region. Dura was sutured in a watertight fashion along with the fascia. The patient was extubated and no additional neurological deficits were observed. The postoperative period was uneventful, and the patient was

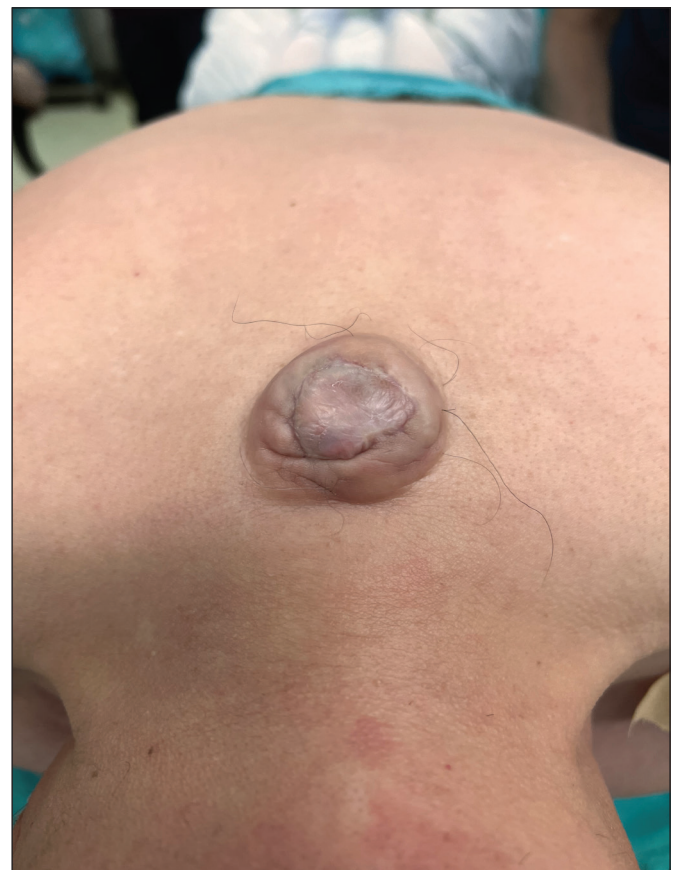

Figure 1: Non-tender skin lesion at the C6 midline level covered with dysplastic skin.

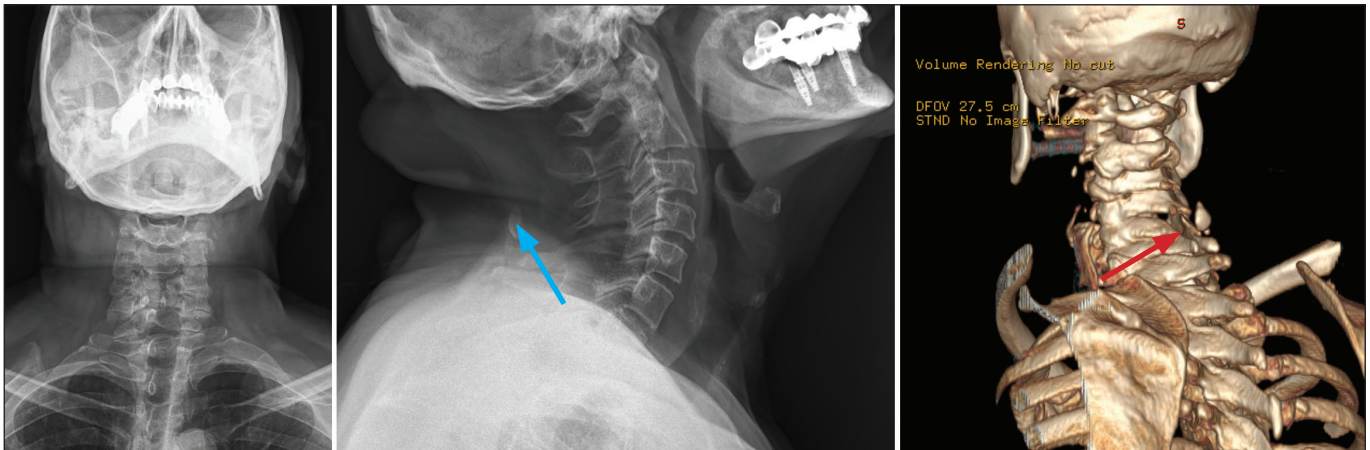


Figure 2: Posterior arch fusion defect at the C5 and C6 levels and a floating C6 accessory spinous process.

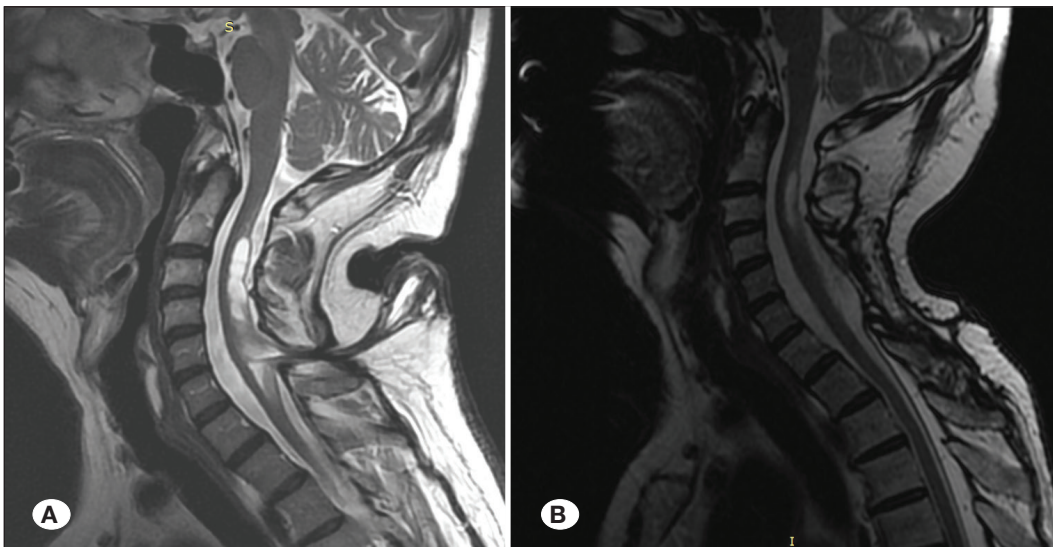

Figure 3: Cervical sagittal T2-weighted MRI. **A)** Pre-operative. Note the syrinx cavity and the tethering meningocele at the C6 level. **B)** Post-operative. Significant resolution of the syrinx cavity with detethered spinal cord.

discharged with mild analgesics and appropriate antibiotics. Histopathological analysis revealed no neural tissue within the mass with dense connective tissue and parts of the skin and subcutaneous tissue. However, meningotheial cell clusters and psammoma bodies were observed (Figure 5). At his sixth month control, he continued receiving neuropathic pain treatment as the postoperative EMG study yielded C5-T1 chronic radiculopathy signs. At his one-year follow-up, the syrinx cavity resolved significantly (Figure 3B). His only remaining complaint was a tingling sensation in his left arm followed by straining.

DISCUSSION

The study was carried out according to the latest revision of the Helsinki Declaration regarding medical research involving human subjects. Informed written consent was acquired from the patient before the study. No IRC board approval was obtained due to the publication being a case report and anonymity of the patient.

Since a meningocele usually has no functional neural involvement, its symptoms and prognosis are excellent. Surgical repair at the time of diagnosis is believed to prevent infection and neurological compromise while improving cosmetic appearance. Its incidence has decreased dramatically after folic acid supplements during pregnancy (9). A review of 11 cases, including our own (Table I), found that adult cervical meningoceles are rare and there is limited knowledge regarding their clinical features, treatment, and outcomes.

Although NTDs have been extensively studied and classified, adulthood rudimentary meningoceles may require special attention. Instead of a simple cystic dilatation of the meninges through a defect filled with CSF, adulthood meningoceles have been called “cutaneous meningioma.” It is believed that the meningeal cells along the cutaneous nerves proliferate, leading to a solid cutaneous mass (14). Although the possible neoplastic process of meningoceles needs to be elucidated, this warrants early surgical removal and repair even in asymptomatic cases. The histological analysis of this case revealed

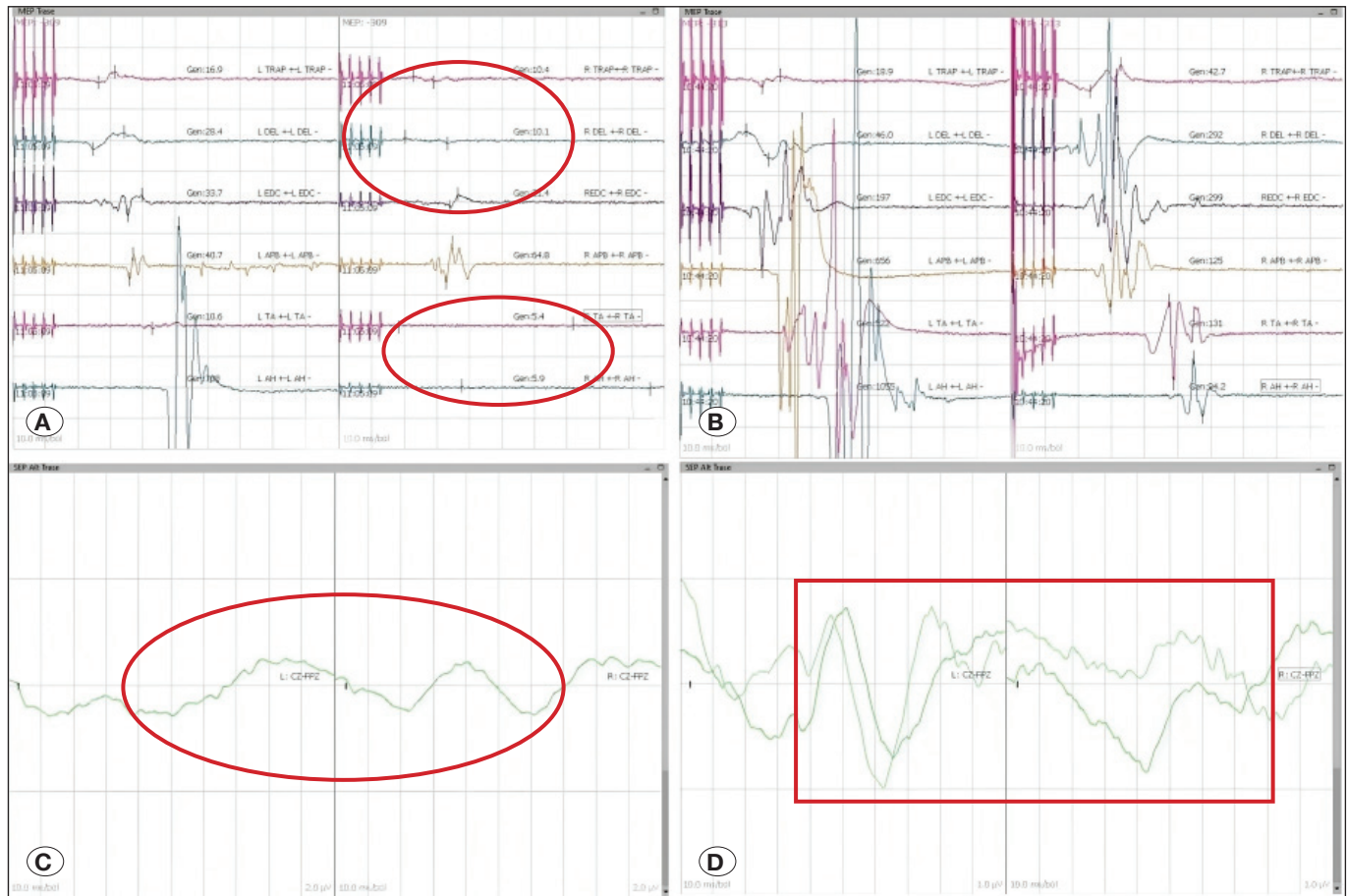


Figure 4: Pre-operative hyperflexion of the neck caused a major block in impulse condition. **A)** MEP values decreased to 10% of the baseline. **C)** No SSEP values observed. After correction of the hyperflexion, **B)** MEP values and **D)** SSEP values returned to normal.

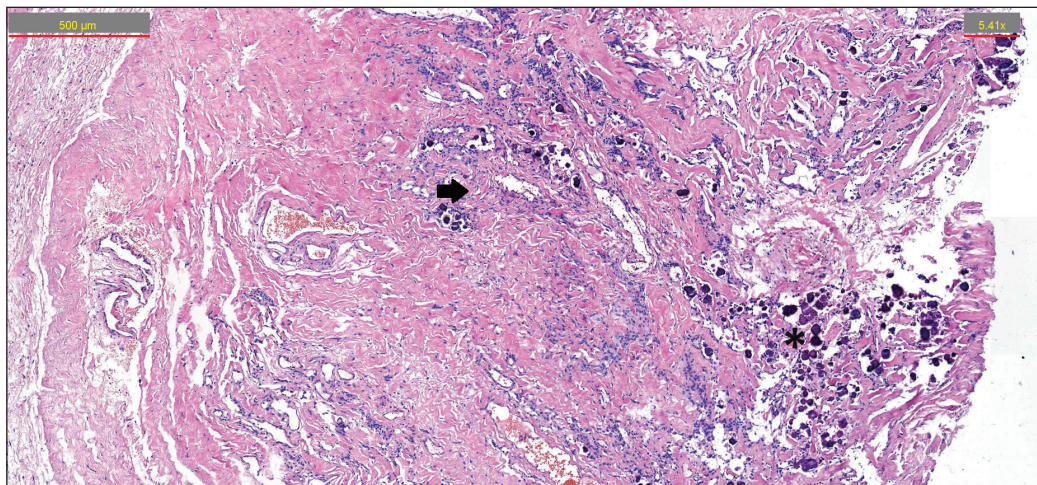


Figure 5: Hematoxylin and eosin stain clearly depicting the Psammoma bodies (asterisk) and meningothelial cell clusters (arrow) which are typically observed in meningiomas (100x).

Table I: Previous Reports of Adult Cervical Meningocele and Myelomeningocele

Author/Year	Age/ Gender	Affected Level	Type	Syrinx	Stalk Excision	Untethering, Adhesiolysis	Symptom	Outcome
Akay et al. (1) 2003	21/M	C2-3	MC	-	+	+	Cosmetic	Good
Konya et al. (8) 2006	47/M	C4-5	MC	-	+	+	Intermittent CSF leakage, lower extremity stiffness	Improved, asymptomatic
Denaro et al. (5) 2008	52/M	C4-5	MMC	+	+	+	Neurological deficits	Improved, asymptomatic
Duz et al. (6) 2008	22/M	C2-3	MC	-	+	+	Intermittent CSF leakage	Good
	22/M	C4-5	MC	-	+	+	Neck pain	Good
	20/M	C3-4	MC	-	+	+	Neurological deficits	Improved, asymptomatic
	20/M	C6-7	MC	-	+	+	Neck pain	Good
	18/M	C6-7	MC	-	+	+	Neurological deficits	Improved, asymptomatic
Wang et al. (14) 2013	21/F	C3-4	MC	-	+	+	Cosmetic	Good
Nourelidine et al. (10) 2020	47/M	C5-6	MMC	-	-	+	Neck pain, neurological deficits	Improved, minimum symptoms
This study	64/M	C5-6	MC	+	+	+	Neurological deficits, neuropathic pain	Improved, minimum symptoms

MC: Meningocele, **MMC:** Myelomeningocele

meningothelial cells, which are precursor cells for meningioma and psammoma bodies that are characteristic of a meningioma. Psammoma bodies are concentric lamellated calcified structures, but they remain unclear. Collagen production by neoplastic cells, followed by calcification, is the most commonly accepted theory. However, it is also believed to form a barrier around neoplastic cells, leading to the degeneration or retardation of tumor cells (4). The findings of this study may support the notion that psammoma bodies have successfully retarded the growth of a meningioma precursor and have resulted in the formation of a stable meningocele.

The case also presented a unique challenge while positioning the patient. IONM was performed in the supine position with normal MEP values but diminished median SSEP values only on the right side and absent tibial SSEP values. However, as soon as the patient was placed in the prone position with flexion of the neck to assist in the surgical approach, all MEP values diminished significantly. Fortunately, this was reversible with relaxation of neck flexion. Changes in IONM values after positioning the patient are not rare and have been

documented previously. Various etiologies include prone and sitting positioning, malposition, tapes, and tractions (7). This particular case may have had transient neurological function loss due to a couple of reasons. The tethering caused by the meningocele stalk, which was evident as it caused a syrinx cavity, might have been aggravated by neck flexion, leading to increased myelopathy. Another possible explanation is the hypoperfusion of the spinal cord due to the stretching of the spinal arteries during hyperflexion (3). Proper positioning of the patient with patient-specific placement of gel rolls and maintaining a proper arterial blood pressure are advised to prevent hypoperfusion. Several methods have been proposed to overcome the complications of placing the patient in the prone position. The most commonly employed method is the method used in this case, that is, the logroll method with manual in-line stabilization. It is easy to perform as no additional equipment is required, but the exact coordination of all members to keep the spine in the midline is a disadvantage. The “sandwich and flip” method is applicable to specialized spinal surgery tables, in which the patient is fixed both anteriorly and posteriorly with a neutral neck position before

being rotated with a built-in mechanism. However, this requires specialized instruments and trained personnel, which may not be present in most settings. The least used method due to the lack of familiarity and possible patient discomfort is awake-prone positioning (2).

Previous reports of adulthood meningocele and myelomeningocele advocated intradural adhesiolysis and untethering. Because most of the symptoms occurring in NTDs are due to the tight tethering of the spinal cord, removal of the stalk alone is not sufficient in treating or preventing symptoms. The patient in this case had a long-time neglected tethering, which at first, did not cause major symptoms, but over the years, it resulted in a syrinx cavity with aggravating symptoms. Although information on the natural course of cervical spinal cord pathologies with respect to age is limited, a biomechanical study of age-related changes in the spinal cord in bovine models has been conducted (11). In older bovine models, the white matter was more fragile than the gray matter and higher stress levels were observed in response to compression. This may explain why cervical myelopathy develops later with the progression of age and why the elderly have poorer postsurgical recovery.

CONCLUSION

Although benign in nature, meningoceles can cause symptoms with increasing age. In addition to improving cosmetic appearance and reducing the possibility of infection, repairing meningoceles at the time of diagnosis would prevent complications such as syringomyelia due to tethering. This case was unique as most meningoceles are surgically treated during the early years of life. Imaging and treatment of a 64-year-old patient with meningocele may shed light on the natural course of the disease. The possibility of a meningocele being a “cutaneous meningioma” should also be further evaluated.

Declarations

Funding: This research received no specific grant from any funding agency in the public, commercial, or not-for-profit sectors. No corporate, government or institutional funding has been received.

Availability of data and materials: All data underlying the results are available as part of the article and no additional source data are required.

Disclosure: The authors have no competing interests related to this study.

AUTHORSHIP CONTRIBUTION

Study conception and design: SC

Data collection: AD, IB

Analysis and interpretation of results: IB

Draft manuscript preparation: IB

Critical revision of the article: SC

Other (study supervision, fundings, materials, etc.): AD, SC, IB

All authors (IB, AD, SC) reviewed the results and approved the final version of the manuscript.

REFERENCES

1. Akay KM, Gönül E, Ocal E, Timurkaynak E: The initial treatment of meningocele and myelomeningocele lesions in adulthood: Experiences with seven patients. *Neurosurg Rev* 26:162-167, 2003. <https://doi.org/10.1007/s10143-002-0230-0>
2. Boyle SL, Unger Z, Kulkarni V, Massicotte EM, Venkatraghavan L: Prone positioning of patients with cervical spine pathology. *J Neuroanaesthesiol Critic Care* 7:70-76, 2020
3. Cavinato M, Vittoria F, Piccione F, Masiero S, Carbone M: The value of intraoperative neurophysiological monitoring during positioning in pediatric scoliosis correction: A case report. *Clin Neurophysiol Pract* 7:366-371, 2022. <https://doi.org/10.1016/j.cnp.2022.11.001>
4. Das DK: Psammoma body: A product of dystrophic calcification or of a biologically active process that aims at limiting the growth and spread of tumor? *Diagn Cytopathol* 37:534-541, 2009. <https://doi.org/10.1002/dc.21081>
5. Denaro L, Padoan A, Manara R, Gardiman M, Ciccarino P, d'Avella D: Cervical myelomeningocele in adulthood: Case report. *Neurosurgery* 62:E1169-E1171, 2008. <https://doi.org/10.1227/01.neu.0000325883.98246.64>
6. Duz B, Arslan E, Gonul E: Cervical congenital midline meningoceles in adults. *Neurosurgery* 63:938-945, 2008. <https://doi.org/10.1227/01.NEU.0000327577.49724.32>
7. Gowda S: Position-related neurovascular injuries detected by intraoperative monitoring. *Indian Spine J* 4:113-120, 2021. https://doi.org/10.4103/ISJ.ISJ_59_19
8. Konya D, Dagainar A, Akakin A, Gercek A, Ozgen S, Pamir MN: Cervical meningocele causing symptoms in adulthood: Case report and review of the literature. *J Spinal Disord Tech* 19:531-533, 2006. <https://doi.org/10.1097/01.bsd.0000211223.51436.0b>
9. Nethi S, Arya K: Meningocele. [Updated 2023 Sep 4]. In: StatPearls [Internet]. Treasure Island (FL): StatPearls Publishing, 2023. Available: <https://ncbi.nlm.nih.gov/books/NBK562174/>
10. Noureldine MHA, Peto I, Jallo GI, Agazzi S: Symptomatic recurrence of cervical spine myelomeningocele in an adult patient. *World Neurosurg* 137:376-378, 2020. <https://doi.org/10.1016/j.wneu.2020.02.102>
11. Okazaki T, Kanchiku T, Nishida N, Ichihara K, Sakuramoto I, Ohgi J, Funaba M, Imajo Y, Suzuki H, Chen X, Taguchi T: Age-related changes of the spinal cord: A biomechanical study. *Exp Ther Med* 15:2824-2829, 2018. <https://doi.org/10.3892/etm.2018.5796>
12. Ozdemir N, Ozdemir SA, Ozer EA: Management of the giant occipital encephaloceles in the neonates. *Early Hum Dev* 103:229-234, 2016. <https://doi.org/10.1016/j.earlhumdev.2016.10.006>
13. Ozdemir SA, Ozdemir N, Celik H, Ozer EA: Servikal meningomyeloselli yenidoğanların klinik ve cerrahi yönetimi. *Ankara Eğitim ve Araştırma Hastanesi Tıp Dergisi* 50:96-102, 2017
14. Wang H, Yu W, Zhang Z, Lu Y, Li X: Cervical rudimentary meningocele in adulthood. *J Neurosurg Spine* 18:511-514, 2013. <https://doi.org/10.3171/2013.2.SPINE12603>