



Assessment of Increased T2 Signal Activity in Patients with Cervical Spondylotic Myelopathy Undergoing Posterior Cervical Fusion

Semih Kivanc OLGUNER¹, Yurdal GEZERCAN¹, Zeki BOGA¹, Mehmet OZER¹, Mehmet SECER², Ferhat HARMAN^{3,4}, Can KIVRAK^{3,4}, Derya KARAOGLU⁵, Ender KOKTEKIR⁵, Hakan KARABAGLI⁵, Kadir OKTAY⁶, Tahsin ERMAN⁶, Mehmet Yigit AKGUN⁷, Ozkan ATES⁷, Melihcan SAVASCI⁸, Ahmet OGRENCI⁹, Sedat DALBAYRAK⁹, Tunc OKTENOGU¹⁰, Ali Fahir OZER¹⁰

¹Adana City Training Research Hospital, Department of Neurosurgery, Adana, Türkiye

²Alaaddin Keykubat Faculty of Medicine, Department of Neurosurgery, Alanya, Antalya, Türkiye

³Marmara University Faculty of Medicine, Department of Neurosurgery, Istanbul, Türkiye

⁴Marmara University Institute of Neurological Sciences, Department of Neurosurgery, Istanbul, Türkiye

⁵Selcuk University Faculty of Medicine, Department of Neurosurgery, Konya, Türkiye

⁶Cukurova University Faculty of Medicine, Department of Neurosurgery, Adana, Türkiye

⁷Koc University Faculty of Medicine, Department of Neurosurgery, Istanbul, Türkiye

⁸Bakirkoy, Prof. Dr. Mazhar Osman Training and Research Hospital, Department of Neurosurgery, Istanbul, Türkiye

⁹Atasehir Medica Hospital, Department of Neurosurgery, Istanbul, Türkiye

¹⁰Amerikan Hospital, Department of Neurosurgery, Istanbul, Türkiye

Corresponding author: Semih Kivanc OLGUNER ✉ gezercan@hotmail.com

ABSTRACT

AIM: To compare the preoperative and postoperative increased signal intensity (ISI) outcomes of cervical spondylotic myelopathy (CSM) patients who underwent posterior decompression and fusion, and to assess the correlation between ISI changes and postsurgical clinical prognosis.

MATERIAL and METHODS: The results from 123 patients were evaluated. In addition to demographic data, such as age and gender, factors, including body mass index (BMI); smoking history; duration of symptoms; follow-up periods; levels of decompression and fusion; comorbidities, such as diabetes, coronary artery disease, and hypertension; ISI grading; cervical sagittal vertical axis; C2-7 cervical lordosis parameters; and Modified Japanese Orthopedic Association (mJOA) scores, were statistically analyzed preoperatively and postoperatively.

RESULTS: ISI improved in 39 patients (31.7%), remained unchanged in 53 patients (latent, 43.1%), and deteriorated in 31 patients (25.2%). There were no statistically significant differences in terms of age, gender, BMI, or levels of decompression and fusion between patients with ISI improvement, latent ISI, and worsened ISI. Patients with ISI improvement had the highest postoperative C2-7 lordosis values and shortest duration of symptoms. There was no statistically significant difference in the mJOA scores between patients with and without ISI improvement.

CONCLUSION: ISI improvement in CSM patients undergoing posterior cervical decompression and fusion is influenced by symptom duration and preoperative–postoperative cervical lordosis values. However, this study did not find a correlation between ISI improvement and clinical recovery based on the mJOA scores.

KEYWORDS: Cervical spondylotic myelopathy, Increased signal intensity, Magnetic resonance imaging, Posterior fusion, Prognosis

Semih K. OLGUNER : 0000-0002-5314-4636

Yurdal GEZERCAN : 0000-0002-4124-2036

Zeki BOGA : 0000-0002-6387-5272

Mehmet OZER : 0009-0003-6709-5075

Mehmet SECER : 0000-0001-9521-2476

Ferhat HARMAN : 0000-0003-4685-2201

Can KIVRAK : 0000-0001-6008-1285

Derya KARAOGLU : 0000-0003-2345-8818

Ender KOKTEKIR : 0000-0002-6442-6663

Hakan KARABAGLI : 0000-0002-1184-3965

Kadir OKTAY : 0000-0003-2420-2734

Tahsin ERMAN : 0000-0002-2641-8216

Mehmet Yigit AKGUN : 0000-0003-1342-7663

Ozkan ATES : 0000-0002-3132-4839

Melihcan SAVASCI : 0000-0002-9364-4424

Ahmet OGRENCI : 0000-0002-7580-0227

Sedat DALBAYRAK : 0000-0001-9538-5190

Tunc OKTENOGU : 0000-0001-7431-0579

Ali Fahir OZER : 0000-0001-7285-381X

■ INTRODUCTION

Cervical spondylotic myelopathy (CSM) is a spinal disorder that causes spinal dysfunction and is more frequent in the elderly (3). Clinically, myelopathic symptoms, such as gait problems, numbness and clumsiness in the hands, and weakness in both the upper and lower extremities, reduced ambulatory and self-care abilities (15,18). The pathogenesis of this disease involves a combination of static and dynamic factors. Static factors include centrally located disc herniation, ligamentum flavum hypertrophy, and posterior longitudinal ligament hypertrophy (3,15,25). Instability pathologies are often accompanied by dynamic factors that are typically associated with instability-related manifestations. Magnetic resonance imaging (MRI) and clinical findings are currently used to diagnose this condition (2,15). Surgical intervention aims to halt disease progression and, if possible, to achieve clinical improvement (1). However, predicting the prognosis of this condition remains challenging, particularly in the elderly population. According to the literature, increased signal intensity (ISI) in T2-weighted (T2WI) MRI is a sign of spinal cord swelling and edema, and it serves as an indicator of poor prognosis (4,7,15,17,18,24,25). Some studies have suggested that a combined evaluation of decreased signal intensity on T1WI MRI and ISI on T2WI MRI is a more significant prognostic marker. ISI on T2WI is believed to regress and be reversible during the postoperative period, which has implications for prognosis (25). However, most of these studies focused on cases treated with anterior cervical discectomy and fusion, or posterior decompression and laminoplasty. To the best of our knowledge, no study has evaluated the change in ISI outcomes in patients who have undergone solely posterior decompression and fusion. This multicenter study aimed to compare the preoperative and postoperative T2WI MRI ISI outcomes of patients with CSM undergoing posterior decompression and fusion and assess the correlation between ISI changes and postoperative clinical prognosis.

■ MATERIAL and METHODS

Patient Population

This study retrospectively evaluated the results of 123 patients who underwent cervical posterior decompression, instrumentation, and fusion at seven centers between 2015 and 2022 due to CSM. The diagnostic process and surgical procedures were performed by experienced spinal surgeons at these centers, and the same physicians reviewed the records. In addition to demographic data such as age and gender, factors, including body mass index (BMI), smoking history, duration of symptoms, follow-up periods, levels of decompression and fusion, and comorbidities, such as diabetes, coronary artery disease (CAD), and hypertension (HT), were recorded. The inclusion criteria were adult patients with a minimum follow-up period of 1 yr who presented with multilevel spinal cord compression due to CSM, neck pain, and myelopathy and underwent posterior decompression and instrumented fusion. The exclusion criteria included patients under the age of 18 yr, previous cervical or lumbar spine surgery, motor neuron or polyneuropathy findings on electromyographic examination, and cervical kyphosis.

Radiological Evaluation

T2-weighted MRI was used to assess ISI both preoperatively and at 12 months postoperatively. ISI values from patients with a minimum follow-up period of 1 yr were included in the study. According to the classification of Yukawa et al., sagittal T2WI MR images were categorized into grades for ISI assessment: Grade 0, indicates no ISI; Grade 1, light ISI; and Grade 2, intense ISI (similar to cerebrospinal fluid) (23). The radiological parameters were evaluated using lateral cervical radiographs. The cervical sagittal vertical axis (cSVA) and C2-7 cervical lordosis (CL) were assessed preoperatively and at the last follow-up. The cSVA represents the distance between a line perpendicular to the center of C2 and the posterior superior corner of C7. C2-7 lordosis was measured using the Cobb method, which is defined as the angle between the inferior endplates of C2 and C7.

Clinical Assessment

The Modified Japanese Orthopedic Association (mJOA) score was calculated preoperatively and postoperatively to better understand the patient's clinical condition. The preoperative and final postoperative values were compared for analysis based on the follow-up period.

Statistical Analysis

Descriptive statistics for continuous variables included the mean, standard deviation, median, and minimum and maximum values. For categorical variables, counts and percentages were calculated. The normal distribution of the data was assessed using the Shapiro–Wilk test. The Wilcoxon test was used to compare preoperative and postoperative measurements. For continuous data with a normal distribution, one-way analysis of variance was used, whereas Kruskal–Wallis analysis of variance was used for nonnormally distributed data. For nominal variable group comparisons, the Chi-square or Fisher's exact test was used. The multivariate logistic regression analysis included independent variables considered effective, relevant factors on ISI recovery and significant in univariate analyses. For statistical analysis, IBM SPSS version 20 (Chicago, Illinois) was used, with a significance level of $p < 0.05$ considered.

Ethics Statement

This study has been carried out in accordance with the principles of the Declaration of Helsinki and approved by the Clinical Research Ethics Committee of Marmara University Faculty of Medicine with decision number 09.2023.479.

Informed consent was obtained from all individual participants included in the study.

■ RESULTS

The study included 123 patients (41 females and 82 males). The mean age was 65.42 ± 10.09 yr. The entire study group had a mean follow-up period of 35.47 ± 18.11 months. The mean duration of symptoms was 29 months, and the mean BMI was 28.23 ± 3.86 . The patients' smoking status and comorbidities, such as diabetes, CAD, and HT, are shown

Table I: Patients' Characteristics

N = 123	Mean ± SD Median (min-max)	
	Age (yr)	65.42 ± 10.09 66 (42-90)
Body mass index (BMI)	28.23 ± 3.86 28 (18-36)	
Follow-up period (months)	35.47 ± 18.11 32 (12-96)	
Level of decompression	3.28 ± 1.50 3 (2-13)	
Fusion level	4.10 ± 0.87 4 (3-8)	
	n	%
Gender		
Female	32	26.0
Male	91	74.0
Smoking		
No	65	52.8
Yes	58	47.2
Diabetes		
No	75	61.0
Yes	48	39.0
Hypertension		
No	57	46.3
Yes	66	53.7
Coronary artery disease		
No	79	64.2
Yes	44	35.8

Note. **max:** maximum; **min:** minimum; **n:** number; **SD:** standard deviation.

in Table I. The patients had an average level of posterior decompression (laminectomy) of 3 and a fusion level of 4 (Table I). The ISI values of patients are presented in Table II. Accordingly, the ISI improved in 39 patients (31.7%), remained constant in 53 patients (latent, 43.1%), and worsened in 31 patients (25.2%) (Figures 1-3).

Postoperative C2-7 lordosis angle showed a significant improvement compared with the preoperative values across all study participants, with $12.24^\circ \pm 6.21^\circ$ and $10.74^\circ \pm 6.57^\circ$, respectively ($p < 0.001$). However, no statistically significant difference in cSVA was observed between the preoperative and postoperative values ($p = 0.127$). Postoperative mJOA scores assessing clinical conditions were significantly higher than preoperative mJOA scores, with values of 12.75 ± 3.02 and 10.87 ± 2.96 , respectively ($p < 0.001$, Table III).

There were no significant differences in terms of age, gender, BMI, decompression level, and fusion level between patients with ISI improvement, latent ISI, and ISI worsening (Table IV). However, there was a significant difference in follow-up periods between patients with ISI improvement and those with worsening ISI ($p < 0.01$).

Symptom duration differed significantly between patients with ISI improvement, those with latent ISI, and those with worsening ISI ($p < 0.001$). Patients with ISI improvement had

Table II: Distribution of ISI Improvement in Patients

ISI status	N	%
Improved	39	31.7
Latent	53	43.1
Worsened	31	25.2

ISI: Increased signal intensity, N: number.

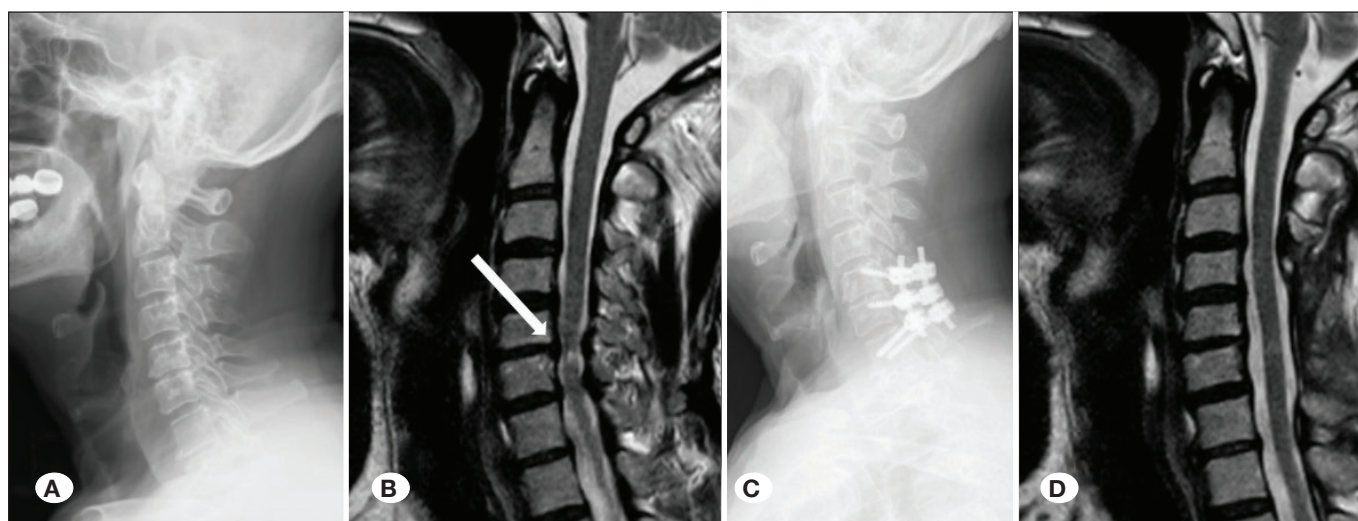


Figure 1: Images of a patient with ISI recovery are shown. **A)** Preoperative lateral cervical graph. **B)** The white arrow shows the hyperintense signal change in the spinal cord on the sagittal T2WI. **C)** Posterior fusion and instrumentation are observed on the postoperative lateral cervical graph. **D)** The hyperintense lesion disappears in the sagittal MR section.

significantly shorter symptom duration than those with latent ISI and ISI worsening (18 months vs. 32 and 36 months, respectively). There was no statistically significant difference in symptom duration between the patients with latent ISI and those with worsening ISI (Table IV).

There were no significant differences in terms of smoking, comorbid HT, and CAD rates among patients with ISI improvement, latent ISI, and worsening ISI ($p > 0.05$). However, there are differences in the incidence of diabetes. The rate of diabetes was higher in patients with worsening ISI than in

those with latent ISI ($p = 0.009$). The other group comparisons revealed no significant differences.

Patients with worsening ISI had lower preoperative C2-7 lordosis values than those with improved and latent ISI ($7.96^\circ \pm 3.46^\circ$ vs. $13.34^\circ \pm 8.50^\circ$ and $10.44^\circ \pm 5.65^\circ$, respectively). Although the difference was insignificant compared with latent ISI, it was statistically significant compared with patients with ISI improvement ($p = 0.631$ and $p = 0.015$, respectively; Table IV).

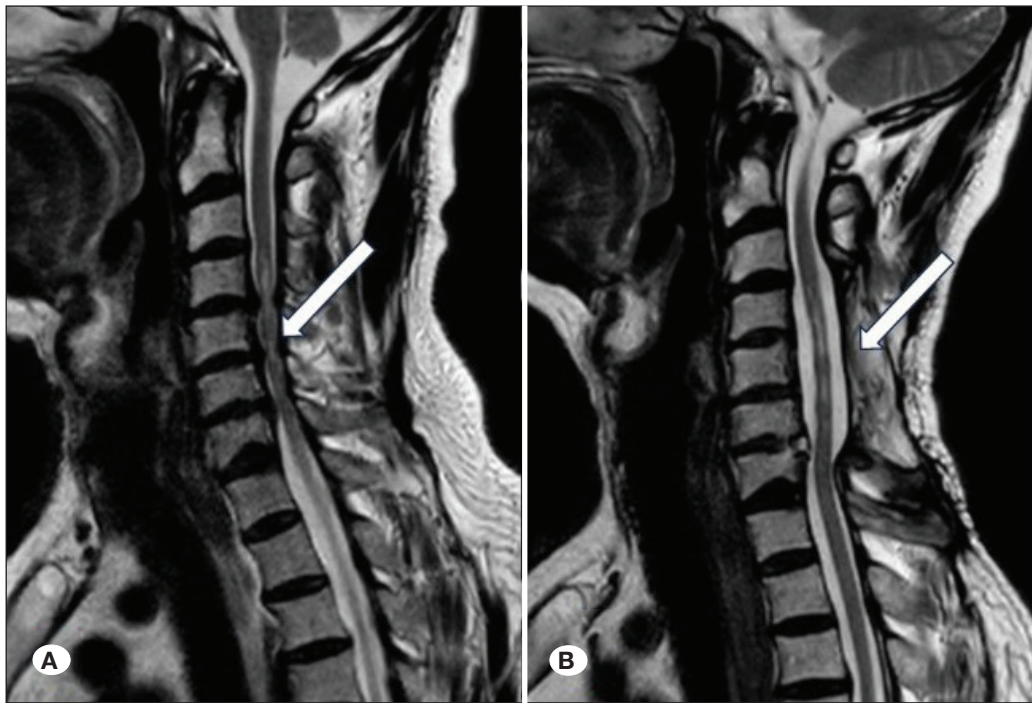


Figure 2: Example of ISI worsening in patient images. **A)** There was significant neural pressure at the C4–C7 level on MRI and slightly increased intensity in the medulla spinalis on preoperative cervical T2WI MRI. **B)** Following posterior decompression and fusion, the white arrow indicates an increase in intensity at the spinal cord on sagittal T2WI MRI.

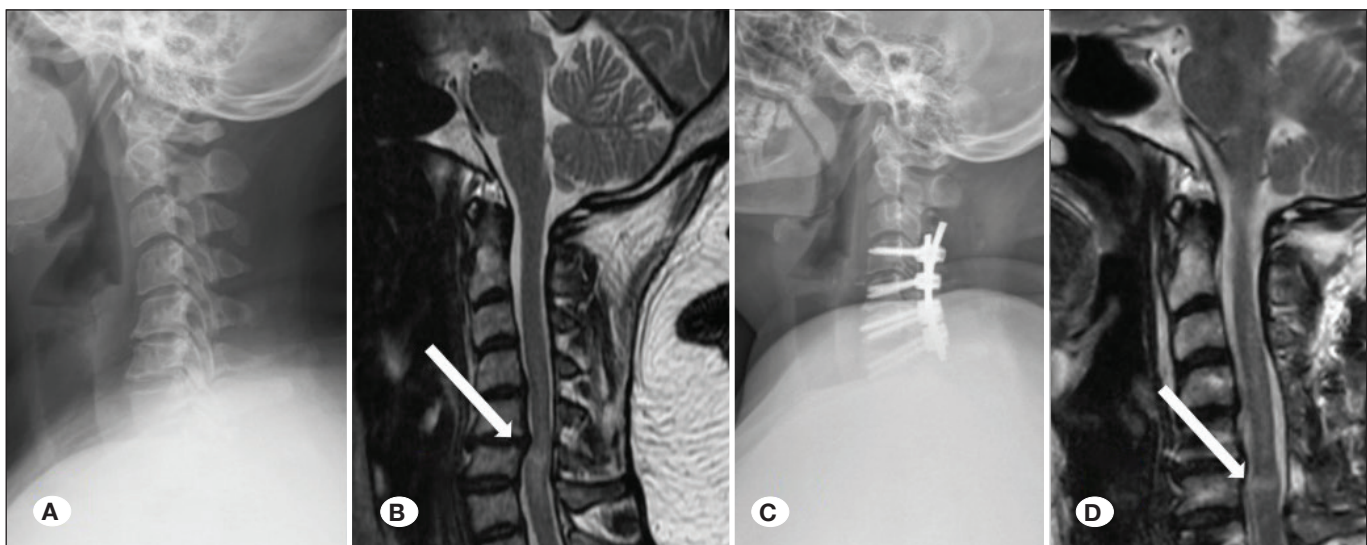


Figure 3: Patient images without ISI (latent) changes. **A)** Preoperative lateral cervical graph. **B)** White arrow indicates increased intensity of the medulla spinalis. **C)** Metallic surgical instruments applied to C4-7 levels are shown. **D)** On sagittal T2WI MRI, the white arrow shows an increase in intramedullary intensity, remaining latent.

Table III: Comparison of Preoperative and Postoperative Data of Patients

	Preoperative	Postoperative	p-value
	Mean ± SD Median (min-max)	Mean ± SD Median (min-max)	
C2-7 lordosis	10.74 ± 6.57 9.4 (-4.0)-(34.5)	12.24 ± 6.21 11 (2.0-36.7)	<0.001 ^a
cSVA (mm)	14.53 ± 10.29 14 (0-53.2)	13.64 ± 9.66 13 (0-42.4)	0.127 ^a
mJOA score	10.87 ± 2.96 11 (4-17)	12.75 ± 3.02 13 (0-17)	<0.001 ^a
ISI	1 (0-2)	1 (0-2)	0.339 ^a

^aWilcoxon test. **cSVA:** Cervical sagittal vertical axis, **mJOA:** The modified Japanese orthopedic association score, **ISI:** Increased signal intensity.

Table IV: Comparison of Patients Regarding ISI Status

	ISI improved	Latent	Worsened	p-value
	Mean ± SD Median (min-max)	Mean ± SD Median (min-max)	Mean ± SD Median (min-max)	
Age	66.79 ± 11.60 69 (42-90)	65.25 ± 9.64 66 (48-84)	64.00 ± 8.84 65 (45-82)	0.810 ^c
BMI	28.30 ± 4.21 29 (18-35)	28.23 ± 4.26 28 (19-36)	28.12 ± 256 28 (22-34)	0.803 ^c
Follow-up period (months)	31.23 ± 21.84 27 (12-86)	35.92 ± 18.53 33 (12-93)	40.03 ± 9.43 41 (23-60)	0.003 ^b
Duration of symptoms (months)	18.90 ± 38.55 10 (1-240)	32.51 ± 24.12 29 (2-120)	36.06 ± 15.09 36 (12-84)	<0.001 ^b
Level of decompression	3.18 ± 0.88 3 (2-5)	3.32 ± 1.60 3 (2-13)	3.32 ± 1.92 3 (2-13)	0.860 ^b
Fusion level	4.15 ± 1.01 4 (3-8)	4.00 ± 0.73 4 (3-6)	4.19 ± 0.91 4 (3-6)	0.685 ^b
Preoperative C2-C7 lordosis	13.34 ± 8.50 12.93 (1.8-34.5)	10.44 ± 5.65 9.40 (-4)-(22.9)	7.96 ± 3.46 8 (1-15)	0.020 ^b
Postoperative C2-C7 lordosis	14.69 ± 6.87 15.6 (4.2-33.4)	11.98 ± 6.40 10.7 (2.0-36.7)	9.54 ± 3.34 9 (3.0-15.0)	0.003 ^b
Preoperative cSVA (mm)	18.87 ± 8.00 18.07 (1.9-36.0)	16.34 ± 11.10 16.80 (2-53.2)	5.96 ± 5.48 5 (0-25)	<0.001 ^b
Postoperative cSVA (mm)	18.56 ± 7.71 18.0 (2.1-38.4)	14.88 ± 10.03 12.7 (2.0-42.4)	5.33 ± 4.91 4 (0-22.0)	<0.001 ^b
Preoperative mJOA score	10.95 ± 3.56 11 (4-17)	11.26 ± 2.74 11 (6-17)	10.10 ± 2.38 10 (6-17)	0.193 ^b
Postoperative mJOA score	12.87 ± 3.48 13 (0-17)	12.89 ± 3.29 13 (0-17)	12.35 ± 1.70 12 (10-17)	0.403 ^b
Change (postoperative-preoperative) C2-C7 lordosis ^o	1.35 ± 7.67 2.4 (-18.60)-(14.80)	1.54 ± 6.15 1.40 (-20.87)-(20.10)	1.63 ± 2.39 1.0 (-1.0)-(10.0)	0.711 ^b

Table IV: Cont.

	ISI improved		Latent		Worsened		p-value
	Mean ± SD Median (min-max)		Mean ± SD Median (min-max)		Mean ± SD Median (min-max)		
Change (postoperative-preoperative) cSVA	-0.30 ± 6.60 -1.0 (-14.10)-(18.60)		-1.45 ± 8.78 -1.0 (-26.63)-(22.72)		-0.62 ± 2.76 0 (-8.0)-(4.0)		0.956 ^b
Change (postoperative-preoperative) mJOA	1.92 ± 3.19 2.0 (-14)-(6.0)		1.62 ± 2.65 2.0 (-12)-(9)		2.25 ± 1.76 2.0 (0)-(6)		0.165 ^b
	n	%	n	%	n	%	
Gender							
Female	11	28.2	14	26.4	7	22.6	0.916 ^a
Male	28	71.8	39	73.6	24	77.4	
Smoking							
No	15	38.5	30	56.6	20	64.5	0.073 ^a
Yes	24	61.5	23	43.4	11	35.5	
Diabetes							
No	22	56.4	39	73.6	14	45.2	0.028 ^a
Yes	17	43.6	14	26.4	17	54.8	
Hypertension							
No	15	38.5	29	54.7	13	41.9	0.258 ^a
Yes	24	61.5	24	45.3	18	58.1	
Coronary artery disease							
No	24	61.5	38	71.7	17	54.8	0.273 ^a
Yes	15	38.5	15	28.3	14	45.2	

^aChi-square test. ^bKruskal-Wallis test. ^cANOVA test. **BMI**: Body mass index, **cSVA**: Cervical sagittal vertical axis, **mJOA**: The modified Japanese orthopedic association score, **ISI**: Increased signal intensity.

Patients with ISI improvement had the highest postoperative CL values (14.69° ± 6.87°). This value differed significantly from that of patients with a worsening ISI (p=0.002).

There was a significant difference in the preoperative cSVA values (p<0.001). Patients with worsening ISI showed lower preoperative cSVA values than those with latent ISI and those with improved ISI (5.96 ± 5.48 mm vs. 16.34 ± 11.10 and 18.87 ± 8.00 mm, respectively, Table IV). Similarly, patients with worsening ISI had the lowest postoperative cSVA values.

The multivariate logistic regression analysis indicated that symptom duration, preoperative C2-C7 lordosis, and preoperative cSVA variables were effective factors in ISI recovery. A 1-month increase in symptom duration results in a 1.029-fold decrease in ISI recovery (p<0.05). A single 1° increase in preoperative C2-C7 lordosis value leads to a 1.075-fold increase in ISI recovery (p<0.05), whereas a 1-mm increase in preoperative CSVA value causes a 1.055-fold increase in ISI recovery (p<0.05, Table V).

Comparisons of ISI revealed no statistically significant differences in terms of preoperative JOA, postoperative JOA, C2-7 lordosis change, cSVA change, and mJOA change (p>0.05, Table IV).

DISCUSSION

Cervical spondylotic myelopathy is the most common cause of spinal cord dysfunction (24). MRI plays a crucial role in the diagnostic processes and clinical examinations. Sagittal and axial MRIs help examine signal changes within the spinal cord and assess bone and soft tissues (1,5,19). Takahashi et al. first reported that high-intensity lesions on T2WI MRI in CSM develop due to chronic compression (14). The pathophysiology involves myelomalacia and cord gliosis. Many studies have investigated the effects of intramedullary signal changes on treatment strategies and prognosis. While intramedullary signal changes have been widely studied in CSM treatment, most of these studies have focused on patients treated with

Table V: Multivariate Logistic Regression Analysis for Factors Affecting ISI Recovery

Variate	Regression Coefficient (SE)	Adj. OR	95 % CI		p-value
Age	0.030 (0.021)	1.031	0.988	1.071	0.158
Duration of symptom	-0.029 (0.013)	1.029	1.004	1.055	0.022
DM	0.175 (0.452)	1.191	0.492	2.887	0.698
Preoperative C2- C7 Lordosis	0.073 (0.032)	1.075	1.009	1.146	0.025
Preoperative cSVA	0.054 (0.023)	1.055	1.009	1.103	0.017

Adj. OR: Adjusted odds ratio, **CI:** Confidence Interval, **OR:** Odds Ratio, **SE:** Standard Error.

either anterior cervical surgery or posterior laminoplasty (5-7,15,18-20,23,24). Although some studies have described results for both anterior and posterior approaches (1), no study has explicitly evaluated the outcomes of isolated posterior decompression and fusion. In this context, we were interested in the outcomes of patients who underwent posterior decompression and fusion. This treatment strategy effectively addressed static and dynamic pathological factors with instability-related issues.

The presence and severity of preoperative symptoms give an idea of how far we can go in the treatment of CSM. It has been reported in previous publications that clinical results worsen in CSM treatment, especially as the duration of symptoms increases. In Zhang et al's study, 73 patients were evaluated and reported better surgical outcomes in patients with a low signal intensity rate and a short duration of disease (24). In another wide-ranging study, Tetrault et.al reviewed 91 articles and evaluated the most important outcome predictor as the severity and duration of symptoms (16). A similar conclusion was reached in Yoon et al's study published as systematic review, which found that poorer clinical neurological outcomes after surgery were associated with increased severity and duration of symptoms (21). In the study of Machino et al, the duration of symptoms of patients with ISI recovery in the postoperative process was found to be shorter, although it was not statistically significant (12.6 ± 23.0 months) (7). In our study, the symptom duration of patients with ISI recovery was found to be shorter than those who remained latent and worsened (average of 18 months, $p < 0.001$). In this context, we think that the data we have obtained are in parallel with the literature.

This study examined the correlation between ISI changes and the JOA test results and found no significant impact of ISI improvement on clinical outcomes ($p > 0.05$). The literature contains a variety of viewpoints on this subject. While some authors found that ISI improvement positively affects clinical outcomes, others indicated no change (10,13,22). The recuperative potential of the spinal cord is reduced in cases with high signal intensity, whereas patients with moderate-intensity increases have a better potential for recovery (8). Intramedullary edema or swelling causes signal changes on magnetic resonance T2WI compared to other areas (11). The clinical implications of histopathological changes in the nerve tissue under compression can be observed in patients. The

clinical symptoms are caused by neurodegeneration and demyelination. Cystic necrosis can occur in advanced cases due to progressive neuronal loss and parenchymal damage (11). However, radiological images and clinical symptoms may not always correlate. Although our study indicated that patients with ISI grade improvement had significantly improved mJOA scores, there was no statistically significant difference in patients with ISI worsening or latent ISI.

Patients with ISI improvement had higher preoperative and postoperative CL values. The lowest values were found in patients with worsening ISI. Although we were unable to show a statistically significant correlation between radiological and clinical improvement, we realized the importance of achieving stability and optimal lordosis in the cervical spine for patient comfort and quality of life. The effect of cervical spinal parameters on the prognosis of ISI is unknown, and there have been few studies on this subject. Mohanty et al. evaluated the relationship between preoperative cervical spinal alignment and T2 hyperintensity and myelopathy in 124 patients and found that ISI changed with SVA (9). They found that patients with kyphotic curvature and high SVA had more MR signal abnormalities than those with lordotic postures. Shamji et al. investigated the effect of cervical alignment on neurological recovery and found that patients with preoperative lordotic alignment performed better than those with kyphotic alignment (12). In a review study, Zileli et al. reported that patients with abnormal cervical spinal sagittal parameters had poorer clinical recovery postoperatively, whereas patients with preoperative lordotic alignment had better results (26). In our study, we performed logistic regression analysis and found that preoperative 1° lordosis increase was positively correlated with ISI recovery. We achieved a similar result with SVA. We found a proportional relationship between ISI recovery and increasing preoperative cSVA by 1 mm. Although increased cSVA may be considered initially negative, the mean preoperative cSVA value in the study group (mean, 14.53 ± 10.29 mm) was within normal range. Therefore, the relationship between increased cSVA and ISI recovery should be studied in a larger cohort group. Although the effect of cervical spinal parameters on ISI prognosis is unknown, we believe the effect of preoperative CL on ISI recovery observed in this study is useful.

This study has several limitations. Due to challenges in acquiring patient data during the COVID-19 pandemic and

subsequent major earthquake in southern Turkey, the number of patients who participated in the study was limited. The retrospective design of the study, absence of T1WI assessment for ISI, reliance only on mJOA scoring for clinical evaluation, lack of global spinal parameters accompanying radiological parameters, and mid-term follow-up duration are limitations. However, the strength of this multicenter study lies in it being the first to evaluate the outcomes of patients who underwent surgery using a specific surgical technique in a specific patient group.

CONCLUSION

Symptom duration and preoperative and postoperative CL values affect ISI improvement in patients with cervical posterior decompression and fusion for CSM. Although our study did not find a correlation between the ISI and clinical improvement, a more extensive study with more significant participation and use of quality-of-life scores yielded more objective results.

AUTHORSHIP CONTRIBUTION

Study conception and design: SKO, DK, AO, FH

Data collection: SKO, DK, AO, FH

Analysis and interpretation of results: SKO, DK, AO, FH

Draft manuscript preparation: SKO, FH

Critical revision of the article: SKO, YG, ZB, MO, MS, FH, CK, DK, EK, HK, KO, TE, MYA, OA, MS, AO, SD, TO, AFO

All authors (SKO, YG, ZB, MO, MS, FH, CK, DK, EK, HK, KO, TE, MYA, OA, MS, AO, SD, TO, AFO) reviewed the results and approved the final version of the manuscript.

REFERENCES

- Arvin B, Kalsi-Ryan S, Karpova A, Mercier D, Furlan J, Massicotte E, Fehlings M: Postoperative magnetic resonance imaging can predict neurological recovery after surgery for cervical spondylotic myelopathy: A prospective study with blinded assessments. *Neurosurgery* 69:362-368, 2011. <https://doi.org/10.1227/NEU.0b013e31821a418c>
- Chen H, Pan J, Nisar M, Zeng H, Dai L, Lou C, Zhu C, Dai B, Xiang G: The value of preoperative magnetic resonance imaging in predicting postoperative recovery in patients with cervical spondylosis myelopathy: A meta-analysis. *Clinics* 71:179-184, 2016. [https://doi.org/10.6061/clinics/2016\(03\)10](https://doi.org/10.6061/clinics/2016(03)10)
- Fehlings MG, Tetreault LA, Wilson JR, Skelly AC: Cervical spondylotic myelopathy: Current state of the art and future directions. *Spine* 38:S1-8, 2013. <https://doi.org/10.1097/BRS.0b013e3182a7e9e0>
- Fernández de Rota JJ, Meschian S, Fernández de Rota A, Urbano V, Baron M: Cervical spondylotic myelopathy due to chronic compression: The role of signal intensity changes in magnetic resonance images. *J Neurosurg Spine* 6:17-22, 2007. <https://doi.org/10.3171/spi.2007.6.1.4>
- Li FN, Li ZH, Huang X, Yu S, Zhang F, Chen Z, Shen H, Cai B, Hou T: The treatment of mild cervical spondylotic myelopathy with increased signal intensity on T2-weighted magnetic resonance imaging. *Spinal Cord* 52:348-353, 2014. <https://doi.org/10.1038/sc.2014.11>
- Machino M, Ando K, Kobayashi K, Ito K, Tsushima M, Morozumi M, Tanaka S, Ota K, Ito K, Kato F, Ishiguro N, Imagama S: Alterations in intramedullary T2-weighted increased signal intensity following laminoplasty in cervical spondylotic myelopathy patients: Comparison between pre- and postoperative magnetic resonance images. *Spine (Phila Pa 1976)* 43:1595-1601, 2018. <https://doi.org/10.1097/BRS.0000000000002674>
- Machino M, Ando K, Kobayashi K, Ota K, Morozumi M, Tanaka S, Ito K, Kato F, Ishiguro N: Postoperative resolution of MR T2 increased signal intensity in cervical spondylotic myelopathy: The impact of signal change resolution on the outcomes. *Spine* 44:E1241-E1247, 2019. <https://doi.org/10.1097/BRS.0000000000003128>
- Machino M, Imagama S, Ando K, Kobayashi K, Ito K, Tsushima M, Matsumoto A, Morozumi M, Tanaka S, Ito K, Kato F, Nishida Y, Ishiguro N: Image diagnostic classification of magnetic resonance T2 increased signal intensity in cervical spondylotic myelopathy: Clinical evaluation using quantitative and objective assessment. *Spine* 43:420-426, 2018. <https://doi.org/10.1097/BRS.0000000000002328>
- Mohanty C, Massicotte EM, Fehlings MG, Shamji MF: Association of preoperative cervical spine alignment with spinal cord magnetic resonance imaging hyperintensity and myelopathy severity: Analysis of a series of 124 cases. *Spine* 40:11-16, 2015. <https://doi.org/10.1097/BRS.0000000000000670>
- Morio Y, Teshima R, Nagashima H, Nawata K, Yamasaki D, Nanjo Y: Correlation between operative outcomes of cervical compression myelopathy and mri of the spinal cord. *Spine* 26:1238-1245, 2001. <https://doi.org/10.1097/00007632-200106010-00012>
- Ohshio I, Hatayama A, Kaneda K, Takahara M, Nagashima K: Correlation between histopathologic features and magnetic resonance images of spinal cord lesions. *Spine* 18:1140-1149, 1993. <https://doi.org/10.1097/00007632-199307000-00005>
- Shamji MF, Mohanty C, Massicotte EM, Fehlings MG: The association of cervical spine alignment with neurologic recovery in a prospective cohort of patients with surgical myelopathy: Analysis of a series of 124 cases. *World Neurosurg* 86:112-119, 2016. <https://doi.org/10.1016/j.wneu.2015.09.044>
- Suri A, Chhabra RPS, Mehta VS, Gaikwad S, Pandey RM: Effect of intramedullary signal changes on the surgical outcome of patients with cervical spondylotic myelopathy. *Spine Journal* 3:33-45, 2003. [https://doi.org/10.1016/S1529-9430\(02\)00448-5](https://doi.org/10.1016/S1529-9430(02)00448-5)
- Takahashi M, Sakamoto Y, Miyawaki M, Bussaka H: Increased MR signal intensity secondary to chronic cervical cord compression. *Neuroradiology* 29:550-556, 1987. <https://doi.org/10.1007/BF00350439>
- Tetreault LA, Dettori JR, Wilson JR, Singh A, Nouri A, Fehlings M, Brodt E, Jacobs W: Systematic review of magnetic resonance imaging characteristics that affect treatment decision making and predict clinical outcome in patients with cervical spondylotic myelopathy. *Spine (Phila Pa 1976)* 38(22 Suppl 1):S89-S110, 2013. <https://doi.org/10.1097/BRS.0b013e3182a7eae0>

16. Tetreault LA, Karpova A, Fehlings MG: Predictors of outcome in patients with degenerative cervical spondylotic myelopathy undergoing surgical treatment: Results of a systematic review. *Eur Spine J* 24:236-251, 2015. <https://doi.org/10.1007/s00586-013-2658-z>
17. Uchida K, Nakajima H, Takeura N, Yayama T, Guerrero A, Yoshida A, Sakamoto T, Honjoh K, Baba T: Prognostic value of changes in spinal cord signal intensity on magnetic resonance imaging in patients with cervical compressive myelopathy. *Spine J* 14:1601-1610, 2014. <https://doi.org/10.1016/j.spinee.2013.09.038>
18. Wei L, Cao P, Xu C, Chen H, Wang X, Tian Y, Yuan W: The relationship between preoperative factors and the presence of intramedullary increased signal intensity on T2-weighted magnetic resonance imaging in patients with cervical spondylotic myelopathy. *Clin Neurol Neurosurg* 178:1-6, 2019. <https://doi.org/10.1016/j.clineuro.2019.01.006>
19. Wei L, Cao P, Xu C, Hu B, Tian Y, Yuan W: Clinical and radiologic results of anterior cervical discectomy and fusion for cervical spondylotic myelopathy in elderly patients with T2-weighted increased signal intensity. *World Neurosurg* 112:e520-e526, 2018. <https://doi.org/10.1016/j.wneu.2018.01.071>
20. Yagi M, Ninomiya K, Kihara M, Horiuchi Y: Long-term surgical outcome and risk factors in patients with cervical myelopathy and a change in signal intensity of intramedullary spinal cord on magnetic resonance imaging: Clinical article. *J Neurosurg Spine* 12:59-65, 2010. <https://doi.org/10.3171/2009.5.SPINE08940>
21. Yoon ST, Raich A, Hashimoto RE, Riew K, Shaffrey C, Rhee J, Tetrault L, Skelly A, Fehlings M: Predictive factors affecting outcome after cervical laminoplasty. *Spine (Phila Pa 1976)*. 38:S232-S252, 2013. <https://doi.org/10.1097/BRS.0b013e3182a7eb55>
22. Yukawa Y, Kato F, Ito K, Horie Y, Hida T, Machino M, Ito Z, Matsuyama Y: Postoperative changes in spinal cord signal intensity in patients with cervical compression myelopathy: Comparison between preoperative and postoperative magnetic resonance images. *J Neurosurg Spine* 8:524-528, 2008. <https://doi.org/10.3171/SPI/2008/8/6/524>
23. Yukawa Y, Kato F, Yoshihara H, Yanase M, Ito K: MR T2 image classification in cervical compression myelopathy: Predictor of surgical outcomes. *Spine (Phila Pa 1976)* 32:1675-1678, 2007. <https://doi.org/10.1097/BRS.0b013e318074d62e>
24. Zhang YZ, Shen Y, Wang LF, Ding WY, Xu JX, He J: Magnetic resonance T2 image signal intensity ratio and clinical manifestation predict prognosis after surgical intervention for cervical spondylotic myelopathy. *Spine* 35: E396-399, 2010. <https://doi.org/10.1097/BRS.0b013e3181c6dbc4>
25. Zileli M, Borkar SA, Sinha S, Reinas R, Alves O, Kim S, Pawar S, Murali B, Parthiban J: Cervical spondylotic myelopathy: natural course and the value of diagnostic techniques -WFNS spine committee recommendations. *Neurospine* 16:386-402, 2019. <https://doi.org/10.14245/ns.1938240.120>
26. Zileli M, Maheshwari S, Kale SS, Garg K, Menon SK, Parthiban J: Outcome measures and variables affecting prognosis of cervical spondylotic myelopathy: WFNS spine committee recommendations. *Neurospine* 16:435-447, 2019. <https://doi.org/10.14245/ns.1938196.098>