



Mechanical Thrombectomy for Acute Cardiogenic Internal Carotid Artery Occlusion with Cross-Flow through the Communicating Artery

Seigo KIMURA¹, Ryokichi YAGI², Fumihisa KISHI¹, Ryo TAMAKI³, Daiji OGAWA¹, Keiichi YAMADA¹, Hirokatsu TANIGUCHI¹, Masahiko WANIBUCHI²

¹Kouzenkai Yagi Neurosurgical Hospital, Osaka, Japan

²Osaka Medical and Pharmaceutical University Hospital, Department of Neurosurgery and Endovascular Therapy, Takatsuki, Osaka, Japan

³Osaka General Medical Center, Department of Neurosurgery, Osaka, Japan

Corresponding author: Seigo KIMURA ✉ seigo.kimura@ompu.ac.jp

ABSTRACT

AIM: To report mechanical thrombectomy (MT) for internal carotid artery (ICA) occlusion with cross-flow through the communicating artery (“with” group), and to compare it with ICA or middle cerebral artery occlusion without cross-flow (“without” group).

MATERIAL and METHODS: This study included 10 and 57 cases of the “with” and “without” groups, respectively. Cases analyzed by rapid processing of perfusion and diffusion (RAPID) since October 2020 were included.

RESULTS: Puncture-to-reperfusion time was 78.5 and 39 min ($p=0.0155$), the National Institutes of Health Stroke Scale score at discharge was 10.5 and 4 ($p=0.0166$), decline from pre to post Diffusion-Weighted Image-Alberta Stroke Program Early computed tomography (CT) Score was 0.5 and 0 ($p=0.0495$), and the modified Rankin Scale score at 90 days was 4 and 2 ($p=0.0195$) in the “with” and “without” groups, respectively. Furthermore, Tmax values of >6 s (50 cc vs. 164 cc; $p=0.0277$) and Tmax >4 s/Tmax > 6 s ratio (3.23 vs. 1.55) ($p=0.0074$) were significantly different between the “with” and “without” groups.

CONCLUSION: The “with” group may have been affected by the longer treatment time and being at high risk of distal migration of thrombus due to poor prognosis. Although the region with a Tmax of >6 s tends to be small in patients of the “with” group, it indicates a low-perfusion state that can lead to cerebral infarction, and MT should be performed.

KEYWORDS: Anterior communicating artery, Cross-flow, Cardiogenic internal carotid artery occlusion, Mechanical thrombectomy

ABBREVIATIONS: Acom: Anterior communicating artery, AF: Atrial fibrillation, DWI: Diffusion-weighted imaging, **DWI-ASPECTS:** Diffusion-Weighted Image-Alberta Stroke Program Early CT Score, ICA: Internal carotid artery, MCA: Middle cerebral artery, MeVO: medium vessel occlusion, MRA: Magnetic resonance angiography, mRS: Modified Rankin Scale, MT: Mechanical thrombectomy, NIHSS: National Institution of Health Stroke Scale, PCA: Posterior cerebral artery, RAPID: Rapid processing of perfusion and diffusion, rt-PA: Recombinant tissue plasminogen activator, TICI: Thrombolysis in cerebral infarction, Tmax: Time-to-maximum

Seigo KIMURA : 0000-0001-5318-5588
Ryokichi YAGI : 0000-0001-9949-4853
Fumihisa KISHI : 0000-0001-7073-8439

Ryo TAMAKI : 0000-0001-5479-9629
Daiji OGAWA : 0009-0009-6555-602X
Keiichi YAMADA : 0009-0004-7531-1388

Hirokatsu TANIGUCHI : 0009-0002-7560-9147
Masahiko WANIBUCHI : 0000-0002-1856-7123

INTRODUCTION

In recent years, mechanical thrombectomy (MT) of the internal carotid artery (ICA) and middle cerebral artery (MCA) for acute M1 occlusion of the main artery of the anterior circulation has become a common procedure (4). Additionally, there have been reports of MT for medium vessel occlusion (MeVO) beyond M2 of MCA (13,16), and the effectiveness of MT for many acute anterior circulation artery occlusions has been established. In cases of acute cardiogenic ICA occlusion, cross-flow through the anterior communicating artery (Acom) or posterior communicating artery (Pcom) may perfuse the diseased side of the MCA region when only the proximal side of the ICA is acutely occluded. However, only a few studies have reported on MT being performed for such cases. In cases of ICA occlusion with Acom or Pcom cross-flow (“with” group), cerebral blood flow is preserved due to the collateral flow of cross-flow, but the thrombus may migrate distally and worsen symptoms. Additionally, MT may worsen cerebral infarction by obstructing the blood flow supplied by the cross-flow due to the distal migration of the thrombus. Thus, we are often faced with difficult treatment choices. Herein, we report MT performed on the patients in the “with” group and compare it to ICA or MCA occlusion without cross-flow supplying the diseased side of the MCA region (“without” group).

MATERIAL and METHODS

This study was approved by the local institutional ethical committee (Date: April 19, 2022; No: 2106).

Overall, 10 and 57 patients were included in the “with” and “without” groups, respectively, who were treated at our hospital between July 2015 and January 2023. Cases with modified Rankin Scale (mRS) of 4 or higher before onset were excluded. Cardiogenic cerebral embolism was judged as atrial fibrillation (AF) via electrocardiography. With or without AF, cardiogenic cerebral embolism was diagnosed when a red thrombus was retrieved, distal migration of a thrombus considered to be fragile was observed, no residual stenosis was observed after the occluded vessel recanalization, plasma brain natriuretic peptide level was high, and the ejection fraction on echocardiography was low. Confirmed diagnosis of the “with” group was made when acute ICA occlusion was observed in head magnetic resonance angiography (MRA) and cerebral angiography images, exhibiting the flow from the healthy side to the diseased side of the MCA region via Acom or Pcom. The “without” group was diagnosed when acute ICA top occlusion or M1 portion of MCA occlusion was observed on head MRA and cerebral angiography images. Some patients were analyzed by rapid processing of perfusion and diffusion (RAPID) (computed tomography [CT] and magnetic resonance [MR] perfusion) since its introduction in October 2020 (“with” group: 3 patients, “without” group: 19 patients). Minimal MR imaging (diffusion-weighted imaging [DWI]) and head and neck MRA were performed even when CT perfusion was performed. As in the DEFUSE3 trial,(1) cerebral blood flow of <30% in CT perfusion and an apparent diffusion coefficient of $<620 \times 10^{-6} \text{ mm}^2/\text{s}$ in MR perfusion were defined as the

ischemic core, Time-to-maximum (Tmax) >6 s was defined as the penumbra, and perfusion mismatch was analyzed. Mechanical thrombectomy was performed using an 8Fr or 9Fr balloon guiding catheter. The stent retriever alone or combined technique with a suction catheter was used, and the balloon of the balloon guiding catheter was inflated at the time of clot retrieval. The presence of AF, recombinant tissue plasminogen activator (rt-PA) administration, thrombolysis in cerebral infarction, onset-to-puncture time and puncture-to-reperfusion time were determined. Onset was defined as the last time the disease did not occur. The National Institutes of Health Stroke Scale (NIHSS) score at arrival and discharge, Diffusion-Weighted Image-Alberta Stroke Program Early CT Score (DWI-ASPECTS) at arrival and within 24 hours postoperatively, decline from pre to post DWI-ASPECTS, mRS scores before onset and 90 days later, and hemorrhagic complication were recorded.

Statistical Analysis

Statistical analyses were performed using the free statistical software EZR (version 1.61, Saitama Medical Center, Jichi Medical University, Saitama, Japan) (6). *P* values of <0.05 were considered to be indicative of statistically significant differences in the results of the Fisher exact test and Mann-Whitney *U*-test.

RESULTS

Summaries of the “with” and “without” groups are shown in Table I. There were 10 and 57 patients in the “with” and “without” groups, respectively. There were no significant differences (all *p* values ≥ 0.05) in terms of age (81 vs. 79 years), sex (male: 40% vs. 47.4%), percentage analyzed using RAPID (30% vs. 33.3%), AF prevalence (90% vs. 75.4%), and rt-PA administration rate (40% vs. 57.9%). In one case in the “with” group, MT was performed because the patient’s NIHSS worsened from 3 to 21 and the thrombus was observed to migrate to the distal part compared with the MRA before the deterioration. In the “without” group, ICA top occlusion was 26.3% and M1 occlusion was 73.7%. In “with” group, 90% had Acom cross-flow alone, 0% had Pcom cross-flow alone and 10% had both Acom and Pcom cross-flow. There were also no significant differences (all *p* values ≥ 0.05) in the recanalization rate of TICI2b-3 (90% vs. 100%), onset-to-puncture time (201.5 vs. 150), NIHSS score at arrival (18 vs. 15), preoperative DWI-ASPECTS (9.5 vs. 9), postoperative DWI-ASPECTS (7 vs. 8), mRS score before the onset (0 vs. 0), and hemorrhagic complication (0 vs. 2). The puncture-to-reperfusion time (78.5 vs. 39 min; *p*=0.0155), NIHSS score at discharge (10.5 vs. 4; *p*=0.0166), decline from pre to post DWI-ASPECTS (0.5 vs 0; *p*=0.0495), and mRS score at 90 days (4 vs. 2; *p*=0.0195) were significantly better in the “without” group than in the “with” group.

Patients analyzed by RAPID were included three in the “with” group and 19 “without” group, respectively. Two of the three patients in the “with” group (Cases 1 and 2) showed perfusion mismatch in the diseased MCA region (Figure 1A, B); the remaining patient (Case 3) (7) showed no mismatch in

Table I: Clinical Characteristics of “with” and “without” Groups

| | with group (n=10) | without group (n=57) | p-value |
|---|-------------------|----------------------|----------------|
| Age, median, years (IQR) | 81 (73-84) | 79 (70-86) | 0.986 |
| Male, n (%) | 4 (40) | 27 (47.4) | 0.742 |
| RAPID, n (%) | 3 (30) | 19 (33.3) | 1 |
| AF, n (%) | 9 (90) | 43 (75.4) | 0.436 |
| Side (left), n (%) | 6 (60) | 30 (52.6) | 0.742 |
| rt-PA, n (%) | 4 (40) | 33 (57.9) | 0.324 |
| Cross flow | | | |
| Acom only, n (%) | 9 (90) | 0 (0) | |
| Pcom only, n (%) | 0 (0) | 0 (0) | |
| Acom and Pcom, n (%) | 1 (10) | 0 (0) | |
| Llocation | | | |
| ICA, n (%) | 10 (100) | 15 (26.3) | |
| M1, n (%) | 0 (0) | 42 (73.7) | |
| TICI2b-3, n (%) | 9 (90) | 57 (100) | 0.149 |
| Median Onset-to-Puncture time, min (IQR) | 201.5 (105-282.3) | 150 (124-266.0) | 0.923 |
| Median Puncture-to-Reperfusion time, min (IQR) | 78.5 (44.5-102.0) | 39 (26-59) | 0.0155* |
| Median NIHSS at arrival (IQR) | 18 (15.3-20.8) | 15 (11-20) | 0.172 |
| Median NIHSS at discharge (IQR) | 10.5 (7.5-13.3) | 4 (2-9) | 0.0166* |
| Median pre DWI-ASPECTS, median (IQR) | 9.5 (7.5-10) | 9 (8-9) | 0.466 |
| Median post DWI-ASPECTS, median (IQR) | 7 (4.8-9.5) | 8 (7-11) | 0.194 |
| Median decline from pre to post DWI-ASPECTS (IQR) | 0.5 (0-7) | 0 (0-3) | 0.0495* |
| Median pre mRS (IQR) | 0 (0-2.8) | 0 (0-1) | 0.537 |
| Median post mRS (IQR) | 4 (2.5-5) | 2 (1-3) | 0.0195* |
| Hemorrhagic complications, n (%) | 0 (0) | 2 (3.5) | 1 |

*p values of <0.05 were considered statistically significant in the results of the Fisher exact test and Mann-Whitney U-test. **RAPID:** Rapid processing of perfusion and diffusion. **AF:** Atrial fibrillation. **rt-PA:** Recombinant tissue plasminogen activator. **Acom:** Anterior communicating artery. **Pcom:** Posterior communicating artery. **ICA:** Internal carotid artery. **TICI:** Thrombolysis in cerebral infarction. **NIHSS:** The National Institutes of Health Stroke Scale. **DWI-ASPECTS:** Diffusion-Weighted Image-Alberta Stroke program Early CT Score. **mRS:** Modified Rankin Scale.

the diseased MCA region; however, the fetal-type posterior cerebral artery (PCA) on the diseased side was occluded, resulting in a mismatch only in the PCA region on the diseased side (Figure 1C). In all three patients in the “with” group, few Tmax >6 s regions were observed in the MCA region on the diseased side, and there were many Tmax >4 s regions (Figure 1D, E, F). The head MRA of each of the three patients is shown in Figure 1G, H, I. 19 patients analyzed by RAPID in the “without” group each showed a perfusion mismatch in the diseased side of the MCA region. Three representative cases of ICA top occlusion (Figure 2A, B, C) and M1 occlusion (Figure 2D, E, F) are presented in this report. The diseased side of the MCA region in all patients tended to occupy most of the

Tmax >6 s regions (Figure 2G, H, I, J, K, L). The head MRA of each of the six patients is shown in Figure 2M, N, O, P, Q, R. No significant difference was found in the Tmax >4 s region between the “with” and “without” groups (166 cc vs. 244 cc; p=0.718). However, significant differences were observed in the Tmax >6 s region (50 cc vs. 164 cc; p=0.0277) and Tmax >4 s/Tmax >6 s regions (3.23 vs. 1.55; p=0.0074; Table II).

DISCUSSION

No significant differences in NIHSS scores or DWI-ASPECTS at arrival were found for the 10 and 57 patients in the “with” and “without” groups, respectively, regardless of whether or

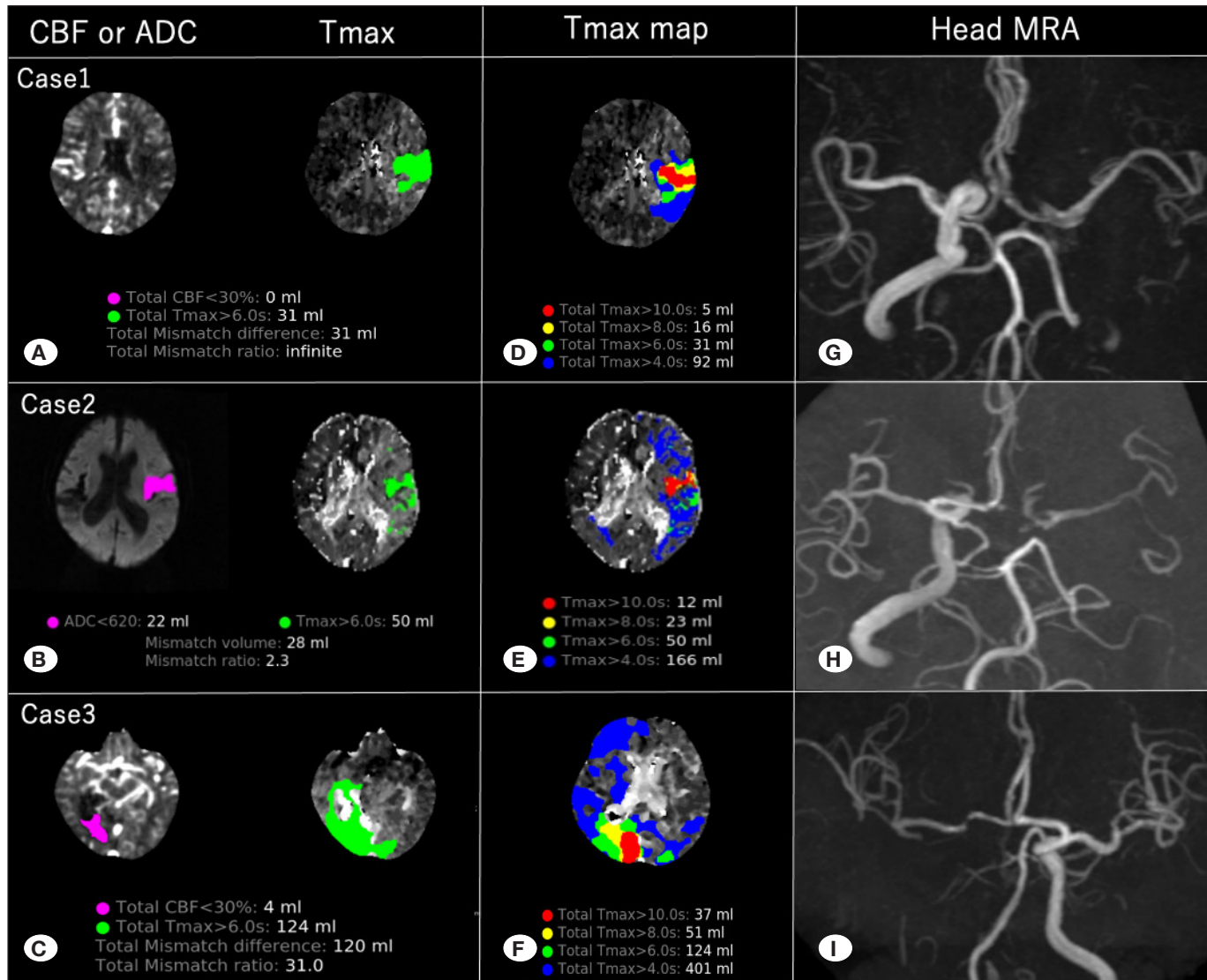


Figure 1: Two of the three patients in the “with” group (Cases 1 and 2) shows perfusion mismatch in the diseased middle cerebral artery (MCA) region (**A, B**), and the third patient (Case 3) did not show mismatch in the diseased MCA region. However, the fetal-type posterior cerebral artery (PCA) on the diseased side was occluded, which resulted in a mismatch only in the PCA region on the diseased side (**C**). In all three patients, there were few Tmax >6 s regions in the MCA region on the diseased side and many Tmax >4 s regions (**D, E, F**). The head magnetic resonance angiographic images of all three patients are shown (**G, H, I**). **CBF**: Cerebral blood flow. **ADC**: Apparent diffusion coefficient. **Tmax**: Time-to-maximum. **MRA**: Magnetic resonance angiography.

not the patients had cross-flow. The cross-flow did not appear to contribute to a lower NIHSS score at arrival or higher preoperative DWI-ASPECTS. Compensation via collateral flow occurs as atherosclerotic cerebral vascular stenosis progresses in the case of atherothrombotic brain infarction, which has been reported to maintain perfusion and stabilize cerebral blood flow (8-11,15). Therefore, it may be mild or asymptomatic, although the main vessel was eventually occluded. The occlusion of the ICA was not progressive but sudden in the “with” group, and compensation via cross-flow was considered inadequate, suggesting severe neurological deterioration in many patients. Zhao et al. examined the prognosis of patients after MT for ICA occlusion by classifying it according to the degree of circle of Willis development (18).

They revealed that patients with ICA occlusion but preserved Acom and Pcom with collateral flow had a significantly better prognosis and that good collateral flow may be a predictor of prognosis in patients with ICA occlusion after MT. Conversely, Seifert-Held et al. reported no significant difference in prognosis after MT regardless of circle of Willis development (14). Wu et al. evaluated the prognostic differences after MT for acute intracranial ICA occlusion due to the development of circle of Willis (17). The study showed that patients with collateral blood flow through circle of Willis at the onset of stroke exhibited significantly better prognosis than those without. However, the report included some patients who did not have cardiogenic ICA occlusion. Of those patients, the ones with AF exhibited poor outcome after MT. NIHSS scores

Table II: Comparison of “with” and “without” Groups Analyzed Using Rapid Processing of Perfusion and Diffusion

| | with group (n=3) | without group (n=19) | p-value |
|------------------------------------|------------------|----------------------|----------------|
| Tmax > 4 s, median, cc, (IQR) | 166 (129-283.5) | 244 (188-287.5) | 0.718 |
| Tmax > 6 s, median, cc, (IQR) | 50 (40.5-87) | 164 (135-196.5) | 0.0277* |
| Tmax > 4 s/Tmax >6 s, median (IQR) | 3.23 (3.10-3.28) | 1.55 (1.39-1.73) | 0.0074* |

* *p* values of <0.05 were considered statistically significant in the results of the Fisher exact test and Mann-Whitney U-test.

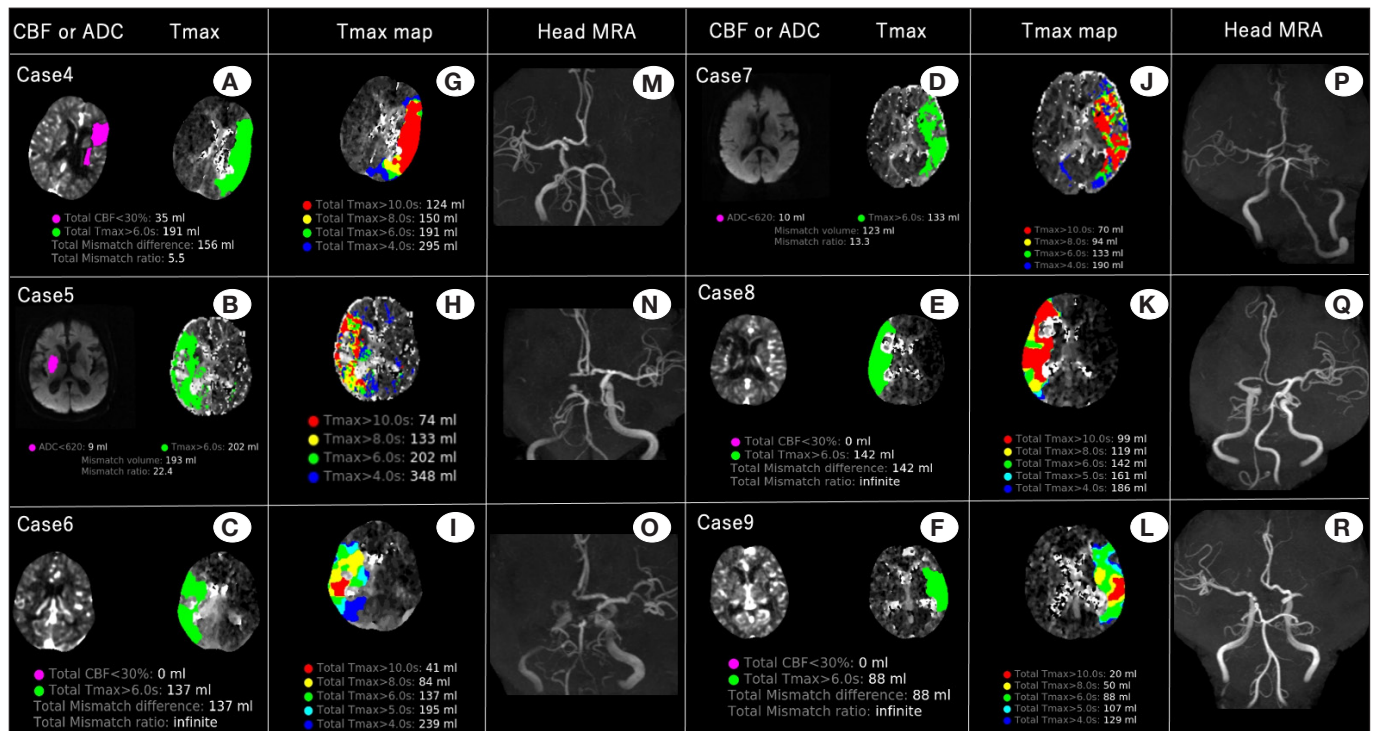


Figure 2: Three representative cases of internal carotid artery top occlusion (A, B, C), and M1 occlusion analyzed via rapid processing of perfusion and diffusion showed perfusion mismatch in the diseased side of the middle cerebral artery (MCA) region, respectively (D, E, F). The diseased side of the MCA region tends to occupy most of the Tmax >6 s regions (G, H, I, J, K, and L). The head magnetic resonance angiographic images of all six patients are shown (M, N, O, P, Q, R). CBF: Cerebral blood flow, ADC: Apparent diffusion coefficient, Tmax: Time-to-maximum, MRA: Magnetic resonance angiography.

at discharge and mRS scores at 90 days in our cases were significantly poorer in the “with” group than in the “without” group. One patient with both Acom and Pcom cross-flow in “with group” had a good prognosis with mRS score of 2 at 90 days. However, the other nine patients in the “with” group had Acom cross-flow alone, and only two of the nine cases had a good prognosis. MT for the “with” group may not lead to a good prognosis even when accompanied by cross-flow, particularly in cases with Acom cross-flow alone.

The puncture-to-reperfusion time was significantly longer in the “with” group than in the “without” group. The thrombus was large enough to occlude a large ICA, and the thrombus volume tended to be large. The thrombus was soft because of cardiogenic cerebral embolism and could migrate distally upon onset. Similarly, it could migrate distally if missed during MT. This might have required a longer treatment time.

The thrombus volume may be relatively small in the case of ICA top occlusion or M1 occlusion because arterial vessels become smaller in diameter at the point of transition from ICA to MCA. Therefore, the risk of massive thrombus migration was low, which may have contributed to the short treatment time. NIHSS scores at discharge and mRS scores at 90 days were significantly worse in the “with” group than those in the “without” group. Although there were no significant differences, “with” group tended to have higher pre DWI-ASPECTS and lower post DWI-ASPECTS than the “without” group. Decline from pre to post DWI-ASPECTS was significantly higher in the “with” group than the “without” group. A longer treatment time and higher risk of distal migration of thrombus was observed in the “with” group may have influenced the poor prognosis.

Amuluru et al. reported a case of MT through Acom from the contralateral ICA for tandem occlusion of the MCA

and ipsilateral ICA with a favorable outcome (2). MT was performed with trans-Acom via the contralateral ICA because atherosclerosis prevented reperfusion of the ICA. The “with” group of our study were at risk of distal migration of a large amount of thrombus in the ICA as a result of MT manipulation. Therefore, trans-Acom via the contralateral ICA approach may be a feasible method. However, in our patients, even if the lesion was tandem, it was a distal occlusion rather than an occlusion of M2, and even if it was a peripheral tandem lesion, the microcatheter would have to be guided distally if it was approached with trans-Acom; as a result, treatment could be quite difficult. Additionally, even if the MCA thrombus is successfully retrieved, an unstable thrombus may remain in the diseased ICA and later migrate distally. The neurological symptoms in the “with” group were observed despite the presence of Acom cross-flow, which may be caused by decreased cerebral blood flow on the diseased side as a result of ICA occlusion. Thrombi in the ICA should be retrieved even if patients are at risk for thrombus migration in the ICA.

We previously reported Case 3 as an example of a case in which the penumbra was thought to be present in a region with a $T_{max} \leq 6$ s based on RAPID analysis (7). The RAPID analysis in that report did not reveal a $T_{max} > 6$ s region defined as a penumbral region in the diseased side of the MCA region, indicating no penumbra in this region. However, the T_{max} map revealed a wide $T_{max} > 4$ s region on the diseased side of the MCA region, suggesting the possibility of acute ipsilateral ICA occlusion. Therefore, MT was performed for the ICA occlusion on the diseased side, and the ICA was reperfused. Analyzing not only the $T_{max} > 6$ s region to evaluate perfusion mismatch but also the $T_{max} > 4$ s region in the T_{max} map would be useful. The $T_{max} > 4$ s/ $T_{max} > 6$ s ratio was significantly higher in atherothrombotic brain infarction cases than in non-atherothrombotic brain infarction cases because of the development of collateral flow in cases of acute occlusion of intracranial arteries (5). The three patients in the “with” group analyzed by RAPID had significantly higher $T_{max} > 4$ s/ $T_{max} > 6$ s ratios than those of the 19 patients in the “without” group, which may be similar to the higher $T_{max} > 4$ s/ $T_{max} > 6$ s ratio in cases of atherothrombotic brain infarctions due to collateral flow development. The $T_{max} > 6$ s region was smaller and the $T_{max} > 4$ s region was larger in the “with” group than in the “without” group, which reduced perfusion mismatch. Furthermore, in the “with” group, as in case 3, there may be no $T_{max} > 6$ s region due to collateral flow. In such cases, RAPID analysis may show no evidence of perfusion mismatch in the MCA region, and the patient may be misjudged not to be performed the MT. However, the lesions were considered to be in a low-perfusion state that could lead to cerebral infarction, and MT was considered desirable.

As mentioned earlier, the thrombi of patients in the “with” group were massive, and there is a risk that the surgical procedure will cause distal migration of the thrombus. The collateral flow in the “with” group, which was barely preserved by the cross-flow, is lost, and the stroke may be worse than it was preoperatively, resulting in a poor prognosis. Chueh et

al. (3) reported that a direct aspiration first-pass technique and the use of a balloon guiding catheter during MT reduced the incidence of distal migration of thrombus. Ohshima and Miyachi reported that the use of a balloon guiding catheter to retrieve a thrombus into the aspiration catheter using a stent while the balloon is inflated (the aspiration catheter with proximal balloon technique) reduced the risk of intraoperative distal migration of thrombus (12). Until our retrospective study, we had not been aware of the risk of distal migration of large amounts of thrombus and the poor prognosis of the “with” group; therefore, we had not actively implemented the above innovations and tips in our daily clinical practice. Reducing the risk of distal migration of thrombus as much as possible using balloon guiding and aspiration catheters as described above is desirable when performing MT for “with” group. In doing so, we can achieve a good prognosis of “with” group hereafter. Additionally, favorable outcomes of endovascular treatment for MeVO have been reported in recent years owing to the miniaturization of MT devices (13,16). More attention should be paid to the distal migration of thrombus when performing MT for “with” group, with a focus on achieving the best possible recovery if distal migration does occur.

This study has several limitations. This was a single-center retrospective study with a small number of patients, and the results in other institutions may vary depending on the choice of MT device and the skill of the surgeon. Because of the infrequency with which we experience “with” group in our daily clinical practice, the number of cases is less, and thus, more cases need to be examined. In addition, because the onset time was defined as the last time the disease did not occur, there were cases in both groups for which the exact onset time was unknown, which made an accurate comparison of actual “onset”-to-reperfusion times difficult. Further accumulation of cases and randomized controlled trials that include a method of MT for “with” group with careful attention paid to the risk of distal migration of the thrombus are needed.

■ CONCLUSION

Cardiogenic ICA occlusion with cross-flow, even if accompanied by cross-flow, is not necessarily a sufficient collateral flow and may not be associated with a good prognosis by itself. In cases where MT is performed for cardiogenic ICA occlusion with cross-flow, long treatment time and high risk of distal migration of thrombus may influence the poor prognosis. Cardiogenic ICA occlusion with cross-flow tends to have a smaller $T_{max} > 6$ s region and a larger $T_{max} > 4$ s region, resulting in a smaller perfusion mismatch. However, the lesion may cause cerebral infarction, and thus, MT should be performed. When MT is performed, we should try to reduce the risk of distal migration of thrombi. However, if distal migration of thrombus does occur, we should aim for the best possible recovery.

AUTHORSHIP CONTRIBUTION

Study conception and design: SK, RY, FK

Data collection: SK, RT, DO, KY

Analysis and interpretation of results: SK, FK

Draft manuscript preparation: SK

Critical revision of the article: KY, HT, MW

Other (study supervision, fundings, materials, etc.): MW

All authors (SK, RY, FK, RT, DO, KY, HT, MW) reviewed the results and approved the final version of the manuscript.

REFERENCES

- Albers GW, Marks MP, Kemp S, Christensen S, Tsai JP, Ortega-Gutierrez S, McTaggart RA, Torbey MT, Kim-Tenser M, Leslie-Mazwi T, Sarraj A: Thrombectomy for stroke at 6 to 16 hours with selection by perfusion imaging. *N Engl J Med* 378: 708-718, 2018
- Amuluru K, Romero CE, Pyle L, El-Ghanem M, Al-Mufti F: Mechanical thrombectomy of acute middle cerebral artery occlusion using trans-anterior communicating artery approach. *World Neurosurg* 112:46-52, 2018
- Chueh JY, Puri AS, Wakhloo AK, Gounis MJ: Risk of distal embolization with stent retriever thrombectomy and ADAPT. *J Neurointerv Surg* 8:197-202, 2016
- Goyal M, Menon BK, van Zwam WH, J Dippel DW, Mitchell PJ, Demchuk AM, Dávalos A, Majoie CB, van Der Lugt A, De Miquel MA, Donnan GA: Endovascular thrombectomy after large-vessel ischaemic stroke: A meta-analysis of individual patient data from five randomised trials. *Lancet* 387:1723-1731, 2016
- Haussen DC, Bousslama M, Dehkharghani S, Grossberg JA, Bianchi N, Bowen M, Frankel MR, Nogueira RG: Automated CT perfusion prediction of large vessel acute stroke from intracranial atherosclerotic disease. *Interv Neurol* 7:334-340, 2018
- Kanda Y: Investigation of the freely available easy-to-use software 'EZ' for medical statistics. *Bone Marrow Transplant* 48:452-458, 2013
- Kimura S, Yagi R, Kishi F, Ogawa D, Yamada K, Taniguchi H, Wanibuchi M: RAPID Tmax map was useful for determining the site of acute right internal carotid artery occlusion presenting with cerebral infarction in the right posterior cerebral artery region. *Interdiscip Neurosurg* 30:101649, 2022
- Kluytmans M, van der Grond J, van Everdingen KJ, Klijn CJ, Kappelle LJ, Viergever MA: Cerebral hemodynamics in relation to patterns of collateral flow. *Stroke* 30:1432-1439, 1999
- Liebeskind DS: Understanding blood flow: The other side of an acute arterial occlusion. *Int J Stroke* 2:118-120, 2007
- Liebeskind DS, Cotsonis GA, Saver JL, Lynn MJ, Cloft HJ, Chimowitz MI: Collateral circulation in symptomatic intracranial atherosclerosis. *J Cereb Blood Flow Metab* 31: 1293-1301, 2011
- Liebeskind DS, Cotsonis GA, Saver JL, Lynn MJ, Turan TN, Cloft HJ, Chimowitz MI: Collaterals dramatically alter stroke risk in intracranial atherosclerosis. *Ann Neurol* 69:963-974, 2011
- Ohshima T, Miyachi S: Experimental evaluation of the risk of distal embolization during endovascular clot retrieval using various techniques. *Asian J Neurosurg* 16:84-88, 2021
- Rikhtegar R, Mosimann PJ, Weber R, Wallocha M, Yamac E, Mirza-Aghazadeh-Attari M, Chapot R: Effectiveness of very low profile thrombectomy device in primary distal medium vessel occlusion, as rescue therapy after incomplete proximal recanalization or following iatrogenic thromboembolic events. *J Neurointerv Surg* 13:1067-1072, 2021
- Seifert-Held T, Eberhard K, Christensen S, Hofer E, Enzinger C, Albers GW, Lansberg M: Circle of Willis variants are not associated with thrombectomy outcomes. *Stroke Vasc Neurol* 6:310-313, 2021
- Shuaib A, Butcher K, Mohammad AA, Saqqur M, Liebeskind DS: Collateral blood vessels in acute ischaemic stroke: A potential therapeutic target. *Lancet Neurol* 10:909-921, 2011
- Sweid A, Head J, Tjoumakaris S, Xu V, Shivashankar K, Alexander TD, Dougherty JA, Gooch MR, Herial N, Hasan D, DePrince M: Mechanical thrombectomy in distal vessels: Revascularization rates, complications, and functional outcome. *World Neurosurg* 130:e1098-e1104, 2019
- Wu W, Cheng Y, Li Y, Jiang J, Chen F, Cai D, Zhang L: Assessment of primary collateral grades based on the integrity of Willis' Circle: Predicting the prognosis of acute intracranial internal carotid artery occlusion before thrombectomy. *World Neurosurg* 167:e1138-e1146, 2022
- Zhao H, Wang B, Xu G, Dong Y, Dong Q, Cao W: Collateral grade of the Willis' circle predicts outcomes of acute intracranial internal carotid artery occlusion before thrombectomy. *Brain Behav* 9:e01452, 2019