



Morphometric Development of Medial Surface of Cerebrum in Fetal Cadavers

Onur Can SANLI^{1,2}, Kenan OZTURK², Ahmet DURSUN³, Yadigar KASTAMONI², Soner ALBAY²

¹Lokman Hekim University Faculty of Medicine, Department of Anatomy, Ankara, Türkiye

²Suleyman Demirel University Faculty of Medicine, Department of Anatomy, Isparta, Türkiye

³Karamanoglu Mehmet Bey University Faculty of Medicine, Department of Anatomy, Karaman, Türkiye

This study was presented as a oral presentation at the 21th National Anatomy Congress, between 28 and 29 November 2020 (Online)

Corresponding author: Onur Can SANLI ✉ fztonurcansanli@gmail.com

ABSTRACT

AIM: To investigate the morphometric and morphological development of the medial surface of the cerebrum in 40 fetal cadavers without external anomalies and pathologies between the gestational ages of 22 and 40 weeks.

MATERIAL and METHODS: In this study, we measured the height and width of the cerebral hemisphere, cingulate sulcus, marginal sulcus, sulcus of the corpus callosum, calcarine sulcus, parieto-occipital sulcus, and central sulcus in each hemisphere. We examined these measures between genders and sides and assessed how these parameters developed over the course of gestational age (measured in months). Additionally, we aimed to determine the age at which each sulcus started to be visible.

RESULTS: The dimensions of the parameters showed a significant increase with gestational age. When comparing these parameters between the right and left hemispheres as well as genders, no statistically significant difference was found. Regarding the classification of the marginal sulcus, Type I accounted for 33% and Type II accounted for 32% of the cases. As for the classification of the parieto-occipital sulcus and calcarine sulcus, Type I was the most common with 47%, followed by Type II with 23%.

CONCLUSION: In our study, we believe that valuable parameters can be obtained to understand the morphometric development of sulcus structures in the medial surface of the cerebrum. The contribution of such studies to the knowledge of anatomy and neurosurgery will be significant. Knowledge of morphological differences in the cortex cerebri may also play a role in detecting certain neurological diseases (such as lissencephaly and Walker-Warburg syndrome) and explaining their neuropathology.

KEYWORDS: Brain, Telencephalon, Cerebral sulci, Dissection, Anatomy

ABBREVIATIONS: EQ: The encephalization quotient, US: Ultrasound, MRI: Magnetic resonance imaging, CRL: Crown rump length, BPD: Bi-parietal diameter, HC: Head circumference, FL: Femur length, FtL: Foot length, HCH: The height of the cerebral hemisphere, WCH: The width of the cerebral hemisphere, LCS: The length of the central sulcus, LCIS: The length of the cingulate sulcus, LMS: The length of the marginal sulcus, LPOS: The length of the parieto-occipital sulcus, LCAS: The length of the calcarine sulcus, LSCC: The length of the sulcus of corpus callosum

■ INTRODUCTION

The encephalization quotient (EQ) represents a quantitative value that describes the relative brain mass, which is the ratio of brain size to body size, in a wide range of species (14). Among all species, humans have the highest EQ scores (2). The increased cortical surface area within a relatively small cranial cavity is achieved through cortical folding (31). During fetal development, the initially smooth cortical surface (lissencephalic) matures into a convoluted state (gyrencephalic) through the formation of a complex pattern of gyrus and sulcus, which becomes longer and deeper as pregnancy progresses (3,4,6). The process of gyrogenesis, involving the formation of sulci and gyri, follows a regular sequence (12). The major phase of gyrogenesis begins in the third trimester of pregnancy and continues at least through the first year after birth (26,27,32). This convoluted appearance of the cortex indicates a normal, mature brain and is associated with various cognitive processes such as memory, attention, perceptual awareness, thought, language, and consciousness (12).

Subjective anatomical methods such as ultrasound or MRI (Magnetic Resonance Imaging) are utilized for fetal brain imaging (12). It has been suggested that embryogenesis, organogenesis, and fetal anatomy should be assessed individually for each gestational week to optimize the utilization of fetal ultrasonography. Thus, it is crucial to conduct morphometric studies on the anatomical and physiological characteristics that undergo changes throughout fetal development (20).

In normal fetal brains, there can be a delay of up to 8 weeks in the appearance of sulci as observed in MRI images. However, based on the generally defined appearance of sulci, it is expected that normal fetuses would exhibit the general characteristics noted in previous studies earlier than the given gestational age. On the other hand, if there is a delay of 10 weeks or more in the appearance of sulci in an otherwise normal-looking image, it should be interpreted as potentially abnormal (18). Therefore, obtaining detailed information on the normal fetal cortical development through MR images in at-risk groups, such as pregnant women with a family history of lissencephaly, can be valuable. Lissencephaly is a severe cortical malformation resulting from impaired neuronal migration during the 3rd and 4th months of pregnancy (34). The affected brains exhibit the absence or scarcity of gyri, referred to as agyria or pachygyria, respectively (11). The surface of the cerebrum appears smooth, resembling the state seen in fetuses before the 20th week of pregnancy (18). The most common clinical manifestations include severe psychomotor retardation, developmental delay, seizures, and growth retardation. The prognosis varies depending on the degree of cortical development, with severe cases often leading to death in infancy or early childhood. Prenatal diagnosis of an affected fetus enables appropriate counseling and optimization of obstetric management. Chromosomal abnormalities can be detected through chorionic villus sampling or amniocentesis. As routine chromosomal analysis may not detect chromosomal abnormalities in Miller-Dieker syndrome (9), it is crucial to discuss the findings of ultrasound

and MRI with the cytogenetic laboratory to ensure that appropriate tests are performed (11).

There are few dissection studies available in the literature that focus on the developmental aspects of the cerebrum in fetal cadavers. The objective of this study was to investigate the morphometric and morphological development of the medial surface of the cerebrum in fetal cadavers. The morphometric data and morphological categorizations provided in the study can be taken into consideration, especially in invasive procedures on the cerebrum in newborns (34). Such studies provide valuable contributions to the fields of neurosurgery and our understanding of anatomy. Additionally, morphometric and morphological differences observed in the cerebral cortex may have implications in the detection and explanation of neuropathology associated with certain neurological disorders, such as lissencephaly and Walker-Warburg syndrome.

■ MATERIAL and METHODS

This study involved the examination of 40 human fetuses (20 male fetuses, 20 female fetuses) ranging in age from 22 to 40 weeks of gestation. None of the fetuses we used in our study had any visible anomalies or pathologies (cleft palate and/or lip, polydactyly, syndactyly, meningomyelocele etc.) (5). The fetuses were obtained from the Maternity and Children's Hospital between 1996 and 2014 with the consent of their families. The causes of death in fetal cadavers are unknown. The fetuses were preserved in a 10% formaldehyde solution. Formaldehyde exhibits a shrinkage effect on tissues. According to the conducted studies, it is observed that this rate is approximately 3%. This 3% effect should be taken into consideration when evaluating the data in the publication (7). Approval for the study was obtained from the Suleyman Demirel University Faculty of Medicine Clinical Research Ethics Committee (Decision number 85, dated September 5, 2019). The fetuses were categorized into five groups based on their developmental stages: the 6th month (22-24 weeks of gestation), 7th month (25-28 weeks of gestation), 8th month (29-32 weeks of gestation), 9th month (33-36 weeks of gestation), and full-term (37-40 weeks of gestation). The gestational age of the fetuses was determined using measurements such as Crown Rump Length (CRL), Bi-Parietal Diameter (BPD), Head Circumference (HC), Femur Length (FL), and Foot Length (FtL) (17,18).

The cerebrum, cerebellum, and brainstem were extracted by employing the craniotomy technique in the fetuses. To visualize the medial surface of the cerebrum, which is distinct from the cerebellum and brainstem, a midsagittal incision was performed, allowing both medial surfaces to become visible. Subsequently, the dura mater and arachnoid mater were meticulously removed using forceps from the cerebral hemispheres, thus highlighting the sulci and gyri. The obtained medial surface of the cerebrum was then photographed in a parallel orientation to the ground. Morphometric measurements were conducted by uploading the captured photos to the Image-J program.

The following parameters were measured on both the right and left sides of the sulci on the medial surface of the cerebrum:

- Height of the Cerebral Hemisphere (HCH) (Figure 1)
- Width of the Cerebral Hemisphere (WCH) (Figure 1)
- Length of the Central Sulcus (LCS) (Figure 2)
- Length of the Cingulate Sulcus (LCIS) (Figure 2)

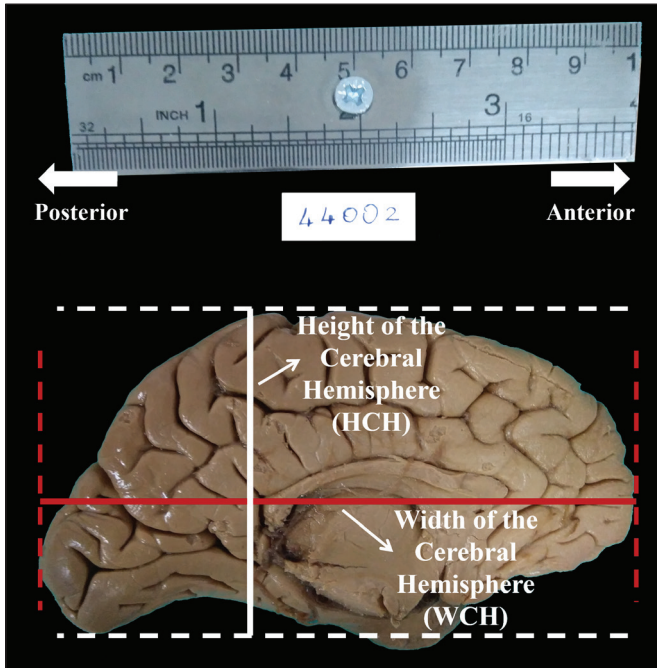


Figure 1: Measurement of hemisphere height and hemisphere width.

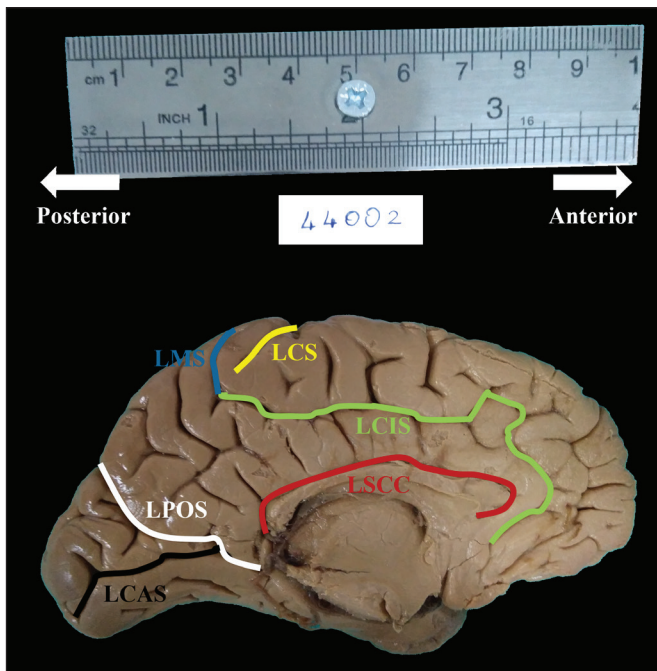


Figure 2: Measurement of the lengths of the sulci in the medial surface of the cerebrum.

- Length of the Marginal Sulcus (LMS) (Figure 2)
- Length of the Parieto-Occipital Sulcus (LPOS) (Figure 2)
- Length of the Calcarine Sulcus (LCAS) (Figure 2)
- Length of the Sulcus of the Corpus Callosum (LSCC) (Figure 2)

We examined the weeks in which the sulci were observed in fetal cadavers dissected from the 22nd week of gestation. To determine the precise week in which the sulcus becomes detectable, we followed this approach: If a sulcus was observed in more than 50% of the medial surface of fetal cadavers consistently for two consecutive weeks, we identified those weeks as the onset of sulcus appearance.

Classification of Sulcus

During the period of measurement, we identified distinct morphological features in the cingulate sulcus, parieto-occipital sulcus, and calcarine sulcus, which are primary sulci located on the medial surface of the cerebrum. Additionally, we classified these sulci based on their observed characteristics.

a- Typing of Cingulate Sulcus

To enhance the accuracy of typing of cingulate sulcus, we initiated the observation one week after detecting the marginal sulcus, specifically from the 29th week of gestation. We examined the formation of the cingulate sulcus in 26 fetuses. The types of cingulate sulcus observed are depicted in Figure 3.

If the paracentral sulcus and marginal sulcus are observed in conjunction with the cingulate sulcus, we named it as Type I.

If the paracentral sulcus, marginal sulcus, and subparietal sulcus are observed together with the cingulate sulcus, we named it as Type II.

When the paracentral sulcus, marginal sulcus, and subparietal sulcus are observed in conjunction with the cingulate sulcus, if an additional sulcus emerges between the paracentral sulcus and marginal sulcus within the cingulate sulcus, we named it as Type III.

If the marginal sulcus and paracentral sulcus are present alongside the cingulate sulcus, and the cingulate sulcus is not continuous, we named it as Type IV.

Apart from these typings, a cingulate sulcus type was observed on the unilateral medial surface of a 33-week-old fetus (Figure 4). We did not include this in these typings.

b- Typing of Parieto-occipital Sulcus and Calcarine Sulcus

To ensure more accurate typing of the sulci, we initiated the observation one week after detecting the calcarine sulcus, specifically from the 25th week of gestation. In two fetuses, the calcarine sulcus did not form. However, we examined the sulcus formations in 33 other fetuses. The types of sulcus formations are depicted in Figure 5.

If the parieto-occipital sulcus and calcarine sulcus run straight without branching, we named it as Type I.

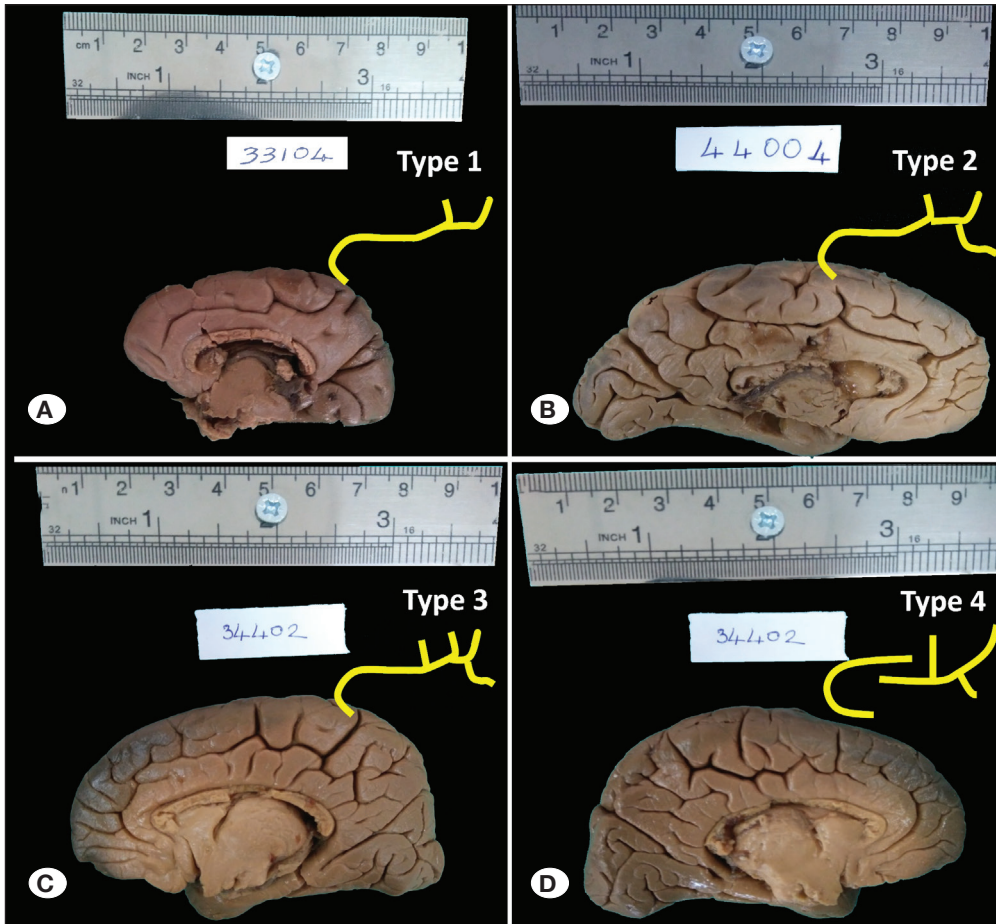


Figure 3: Types of cingulate sulcus (while the typings were schematized, Type 2 and Type 4 was schematized by taking its mirror image).

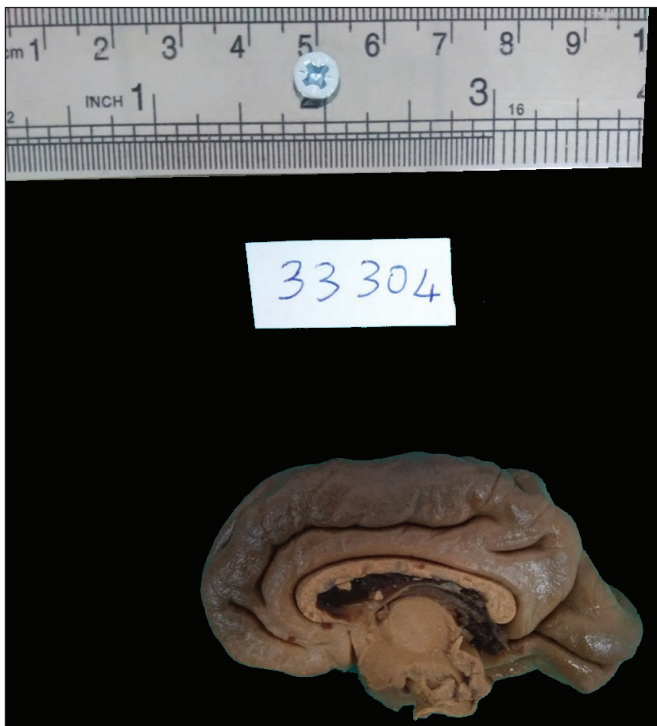


Figure 4: Right medial surface of cerebrum of 33-week-old fetus not included in sulcus cinguli typing.

If the parieto-occipital sulcus is unbranched and the calcarine sulcus bifurcates at the end, we named it as Type II.

If the parieto-occipital sulcus bifurcates at the end and the calcarine sulcus is unbranched, we named it as Type III.

If the parieto-occipital sulcus bifurcates at the end and the calcarine sulcus branches off, forming an oblique letter H, we named it as Type IV.

If the parieto-occipital sulcus gives off two separate branches and the calcarine sulcus runs unbranched, we named it as Type V.

Statistical Analysis

Statistical analysis was performed using the SPSS 22 for Windows package program. For parameters related to the medial surface of the cerebrum, minimum and maximum values, arithmetic averages, and standard deviations were calculated based on gestational age (months). Parametric values, presented in terms of arithmetic mean \pm standard deviation, were determined after conducting normality tests (Kolmogorov-Smirnov, Shapiro-Wilk W) to assess whether the data followed a parametric or nonparametric distribution.

Parametric data (excluding the measurement of LCS) were analyzed using independent t-tests (Independent samples

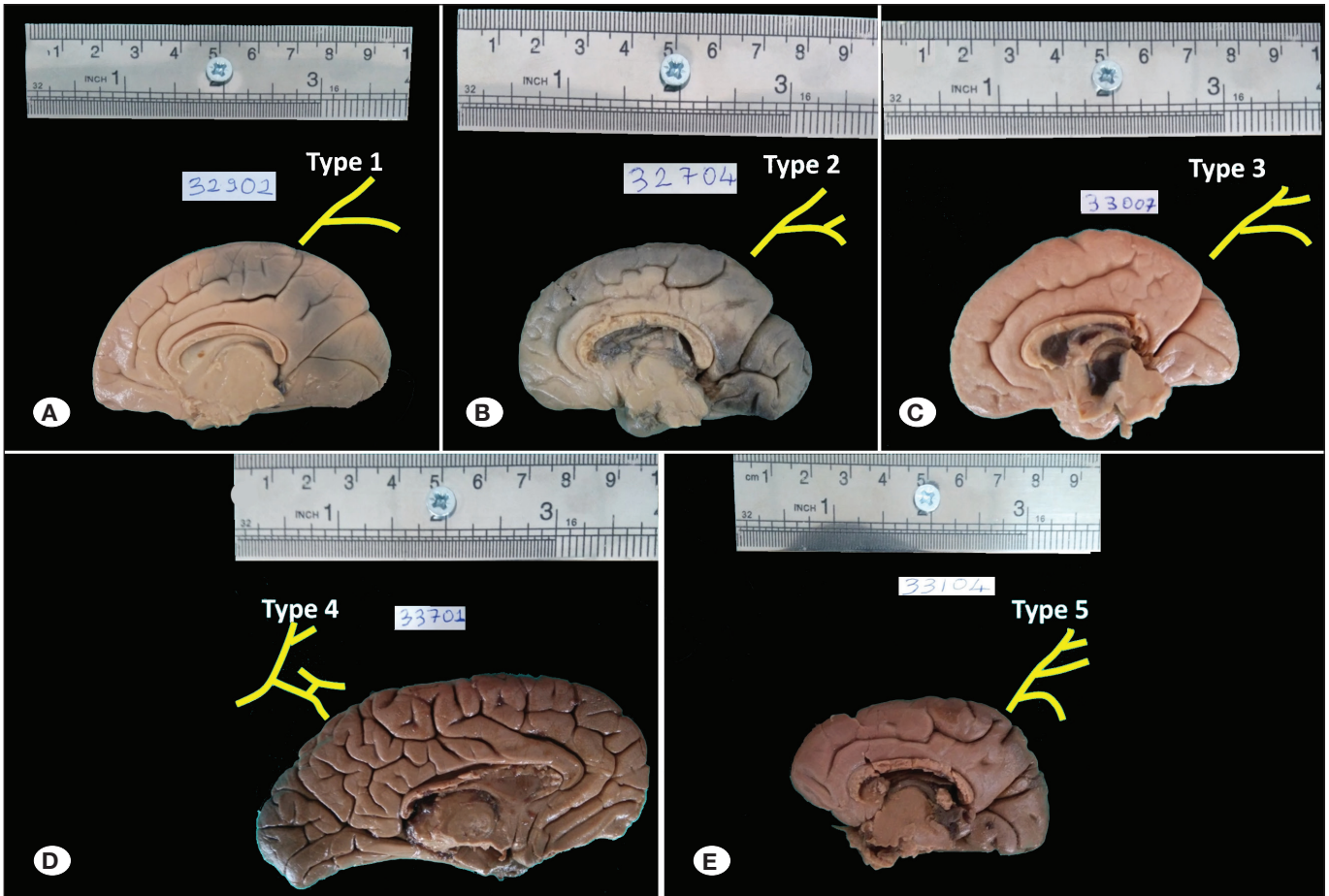


Figure 5: Types of parieto-occipital sulcus and calcarine sulcus (while the typings were schematized, Type 4 was schematized by taking its mirror image).

t-test) and one-way analysis of variance (One-way ANOVA). Nonparametric data (measurement of LCS) were analyzed using the Mann-Whitney U test.

A significance level of $p < 0.05$ was considered statistically significant. Pairwise comparisons between groups (months) are represented by figures and explained below the table.

RESULTS

In our study, we evaluated the morphometric data of the medial surface of a total of 80 cerebrums, including both the right and left sides of 40 fetuses (20 males and 20 females). The number of fetuses examined and the distribution of gestational months are presented in Table I.

Table II displays the length parameters associated with the medial surface of the cerebrum, including the maximum, minimum, mean values, standard deviations, and a comparison between the right and left sides. Statistical analysis revealed no significant difference between the right and left parameters.

The mean values and standard deviations of the length measurements for each parameter on the medial surface of the cerebrum, stratified by gender, are presented in Table III.

Table I: Number of Fetuses by Month

Gestational Age (month)	Fetus	Percentage
6	7	17.5
7	7	17.5
8	9	22.5
9	8	20
Term	9	22.5
Total	40	100

However, no statistically significant difference was observed when comparing these parameters based on gender.

Table IV presents the mean values and standard deviations of the length measurements for each parameter on the medial surface of the cerebrum, categorized by gestational months. Generally, when examining the lengths of the sulci across months, an increase of approximately 10% to 20% is observed. The tables provide a comparison of these

Table II: Length Parameters Related to Medial Surface of Cerebrum

	n	Minimum	Maximum	Mean	Standard Deviation	p-value
HCH right	39	24.68	67.14	40.20	9.40	0.790
HCH left	40	25.10	63.60	39.66	8.67	
WCH right	39	48.72	105.53	72.39	16.09	0.889
WCH left	40	48.10	105.27	71.89	15.98	
LCS right	20	2.46	13.68	6.11	2.93	0.182
LCS left	15	3.51	13.48	7.68	3.38	
LSCC right	39	33.99	66.75	50.27	7.84	0.244
LSCC left	40	34.27	69.77	50.24	9.20	
LCIS right	27	41.71	97.06	63.54	14.47	0.988
LCIS left	19	41.64	93.52	61.29	13.38	
LMS right	23	6.81	18.65	12.04	3.02	0.621
LMS left	18	6.48	18.29	12.51	2.91	
LPOS right	39	11.80	41.97	26.20	6.88	0.640
LPOS left	39	12.90	38.96	26.90	6.24	
LCAS right	35	11.09	34.07	18.54	5.00	0.552
LCAS left	37	10.59	30.43	18.30	4.60	

HCH: The Height of the Cerebral Hemisphere, **WCH:** The Width of the Cerebral Hemisphere, **LCS:** The Length of the Central Sulcus, **LSCC:** The Length of the Sulcus of Corpus Callosum, **LCIS:** The Length of the Cingulate Sulcus, **LMS:** The Length of the Marginal Sulcus, **LPOS:** The Length of the Parieto-occipital Sulcus, **LCAS:** The Length of the Calcarine Sulcus.

Table III: Distribution of Parameters by Gender

	Male (Mean±Std.)	Female (Mean±Std.)	p-value
HCH right	41.92 ± 10.21	41.25 ± 9.51	0.22
HCH left	41.25 ± 9.51	37.9 ± 7.49	0.23
WCH right	73.9 ± 15.89	70.63 ± 16.60	0.54
WCH left	73.71 ± 16.23	69.88 ± 15.88	0.46
LSCC right	51.03 ± 7.48	49.37 ± 8.37	0.52
LSCC left	51.01 ± 8.82	49.38 ± 9.78	0.58
LCIS right	6.47 ± 2.87	5.75 ± 3.09	0.29
LCIS left	7.81 ± 3.58	7.53 ± 3.42	0.73
LCS right	64.44 ± 14.32	62.56 ± 15.15	0.58
LCS left	61.16 ± 10.62	61.42 ± 16.62	0.97
LMS right	12.22 ± 2.57	11.78 ± 3.76	0.74
LMS left	12.34 ± 3.02	12.78 ± 2.93	0.76
LPOS right	26.99 ± 6.38	25.28 ± 7.49	0.45
LPOS left	27.17 ± 6.13	26.59 ± 6.52	0.75
LCAS right	18.96 ± 5.45	17.97 ± 4.44	0.57
LCAS left	18.9 ± 4.57	17.6 ± 4.69	0.40

HCH: The Height of the Cerebral Hemisphere, **WCH:** The Width of the Cerebral Hemisphere, **LCS:** The Length of the Central Sulcus, **LSCC:** The Length of the Sulcus of Corpus Callosum, **LCIS:** The Length of the Cingulate Sulcus, **LMS:** The Length of the Marginal Sulcus, **LPOS:** The Length of the Parieto-occipital Sulcus, **LCAS:** The Length of the Calcarine Sulcus.

parameters based on gestational months, and the specific months with significant differences are indicated below the table (Table 3). Statistically significant differences were observed in all parameters, except for the left LCS and left LMS, based on gestational months.

Table 5 displays the weeks from which the sulci are observed. However, we could not provide data on the specific week of detection for the parieto-occipital sulcus since it was already visible in the fetal cadavers dissected from the 22nd week. It

has been determined that calcarine sulcus starts to appear from 24-25 weeks, cingulate sulcus from 24-25 weeks, marginal sulcus from 27-28 weeks, paracentral sulcus from 29-30 weeks, "paraolfactory sulci" and subparietal sulcus from 30-31 weeks.

According to the typing of the cingulate sulcus:

Type I was observed bilaterally in 7 fetuses and unilaterally in 4 fetuses (1 on the right side, 3 on the left side), making a total of 18 hemispheres (33%).

Table IV: Distribution of Parameters by Month

	6. Month Mean±Std., n	7. Month Mean±Std., n	8. Month Mean±Std., n	9. Month Mean±Std., n	Term	p-value
HCH right ^a	30.03 ± 2.83 6	31.51 ± 4.40 7	40.43 ± 4.55 9	42.25 ± 5.46 8	51.68 ± 7.57 9	<0.001
HCH left ^a	30.22 ± 2.89 7	32.14 ± 4.07 7	39.60 ± 4.05 9	42.76 ± 4.85 8	50.15 ± 7.03 9	<0.001
WCH right ^b	52.49 ± 4.63 6	60.02 ± 7.61 7	70.06 ± 6.92 9	75.83 ± 8.30 8	94.55 ± 7.80 9	<0.001
WCH left ^a	52.22 ± 4.53 7	60.29 ± 5.47 7	69.00 ± 5.39 9	77.27 ± 8.16 8	94.30 ± 7.72 9	<0.001
LSCC right ^c	41.92 ± 3.52 6	43.86 ± 5.25 7	48.34 ± 4.30 9	53.56 ± 4.45 8	59.81 ± 4.69 9	<0.001
LSCC right ^c	40.86 ± 5.03 7	44.86 ± 6.14 7	47.28 ± 5.75 9	54.08 ± 6.05 8	61.25 ± 6.13 9	<0.001
LCIS right ^d		51.57 ± 6.46 3	52.71 ± 6.37 7	59.34 ± 9.59 8	79.67 ± 9.61 9	<0.001
LCIS left ^e		53.53 ± 16.81 2	48.86 ± 6.33 5	59.93 ± 8.43 5	73.35 ± 9.81 7	0.003
LCS right ^f			4.33 ± 0.89 6	4.84 ± 1.48 7	8.90 ± 3.19 7	0.002
LCS left			4.28 ± 1.09 2	6.95 ± 2.95 6	9.27 ± 3.45 7	0.056
LMS right ^g		8.94 1	9.77 ± 2.54 7	11.78 ± 2.00 7	14.66 ± 2.29 8	0.003
LMS left		11.99 1	9.80 ± 2.72 4	13.07 ± 2.98 6	13.66 ± 2.46 7	0.185
LPOS right ^c	18.23 ± 3.94 6	21.75 ± 2.13 7	24.52 ± 3.63 9	28.11 ± 5.15 8	34.97 ± 4.09 9	<0.001
LPOS left ^g	21.15 ± 4.96 7	23.49 ± 4.11 6	25.57 ± 4.10 9	29.13 ± 5.98 8	32.99 ± 4.61 9	<0.001
LCAS right ^f	13.09 ± 2.16 4	15.85 ± 1.93 5	18.13 ± 4.39 9	18.10 ± 4.38 8	23.24 ± 5.81 9	0.002
LCAS left ^g	13.74 ± 2.11 5	14.67 ± 3.11 6	18.35 ± 2.83 9	18.29 ± 3.41 8	23.21 ± 4.35 9	0.001

^a: p<0.05 (6-9, 6-10, 7-10); ^b: p<0.05 (6-9, 6-10, 7-10, 8-10); ^c: p<0.05 (6-9, 6-10, 7-10, 8-10); ^d: p<0.05 (7-10, 8-10); ^e: p<0.05 (7-10); ^f: p<0.05 (6-10); ^g: p<0.05 (6-10, 7-10). **HCH**: The Height of the Cerebral Hemisphere, **WCH**: The Width of the Cerebral Hemisphere, **LCS**: The Length of the Central Sulcus, **LSCC**: The Length of the Sulcus of Corpus Callosum, **LCIS**: The Length of the Cingulate Sulcus, **LMS**: The Length of the Marginal Sulcus, **LPOS**: The Length of the Parieto-occipital Sulcus, **LCAS**: The Length of the Calcarine Sulcus

Type II was observed bilaterally in 5 fetuses and unilaterally in 7 fetuses (5 on the right side, 2 on the left side), making a total of 17 hemispheres (32%).

Type III was observed bilaterally in 4 fetuses and unilaterally in 4 fetuses (2 on the right side, 2 on the left side), making a total of 12 hemispheres (22%).

Type IV was observed bilaterally in 1 fetus and unilaterally in 4 fetuses (2 on the right side, 2 on the left side), making a total of 6 hemispheres (11%).

According to the typing of the parieto-occipital sulcus and calcarine sulcus:

Type I was observed bilaterally in 12 fetuses and unilaterally in 7 fetuses (4 on the right side, 3 on the left side), making a total of 31 hemispheres (47%).

Type II was observed bilaterally in 6 fetuses and unilaterally in 3 fetuses (1 on the right side, 2 on the left side), making a total of 15 hemispheres (23%).

Type III was observed bilaterally in 2 fetuses and unilaterally in 4 fetuses (2 on the right side, 2 on the left side), making a total of 8 hemispheres (12%).

Type IV was observed bilaterally in 3 fetuses and unilaterally in 3 fetuses (1 on the right side, 2 on the left side), making a total of 9 hemispheres (14%).

Type V was observed bilaterally in 1 fetus and unilaterally in 1 fetus (1 on the right side), making a total of 3 hemispheres (4%).

DISCUSSION

Characterizing the human anatomy at different stages of brain development during the fetal period not only enhances our understanding of this highly regulated process but also provides valuable insights for detecting abnormalities arising from genetic or environmental factors. Significant morphological changes occur in the nerve structures of the human brain during the second trimester of fetal life (24).

Studies on the human brain have revealed substantial variations in the appearance of sulci and gyri, even between the two hemispheres of the same individual. Due to this variability, it becomes challenging to identify specific sulci as they can exhibit asymmetry and variations. However, despite these variations, studies have consistently demonstrated the presence of primary sulcus structures (13,32). In a study conducted by Ebeling et al. (8), no significant difference was found when comparing the lengths of sulci between the right and left hemispheres, suggesting that the hemispheres may exhibit symmetry.

The development of sulci in the cerebral cortex is considered a significant marker of fetal brain maturation by neuropathologists. However, there are variations in the literature regard-

Table V: Weeks in Which Sulcus were Detected

Sulcus	Determined week
Parieto-occipital sulcus	<22
Calcarine sulcus	23-24
Cingulate sulcus	24-25
Marginal sulcus	27-28
Paracentral sulcus	29-30
Paraolfactory sulcus	30-31
Subparietalis sulcus	30-31

Table VI: Comparison of Studies on the Weeks When Sulcus ae Detected

	US Study			MRI Study			Anatomy Study		
	Bernard et al., 1988 (1)	Monteagudo &Timor-Tritch, 1997 (219)	Toi et al., 2004 (33)	Levine& Barnes, 1999 (16)	Ruoss et al., 2001 (29)	Garel et al., 2001 (10)	Dorovini-Zis & Dolman, 1977 (6)	Nishikuni, 2013 (22)	Our study
Fetus	70	262	50	40	51	173	80	107	40
Gestational age (week)	10-37	14-40	15-30	14-38	23-43	22-38	22-41	12-40	22-40
Cingulate sulcus	22-24	26	23	24-25	28-33	24-25	24	19	24-25
Margine sulcus	30							30 ± 3	27-28
Paracentral sulcus								30 ± 3	29-30
Paraolfactory sulcus								29 ± 3	30-31
Subparietalis sulcus								30 ± 3	30-31
Calcarine sulcus	23	18	19	18-19	29-38	22-23	22	17	23-24
Parieto-occipital sulcus	23	18	19	18-19	30-33	22-23	22	17	

ing the timing of emergence for certain sulci (3,6,15). Table 6 presents data from various studies, demonstrating that the formation time of the same sulcus can vary across different weeks (1,3,10,16,19,22,29,33). The inconsistencies in sulcus formation patterns can be attributed to several factors:

1. Gestational age, which is not based on the same criteria for all authors - some of them use the last menstrual period (known to be unreliable), while others consider measurements such as head circumference, crown-rump length, or the presence of general pathological findings.
2. Differences in the study methods - MRI, ultrasonography, and anatomical studies are used, leading to variations in the observed results.
3. Brain side (right-left) and the inclusion of twin fetuses, which may impact sulcus development. A previous study reported a 2 or 3 week delay in the development of sulcation patterns in the brains of twins between 19 and 32 weeks of gestation.
4. The criteria for determining the week at which sulci are detected vary among studies.

These inconsistencies highlight the challenge of establishing clear and reliable patterns of sulcus formation with high precision.

According to the typings we performed for the cingulate sulcus, the most common type observed in all examined medial surfaces was Type I (33%), followed by Type II (32%). As the secondary sulci began to form, the incidence of Type I decreased, while the incidences of Type II and Type III increased. This suggests that the shape of the cingulate sulcus tends to resemble Type II and Type III as the secondary sulci develop during the developmental process. If Type IV was seen in a scattered way.

Regarding the typings we conducted for the parieto-occipital sulcus and calcarine sulcus, the most common type observed in all examined medial surfaces was Type I with a frequency of 47%, followed by Type II with 23%. Type IV was observed since the formation of the secondary sulci. This suggests that the type may closely resemble Type IV when the secondary sulci grow during the developing process. When the parameters we measured were analyzed by months, it was observed that almost all parameters showed an increase in length (except for left LCS and left LMS). The lengths of the sulci increased consistently, with approximately the same percentage increase, when analyzed across different months.

There is a limited number of studies available on the morphometry of the medial surface of the cerebrum in fetal cadavers. The majority of studies conducted in this area primarily utilize MRI or ultrasound (US) techniques.

Tumors in the brain can often lead to changes in the boundaries of the cortex between hemispheres, similar to asymmetrical formations. In such cases, it is important to consider cerebral asymmetry and evaluate the MRI of the unaffected hemisphere for preoperative planning (6). Having a better understanding of the anatomical structures within the hemispheres is crucial

in the field of neurosurgery. Certain prominent formations in the human brain can serve as reference points for locating lesions and tumors in different regions and depths (23,25). Specifically, the parameters related to the term period that we have examined in our study may contribute to surgical procedures for conditions such as brain tumors in newborns.

Gaining more morphological information about the relevant central nervous system formations is crucial for better comprehending the diversity present in the human brain, interpreting functional imaging studies, and guiding intraoperative dissection (28,30). Taking into account racial and individual differences, particularly in the context of neurosurgery, may hold significance for the management of operations that involve microdissection (28).

Limitations of Our Study

The conditions that created limitations in our study were as follows:

- In the pre-22 week group, fetuses at and after 22 weeks were examined due to the inadequacy of the number of fetuses and difficulties in dissection.
- Since the right cerebral hemisphere was fragmented after dissection in a 23-week-old fetus, measurements on this side could not be made.
- Measurements have been made since the central sulcus began to appear in the medial surface of the cerebrum, but sometimes it cut the inner surface of the hemisphere on one side.
- The cingulate sulcus was sometimes not continuous, thus creating a change in the number of hemispheres measured on the right or left in the LCS measurement.
- Although the marginal sulcus was seen in the continuation of the cingulate sulcus, it was sometimes absent on one of the parties.
- In the measurement of the length of calcarine sulcus, the continuity of the sulcus affected the measurements.

CONCLUSION

The morphometric measurements we conducted were performed for the first time on fetal cadavers. When evaluating the lengths of the sulci according to the right-left sides and gender, no statistically significant differences were found. The lengths of the sulci demonstrated a consistent percentage increase by months, and significant differences were observed between them. The variations in the weeks when the sulci were detected were remarkable. These inconsistencies highlight the challenge of establishing precise and reliable patterns regarding sulcus formation with a high level of precision. Through our anatomical study, we aimed to contribute more reliable findings to the existing literature in determining the specific weeks.

Knowledge of the normal pattern of sulcus development in the fetal period may allow prenatal detection of lissencephaly associated with Miller-Dieker syndrome with US and MRI

(11,16). Likewise, mastery of the cranial and extracranial US findings associated with Walker-Warburg syndrome enables the diagnosis (10). Therefore, we classified cingulate sulcus, calcarine sulcus and parieto-occipital sulcus. Our findings might be a reference for future studies. We still need to learn more about how the human brain develops and conduct more research on fetuses.

Declarations

Funding: There is no funding to report.

Availability of data and materials: The datasets generated and/or analyzed during the current study are available from the corresponding author by reasonable request.

Disclosure: Authors declare no conflict of interest.

AUTHORSHIP CONTRIBUTION

Study conception and design: OCS, SA

Data collection: OCS, KO

Analysis and interpretation of results: KO, OCS

Draft manuscript preparation: OCS, AD, YK

Critical revision of the article: AD, YK, SA, OCS

Other (study supervision, fundings, materials, etc...): OCS, KO, AD, YK, SA

All authors (OCS, KO, AD, YK, SA) reviewed the results and approved the final version of the manuscript.

REFERENCES

- Bernard C, Droulle P, Didier F, Gérard H, Larroche JC, Plenat F, Bomsel F, Roland J, Hoeffel JC: Echographic aspects of cerebral sulci in the ante- and perinatal period. *J Radiol* 69:521-532, 1988
- Boddy AM, McGowen MR, Sherwood CC, Grossman LI, Goodman M, Wildman DE: Comparative analysis of encephalization in mammals reveals relaxed constraints on anthropoid primate and cetacean brain scaling. *J Evol Biol* 25:981-994, 2012. <https://doi.org/10.1111/j.1420-9101.2012.02491.x>
- Chi JG, Dooling EC, Gilles FH: Gyral development of the human brain. *Ann Neurol* 1:86-93, 1977. <https://doi.org/10.1002/ana.410010109>
- Cusack R: The intraparietal sulcus and perceptual organization. *J Cogn Neurosci* 17:641-651, 2005. <https://doi.org/10.1162/0898929053467541>
- Dagtekin O, Beger O, Taghipour P, Dagtekin A, Ors AB, Vayisoglu Y, Talas DU: Development of the geniculate ganglion in human fetuses. *Turk Neurosurg* 32:406-411, 2022. <https://doi.org/10.5137/1019-5149.JTN.35393-21.2>
- Dorovini-Zis K, Dolman CL: Gestational development of brain. *Arch Pathol Lab Med* 101:192-195, 1977
- Dursun A, Kastamoni Y, Kacaroglu D, Yuzbasioglu N, Ertekin T: Morphometric development of the tongue in fetal cadavers. *Surg Radiol Anat* 42:3-8, 2020. <https://doi.org/10.1007/s00276-019-02301-z>
- Ebeling U, Steinmetz H: Anatomy of the parietal lobe: Mapping the individual pattern. *Acta Neurochir* 136:8-11, 1995. <https://doi.org/10.1007/BF01411428>
- Fong KW, Ghai S, Toi A, Blaser S, Winsor EJ, Chitayat D: Prenatal ultrasound findings of lissencephaly associated with Miller-Dieker syndrome and comparison with pre- and postnatal magnetic resonance imaging. *Ultrasound Obstet Gynecol* 24:716-723, 2004. <https://doi.org/10.1002/uog.1777>
- Garel C, Chantrel E, Brisse H, Elmaleh M, Luton D, Oury JF, Sebag G, Hassan M: Fetal cerebral cortex: Normal gestational landmarks identified using prenatal MR imaging. *AJNR Am J Neuroradiol* 22:184-189, 2001
- Ghai S, Fong KW, Toi A, Chitayat D, Pantazi S, Blaser S: Prenatal US and MR imaging findings of lissencephaly: Review of fetal cerebral sulcal development. *Radiographics* 26:389-405, 2006. <https://doi.org/10.1148/rg.262055059>
- Ginsberg Y, Ganor-Ariav O, Hussein H, Adam D, Khatib N, Weiner Z, Beloosesky R, Goldstein I: Quantification of fetal gyrogenesis in the third trimester. A novel algorithm for evaluating fetal sulci development. *J Neuroimaging* 31:372-378, 2021. <https://doi.org/10.1111/jon.12817>
- Gonul Y, Songur A, Uzun I, Uygur R, Alkoc OA, Caglar V, Kucuker H: Morphometry, asymmetry and variations of cerebral sulci on superolateral surface of cerebrum in autopsy cases. *Surg Radiol Anat* 36:651-661, 2013. <https://doi.org/10.1007/s00276-013-1237-7>
- Jerison HJ: Evolution of the brain and intelligence by Harry J. Jerison. *Curr Anthropol* 16:403-426, 1975. <https://doi.org/10.1086/201571>
- Larroche JC: Morphological criteria of central nervous system development in the human foetus. *J Neuroradiol* 8:93-108, 1981
- Levine D, Barnes PD: Cortical maturation in normal and abnormal fetuses as assessed with prenatal MR imaging. *Radiology* 210:751-758, 1999. <https://doi.org/10.1148/radiology.210.3.r99mr47751>
- Lomholt JF, Fischer-Hansen B, Keeling JW, Reintoft I, Kjaer I: Subclassification of anencephalic human fetuses according to morphology of the posterior cranial fossa. *Pediatr Dev Pathol* 7:601-606, 2004. <https://doi.org/10.1007/s10024-004-9098-z>
- Malas MA, Salbacak A, Sulak O: The growth of the upper and lower extremities of Turkish fetuses during the fetal period. *Surg Radiol Anat* 22:249-254, 2000. <https://doi.org/10.1007/s00276-000-0249-2>
- Monteagudo A, Timor-Tritsch IE: Development of fetal gyri, sulci and fissures: A transvaginal sonographic study. *Ultrasound Obstet Gynecol* 9:222-228, 1997. <https://doi.org/10.1046/j.1469-0705.1997.09040222.x>
- Munsick RA: Similarities of Negro and Caucasian fetal extremity lengths in the interval from 9 to 20 weeks of pregnancy. *Am J Obstet Gynecol* 156:183-185, 1987. [https://doi.org/10.1016/0002-9378\(87\)90234-1](https://doi.org/10.1016/0002-9378(87)90234-1)
- Naidich TP, Grant JL, Altman N, Zimmerman RA, Birchansky SB, Braffman B, Daniel JL: The developing cerebral surface. Preliminary report on the patterns of sulcal and gyral maturation-anatomy, ultrasound, and magnetic resonance imaging. *Neuroimaging Clin N Am* 4:201-240, 1994
- Nishikuni K, Ribas GC: Study of fetal and postnatal morphological development of the brain sulci. *J Neurosurg Pediatr* 11:1-11, 2013. <https://doi.org/10.3171/2012.9.PEDS12122>

23. Ono M, Kubik S, Abernathy CD: Atlas of the cerebral sulci. New York: Georg Thieme Verlag, 1990: 62-74
24. Prayer D, Kasprian G, Krampfl E, Ulm B, Witzani L, Prayer L, Brugger PC: MRI of normal fetal brain development. *Eur J Radiol* 57:199-216, 2006. <https://doi.org/10.1016/j.ejrad.2005.11.020>
25. Ribas GC: The cerebral sulci and gyri. *Neurosurg Focus* 28:E2, 2010. <https://doi.org/10.3171/2009.11.FOCUS09245>
26. Richman DP, Stewart RM, Hutchinson JW, Caviness Jr VS: Mechanical model of brain convolutional development. *Science* 189:18-21, 1975. <https://doi.org/10.1126/science.1135626>
27. Rolo LC, Araujo Junior E, Nardoza LMM, Oliveira PS, Ajzen SA, Moron AF: Development of fetal brain sulci and gyri: assessment through two and threedimensional ultrasound and magnetic resonance imaging. *Arch Gynecol Obstet* 283:149-158, 2011. <https://doi.org/10.1007/s00404-010-1691-y>
28. Rumeau C, Tzourio N, Murayama N, Peretti-Viton P, Levier O, Joliot M, Mazoyer B, Salamon G: Location of hand function in the sensorimotor cortex: MR and functional correlation. *AJNR Am J Neuroradiol* 15:567-572, 1994
29. Ruoss K, Lövlblad K, Schroth G, Moessinger AC, Fusch C: Brain development (sulci and gyri) as assessed by early postnatal MR imaging in preterm and term newborn infants. *Neuropediatrics* 32:69-74, 2001. <https://doi.org/10.1055/s-2001-13871>
30. Sanes JN, Donoghue JP, Thangaraj V, Edelman RR, Warach S: Shared neural substrates controlling hand movements in human motor cortex. *Science* 268:1775-1777, 1995. <https://doi.org/10.1126/science.7792606>
31. Stiles J, Jernigan TL: The basics of brain development. *Neuropsychol Rev* 20:327-348, 2010. <https://doi.org/10.1007/s11065-010-9148-4>
32. Symington J, Crymble PT: The central fissure of the cerebrum. *J Anat Physiol* 48:321-339, 1913
33. Toi A, Lister WS, Fong KW: How early are fetal cerebral sulci visible at prenatal ultrasound and what is the normal pattern of early fetal sulcal development? *Ultrasound Obstet Gynecol* 24:706-715, 2004. <https://doi.org/10.1002/uog.1802>
34. Van der Knaap MS, Valk J: Classification of congenital abnormalities of the CNS. *AJNR Am J Neuroradiol* 9:315-326, 1988
35. Yagmurkaya U, Uysal II, Kabakci A: Definition of an effective site for greater and third occipital nerve block in the nuchal region: A fetal cadaver study. *Turk Neurosurg* 33:535-540, 2023. <https://doi.org/10.5137/1019-5149.JTN.41588-22.2>