



Endoscopy-Assisted Suturectomy: Can It be the Priority Choice in the Treatment of Metopic Synostosis?

Harun DEMIRCI¹, Pelin KUZUCU², Emrah EGEMEN³, Gokcen EMMEZ⁴, Yunus Emre INCE⁵, Pınar OZISIK¹

¹Yıldırım Beyazıt University School of Medicine, Department of Neurosurgery, Ankara, Türkiye

²Gazi University Faculty of Medicine, Division of Pediatric Neurosurgery, Ankara, Türkiye

³Pamukkale University, Faculty of Medicine, Department of Neurosurgery, Denizli, Türkiye

⁴Gazi University Faculty of Medicine, Department of Anesthesia, Ankara, Türkiye

⁵Ankara City Hospital, Children's Hospital Tower, Department of Pediatrics, Ankara, Türkiye

Corresponding author: Pelin KUZUCU ✉ drpelinkuzucu@gmail.com

ABSTRACT

AIM: To mathematically present the results of endoscopic assisted surgery in the treatment of metopic synostosis.

MATERIAL and METHODS: We present a follow-up of the stages of treatment of 43 patients with metopic synostosis who underwent surgery in a multicenter retrospective study between 2018 and 2021. We developed the formula $D3/((D1+D2)/2)$ based on the theory of "The Angle of a Triangle Opposite The Longest Side is the Largest Angle". And we called this method 'Metopic Angle Proportion (MAP)'. Paired samples T-test was performed for statistical results. P value <0.05 was considered statistically significant.

RESULTS: According to the MAP method; measurements for frontal enlargement, mean pretreatment length D1: 34,57 mm, D2: 34,81 mm, D3: 60,46 mm, and the end of treatment as D1: 37,88 mm, D2: 38,19 mm, D3: 71,09 mm. We performed the formula $D3/((D1+D2)/2)$. While this rate was 1.74 before treatment, it increased to 1.87 after treatment. As a result of statistical analysis, it was also found to be significant ($p \leq 0.05$).

CONCLUSION: Endoscopy-assisted suturectomy can be applied in many health centres because it is safe, easy and cheaper.

KEYWORDS: Endoscopic assisted surgery, Craniosynostosis, Metopic synostosis

ABBREVIATIONS: EACS: Endoscopic-assisted craniosynostosis surgery, **MAP:** Metopic angle proportion

INTRODUCTION

Craniosynostosis is a clinical condition that occurs after the early ossification of fibrous tissue at the suture line. It occurs in 1 in 2500 live births, and approximately 5-28 % of this is metopic synostosis (12). The rate of metopic synostosis has been increasing in recent years (22). Metopic synostosis is also a classic clinical triad; triangular forehead structure, biparietal enlargement and hypothelorism (1). During metopic synostosis surgery, an orbital advancement and expansion in classical open vault surgery are performed.

In addition, endoscopy-assisted suturectomy, which has become widespread recently, releases the fused suture line and provides advancement and expansion with helmet moulding and brain growth.

Our aim in this article is to contribute to the literature with the 'Metopic Angle Proportion (MAP)' method that we have developed to statistically identify the results of endoscopic assisted surgery in the treatment of metopic synostosis.

Harun DEMIRCI : 0000-0003-2213-5953
Pelin KUZUCU : 0000-0003-0484-3753
Emrah EGEMEN : 0000-0003-4930-4577

Gokcen EMMEZ : 0000-0003-4209-9216
Yunus Emre INCE : 0000-0001-6018-5041
Pınar OZISIK : 0000-0001-5183-8100

■ MATERIAL and METHODS

This study presents follow-up of the stages between the diagnosis and treatment of 43 metopic synostosis patients operated on in a multicenter retrospective study between 2018 and 2021 (Yıldırım Beyazıt University Ethical Committee, Date:12.05.2022, No: 2022-903). Our follow-up period was 1 year each patient. The average duration of helmet use was 8 months. Computed tomography and 3D laser scanning (Starscanner®) method were studied in all patients for diagnostic proof purposes.

The parameters of mean age, mean anesthesia preparation time, mean surgery time, mean amount of bleeding and blood replacement, mean hospital stay, mean follow-up and treatment end times were used in patient follow-ups, gender, diagnosis and surgery.

In our study, we measured the distances between the front contact points of the diagonal diameters and the front center line with a temperature of 30 degrees on the center line according to the concept of the Frontal angle, which was defined by Oi and Matsumoto (16). We named these distances as D1 (right side) and D2 (left side). (The D1 and D2 lines determine the distance between the midpoint and where the diagonal lines cross the frontal bone. Diagonal measurements are virtual lines drawn at a 30-degree angle to the midline. They are used to measure the farthest distance between the frontal and parietal bones and thus to understand asymmetry). Next, we measured the distance between these two edges. We defined this distance as D3 (Figure 1). We developed the formula $D3/((D1+D2)/2)$ based on the theorem of “The Angle of a Triangle Opposite The Longest Side is the Largest Angle”. We called this method ‘Metopic Angle Proportion (MAP)’.

The data were collected in Microsoft Excel (Microsoft Corporation, Redmond, Washington, USA) and analyzed using SPSS version 24.0 (IBM Corporation, Armonk, New York, USA) and Stata 13.1 (StataCorp LLC, College Station,

Texas). Paired samples T-test was performed for statistical results. P value <0.05 was considered statistically significant.

Surgical Procedure

Surgery was performed under general anaesthesia in all patients in the supine and neutral positions. Anesthesia preparation took an average of 30 minutes. The patients were followed up with bispectral index monitoring by anesthesia. A pre-operative prophylactic dose of second-generation cephalosporin was administered. The surgical incision was made just behind the hairline, centred on the midline, with a size of 4 cm. With the endoscopic assisted method, help of scissors and high-speed drill, a posterior 3 cm wide and about 0.7 cm anterior wedge-shaped bone line was excised between the frontonasal suture and the anterior fontanel. Bleeding control was achieved in all patients using a Floseal hemostatic matrix (Baxter, USA). The skin was closed with a primary suture. Postoperative complication did not develop. Patients were discharged with health on average in 40 hours.

■ RESULTS

Forty-three patients operated on between 2018 –2021 were included in this study. There were 6 (14%) female and 37 (86%) male patients. The mean age at admission to the clinic was 1.5-age-months, and the mean age at surgery was 2.8-age-months. Open surgery was recommended for all children over 4-age-months.

Proper vascular access was applied to the patients. Arterial and bispectral index monitoring were used to correlate blood supply and bleeding moments. Anaesthesia preparation was, on average, 30 minutes. The mean operative time was 37 minutes, and intraoperative bleeding was recorded as 30 ml. Dural damage occurred in one patient. The damage was repaired by primary suturing. None of the patients needed intensive care. Blood replacement was performed on average 35 ml.

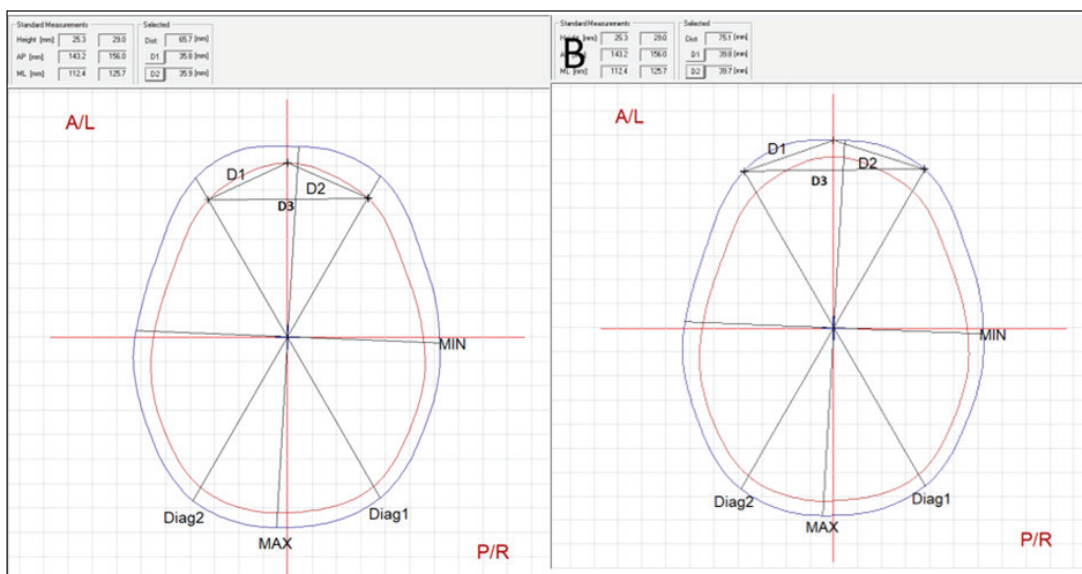


Figure 1: Schematic view of measurements before and after treatment. (Red: pre-treatment, blue: post-treatment). **Min:** Minimum diagonal, **Max:** Maximum diagonal.

Measurements were taken for the helmet moulding on the 7th day after surgery. Day 12 Starband® helmets were put on. All patients underwent laser scanning and photographing at 2-week intervals. All patients were in the normal percentile range in the pre-operative and post-treatment periods. In the Axial2 scans of the patients, the mean pre-op head circumference was 388.3 mm, and the mean post-treatment head circumference was 453.5 mm. The triangle formed between the frontal contact points of the diagonal diameters and the midline, formed with an angle of 30 degrees to the midpoint, can give us some ideas. According to the MAP method; measurements for frontal enlargement, mean pretreatment length D1: 34,57 mm, D2: 34,81 mm, D3: 60,46 mm, and the end of treatment as D1: 37,88 mm, D2: 38,19 mm, D3: 71,09 mm. We performed the formula $D3/((D1+D2)/2)$. While this rate was 1.74 before treatment, it increased to 1.87 after treatment.

This proportional increase shows that the frontal angle also increased. As a result of the statistical analysis, it was determined that there was a significant difference between the ratios made before and after the treatment, and the D3 average was higher after the treatment ($p \leq 0.05$) (Table I) (Figure 2).

DISCUSSION

Cranial deformities are a subject of pediatric neurosurgery that requires sensitive and careful follow-up treatment. Among these, it occupies an important place in metopic synostosis

with an incidence rate of 5-28%. Metopic synostosis is a clinical condition that can be diagnosed by clinical examination. Birgfeld et al, reported that triangular forehead structure, biparietal enlargement, and hypotelorism, which are the classic triads for metopic synostosis, were found in only 14% of patients (1). In the same study, flat frontal bone and narrow-inclined orbit were associated with a higher rate.

Studies have shown that the ratio of trigonocephaly among synostoses is increasing (13,22). The reason for this has not yet been determined. However, there are many studies in which the success achieved with endoscopy-assisted suturectomy and subsequent helmet use is similar or superior to that of open vault surgery.

There is a tendency to non-radiation methods in the diagnosis of trigonocephaly Purnell et al., said that it was determined that the diagnosis was made by clinical examination at a rate of 94%. The same study reported that 35% use calliper measurement, 29% digital photography, 18% laser scanning, and 9.4% 3D photography techniques (19). Open vault surgery is an older and more familiar technique for treating craniosynostosis. In this method, some disadvantages are long surgical time, higher blood loss, the need for intensive care in the post-operative period, and the surgeon's dependence on experience and 3D thinking skills. Jimenez and Barone reported that endoscopic-assisted suturectomy, which is a technique that is becoming increasingly popular today, dramatically reduces or eliminates these disadvantages (9).

Table I: As a Result of the Statistical Analyzes Performed, It was that There was a Significant Difference between the Rates Performed Before and After Treatment

	N	D3/((D1+D2)/2)	S. Deviation	95% confidence interval		Paired Samples T Test	Statistically Significant
				Lower	Upper		
Pre	43	1.74	0.04	-0.14076	-0.11339	-18.741	0.00*
Post	43	1.87	0.03				

* $p \leq 0.05$: statistically significant.

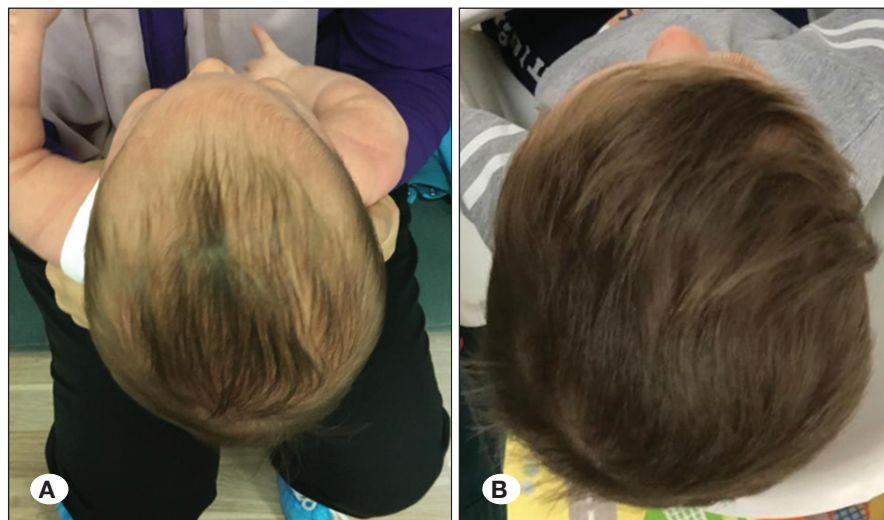

Figure 2: A) A photographic image of a patient with metopic synostosis before treatment. B) Photographic image of the patient with metopic synostosis at the end of treatment (One year later).

Similar to our study, it is more common in males in the literature (9,17). The average surgical age ranges from 2.4 to 4.1 months (6,10,15). In our study, the mean surgical age was found to be 2.8 months. Coleman et al. reported that surgeries performed before the 3rd month for all synostosis patients produced more successful results; They recommended open surgery for patients older than three months (20).

New methods are being developed in the literature that are starting to be used for endoscope-assisted surgery for metopic synostosis (20). Sakar et al. used that STARscanner laser acquisition system for patients' calculations (21). They used bilateral trignons and sellions as external landmarks and they divided into 10 equally distant parallel sections, with section 0 crossing bilateral trignons and the sellion, and section 10 crossing through the vertex. Then they transferred to AutoCAD (Autodesk) all images. They called the area from the midline to each side 90° that the sinusoidal curve (AUC). Elawadly et al. used 9 craniometric parameters using 3dMDhead System (3dMD), M4D scan (Rodin4D, Pessac), or TechMed 3D body scanner (TechMed3D) for calculations (5). They defined the origin of the 3D mesh as the center of all vertices, similar to the published computed cranial focal point. These parameters show the origin point (P.0) and radial vector indicators intersecting the contour at 12 o'clock with the bird's-eye view.

Family stress factor is high in surgeries performed at this age. However, Kim et al. stated that on families, it was determined that the families of patients who underwent endoscopic assisted surgery had less stress (11).

The short surgical time, the absence of the need for intensive care, and the short hospitalization in the post-op period significantly reduce the financial burden (4,23,24). In various studies, the need for blood transfusion has been reported as 10-20% (13,17,24). In addition, the small size of the incision provides an essential advantage in this surgical technique, which also includes aesthetic concerns. For this reason, there is a decrease in the risks of oedema, hyperthermia and infection after surgery (7,9,14).

Pressler et al. said that they found similar results in their articles where they shared the results of 2 years of classical calvarial reconstruction and suturectomy surgeries performed using 3D photography technique (18). Braun et al. reported that endoscopic suturectomy was more advantageous than open surgery in terms of reduced processing time, estimated blood loss, blood transfusion volume, and intensive care unit and hospital stay in 17 patients (2). Ha et al. found that the results of endoscopic assisted suturectomy were superior in all four types of anthropometric measurements performed. The study recommends endoscopic assisted suturectomy with the diagnosis of trigonocephaly in children 6-aged-months and younger (8). In addition, Eastwood et al. showed that endoscopic training could be expanded with the technique they used in their simulator study on trigonocephaly and scaphocephaly (4).

Endoscopy-assisted suturectomy can be applied in many health centres because it is safe, easy and inexpensive (3).

CONCLUSION

In cranial deformity surgery, patients' access to treatment and the results obtained are important. In addition to the fact that endoscopic assisted surgery is more accessible, cheaper and safer than open surgery, this technique should be more widespread in the world due to the success rate of its results, and if possible in the future, the patient should not be left to open surgery.

Ethics approval and consent to participate

The study protocol was approved by the Yıldırım Beyazıt University local ethics committee (2022-903) and We obtained permission from the patient's family to use all the materials for this article and all materials used belong to the archive of our two own clinic in this article.

Funding

This research did not receive any specific grant from funding agencies in the public, commercial, or not-for-profit sectors.

ACKNOWLEDGMENT

We certify that the content of this manuscript, in part or in full, has not been submitted to any other journal in any form, and its publication has been approved by all co-authors.

AUTHORSHIP CONTRIBUTION

Study conception and design: HD, PO

Data collection: EE, GE, YEI

Analysis and interpretation of results: HD

Draft manuscript preparation: HD, PK

Critical revision of the article: HD, PO

Other (study supervision, fundings, materials, etc...): PK, EE, GE

All authors (HD, PK, EE, GE, YEI, PO) reviewed the results and approved the final version of the manuscript.

REFERENCES

1. Birgfeld CB, Saltzman BS, Hing AV, Heike CL, Khanna PC, Gruss JS, Hopper RA: Making the diagnosis: Metopic ridge versus metopic craniosynostosis. *J Craniofac Surg* 24:178-185, 2013. <https://doi.org/10.1097/SCS.0b013e31826683d1>
2. Braun TL, Eisemann BS, Olorunnipa O, Buchanan EP, Monson LA: Safety outcomes in endoscopic versus open repair of metopic craniosynostosis. *J Craniofac Surg* 29:856-860, 2018. <https://doi.org/10.1097/SCS.0000000000004299>
3. Chan JWH, Stewart CL, Stalder MW, St Hilaire H, McBride L, Moses MH: Endoscope-assisted versus open repair of craniosynostosis: A comparison of perioperative cost and risk. *J Craniofac Surg* 24:170-174, 2013. <https://doi.org/10.1097/SCS.0b013e3182646ab8>
4. Eastwood KW, Bodani VP, Haji FA, Looi T, Naguib HE, Drake JM: Development of synthetic simulators for endoscope-assisted repair of metopic and sagittal craniosynostosis. *J Neurosurg Pediatr* 22:128-136, 2018. <https://doi.org/10.3171/2018.2.PEDS18121>

5. Elawadly A, Smith L, Borghi A, Abdelaziz K, Silva A, Dunaway D, Jeelani N, Ong J, James G: Correction of trigonocephaly after endoscopic strip craniectomy with postoperative helmet orthosis therapy: A 3D stereophotogrammetric study. *J Neurosurg Pediatr* 30:68-77, 2022, 2022. <https://doi.org/10.3171/2022.2.PEDS21546>
6. Ersahin Y: Endoscope-assisted repair of metopic synostosis. *Childs Nerv Syst* 29:2195-2199, 2013. <https://doi.org/10.1007/s00381-013-2286-2>
7. Gociman B, Agko M, Blagg R, Garlick J, Kestle JRW, Siddiqi F: Endoscopic-assisted correction of metopic synostosis. *J Craniofac Surg* 24:763-768, 2013. <https://doi.org/10.1097/SCS.0b013e31828696a5>
8. Ha AY, Skolnick GB, Chi D, Nguyen DC, Naidoo SD, Smyth MD, Patel KB: School-aged anthropometric outcomes after endoscopic or open repair of metopic synostosis. *Pediatrics* 146:e20200238, 2020. <https://doi.org/10.1542/peds.2020-0238>
9. Jimenez DF, Barone CM: Early treatment of anterior calvarial craniosynostosis using endoscopic-assisted minimally invasive techniques. *Childs Nerv Syst* 23:1411-1419, 2007. <https://doi.org/10.1007/s00381-007-0467-6>
10. Keshavarzi S, Hayden MG, Ben-Haim S, Meltzer HS, Cohen SR, Levy ML: Variations of endoscopic and open repair of metopic craniosynostosis. *J Craniofac Surg* 20:1439-1444, 2009. <https://doi.org/10.1097/SCS.0b013e3181af1555>
11. Kim D, Pryor LS, Broder K, Gosman A, Breithaupt AD, Meltzer HS, Levy M, Cohen SR: Comparison of open versus minimally invasive craniosynostosis procedures from the perspective of the parent. *J Craniofac Surg* 19:128-131, 2008. <https://doi.org/10.1097/SCS.0b013e31816552fd>
12. Kolar JC: An epidemiological study of nonsyndromal craniosynostoses. *J Craniofac Surg* 22:47-49, 2011. <https://doi.org/10.1097/SCS.0b013e3181f6c2fb>
13. van der Meulen J, van der Hulst R, van Adrichem L, Arnaud E, Chin-Shong D, Duncan C, Habets E, Hinojosa J, Mathijssen I, May P, Morritt D, Nishikawa H, Noons P, Richardson D, Wall S, van der Vlugt J, Renier D: The increase of metopic synostosis: A pan-European observation. *J Craniofac Surg* 20:283-286, 2009. <https://doi.org/10.1097/SCS.0b013e31818436be>
14. Murad GJA, Clayman M, Seagle MB, White S, Perkins LA, Pincus DW: Endoscopic-assisted repair of craniosynostosis. *Neurosurg Focus* 19:E6, 2005. <https://doi.org/10.3171/foc.2005.19.6.7>
15. Nguyen DC, Patel KB, Skolnick GB, Naidoo SD, Huang AH, Smyth MD, Woo AS: Are endoscopic and open treatments of metopic synostosis equivalent in treating trigonocephaly and hypotelorism? *J Craniofac Surg* 26:129-134, 2015. <https://doi.org/10.1097/SCS.0000000000001321>
16. Oi S, Matsumoto S: Trigonocephaly (metopic synostosis). Clinical, surgical and anatomical concepts. *Childs Nerv Syst* 3:259-265, 1987. <https://doi.org/10.1007/BF00271819>
17. Ozlen F, Kafadar AM, Abuzayed B, Ulu MO, Isler C, Dashti R, Erdinler P: Surgical treatment of trigonocephaly: Technique and long-term results in 48 cases. *J Neurosurg Pediatr* 7:300-310, 2011. <https://doi.org/10.3171/2010.12.PEDS10359>
18. Pressler MP, Hallac RR, Geisler EL, Seaward JR, Kane AA: Comparison of head shape outcomes in metopic synostosis using limited strip craniectomy and open vault reconstruction techniques. *Cleft Palate Craniofac J* 58:669-677, 2021. <https://doi.org/10.1177/1055665620969294>
19. Purnell CA, Benz AW, Gosain AK: Assessment of Head Shape by Craniofacial Teams: Structuring Practice Parameters to Optimize Efficiency. *J Craniofac Surg* 26:1808-1811, 2015. <https://doi.org/10.1097/SCS.0000000000001948>
20. Riordan CP, Zurakowski D, Meier PM, Alexopoulos G, Meara JG, Proctor MR, Goobie SM: Minimally invasive endoscopic surgery for infantile craniosynostosis: A longitudinal cohort study. *J Pediatr* 216:142-149.e2, 2020. <https://doi.org/10.1016/j.jpeds.2019.09.037>
21. Sakar M, Haidar H, Sonmez O, Erdogan O, Sacak B, Bayri Y, Dacinar A: A new method for quantification of frontal retrusion and complex skull shape in metopic craniosynostosis: A pilot study of a new outcome measure for endoscopic strip craniectomy. *J Neurosurg Pediatr* 29:650-658, 2022. <https://doi.org/10.3171/2022.1.PEDS21553>
22. Selber J, Reid RR, Chike-Obi CJ, Sutton LN, Zackai EH, McDonald-McGinn D, Sonnad SS, Whitaker LA, Bartlett SP: The changing epidemiologic spectrum of single-suture synostoses. *Plast Reconstr Surg* 122:527-533, 2008. <https://doi.org/10.1097/PRS.0b013e31817d548c>
23. Vogel TW, Woo AS, Kane AA, Patel KB, Naidoo SD, Smyth MD: A comparison of costs associated with endoscope-assisted craniectomy versus open cranial vault repair for infants with sagittal synostosis. *J Neurosurg Pediatr* 13:324-331, 2014. <https://doi.org/10.3171/2013.12.PEDS13320>
24. Zubovic E, Lapidus JB, Skolnick GB, Naidoo SD, Smyth MD, Patel KB: Cost comparison of surgical management of nonsagittal synostosis: Traditional open versus endoscope-assisted techniques. *J Neurosurg Pediatr* 10:1-10, 2020. <https://doi.org/10.3171/2019.11.PEDS19515>