



Retrospective Analysis of Paediatric Glial Tumours that Required Modern Molecular Techniques

Mehmet Arda INAN¹, Betül OGUT¹, Meral TOKER¹, Ozge Nur ARICASOY¹, Ozge VURAL², Pelin KUZUCU³, Aylar POYRAZ¹

¹Gazi University Faculty of Medicine, Department of Pathology, Ankara, Turkey

²Gazi University Faculty of Medicine, Department of Pediatric Oncology, Ankara, Turkey

³Gazi University Faculty of Medicine, Department of Pediatric Neurosurgery, Ankara, Turkey

Corresponding author: Mehmet Arda INAN ✉ ardainan@gazi.edu.tr

ABSTRACT

AIM: To determine if previous histological grading systems were sufficient or unreliable with a limited repository of modern techniques.

MATERIAL and METHODS: The pathology reports of pediatric neurosurgery patients between 2019-2022 were accessed. Data on patients that needed unattainable further molecular investigation were extracted. Data were noted from electronic archives, including their sex, age, histologic grade, location, resection type, survival, and therapy.

RESULTS: Out of 61 surgeries, 17 patients needed further investigation for a proper 2022 World Health Organization (WHO) diagnosis. Seven were deceased, and nine were alive. Two of 10 patients with low-grade gliomas and five of six patients with high-grade gliomas were deceased. Data on one foreign patient with high-grade glioma was inaccessible. The average survival was 9 months for the deceased.

CONCLUSION: Modern molecular techniques such as next-generation sequencing and methylation profiling are the state-of-the-art methods, but it is hard for developing and underdeveloped countries to utilize such methods. The classification schemes, diagnostic key figures, and treatment modalities are developed using these techniques, but the less developed world is incapable of achieving these. We are trying to hybridize the modern and classic modalities, and the results of our study show that for overall survival, there is still not much difference. More economic and feasible techniques should be produced and summarized for the rest of the world.

KEYWORDS: Glioma, Pathology, Molecular, Neuropathology, Pediatrics

ABBREVIATIONS: WHO: World Health Organization, CNS: Central nervous system, NGS: Next generation sequencing, IHC: Immunohistochemistry, PCR: Polymerase chain reaction, FISH: Fluorescence in situ hybridization, USA: United States of America

INTRODUCTION

The use of molecular alterations to aid neuropathology is not new (20). The 2022 World Health Organization (WHO) Classification of Tumors of the Central Nervous System (CNS) extends the modification of the “bluebook” begun with the 2016 edition and modified by the c-IMPACT

papers by the non-official WHO authors (5-7,10,11,14-17). In this latest (fifth) edition, nearly every diagnosis has a signature molecular alteration, which is often seen in the name of the tumor as seen in Figure 1 for the newly designated “Adult type” and “Pediatric type” gliomas (5).

Mehmet Arda INAN : 0000-0002-6179-2828
Betül OGUT : 0000-0002-1385-7324
Meral TOKER : 0000-0002-6008-9217

Ozge Nur ARICASOY : 0000-0002-5818-9120
Ozge VURAL : 0000-0001-7523-7553
Pelin KUZUCU : 0000-0003-0484-3753

Aylar POYRAZ : 0000-0002-3316-3020

<i>Adult-type diffuse gliomas</i>
Astrocytoma, IDH-mutant
Oligodendroglioma, IDH-mutant and 1p/19q-codeleted
Glioblastoma, IDH-wildtype
<i>Paediatric-type diffuse low-grade gliomas</i>
Diffuse astrocytoma, MYB- or MYBL1-altered
Angiocentric glioma
Polymorphous low-grade neuroepithelial tumour of the young
Diffuse low-grade glioma, MAPK pathway-altered
<i>Paediatric-type diffuse high-grade gliomas</i>
Diffuse midline glioma, H3 K27-altered
Diffuse hemispheric glioma, H3 G34-mutant
Diffuse paediatric-type high-grade glioma, H3-wildtype and IDH-wildtype
Infant-type hemispheric glioma

Figure 1: Adult-type and pediatric-type glioma classification according to the 2022 World Health Organization (WHO) classification.

Table I: Examples of Main Molecular Alterations that can be Recognized by Immunohistochemistry, Fluorescence in-situ Hybridization and Sequencing

Technique	Molecular Alteration
Immunohistochemistry	IDH1 R132H, BRAF V600E, H3G34R/V, H3K27M, CTNNB1, SMARCB1 etc.
Fluorescence In-Situ Hybridization	1p/19q codeletion, EGFR amplification, BRAF fusion etc.
Sanger sequencing, polymerase chain reaction	IDH1 / IDH2, EGFR, BRAF mutation etc.

IDH: Isocitrate dehydrogenase, **BRAF:** v-Raf murine sarcoma viral oncogene homolog B, **H3G34R/V:** Histone 3 p.G34R/V, **H3K27M:** Histone 3 p.K28M, **CTNNB1:** Catenin beta 1, **SMARCB1:** SWI/SNF-related matrix-associated actin-dependent regulator of chromatin subfamily B member 1, **EGFR:** Epidermal growth factor receptor.

These signature molecular alterations could be obtained in several ways. Immunohistochemistry (IHC) is a modest but strong and reliable method (9). It can be automated or done manually, by almost anyone with some education, and even “rookie” residents can evaluate it. Modern antibody techniques are based on the corresponding specific mutations that we are seeking, and most of them are surrogate markers. The next, perhaps the first, step into molecular pathology for most laboratories is fluorescence in situ hybridization (FISH). This requires educated staff but no special device. Any pathologist with some training can evaluate it with a microscope modified with fluorescence attachments. Sanger sequencing and polymerase chain reaction tests are further steps which require more attention and education for the staff with specially designed devices and kits. Evaluation requires expertise in molecular pathology. Table I shows examples of molecular alterations that could be evaluated/diagnosed/determined by these rather simple molecular techniques.

Next-generation sequencing (NGS) or methylation profiling are complex procedures that need separately designed laboratories and devices, trained biologists, and registered databanks. Specimen preparation takes days and needs molecular pathology expertise for analysis of the results. Methylation

profiling for brain tumors cannot be done in our country (an upper middle-income country according to World Bank data) at the time of writing this paper.

As a tertiary research and education hospital in a developing country, with a limited modern technique repository, we aimed to determine if our previous histological grading systems were sufficient or unreliable according to up-to-date literature. We can do IHC, FISH, and PCR. NGS was available for a short time, but cost efficiency issues halted its use due to the economic crisis and local health insurance system issues.

■ MATERIAL and METHODS

The pathology reports of pediatric neurosurgery patients between 2019-2022 were accessed and compiled from electronic archives. Records of patients that needed unattainable further molecular investigation were extracted. Data noted included: gender, age, diagnosis, localization, biopsy type, histologic WHO grade according to the WHO 2016 or 2007 classification, essential molecular pathway according to WHO 2022, survival, relapse, and therapy. If there were any available NGS data obtained in subsequent years, it was also noted. Ethics approval was obtained from the local institution on 4

April 2023 with the number of 7. No personal identifying data were collected, and participation did not involve any advantage, disadvantage, or potential harm.

Statistical Analysis

Data were analyzed using Kaplan–Meier’s Test in IBM SPSS Statistics version 26 (Armonk, NY, USA).

RESULTS

A total of 61 pediatric brain surgery specimens was archived in 3 years. Seventeen (28% of the total) patients with glial tumors needed further research. The sex distribution was 6 males (35%), and 11 females (65%). The age range was 1 to 15 years, with an average age of 9 years. The diagnosis was low-grade glioma for 10 (59%), and high-grade glioma for 7 (41%). Histologic grades according to WHO 2007 or 2016 were grade 1, 2 patients (12%); grade 2, 8 (47%); grade 3, 2 (12%); grade 4, 5 (29%). One patient was a foreign patient with paraffin consultation blocks, and further clinic data was unavailable to retrieve from the local or national health system archive. Six (38%) of the tumors were midline lesions and 10 (62%) were cortical. Seven (41%) surgeries ended with a gross total resection, 2 (12%) were subtotal resections, and 4 (23%) were biopsied without resection. Surgical data could not be accessed for 4 (23%) biopsies because they were paraffin consultation blocks and surgical data could not be achieved. Eleven (65%) biopsies needed further investigation of the isocitrate dehydrogenase (IDH) and mitogen-activated protein kinase (MAPK) pathways, while six (35%) biopsies needed H3 and IDH analyses. Nine (53%) patients are alive, and seven (41%) patients have deceased. The average overall survival of patients after diagnosis was 28 months: 32 months

for low and 16 for high grades. Survival by tumor grade was: grade 1: 2 of 2; grade 2: 6 of 8; grade 3: 0 of 2; grade 4: 1 of 5. The survival months after diagnosis for deceased patients were: grade 2: 7 and 20 (median 13.5); grade 3: 8 and 15 (median 11.5); grade 4: 5, 10, 14 (median 10). Three (18%) patients had relapses, four (24%) received chemotherapy, and six (35%) had radiotherapy. The only statistically significant result ($p=0,008$) was the relationship between low or high histological grade and survival. Monthly survival can be seen in Figure 2. The sum of demographic and medical data is presented in Table II.

According to 2022 contracts, the average costs for diagnostic procedures, in relation to local insurance reimbursements are: over 30% for IHC, 18% for FISH, 2.7 times for PCR, and 3 times for NGS.

DISCUSSION

Our intensive review of data from 16 patients showed that the lack of advanced molecular techniques did not adversely affect their survival. Clinic data of the foreign patient was unavailable. Although we have a small number of patients, our results show that morphologically low-grade tumors should not compromise survival. An important point is that some low-grade tumors are in complex anatomical areas and may be unavailable for optimal surgery, but may have targetable mutations. Middle or low-income countries should consume valuable resources prudently, with a careful correlation between cost efficiency and scientific truths. However, patients everywhere in the world should have equal chances for treatment and survival. Low-grade gliomas have good survival rates with proper surgical removal (21). Ryall et al. point out that the era of precision medicine has arrived and targeted an-

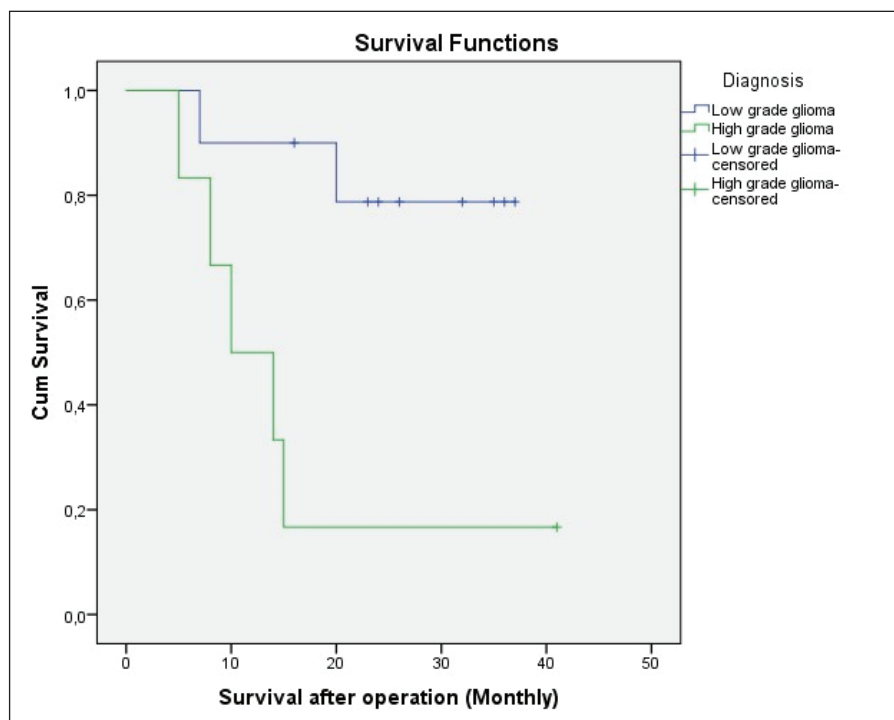


Figure 2: Survival chart of the patients.

Table II: Demographic and Medical Data of Patients Involved in the Study

Sex	Age	Diagnosis	Location	Surgical Resection Grosstotal/ Subtotal/ Biopsy	Absent Molecular Pathway	Histologic WHO Grade (2007/2016)	Alive / Ex	Survival after operation (Monthly)	Relapse	Chemo- therapy	Radio- therapy	Further investigation results
M	1	Low grade glioma	Tectum	Biopsy	IDH and MAPK	1	Alive	23+	No	No	No	
M	3	High grade glioma	Frontal Lobe	Unk.	IDH and MAPK	4	Ex	14	Unk.	Unk.	Unk.	
M	6	Low grade glioma	Frontal Lobe	Biopsy	IDH and MAPK	2	Ex	20	No	Yes	Yes	PTEN, PIK3CA mutant, Olig2 loss (IHC)
F	7	Low grade glioma	Parietal lobe	Grosstotal	IDH and MAPK	2	Alive	16+	Yes	No	Yes	
F	8	Low grade glioma	Parietal lobe	Grosstotal	IDH and MAPK	2	Alive	35+	No	Yes	Yes	
F	9	High grade glioma	Thalamus	Biopsy	H3 and IDH	4	Ex	5	Unk.	Unk.	Unk.	
F	9	Low grade glioma	Thalamus	Unk.	H3 and IDH	2	Ex	7	Unk.	Unk.	Unk.	
F	9	High grade glioma	Parietal lobe	Biopsy	IDH and MAPK	3	Ex	8	Unk.	Unk.	Unk.	
M	10	Low grade glioma	Medulla Oblongata	Subtotal	H3 and IDH	1	Alive	36+	No	No	Yes	
M	11	High grade glioma	Frontal Lobe	Unk.	H3 and IDH	3	Ex	15	Unk.	Unk.	Unk.	
F	12	Low grade glioma	Temporal lobe	Grosstotal	IDH and MAPK	2	Alive	32+	No	No	No	
F	13	Low grade glioma	Mesencephalon	Subtotal	IDH and MAPK	2	Alive	24+	No	No	No	NF1 syndrome
M	13	High grade glioma	Unk.	Unk.	H3 and IDH	4	Unk.	Unk.	Unk.	Unk.	Unk.	Foreign Patient
F	14	High grade glioma	Parietal lobe	Grosstotal	IDH and MAPK	4	Ex	10	Yes	Yes	Yes	
F	14	High grade glioma	Thalamus	Grosstotal	H3 and IDH	4	Alive	41+	Yes	Yes	Yes	H3K27 mutant
F	15	Low grade glioma	Temporal lobe	Grosstotal	IDH and MAPK	2	Alive	26+	No	No	No	
F	15	Low grade glioma	Frontal Lobe	Grosstotal	IDH and MAPK	2	Alive	37+	No	No	No	

IDH: Isocitrate dehydrogenase, **MAPK:** Mitogen-activated protein kinase, **H3:** H3K27 and H3G34 alterations, **IHC:** Immunohistochemistry, **Unk:** Unknown, **Ex:** Exitus.

ti-BRAF drugs or MEK inhibitors are being evaluated in trials, but they also state that these expensive and hard-to-find tests should be applied to chosen patients according to well-chosen schemes (22).

High-grade tumors, on the other hand, still have a high mortality (4,12). New chemotherapy regimens or radiotherapy-associated therapies are not progressing as hoped (21). Midline gliomas have a worse prognosis than cortical tumors. The expected survival of midline gliomas is under 1 year. However, a patient in our study with an H3K27 mutant midline glioma, verified by NGS in subsequent years, is alive in her 4th year. Data on EGFR mutant midline gliomas show promise for targeted therapy (18). Checkpoint inhibitor therapy or immunotherapy is being investigated also for potential modalities (23). Mostly not for therapeutic but for scientific reasons, the underlying pathways of these tumors must be determined. Only by generating enough data can help assigning morphologic, radiologic signatures or creating feasible IHC markers for global use.

Turkey has a sizable young population, but it should be noted that pediatric brain tumors are not a significant proportion of its cancer patients. The latest printed cancer statistics reports from the Health Ministry, for the year 2017 and 2018, shows that 20% of childhood tumors originate in the CNS (1). This statistic is similar in developed countries such as Canada, with 18% (2). The local incidence rate of CNS tumors per 1,000,000 are 29.1-30.5 for boys and 25.8-28.0 for girls (1). The incidence rates according to Ostrom et al. are 58.3 in the USA (19). This difference may be attributed to the accessibility of resources for diagnosis. For 2017 according to the Turkish Statistical Institute, there were 9,769,101 boys and 9,264,387 girls between the ages of 0 to 14 (3). This means only 282 boys and 239 girls, 521 individuals, across the country, were diagnosed with a brain tumor in 2017. This does not fit in the rare cancer definition of the National Cancer Institute of USA, but it must be accepted that it is not as prevalent as lung cancer in adults.

Developing or underdeveloped countries around the world have tried to keep up with advances in diagnostics, but typically NGS or methylation profiling is not applicable (13). Colli et al. represent an alternative approach with basic molecular tests that can provide precision medicine information. They perform IHC, FISH, and Sanger sequencing to gather information (8).

■ CONCLUSION

In developing or under-developed countries, chosen institutions with proper funds, adequate infrastructure, educated staff, and directed patients should be able to do further molecular investigations. Global health standards should be considered with cost efficiency and practicality.

■ ACKNOWLEDGMENT

Local yearly contract costs and fares were obtained from the accountant of the pathology department, who is an author of this paper. Due to the financial confidentiality of the institutions, exact numbers could not be declared.

AUTHORSHIP CONTRIBUTION

Study conception and design: MAI

Data collection: MT, ONA, MAI

Analysis and interpretation of results: BO, MAI

Draft manuscript preparation: AP, OV, PK, MAI

All authors (MAI, BO, MT, ONA, OV, PK, AP) reviewed the results and approved the final version of the manuscript.

■ REFERENCES

1. Turkish Republic Ministry of Health. Available at: <https://hsgm.saglik.gov.tr/tr/kanser-istatistikleri>. Accessed 05.03.2023
2. Canadian Cancer Statistics Advisory Committee, 2019. cancer.ca/Canadian-Cancer-Statistics-2019-EN. Accessed 06.03.2023
3. Turkish Statistical Institute, 2022. Available at: <https://data.tuik.gov.tr/Bulten/Index?p=Istatistiklerle-Cocuk-2021-45633>. Accessed 06.03.2023
4. Bilginer B, Hanalioglu S, Turk CC, Narin F, Oguz KK, Soylemezoglu F, Akalan N: Is the knowledge pertaining to adult glioblastomas enough for pediatric cases? Prognostic factors in childhood. *Turk Neurosurg* 27:279-288, 2017
5. Board WCoTE (2022) Central Nervous System Tumours. International Agency for Research on Cancer. Available at: <https://tumourclassification.iarc.who.int>. Accessed 06.03.2023
6. Brat DJ, Aldape K, Colman H, Figarella-Branger D, Fuller GN, Giannini C, Holland EC, Jenkins RB, Kleinschmidt-DeMasters B, Komori T, Kros JM, Louis DN, McLean C, Perry A, Reifenberger G, Sarkar C, Stupp R, van den Bent MJ, von Deimling A, Weller M: cIMPACT-NOW update 5: Recommended grading criteria and terminologies for IDH-mutant astrocytomas. *Acta Neuropathol* 139:603-608, 2020
7. Brat DJ, Aldape K, Colman H, Holland EC, Louis DN, Jenkins RB, Kleinschmidt-DeMasters BK, Perry A, Reifenberger G, Stupp R, von Deimling A, Weller M: cIMPACT-NOW update 3: Recommended diagnostic criteria for "Diffuse astrocytic glioma, IDH-wildtype, with molecular features of glioblastoma, WHO grade IV". *Acta Neuropathol* 136:805-810, 2018
8. Colli SL, Cardoso N, Massone CA, Cores M, García Lombardi M, De Matteo EN, Lorenzetti MA, Preciado MV: Molecular alterations in the integrated diagnosis of pediatric glial and glioneuronal tumors: A single center experience. *PLoS One* 17:e0266466, 2022
9. Dolen D, Ahmadov T, Dolas I, Unal TC, Aydoseli A, Ozturk M, Sabanci PA, Aras Y, Bilgic MB, Sencer A: Analysis of the prognosis of high-grade gliomas in the view of new immunohistochemistry markers and 2016 WHO classification. *Turk Neurosurg* 32:500-507, 2022
10. Ellison DW, Aldape KD, Capper D, Fouladi M, Gilbert MR, Gilbertson RJ, Hawkins C, Merchant TE, Pajtler K, Venneti S, Louis DN: cIMPACT-NOW update 7: Advancing the molecular classification of ependymal tumors. *Brain Pathol* 30:863-866, 2020
11. Ellison DW, Hawkins C, Jones DTW, Onar-Thomas A, Pfister SM, Reifenberger G, Louis DN: cIMPACT-NOW update 4: Diffuse gliomas characterized by MYB, MYBL1, or FGFR1 alterations or BRAF(V600E) mutation. *Acta Neuropathol* 137:683-687, 2019

12. Kara B, Ertan K, Karabagli P, Karabagli H, Yavas G, Caglayan AO, Koksali Y: Clinical features, treatment and outcome of childhood glial tumors. *Turk Neurosurg* 32:135-142, 2022
13. Kiraz U, Vural C, Turan G, Alparslan B, Dervisoglu E: The value of immunohistochemical methods and preoperative magnetic resonance imaging findings in diagnosis of IDH1 mutant glioblastomas. *Turk Neurosurg* 32:228-236, 2022
14. Louis DN, Giannini C, Capper D, Paulus W, Figarella-Branger D, Lopes MB, Batchelor TT, Cairncross JG, van den Bent M, Wick W, Wesseling P: cIMPACT-NOW update 2: Diagnostic clarifications for diffuse midline glioma, H3 K27M-mutant and diffuse astrocytoma/anaplastic astrocytoma, IDH-mutant. *Acta Neuropathol* 135:639-642, 2018
15. Louis DN, Ohgaki H, Wiestler OD, Cavenee WK: WHO Classification of Tumours of the Central Nervous System. France: International Agency for Research on Cancer, 2016
16. Louis DN, Wesseling P, Aldape K, Brat DJ, Capper D, Cree IA, Eberhart C, Figarella-Branger D, Fouladi M, Fuller GN, Giannini C, Haberler C, Hawkins C, Komori T, Kros JM, Ng HK, Orr BA, Park SH, Paulus W, Perry A, Pietsch T, Reifenberger G, Rosenblum M, Rous B, Sahm F, Sarkar C, Solomon DA, Tabori U, van den Bent MJ, von Deimling A, Weller M, White VA, Ellison DW: cIMPACT-NOW update 6: New entity and diagnostic principle recommendations of the cIMPACT-Utrecht meeting on future CNS tumor classification and grading. *Brain Pathol* 30:844-856, 2020
17. Louis DN, Wesseling P, Paulus W, Giannini C, Batchelor TT, Cairncross JG, Capper D, Figarella-Branger D, Lopes MB, Wick W, van den Bent M: cIMPACT-NOW update 1: Not otherwise specified (NOS) and not elsewhere classified (NEC). *Acta Neuropathol* 135:481-484, 2018
18. Mondal G, Lee JC, Ravindranathan A, Villanueva-Meyer JE, Tran QT, Allen SJ, Barreto J, Gupta R, Doo P, Van Ziffle J, Onodera C, Devine P, Grenert JP, Samuel D, Li R, Metrock LK, Jin LW, Antony R, Alashari M, Cheshier S, Whipple NS, Bruggers C, Raffel C, Gupta N, Kline CN, Reddy A, Banerjee A, Hall MD, Mehta MP, Khatib Z, Maher OM, Brathwaite C, Pekmezci M, Phillips JJ, Bollen AW, Tihan T, Lucas JT Jr, Broniscer A, Berger MS, Perry A, Orr BA, Solomon DA: Pediatric bithalamic gliomas have a distinct epigenetic signature and frequent EGFR exon 20 insertions resulting in potential sensitivity to targeted kinase inhibition. *Acta Neuropathol* 139:1071-1088, 2020
19. Ostrom QT, Patil N, Cioffi G, Waite K, Kruchko C, Barnholtz-Sloan JS: CBTRUS statistical report: Primary brain and other central nervous system tumors diagnosed in the United States in 2013-2017. *Neuro Oncol* 22:iv1-iv96, 2020
20. Pietsch T, Wiestler OD: Molecular neuropathology of astrocytic brain tumors. *J Neurooncol* 35:211-222, 1997
21. Pollack IF, Agnihotri S, Broniscer A: Childhood brain tumors: Current management, biological insights, and future directions: JNSPG 75th Anniversary Invited Review Article. *J Neurosurg Pediatr* 23:261-273, 2019
22. Ryall S, Tabori U, Hawkins C: Pediatric low-grade glioma in the era of molecular diagnostics. *Acta Neuropathol Commun* 8:30, 2020
23. Wang SS, Bandopadhyay P, Jenkins MR: Towards immunotherapy for pediatric brain tumors. *Trends Immunol* 40:748-761, 2019