



Coil Embolization of the Azygos Anterior Cerebral Artery Aneurysm: Three Case Reports

Yuichiro TSUJI^{1,2}, Yuzo KURODA¹, Ryokichi YAGI², Ryo HIRAMATSU², Masahiko WANIBUCHI²

¹Kano General Hospital, Department of Neurosurgery, Osaka, Osaka, Japan

²Osaka Medical and Pharmaceutical University, Department of Neurosurgery, Takatsuki, Osaka, Japan

Corresponding author: Yuichiro TSUJI ✉ abyssinian1225@gmail.com

ABSTRACT

The azygos anterior cerebral artery (ACA) is a rare anatomical anomaly. Clipping surgery has been conducted in approximately 30 reported cases because it is frequently associated with aneurysms. However, few cases in which coil embolization was performed have been reported. We report three cases of coil embolization for distal ACA aneurysms with distal azygos ACA at our institution in 7 years. All patients were over 65-year-old women with saccular aneurysms larger than 7 mm; two with subarachnoid hemorrhage and one with an unruptured aneurysm. No patient had surgical complications associated with coil embolization. Coil embolization is also useful for large aneurysms in the distal azygos ACA, and its indication for treatment could be broadened.

KEYWORDS: Azygos anterior cerebral artery, Saccular aneurysm, Coil embolization

ABBREVIATIONS: **ACA:** Anterior cerebral artery, **SAH:** Subarachnoid hemorrhage, **CTA:** CT angiography, **ICA:** Internal carotid artery, **mRS:** Modified Rankin Scale, **MRI:** Magnetic resonance imaging

INTRODUCTION

The azygos anterior cerebral artery (ACA) is a rare anatomical anomaly with an incidence of 0.4%–1.1% (3,12). Meanwhile, the frequency of azygos ACA complicated by distal ACA has been reported to be high, ranging from 13%–71% (1,2).

Numerous reports regarding clipping surgery for distal ACA aneurysms are associated with azygos ACAs (1). However, few cases in which coil embolization was performed have been reported.

We present three cases of coil embolization for distal ACA aneurysms associated with the distal azygos ACA from 2015 to 2021.

CASE REPORTS

Case 1

A 65-year-old woman arrived at the emergency room with severe headache and vomiting. She had a Glasgow Coma Scale of 10 (E2V3M5). A noncontrast computed tomography (CT) scan of the brain revealed subarachnoid hemorrhage (SAH) and hematoma in the interhemispheric fissure (Figure 1A), and the patient was identified with SAH of the World Federation of Neurosurgical Surgeons (WFNS) Grade 4. CT angiography (CTA) showed an azygos ACA with a saccular aneurysm with a maximum diameter of 9.7 mm at the bifurcation (Figure 1B). Under general anesthesia, a 7Fr Roadmaster (Goodman, Aichi, Japan) was guided to the left internal carotid artery (ICA); then a 4Fr Cerulean G (Medikit, Tokyo, Japan) intermediate catheter was guided to the ICA C2 portion. An Excelsior SL-10 (Stryker, Kalamazoo, MI, USA) was deployed into the aneu-

rysm with CHIAKI 14 (Asahi Intecc, Aichi, Japan). Coil embolization was conducted with five coils using a simple technique (Figure 1C–F). After 3 months of rehabilitation, the patient was discharged with a modified Rankin Scale (mRS) of 1. The patient was followed up for 6 years, and there was no recurrence.

Case 2

A 71-year-old woman with a history of decreased consciousness was admitted to the emergency room. SAH and hematoma in the interhemispheric fissure were discovered on CT of the brain (Figure 2A), and the patient was diagnosed with SAH (WFNS Grade 4). A saccular aneurysm with a maximum diameter of 10 mm located at the azygos ACA bifurcation (Figure 2B). Under general anesthesia, a 7Fr Roadmaster was inserted into the left ICA, two Excelsior SL-10 were guided into the aneurysm using a Traxcess 14 (Terumo, Tokyo, Japan), and coil embolization was performed using the double-catheter

technique (Figure 2C, D). The patient developed symptomatic spasms and was transferred to the hospital with an mRS score of 5.

Case 3

A 72-year-old woman was incidentally diagnosed with an unruptured aneurysm due to dizziness on magnetic resonance imaging (MRI). Magnetic resonance angiography (MRA) of the head revealed a distal ACA aneurysm with a bleb measuring a maximum diameter of 7 mm at the azygos ACA bifurcation (Figure 3A, B). Under general anesthesia, a 7Fr Roadmaster was guided to the left ICA, and a 4Fr Cerulean G was guided to the C2 portion of the ICA as an intermediate catheter. Coil embolization was performed with five coils utilizing a simple technique (Figure 3C, D). The patient was discharged with an mRS score of 0. One year has passed since treatment without recurrence.

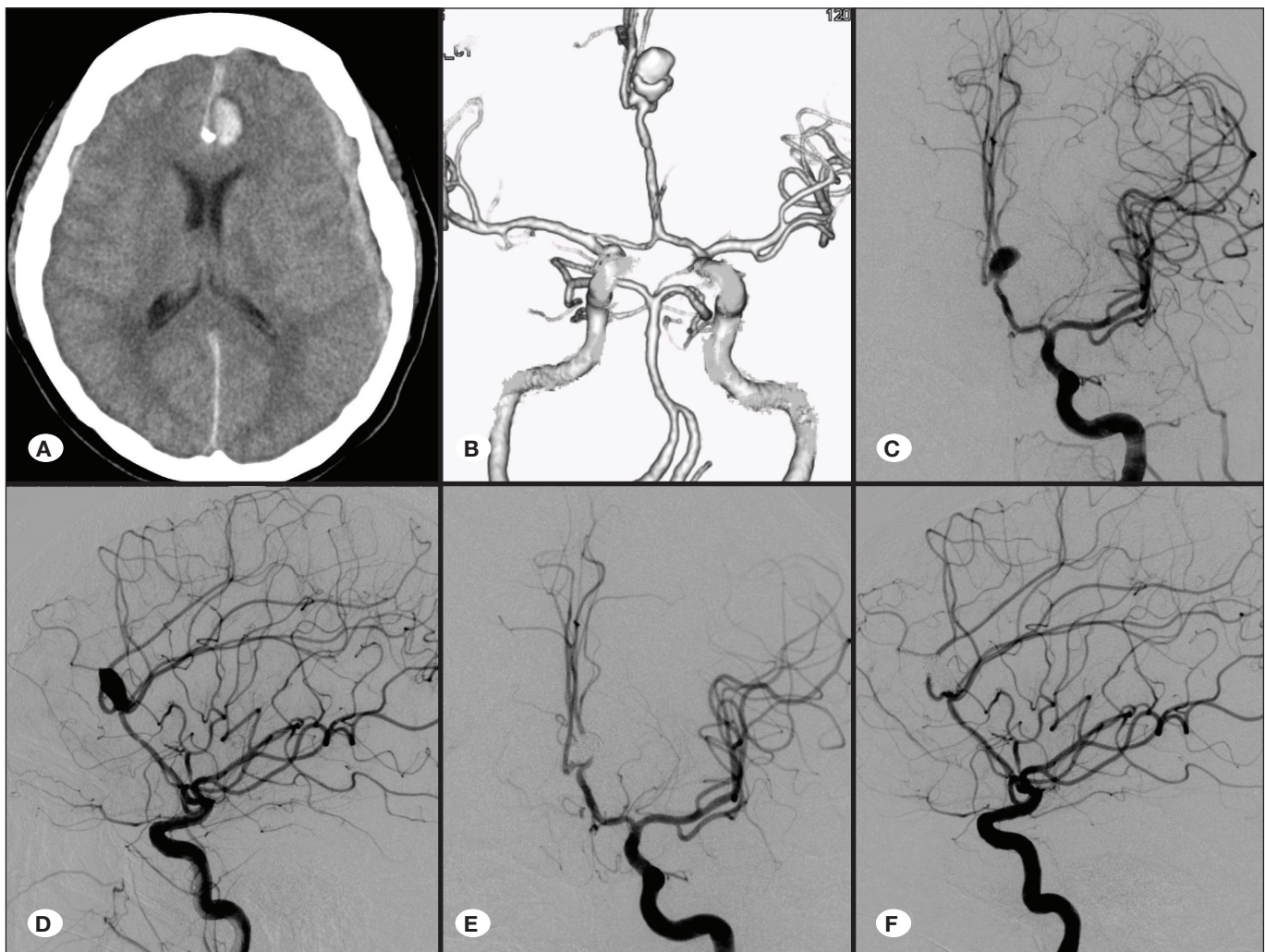


Figure 1: **A)** Plain computed tomography (CT) of the brain revealed a subarachnoid hemorrhage in the interhemispheric fissure with a left frontal hematoma. **B)** CT angiogram of the brain revealed giant, saccular aneurysm at the genu of the corpus callosum. **C,D)** Left internal carotid (ICA) angiograms, anteroposterior view (**C**), and lateral view (**D**) showed the azygos anterior cerebral artery (ACA) and saccular aneurysm at the A2-A3 junction. **E,F)** Left ICA angiograms, anteroposterior view (**E**), and lateral view (**F**) after coil embolization showed complete occlusion of the aneurysm.

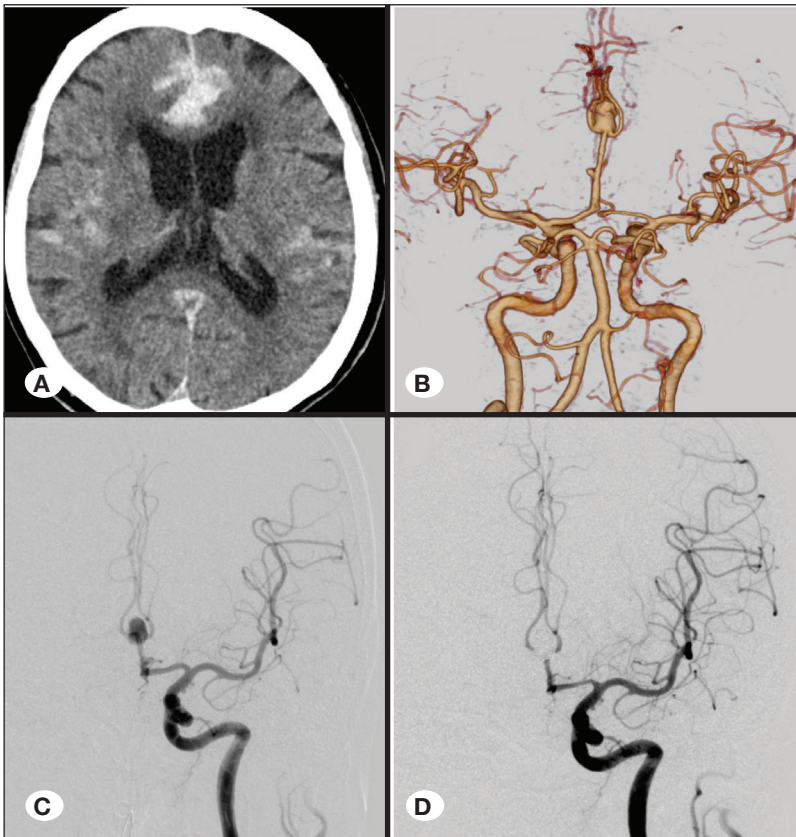


Figure 2: A) Initial CT of the brain showed subarachnoid hemorrhage and hematoma in the interhemispheric fissure. B, C) CT angiography and left ICA angiogram (Anteroposterior view) depicted an azygos ACA and a distal ACA aneurysm. D) Left ICA angiogram after coil embolization showed complete occlusion of the aneurysm.

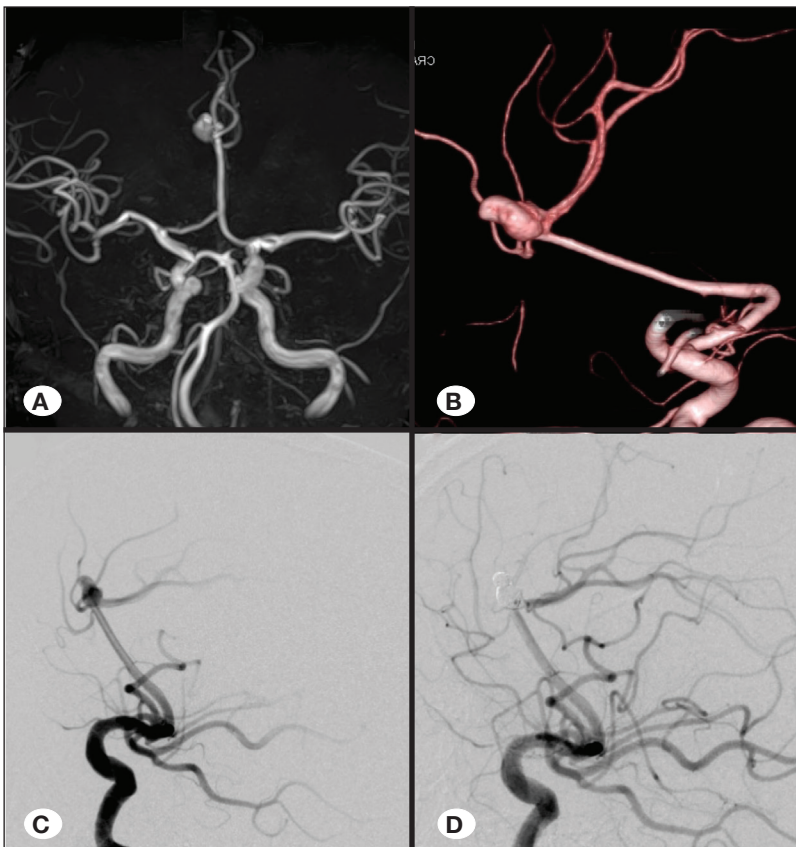


Figure 3: A, B) Magnetic resonance angiography (MRA) and 3D-angiography (A: MRA, B: 3D-angiography) indicate the azygos ACA and the aneurysm, respectively. C) Left ICA angiogram (lateral view) showed azygos ACA and saccular aneurysm. D) Left ICA angiogram after coil embolization revealed occlusion of aneurysm.

Table I: Summary of Previous Reported Cases and the Present Cases

Case	Age, sex	Initial presentation	Dome size	Used technique	Complication	Outcome
Sarikaya et al. (11)	52, F	SAH	1.5 mm	Simple	Nothing	Good
Kaspera et al. (6)	41, M	Incidental	NA	Simple	Nothing	Good
Yamanaka et al. (14)	12, M	Cerebral hemorrhage	9.5 mm	Simple	Nothing	Moderate disabled
Kang H-J et al. (5)	59, F	SAH	8.3 mm	Stent-assisted	Nothing	Good
Maeda et al. (7)	77, F	Incidental	7.0 mm	Double-catheter	Coil migration	Good
Present case 1	65, F	SAH	9.7 mm	Simple	Nothing	Good
Present case 2	71, F	SAH	10.1 mm	Double-catheter	Cerebral vasospasm	Severely disabled
Present case 3	72, F	Incidental	7.0 mm	Simple	Nothing	Good

F: Female; SAH: Subarachnoid hemorrhage; M: Male; NA: not available.

DISCUSSION

Azygos ACA is an uncommon anatomical subtype of the anterior cerebral artery (3,12). In the azygos ACA, the two A1 segments merge to form a single A2 segment (2). Azygos ACAs are commonly linked with distal ACA aneurysms; most are distal to the azygos ACA bifurcation.

Kespera et al. proposed that the vascular geometry at the azygos ACA bifurcation and the sharp backward bending of the pericallosal artery may be responsible for the increased stress on the vessel wall, leading to aneurysm formation (6).

Baldawa et al. reported the results of 32 cases of distal ACA aneurysms associated with azygos ACA between 2000 and 2016 (1). Of these, 29 underwent craniotomy clipping. There are several points to be observed when performing clipping procedures for distal ACA aneurysms. The working space in the aneurysm is narrow, with a broad-based neck; the dome of the aneurysm faces the direction of the surgeon's approach; intraoperative rupture could occur in ruptured cases, and proximal control is difficult (13,15). In ruptured cases, the rate of intraoperative early rupture is reported to be high (10.9%–34.5%), resulting in a poor outcome (9,13). Furthermore, when temporally clipping the proximal part of A2 in the case of aneurysms of the distal part of the azygos ACA, a risk of cerebral infarction exists in the bilateral frontal lobes and corpus callosum (10).

Coil embolization of distal ACA aneurysms takes a long time and is limited by the vessel diameter distal to A2. Therefore, a simple technique is generally used in several cases (8). However, intermediate catheters with high support capability have been guided to the distal ICA and A1 in recent years. Coil embolization with fine microcatheter control has been performed using a simple technique. Even in ruptured cases, the percentage of premature rupture is low, ranging from 0% to 4.9% (4,9). We found five cases where coil embolization was used (5-7,11,14). Table I summarizes previous cases and

the three present cases. Although most aneurysms in the distal azygos ACA have been reported to be small in size in the literature (1,2), all three aneurysms were relatively large, with a maximum diameter of > 7 mm.

Depending on the diameters of A1 and A2, double-catheter treatment using two microcatheters can be considered for wide-neck and large aneurysms.

Except for Case 1, the long-term recurrence rate is unknown. Distal ACA aneurysms tend to have a higher recurrence rate than aneurysms at other sites (8). Furthermore, distal azygos ACA aneurysms may be related to with higher hemodynamic stress than patients without an anomaly (1,6); large aneurysms may be more likely to develop coil compaction. Thus, careful monitoring is required.

CONCLUSION

We have reported three cases of distal ACA aneurysms associated with distal azygos ACA treated with coil embolization. Coil embolization is also effective for large distal azygos ACA aneurysms. We anticipate that treatment indications will expand and more cases will be reported in the future.

Declaration of Conflicting Interest

The authors declared no potential conflicts of interest with respect to the research, authorship, and/or publication of this article.

This study was conducted following the Declaration of Helsinki, and informed consent for publication was obtained from all patients. Our institutional review board approved this study (approval number: 23010, Date; April 25th, 2023).

Funding

The authors received no financial support for the research, authorship, and/or publication of this article.

AUTHORSHIP CONTRIBUTION

Study conception and design: YT, YK, RY, RH, MW

Data collection: YT, RY

Analysis and interpretation of results: YK, RH

Draft manuscript preparation: YT, RY

Critical revision of the article: RH, MW

Other (study supervision, fundings, materials, etc...): RH, MW

All authors (YT, YK, RY, RH, MW) reviewed the results and approved the final version of the manuscript.

REFERENCES

- Baldawa S, Katikar D, Marda S: Giant saccular distal azygos artery aneurysm: Report of a case and review of literature. *Asian J Neurosurg* 11:175, 2016
- Bapuraj JR, Ojili V, Khandelwal N, Kaza RK, Shanbhogue AK, Chhabra R: Case series: Saccular aneurysm of the azygos anterior cerebral artery: Report of 2 cases and review of literature. *Indian J Radiol Imaging* 17:153-155, 2007
- Hashizume K, Nukui H, Horikoshi T, Kaneko M, Fukamachi A: Giant aneurysm of the azygos anterior cerebral artery associated with acute subdural hematoma-case report. *Neurol Med Chir (Tokyo)* 32:693-697, 1992
- Huang Q, Shen J, Xu Y, Liu J: Endovascular treatment of ruptured distal anterior cerebral artery aneurysm. *Neurol India* 58:259-263, 2010
- Kang HJ, Lee YS, Suh SJ, Lee JH, Ryu KY, Kang DG: A ruptured aneurysm at the infraoptic azygous anterior cerebral artery with the contralateral internal carotid artery agenesis treated by Y-stent assisted coil embolization. *J Cerebrovasc Endovasc Neurosurg* 14:237-242, 2012
- Kaspera W, Ladzinski P, Slowinski J, Kopera M, Tomalski W, Slaska: Blood flow velocity in the arteries of the anterior cerebral artery complex in patients with an azygos anterior cerebral artery aneurysm: A transcranial color-coded sonography study. *Clin Neurol Neurosurg* 111:63-68, 2009
- Maeda K, Motoie R, Karashima S, Otsuji R, Ren N, Nagaoka S, Ikai Y, Uno J, Gi H: A case of delayed distal coil migration after coil embolization of an unruptured distal azygos anterior cerebral artery aneurysm: A case report and literature review. *Interv Neuroradiol* 24:643-649, 2018
- Park HS, Kwon SC, Kim MH, Park ES, Sim HB, Lyo IU: Endovascular coil embolization of distal anterior cerebral artery aneurysms: Angiographic and clinical follow-up results. *Neurointervention* 8:87-91, 2013
- Park KY, Kim BM, Lim YC, Chung J, Kim DJ, Joo JY, Huh SK, Kim DI, Lee KC, Lee JW: The role of endovascular treatment for ruptured distal anterior cerebral artery aneurysms: Comparison with microsurgical clipping. *J Neuroimaging* 25: 81-86, 2015
- Rajesh KG, Murthy VS, Varaprasad NV: Aneurysm of azygos anterior cerebral artery: A report of two cases. *Asian J Neurosurg* 11:312, 2016
- Sarikaya B, Oksuz E, Deniz FE, Firat MM: Endovascular treatment of a ruptured aneurysm at a very rare location. Distal azygos anterior cerebral artery. *Interv Neuroradiol* 14: 457-460, 2008
- Schick RM, Rumbaugh CL: Saccular aneurysm of the azygos anterior cerebral artery. *AJNR Am J Neuroradiol* 10:S73, 1989
- Suzuki S, Kurata A, Yamada M, Iwamoto K, Nakahara K, Sato K, Niki J, Sasaki M, Kitahara T, Fujii K, Kan S: Outcomes analysis of ruptured distal anterior cerebral artery aneurysms treated by endosaccular embolization and surgical clipping. *Interv Neuroradiol* 17:49-57, 2011
- Yamanaka K, Ishihara M, Nakajima S, Yamasaki M, Yoshimine T: Coil embolization of a traumatic intracranial aneurysm of the distal part of the azygos anterior cerebral artery followed up for 4 years. *Neurol Med Chir (Tokyo)* 51:572-575, 2011
- Yasargil MG, Carter LP: Saccular aneurysms of the distal anterior cerebral artery. *J Neurosurg* 40:218-223, 1974