



Endovascular Treatment for Ruptured Proximal Anterior Cerebral Artery Dissecting Aneurysm: A Case Series

Jiro AOYAMA¹, Sakyo HIRAI¹, Mariko ISHIKAWA¹, Hirota SAGAWA¹, Kyohei FUJITA¹, Shoko FUJII¹, Tomoyuki NAKANO², Takahiro OGISHIMA², Yohei SATO², Ryosuke SAKAI³, Masataka YOSHIMURA³, Tadahiro ISHIWADA⁴, Kazutaka SUMITA¹

¹Tokyo Medical and Dental University, Department of Endovascular Surgery, Tokyo, Japan

²Japanese Red Cross Musashino Hospital, Department of Neurosurgery, Tokyo, Japan

³Tsuchiura Kyodo General Hospital, Department of Neurosurgery, Ibaraki, Japan

⁴Shioda Memorial Hospital, Department of Neurosurgery, Chiba, Japan

Corresponding author: Kazutaka SUMITA ✉ sumita.nsr@gmail.com

ABSTRACT

Subarachnoid hemorrhage due to the A1 segment of an anterior cerebral artery dissecting aneurysm is rare. Therefore, a standard treatment has not been established. Though several case reports of direct surgery exist, there are few reports on endovascular treatment. This is the first study to describe five patients who underwent endovascular treatment for ruptured A1 dissecting aneurysms. Between January 2001 and December 2022 in our affiliated centers, five cases of SAH-onset A1 dissecting aneurysms were treated with endovascular treatment. We describe in detail two representative cases, briefly summarize the other three, and analyze their complications and outcomes. In the five cases, four were female. Four were in their 50s, and one was in her 80s. The WFNS grades were as follows: three were 2, one was 4, and one was 5. No re-ruptures or symptomatic complications were observed. The modified Rankin Scale scores at the time of discharge were as follows; one was 0, one was 1, two were 2, and one was 5. One in five patients needed retreatment after endovascular trapping because of recanalization. Endovascular treatment may be an effective and viable treatment option for ruptured A1 dissecting aneurysms. Further studies are needed to collect detailed data on complications and outcomes.

KEYWORDS: Subarachnoid hemorrhage, Anterior cerebral artery, Dissecting aneurysm, Endovascular therapy

ABBREVIATIONS: **ACA:** Anterior cerebral artery, **SAH:** Subarachnoid hemorrhage, **VA:** Vertebral artery, **EVT:** Endovascular treatment, **DWI:** Diffusion-weighted imaging, **GCS:** Glasgow coma scale, **CT:** Computed tomography, **CTA:** Computed tomography angiography, **Acom:** Anterior communicating artery, **ICA:** Internal carotid artery, **mRS:** Modified Rankin Scale, **POD:** Postoperative day

INTRODUCTION

An anterior cerebral artery (ACA) dissecting aneurysm is a rare clinical entity (7). It presents with various symptoms including headache, ischemia, and hemorrhage. A previous review of 82 cases of ACA dissecting aneurysms

reported that 55% presented with infarction, 32% with hemorrhage, and 13% with both ischemia and hemorrhage (15). Furthermore, Ohkuma et al. reported that 28.5% of ACA dissecting cerebral aneurysms that occur in subarachnoid hemorrhage (SAH) are located in A1, 28.5% in A2, and 42.9% in A3, suggesting their occurrence in any part of the ACA (13).

Jiro AOYAMA : 0000-0003-1857-3328
Sakyo HIRAI : 0000-0002-3077-1821
Mariko ISHIKAWA : 0000-0003-3918-7338
Hirota SAGAWA : 0000-0002-8476-7721
Kyohei FUJITA : 0000-0002-5240-6884

Shoko FUJII : 0000-0002-0695-4716
Tomoyuki NAKANO : 0000-0003-0933-1714
Takahiro OGISHIMA : 0000-0003-0424-8129
Yohei SATO : 0000-0002-4048-1748
Ryosuke SAKAI : 0000-0002-8838-6264

Masataka YOSHIMURA : 0000-0001-6808-8860
Tadahiro ISHIWADA : 0000-0002-5675-3584
Kazutaka SUMITA : 0000-0002-1348-1099

In the management of ruptured vertebral artery (VA) dissecting aneurysms, surgical treatment to prevent re-rupture is crucial because the risk of re-rupture is high during the first twenty-four hours and the outcome in cases of re-rupture is extremely poor (11). In cases of SAH due to VA dissection, the preferred initial treatment option is endovascular internal trapping (6). Reports indicate that surgery for A2 and more peripherally dissecting lesions of the ACA include clipping, A3-A3 bypass, and stent-assisted coil embolization (14,15). The standard treatment for the ruptured A1 segment of ACA dissecting aneurysms has not yet been established. There have been several case reports of surgical clipping, trapping, or wrapping (2,10,12,13) and a few reports on endovascular treatment (EVT) for A1 dissecting aneurysms. However, the outcomes of direct surgery are not favorable because of re-rupture and infarction of the perforating branch (10,15). In this novel study, we analyze five cases who underwent EVT for ruptured A1 dissecting aneurysms and discuss its clinical utility.

■ CASE REPORTS

Between January 2001 and December 2022, in our affiliated centers, there were five cases of SAH-onset A1 dissecting aneurysms treated with EVT. The age, sex, severity, treatment, timing of surgical intervention, and outcomes are summarized in Table I. High-intensity signals on postoperative diffusion-weighted imaging (DWI) were defined as those occurring in the area dominated by A1. Herein, we describe two representative cases in detail and briefly summarize the other three cases. The ethics committees of the our institution approved this TMDU-NEST registry study (approved number: M2020-102, Tokyo Medical and Dental University Ethics Committee).

Case 1

A 54-year-old patient presented with consciousness disturbance and was admitted to our hospital without any other medical history. On admission, the Glasgow coma scale (GCS) score was 6, and computed tomography (CT) revealed a Fisher grade 3 SAH (Figure 1A). 3D-CT angiography (CTA) revealed a dissecting aneurysm in the fenestrated left A1 segment (Figure 1B). EVT was performed under general anesthesia on the day of admission. The proximal left A1 segment

appeared to be a stenotic dissecting lesion. Therefore, we approached it via the anterior communicating artery (Acom) from the contralateral ACA and performed internal trapping of the left A1 segment dissecting aneurysm (Figure 1C, D). After a bilateral groin puncture, a 4Fr guiding sheath was navigated to the left internal carotid artery (ICA), and a 6 Fr guiding sheath was navigated to the right ICA. We performed internal trapping of the left A1 dissecting aneurysm while preserving the anterograde left ACA blood flow via the unaffected left fenestrated A1 (Figure 1E, F). We had checked the hypothalamic artery by performing super-selective angiography through Acom using a microcatheter during the internal trapping (Figure 1G). DWI on postoperative day (POD) 1 revealed no new ischemic lesions in the ACA territory (Figure 1H). No postoperative re-bleeding or recurrence was observed. The patient was transferred with a modified Rankin Scale (mRS) score of 5 on POD 52 because of initial damage of the SAH and symptomatic cerebral vasospasm.

Case 2

A 55-year-old patient with a medical history of hypertension and multiple renal cysts was admitted to our hospital with a complaint of sudden onset of headache and consciousness disturbance. The GCS score was 13, and CT on admission revealed a Fisher grade 3 SAH (Figure 2A). 3D-CTA and left internal carotid angiogram (ICAG) revealed no significant abnormal vascular lesions (Figure 2B, C). Repeated 3D-CTA performed on day 9 showed a left A1 dissecting aneurysm that was not discovered in the previous angiography (Figure 2D). EVT was performed on day 17. Aspirin (100 mg) was administered the day before the surgery. The right ICAG, under temporary balloon occlusion of the posterior communicating artery segment of the left ICA, depicted good contralateral blood flow through the Acom. Internal trapping of the left A1 segment, including the dissecting aneurysm, was performed (Figure 2E, F). Subsequently, the right ICAG showed good blood flow in both A2 segments (Figure 2G). DWI on POD 1 showed a new ischemic lesion in the left caudal head; however, the patient had no symptoms (Figure 2H).

On POD 56, follow-up cerebral angiography demonstrated recanalization of the occluded A1 segment, which was considered a regrowth of the dissecting aneurysm (Figure 3A),

Table I: Summary Table of Clinical Characteristics of the Case Series with Ruptured A1 Dissecting Aneurysm

Case	Age (years)	Sex	WFNS grade	Time from onset to operation (day)	Contralateral ACA A1	High intense signals on MRI DWI	Re-rupture	mRS at the time of discharge	Retreatment
1	54	female	5	0	yes	no	no	5	no
2	55	female	2	17	yes	yes	no	1	yes
3	83	female	2	6	yes	no	no	2	no
4	54	male	2	18	yes	yes	no	2	no
5	57	female	4	20	yes	no	no	0	no

WFNS: World Federation of Neurosurgical Societies, **ACA:** Anterior cerebral artery, **MRI DWI:** Magnetic resonance imaging Diffusion-Weighted Imaging, **mRS:** modified Rankin Scale.

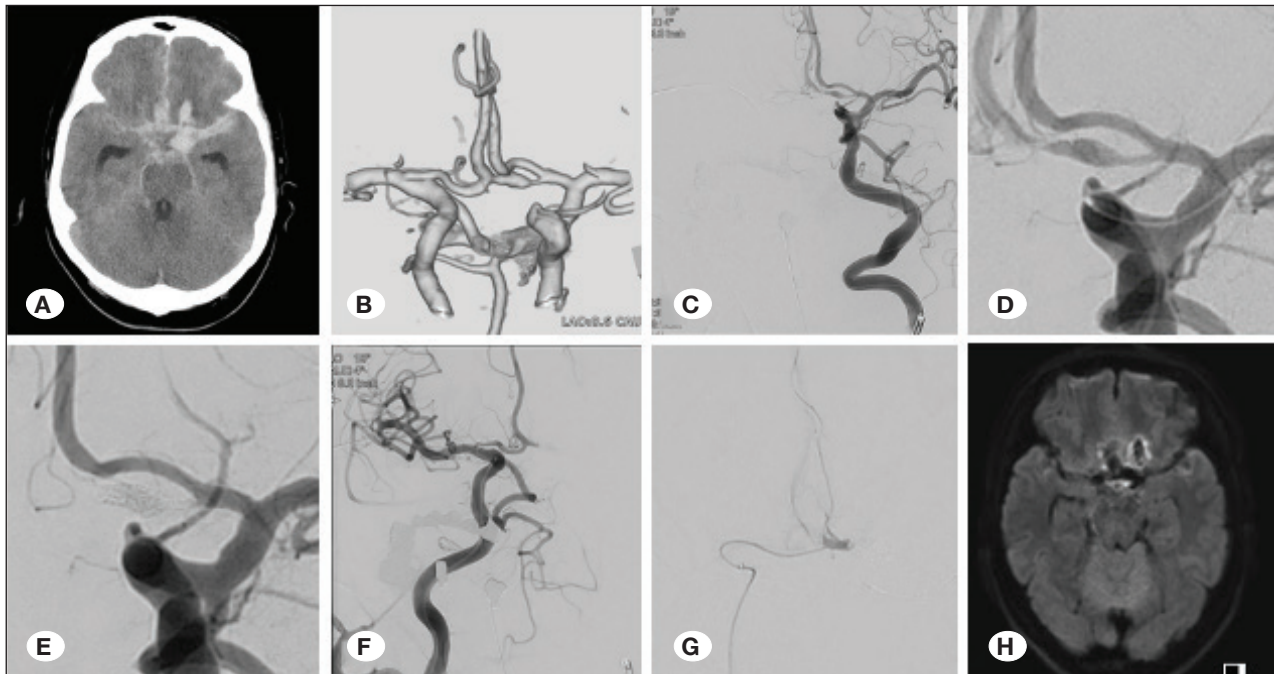


Figure 1: Endovascular trapping in Case 1. **A)** Initial CT shows a diffuse SAH with intracerebral hemorrhage in the left frontal lobe. **B)** CT angiography reveals a dissecting aneurysm in the fenestrated left A1 segment. **C, D)** Anteroposterior view of the left ICAG before endovascular surgery depicts a dissecting aneurysm in the fenestrated left A1 segment. **E, F)** The anteroposterior view of the left and right ICAG displays complete internal trapping of the left A1 dissecting aneurysm while preserving the anterograde left ACA blood flow via the unaffected left fenestrated A1. **G)** Anteroposterior view of the Acom segment angiography using a microcatheter during the internal trapping reveals the patency of the hypothalamic artery. **H)** Diffusion-weighted image on postoperative day 1 discloses no new ischemic lesions in the territory of the ACA.

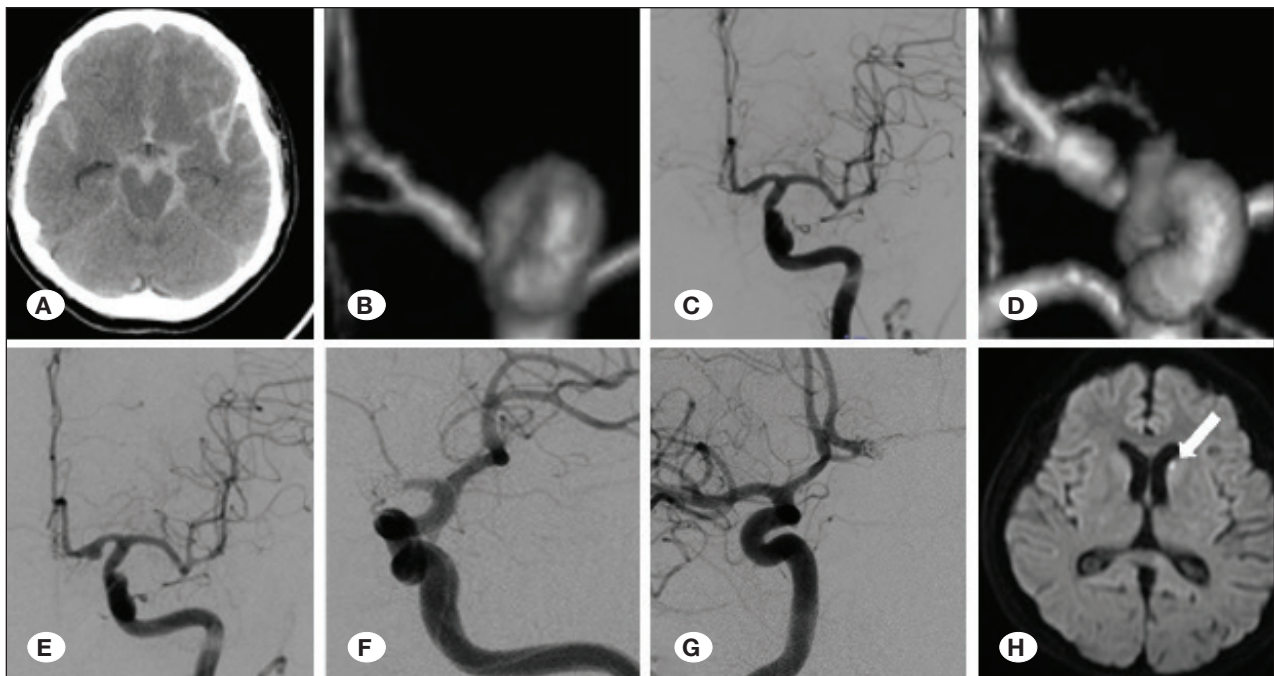

Figure 2: Endovascular trapping in Case 2. **A)** Initial CT reveals a diffuse SAH. **B, C)** Initial CT angiography and Anteroposterior view of the left ICAG show no significant abnormal vascular lesions. **D)** CT angiography performed on day 9 exhibits a left A1 dissecting aneurysm which had not been found in the previous angiography. **E, F)** Anteroposterior view of the left ICAG before and after endovascular trapping of the left A1 dissecting aneurysm. **G)** An anteroposterior view of the right ICAG presents good blood flow of bilateral A2 segments. **G)** Diffusion-weighted image on postoperative day 1 shows a new ischemic lesion in the left caudal head (white arrow).

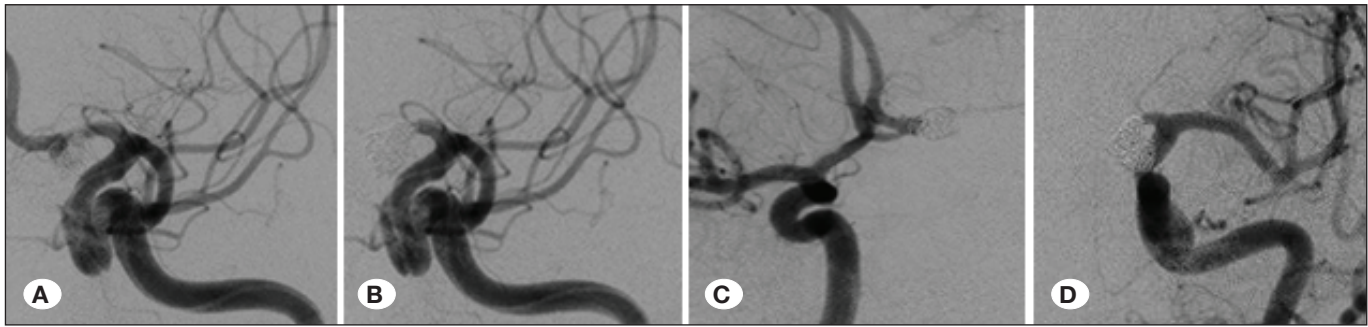


Figure 3: Retreatment in Case 2. **A)** Anteroposterior view of the left ICAG on day 74 discloses recanalization of the left A1 dissecting aneurysm. **B)** Anteroposterior view of the left ICAG after retreatment indicates no blood flow in the dissecting aneurysm. **C, D)** Anteroposterior views of the right and left ICAG on day 80 display no recanalization of the left A1 dissecting aneurysm.

for which an additional embolization procedure was urgently performed (Figure 3B). The postoperative course was good, and follow-up cerebral angiography performed on POD 62 displayed complete occlusion of the left A1 dissecting aneurysm (Figure 3C, D). The patient was discharged with an mRS score of 1.

Cases 3-5

The clinical characteristics of Cases 3, 4, and 5 are shown in Table I. The internal trappings of the A1 segment with EVT were performed from the affected side of the ICA in Cases 3 and 4. In Case 5, the internal trappings of the A1 segment with EVT were performed from the A1 on the unaffected side through Acom. This was because the ICA and middle cerebral artery on the affected side were covered with a flow-diverter stent that had been used to treat ICA C2 unruptured aneurysm previously. DWI on POD 1 revealed no new ischemic lesions in the ACA territory in Cases 3 and 5. However, DWI on POD 1 revealed a new ischemic lesion in the caudal head in Case 4. Moreover, there were no symptomatic complications in all three cases. The patients were discharged with no postoperative re-bleedings or recurrences.

DISCUSSION

Dissecting aneurysms of the A1 segment have rare pathologies (2). It has been reported that more than 80% of dissecting cerebral aneurysms localized in the A1 were SAH and were significantly common in female (12). In most cases, though dissection of A1 with SAH requires early treatment, it is difficult to treat (2,10,15). Although the pearl-and-string sign and tapered occlusion are typical imaging findings of dissecting aneurysms, arriving at the diagnosis of A1 dissecting aneurysms is often challenging (4). In two of the five cases in this study, dissecting aneurysms in the A1 segments were not diagnosed on the initial imaging, however, repeated imaging studies aided its identification.

Certain reports establish EVT for ruptured dissecting aneurysms in the A2 segment (4,5,14). Inoue et al. recommended endovascular trapping of the A2 dissection if an infarction was detected in the affected ACA area (5). However, there have been few reports on acute endovascular surgery for ruptured A1 dissecting aneurysms. In our study, EVT of ruptured dis-

secting aneurysms localized in A1 resulted in favorable outcomes without re-rupture (Table I). A favorable outcome (mRS 0–2) was obtained in four cases (80%), except for one case, which was WFNS grade 5.

There are two major concerns regarding the EVT of A1 dissecting aneurysms in the A1 segment. First, there is a risk of ischemic complications, such as perforator occlusion or cerebral infarction in the affected ACA area. The A1 segment has perforators, such as the recurrent artery of Heubner or the medial lenticulostriate artery (16). In the proximal A1 segment, most aneurysms had no perforator branching on cerebral angiography (1,8). However, the possibility of cerebral infarction in the A2-A3 territory exists. Hino et al. reported that a patent A1 vessel should be preserved or recreated if the Acom is incompetent (3). All five patients had the Acom and contralateral A1 segment. Hence, there were no ischemic complications in the A2-A3 territory. Further, it is important to examine the cross flow through the contralateral A1 by performing a balloon test occlusion. Mitsuhashi et al. reported three cases of ruptured A1 segment dissecting aneurysms (10). Although the clinical outcome was poor, they suggested the advantages of direct surgery over EVT in terms of an accurate identification of the perforating branch and the dissection extent. However, other reports indicate re-rupture of dissecting aneurysms after direct surgery (15). On the other hand, Lv et al. reported that endovascular trapping may be a safe and effective treatment option if the Acom complex is competent (9). Considering these data, since there are no large-scale studies at present, it is necessary to select an appropriate procedure by paying attention to the perforator veins in each case. Second, recanalization may have occurred after endovascular occlusion of the A1 segment. Although clipping both the proximal and distal A1 segments is the most reliable method for complete occlusion, sufficient intraoperative observation is difficult in cases of SAH without damage to the branch. The A1 segment has a shorter distance than dissecting aneurysms in the posterior circulation. Previously, it was difficult to obtain complete occlusion by EVT. However, the recent development of catheters and small-diameter soft coils has enabled effective embolization over short distances. With the development of cerebral angiography, the identification of perforating branches is easier. This explains the safety and

effectiveness of EVT. However, one of the five patients in our case series underwent retreatment because of recanalization, suggesting that close postoperative follow-up is important.

This study had several limitations. First, this was a retrospective and observational study. Therefore, there may exist a selection bias in which patients who were likely to achieve a favorable outcome were frequently enrolled in the study. Second, the current study did not compare the outcomes between clipping and EVT as data from contemporaneous craniotomies were unavailable. In this study, endovascular surgeries were achievable because the contralateral A1 segment was identified in all patients. However, in patients where the contralateral A1 segment was poor, bypass and trapping may be significant.

CONCLUSION

EVT for ruptured A1 dissecting aneurysms may be effective and feasible if collateral flow occurs via the Acom. Further studies are needed to collect detailed data on complications and outcomes.

AUTHORSHIP CONTRIBUTION

Study conception and design: JA, KS

Data collection: JA, TN, TO, YS, RS, MY, TI

Analysis and interpretation of results: JA, KS

Draft manuscript preparation: JA, SH, KS

Critical revision of the article: JA, SH, MI, HS, KF, SF

Other (study supervision, fundings, materials, etc.): JA

All authors (JA, SH, MI, HS, KF, SF, TN, TO, YS, RS, MY, TI, KS) reviewed the results and approved the final version of the manuscript.

REFERENCES

1. Cho YD, Ahn JH, Jung SC, Kim CH, Kang HS, Kim JE, Son YJ, Han MH: Coil embolization in precommunicating (A1) segment aneurysms of anterior cerebral artery. *Neuroradiology* 56:219-225, 2014. <https://doi.org/10.1007/s00234-014-1319-1>
2. Dzhindzhikhadze R, Polyakov A, Dreval O, Lazarev V: Successful microsurgical clipping of ruptured fusiform aneurysm of the anterior cerebral artery. Case report and review of the literature. *Surg Neurol Int* 11:445, 2020. https://doi.org/10.25259/SNI_727_2020
3. Hino A, Fujimoto M, Iwamoto Y, Oka H, Echigo T: Surgery of proximal anterior cerebral artery aneurysms. *Acta Neurochir (Wien)* 144:1291-1296; discussion 1296, 2002. <https://doi.org/10.1007/s00701-002-1014-6>
4. Im TS, Lee YS, Suh SJ, Lee JH, Ryu KY, Kang DG: Two cases of subarachnoid hemorrhage from spontaneous anterior cerebral artery dissection: A case of simultaneous hemorrhage and ischemia without aneurysmal formation and another case of hemorrhage with aneurysmal formation. *J Cerebrovasc Endovasc Neurosurg* 16:119-124, 2014. <https://doi.org/10.7461/jcen.2014.16.2.119>
5. Inoue T, Fujimura M, Matsumoto Y, Kondo R, Inoue T, Shimizu H, Tominaga T: Simultaneous occurrence of subarachnoid hemorrhage and cerebral infarction caused by anterior cerebral artery dissection treated by endovascular trapping. *Neurol Med Chir (Tokyo)* 50:574-577, 2010. <https://doi.org/10.2176/nmc.50.574>
6. Katsuno M, Matsuno A: Aneurysm trapping by both direct and endovascular surgery for vertebral artery dissection: A case report. *Surg Neurol Int* 16:9-10, 2018. https://doi.org/10.4103/sni.sni_382_17
7. Lehecka M, Lehto H, Niemela M: Distal anterior cerebral artery aneurysms: Treatment and outcome analysis of 501 patients. *Neurosurgery* 62:590-601, 2008. <https://doi.org/10.1227/01.neu.0000317307.16332.03>
8. Lubicz B, Lefranc F, Levivier M, Dewitte O, Pirotte B, Brotchi J, Balériaux D: Endovascular treatment of intracranial aneurysms with a branch arising from the sac. *AJNR Am J Neuroradiol* 27:142-147, 2006
9. Lv X, Li Y, Jiang C, Jiang P, Wu Z: Dissecting aneurysm at the proximal anterior cerebral artery treated by parent artery occlusion. *Interv Neuroradiol* 15:123-126, 2009. <https://doi.org/10.1177/159101990901500121>
10. Mitsuhara T, Ikawa F, Hidaka T, Kurokawa Y, Yonezawa U: Ruptured dissecting aneurysms of the A1 segment of the anterior cerebral artery: Three case reports and a review of the literature. *Neurosurg Rev* 41:409-414, 2018. <https://doi.org/10.1007/s10143-017-0841-0>
11. Mizutani T, Aruga T, Kirino T, Miki Y, Saito I, Tsuchida T: Recurrent subarachnoid hemorrhage from untreated ruptured vertebrobasilar dissecting aneurysms. *Neurosurgery* 36:905-913, 1995. <https://doi.org/10.1097/00006123-199505000-00003>
12. Nakajima M, Fuse I, Tsuji K, Nozaki K: Anterior cerebral artery dissecting aneurysm presenting subarachnoid hemorrhage. A case report and review of the literature. *Surg Cereb Stroke (Jpn)* 37:128-132, 2009. <https://doi.org/10.2335/scs.37.128>
13. Ohkuma H, Suzuki S, Kikkawa T, Shimamura N: Neuroradiologic and clinical features of arterial dissection of the anterior cerebral artery. *AJNR Am J Neuroradiol* 24:691-699, 2003
14. Takahashi Y, Endo H, Endo T, Fujimura M, Niizuma K, Tominaga T: Patient with recurrent anterior cerebral artery dissecting aneurysm after stent-assisted coil embolization successfully treated with A3-A3 anastomosis. *World Neurosurg* 109:77-81, 2018. <https://doi.org/10.1016/j.wneu.2017.09.128>
15. Uozumi Y, Katoh H, Tsuzuki N, Toyooka T, Miyazawa T, Nawashiro H, Shima K: Revascularization for anterior cerebral artery dissecting aneurysms-three case reports. *Neurol Med Chir (Tokyo)* 50:49-53, 2010. <https://doi.org/10.2176/nmc.50.49>
16. Wanibuchi M, Kurokawa Y, Ishiguro M, Fujishige M, Inaba K: Characteristics of aneurysms arising from the horizontal portion of the anterior cerebral artery. *Surg Neurol* 55:148-155, 2001. [https://doi.org/10.1016/S0090-3019\(01\)00396-2](https://doi.org/10.1016/S0090-3019(01)00396-2)