



# Relationship Between Brain Tumors and Intracranial Aneurysms: A Systematic Review

Pedro Henrique Mouty RABELLO<sup>1</sup>, Nicollas Nunes RABELO<sup>1</sup>, João Paulo Mota TELLES<sup>2</sup>, Eberval Gadelha FIGUEIREDO<sup>1</sup>

<sup>1</sup>University of Sao Paulo, Department of Neurosurgery, Sao Paulo, Brazil

<sup>2</sup>University of Sao Paulo, Department of Neurology, Sao Paulo, Brazil

**Corresponding author:** Nicollas Nunes RABELO ✉ nicollasrabelo@hotmail.com

## ABSTRACT

**AIM:** To investigate the possible relationship between intracranial aneurysms and brain neoplasms.

**MATERIAL and METHODS:** A comprehensive literature review involving a search of the databases PubMed and Embase to identify relevant articles was conducted in March 2021. The initial search retrieved 451 articles. After deduplication and screening of abstracts, 56 articles were selected. After reading of the full texts, 19 articles were included in the review.

**RESULTS:** There insufficient evidence to support that people with brain neoplasms have a higher incidence rate of IAs. However, the prevalence of IAs appears to be higher in patients with pituitary tumors than in the general population. The key factors affecting prognosis were tumor type in patients with unruptured aneurysms and progression of subarachnoid hemorrhage in individuals with ruptured aneurysms. Treatment should be individualized according to patient age, tumor pathology, location, and aneurysm rupture risk.

**CONCLUSION:** There is a lack of evidence to affirm that the existence of brain neoplasm plays a role in the formation and rupture of intracranial aneurysms. Additionally, there is insufficient evidence to confirm a greater prevalence of intracranial aneurysms in individuals with brain tumors. The association of these two disorders does not appear to worsen patient outcome. Prognosis depends on tumor pathology for malignant cases and on subarachnoid hemorrhage in patients with ruptured aneurysms.

**KEYWORDS:** Intracranial aneurysm, Brain Neoplasms, Prognosis, Therapeutics, Neurosurgery

**ABBREVIATIONS:** IA: Intracranial aneurysm, IAs: Intracranial aneurysms

## INTRODUCTION

Brain neoplasms and intracranial aneurysms (IAs) are frequent in neurosurgical routine practice, but their coexistence is estimated at only 0.7–5.4% (16,19). However, this incidence rate may be underestimated because of the low rate of detection of digital subtraction angiography (DSA) performed before surgery (10,19). Nevertheless, the frequency of incidental tumor or aneurysm findings has increased with the growing use of sophisticated neuroimaging techniques, such as computed tomography and magnetic resonance angiography (13,16).

The most common neoplasms found in patients with co-occurring brain neoplasms and IAs are shown in Table I.

The correlation between brain neoplasms and intracranial aneurysms has been the subject of extensive debate. However, the current literature is inconclusive as to whether a causal relationship exists between these two entities. Furthermore, treatment strategies for managing this association have yet to be established (8).

Thus, given the relevance and complexity of the interaction between these two pathologies, it is important to investigate

**Table I:** Tumors Most Commonly Found in Association with Intracranial Aneurysms

Author	Incidence
Suslu and Bozbuga (16)	Meningioma (29.3-44%), glioma (27.5-38%), pituitary adenoma (11-20.6%), lymphoma, craniopharyngioma, chordoma, epidermoid tumor, dermoid tumor, and choroid plexus adenoma
Lee et al. (8)	Meningioma, followed by astrocytic or oligodendroglial tumors
Zhong et al. (19)	Meningioma, pituitary adenoma, neuroepithelial tumor and metastatic tumor
Licata et al. (9)	Meningioma and glioma
Spitler et al. (13)	Meningioma, pituitary tumor and glioma

how they are related, whether this potential interaction worsens patient prognosis, and how treatment should be planned and conducted. Therefore, the objective of the present study was to carry out a systematic review of studies exploring the relationship between brain neoplasms and intracranial aneurysms.

## ■ MATERIAL and METHODS

A systematic review of the literature was conducted by searching the PubMed and Embase databases in March 2021 using the following search terms:

PubMed: ((intracranial aneurysms[MeSH Terms]) OR (intracranial aneurysm[MeSH Terms])) AND ((aneurysmal rupture) OR (aneurysmal subarachnoid hemorrhage[MeSH Terms])) AND (brain tumors[MeSH Terms]).

Embase: ('intracranial aneurysm'/exp OR 'intracranial aneurysm' OR 'intracranial aneurysms') AND ('brain tumors'/exp OR 'brain tumors' OR 'brain tumor'/exp OR 'brain tumor') AND ('subarachnoid hemorrhage'/exp OR 'subarachnoid hemorrhage').

Additional studies drawn from the references of the articles retrieved in the primary search were also assessed. The initial search led to the retrieval of 451 articles. After removal of duplicate records and screening of abstracts, 56 articles were selected for full reading. A final total of 19 articles were included in the review study (Figure 1).

### Inclusion and Exclusion Criteria

Articles in English or Portuguese that reported intracranial aneurysms (ruptured or unruptured) co-occurring with brain tumors were included. Studies that were in other languages, had significant missing clinical data or irrelevant information, and duplicate publications, were excluded.

## ■ RESULTS

Due to the low incidence and complicated nature of this association, it was unclear whether brain neoplasms contribute to the development and rupture of IAs and in the manner in which this might occur. The relationship between neoplasms and aneurysms remains speculative in all cases (10,16).

The overall prevalence of unruptured IAs was approximately 2-4% (15,18). There is insufficient evidence to affirm that intracranial aneurysms are more common in patients with brain neoplasms (9,16,19).

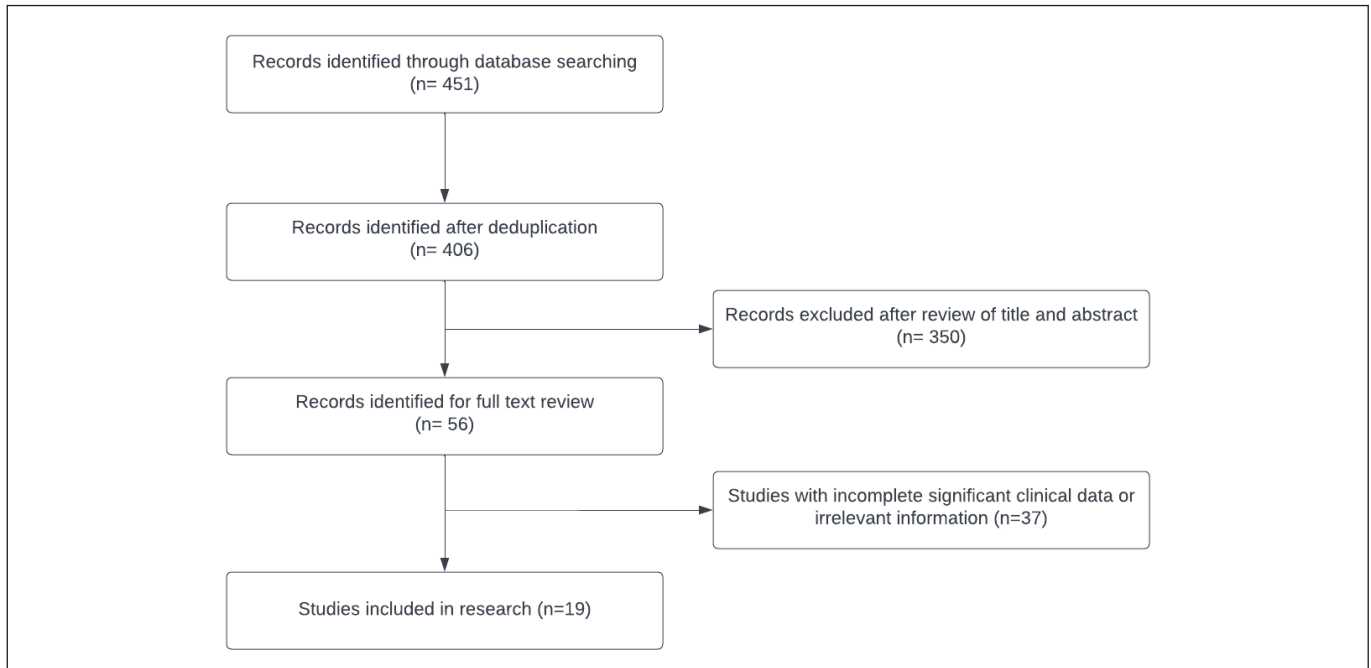
On the other hand, intracranial aneurysms appear to be more frequent in individuals with pituitary tumors than in the general population (incidence range 0.5-7.4%) and were more frequently observed in pituitary tumor cases (2,5,12). According to one of the studies reviewed, the incidence of pituitary tumor alone in the national database (14.1%) was lower than the prevalence of pituitary tumors concomitant with aneurysms (34.2%) (13).

Incidental aneurysm detection is more frequent in individuals with meningiomas, pituitary adenomas or gliomas. This may explain the factors that cause aneurysms in acromegalic individuals to form, grow, and rupture. Nevertheless, there is insufficient evidence associating aneurysms with glioma or meningioma (13).

In order to explore the likelihood of a causal angiogenic link between glioma and aneurysm, a methodical approach and a significant number of case studies are required. Until this information becomes available, any link between glioma and aneurysm can only be interpreted as a chance finding (13).

Regarding prognosis, the main contributing factors included neoplasm pathology in cases of unruptured aneurysms and the development of subarachnoid hemorrhage in cases of ruptured aneurysms. Deaths resulted predominantly from malignant neoplasm progression. The most significant prognostic variables were the location and nature of the neoplasm. The cooccurrence of neoplasm and aneurysm did not appear to worsen the outcome (1,9,16). With regard to clinical symptoms, these were generally secondary to the neoplasm (1,16,19).

There is no consensus on the management of patients with both brain neoplasm and intracranial aneurysm, where treatment must be individualized according to patient age, neoplasm pathology, aneurysm location, and rupture risk.



**Figure 1:** Flow diagram of literature search and screening.

## ■ DISCUSSION

It is known that the size, precise location and form of cerebral aneurysms determine their natural history. Brain aneurysms measuring greater than 7 mm in the anterior communicating or internal-posterior carotid artery are associated with a high probability of rupture (17).

One of the factors potentially influencing the development of brain aneurysms associated with brain neoplasms is mechanical change. The microanatomical changes in cerebral circulation promoted by tumor progression, resulting in compression or traction and consequent blood flow changes, lead to an increase in hemodynamic stress and the development of aneurysms (2). Aneurysm growth and rupture have similar risk factors, where development of an aneurysm has also been associated with risk of rupture (15).

Growth hormone and associated growth factors may also be involved in the development of aneurysms (2). Jakubowski and Kendall examined 150 pituitary tumors and found that adenoma cases which produced growth hormone were more likely to develop intracranial aneurysms (6). This might be explained by the fact that increased production of growth hormone can result in hypertension and atherosclerosis which, in turn, can lead to weak vessel walls and aneurysm dilatation. Furthermore, penetration of arterial walls by neoplasm cells can cause aneurysms to develop (1,7).

Neoplasm infiltration of the aneurysm wall indicates a causal link involving tumor growth and aneurysm formation in aneurysms located within or around brain neoplasms. The neoplasm histology is associated with the formation of aneurysm due to neoplasm invasion. Invasion of the vascular wall by neoplasms may occur in pituitary tumors, lymphomas

and glial tumors, but is not described in meningiomas. Aneurysms can also form as part of an inflammatory process, as seen in epidermoid and dermoid tumors (16).

The possible pathophysiology between gliomas and intracranial aneurysms involves the dissemination of widespread coagulopathy, necrotic neovasculature or neoplastic infiltration of developing cerebral arteries. Additionally, it has been hypothesized that greater blood supply to these neoplasms leads to secondary alterations in the vessel wall, which might contribute to the development of intracranial aneurysms. Lastly, the shunt of blood flow inside the tumor could cause aneurysms to develop (1).

Pia et al. suggested that vascular meningioma may increase blood flow in the supplying artery and promote the development of intracranial aneurysms (11). This hypothesis, however, fails to clarify how aneurysms develop on the opposite side (19).

The rupture rate of intracranial aneurysms associated with previous skull base lesions (including pituitary adenomas) is not well described in the available literature, however, the rate does not appear to differ significantly from unruptured intracranial aneurysms at other sites (12).

### Treatment

Patients with coexisting brain neoplasm and intracranial aneurysm need special treatment to avoid complications. Treatment should be guided according to the condition of the neoplasm and aneurysm, their locations, and type of neoplasm. It is crucial to diagnose the coexistence of both pathologies, as a subarachnoid hemorrhage produced by an undiscovered aneurysm may occur during or after surgery. (19).

There are several reported situations of aneurysm following surgical removal of brain neoplasms. This phenomenon suggests that decompressive tumor resection may increase the risk of aneurysm rupture (8).

Before performing elective intracranial surgery, treatment of unruptured aneurysms (by clipping or endovascular therapy) should be considered given their low morbidity (4). It should be noted that, although endovascular techniques may lower immediate risk, the future danger and longevity of the procedure remain unknown, requiring further investigation (3).

Zhong et al. recommend endovascular IA embolization followed by tumor resection if the aneurysm is involved in the brain neoplasm (19).

Licata et al. proposed that the tumor can be removed without risk of aneurysm rupture and that these lesions should be treated together in the same operation whenever possible (1). On the other hand, it was argued that, when a single surgical approach is not feasible, the lesion causing the symptoms should be addressed first (9, 16).

Before attempting tumor resection in situations when the neoplasm is distal from the aneurysm, clipping or endovascular therapy may be tried to prevent destabilizing the aneurysm. When an incidental aneurysm is large, in danger of rupture, and amenable endovascular or microsurgical therapy, it should be repaired prior to the tumor (13).

Regarding the treatment of IAs coexisting with pituitary adenoma, the aneurysm should be treated first (2,4,12,14). The endovascular procedure to treat the aneurysm should be performed before the transsphenoidal surgery, especially in unruptured aneurysms, in order to reduce the risk involved with the proximity between aneurysms and adenoma (2).

Lee HS, Park W, Kim YH, Park JC, Ahn J, and Kim JH recommend perioperative repair of aneurysms, especially when these have a blood-flow relationship (flow-related) with oligodendroglial or astrocytic tumors (8). In the study, when both tumor and aneurysm were situated in the same brain hemisphere, clipping of the aneurysm was performed during tumor resection. Aneurysms were treated prior to tumor resection when deemed at high risk of rupture and when the neoplasm was benign according to World Health Organization classification.

It is unclear whether patients with both IAs and malignant gliomas should be given specific treatment. As a rule, the lesion exhibiting the greatest symptoms should be managed first (1).

Turan Suslu and Bozbuga advocate that patients with high-grade glial neoplasms, or primary lymphoma of the central nervous system, do not require surgery involving different surgical access to treat an incidental aneurysm (16). It is preferable to avoid surgical aneurysm treatment for those patients with poor long-term survival in order to protect them from surgical complications. Notably, in the study, neoplasm pathology was the main criteria guiding treatment.

## Study Limitations

The study's main limitation is the fact that the initial selection of articles included was carried out by one author only, increasing the chance of selection bias. Furthermore, few studies are available exploring the relationship between intracranial aneurysms and brain neoplasms, precluding any solid conclusion that brain neoplasms contribute to the formation and rupture of IAs and, hence, to a worsening of patient outcome.

## CONCLUSION

Therefore, based on current evidence, it still cannot be affirmed that brain neoplasms contribute to the formation and rupture of IAs. Patient prognosis depends on the nature of the neoplasm in cases with malignant neoplasms and on the presence of subarachnoid hemorrhage in patients with ruptured aneurysms. Outcome does not appear to be worse in patients with both diseases, but the treatment of these coexisting conditions poses a challenge and may increase the risk of morbidity and mortality. In addition, there is no consensus regarding treatment. Lastly, although some studies show IAs are more common in individuals with pituitary tumors than in the general population, there is insufficient evidence supporting a higher prevalence of intracranial aneurysms in individuals with brain neoplasms.

### AUTHORSHIP CONTRIBUTION

Study conception and design: PHMR, EGF

Data collection: PHMR

Analysis and interpretation of results: PHMR, NNR, JPMT, EGF

Draft manuscript preparation: PHMR, NNR, JPMT

Critical revision of the article: NNR, JPMT, EGF

All authors (PHMR, NNR, JPMT, EGF) reviewed the results and approved the final version of the manuscript.

## REFERENCES

1. Ali R, Pabaney A, Robin A, Marin H, Rosenblum M: Glioblastoma and intracranial aneurysms: Case report and review of literature. *Surg Neurol Int* 6:66, 2015
2. Almeida Silva JM, Campos RR, Souza RR, Sette Dos Santos ME, Aguiar GB: Spontaneous subarachnoid haemorrhage from rupture of an anterior communicating artery aneurysm in a patient with pituitary macroadenoma. *Neurocirugia* 25:81-85, 2014
3. Wiebers DO, Whisnant JP, Huston 3<sup>rd</sup> J, Meissner I, Brown Jr RD, Piepgras DG, Forbes GS, Thielen K, Nichols D, O'Fallon WM, Peacock J, Jaeger L, Kassell NF, Kongable-Beckman GL, Torner JC; International Study of Unruptured Intracranial Aneurysms Investigators: Unruptured intracranial aneurysms: Natural history, clinical outcome, and risks of surgical and endovascular treatment. *Lancet* 362:103-110, 2003
4. Habibi Z, Mojtaba Miri S, Sheikhezadei A: Pituitary macroadenoma coexistent with a posterior circulation aneurysm leading to subarachnoidal hemorrhage during transsphenoidal surgery. *Turk Neurosurg* 25:469-474, 2015

5. Imamura J, Okuzono T, Okuzono Y: Fatal epistaxis caused by rupture of an intratumoral aneurysm enclosed by a large prolactinoma. Case report. *Neurol Med Chir* 38:654-656, 1998
6. Jakubowski J, Kendall B: Coincidental aneurysms with tumours of pituitary origin. *J Neurol Neurosurg Psychiatry* 41:972-979, 1978
7. Kadota Y, Hatashita S, Sakakibara T, Takagi S: Intracerebral hemorrhage from a peripheral aneurysm associated with an Astrocytoma: Case report. *Neurol Med Chir* 29:241-244, 1989
8. Lee HS, Park W, Kim YH, Park JC, Ahn J, Kim JH: Follow-up and treatment of patients with coexisting brain tumor and intracranial aneurysm. *World Neurosurg* 129:e73-80, 2019
9. Licata C, Pasqualin A, Freschini A, Barone G, da Pian R: Management of associated primary cerebral neoplasms and vascular malformations - 1. Intracranial aneurysms. *Acta Neurochir* 82:28-38, 1986
10. Niu X, Wang T, Li J, Niu L, Yang Y, Wang X, Liu Y, Mao Q: An integrative survival analysis with identification of prognostic factors in the patients with coexisting glioma and intracranial aneurysm. *World Neurosurg* 111:e592-600, 2018
11. Pia HW, Obrador S, Martin JG: Association of brain tumours and arterial intracranial aneurysms. *Acta Neurochir (Wien)* 27:189-204, 1972
12. Raper DM, Ding D, Evans E, Starke RM, Crowley RW, Liu KC, Oldfield EH, Jane Jr JA: Clinical features, management considerations and outcomes in case series of patients with parasellar intracranial aneurysms undergoing anterior skull base surgery. *World Neurosurg* 99:424-432, 2017
13. Spittler K, Drazin D, Hanna G, Patel A, Chu R: Association of intracranial aneurysms with meningiomas, pituitary adenomas, and gliomas: Review of possible interrelationships. *ISRN Neurol* 2013:1-6, 2013
14. Tian X, Shu H, Zhang H, Wang H, Guo L: Intracranial hemorrhage due to rupture of an anterior communicating artery aneurysm in a patient with pituitary adenoma. *J Craniofac Surg* 26:e154,155, 2015
15. Toth G, Cerejo R: Intracranial aneurysms: Review of current science and management. *Vascular Med* 23(3):276-288, 2018
16. Turan Suslu H, Bozbuga M: Primary brain tumors associated with cerebral aneurysm: Report of three cases. *Turk Neurosurg* 21:216-221, 2011
17. UCAS Japan Investigators; Morita A, Kirino T, Hashi K, Aoki N, Fukuhara S, Hashimoto N, Nakayama T, Sakai M, Teramoto A, Tominari S, Yoshimoto T: The natural course of unruptured cerebral aneurysms in a Japanese Cohort. *N Engl J Med* 366:2474-2482, 2012
18. Wiebers DO, Piepgras DG, Meyer FB, Kallmes DF, Meissner I, Atkinson JLD, Link MJ, Brown Jr RD: Pathogenesis, natural history, and treatment of unruptured intracranial aneurysms. *Mayo Clin Proc* 79:1572-1583, 2004
19. Zhong Z, Sun Y, Lin D, Sun Q, Bian L: Surgical treatment of brain tumor coexisted with intracranial aneurysm--case series and review of the literature. *Neurosurg Rev* 36:645-656; discussion 656, 2013