



# Transient Ageusia and Dysgeusia Following Thalamic Cyst Drainage

Aziz Emre NOKAY<sup>1\*</sup>, Mert Emre ERDEN<sup>1\*</sup>, Yavuz SAMANCI<sup>2,3</sup>, Selcuk PEKER<sup>2,3</sup>

<sup>1</sup>Koc University, School of Medicine, Istanbul, Türkiye

<sup>2</sup>Koc University, School of Medicine, Department of Neurosurgery, Istanbul, Türkiye

<sup>3</sup>Koc University Hospital, Gamma Knife Center, Istanbul, Türkiye

\*Aziz Emre NOKAY and Mert Emre ERDEN contributed equally.

Corresponding author: Selcuk PEKER ✉ peker@selcukpeker.com

## ABSTRACT

Taste consists of sensation and perception. Specific neural structures transmit a stimulus from the taste buds to the gustatory cortex to generate taste sensation. Any disruption of this pathway, whether it affects sensation or perception, can result in taste disorders. Stereotactic procedures involving the thalamus may result in gustatory complications. A 41-year-old female patient who underwent stereotactic drainage of a thalamic cyst suffered transient ageusia. Subsequently, she developed metallic taste perception. When her stereotactic plan was re-evaluated, it was noted that the posteromedial ventral thalamus nucleus was in the path of the needle tract and the needle had passed through it. Follow-up was recommended and her symptoms completely resolved within 2 months following surgery. Modern imaging techniques allow for the visualization of neural structures related to the sense of taste. Additionally, care must be taken when planning stereotactic procedures for such lesions.

**KEYWORDS:** Ageusia, Dysgeusia, Functional neurosurgery, Gustatory system, Stereotactic, Thalamus

**ABBREVIATIONS:** VMP: Posteromedial ventral thalamus, VMPpc: Parvicellular part of the posteromedial ventral thalamus, PGC: Primary gustatory cortex, DBS: Deep brain stimulation

## INTRODUCTION

Although gustation, also referred to as the sense of taste, is a fundamental sensory function, its disorders are not emphasized as much as disorders affecting other senses (10). The sense of taste exhibits remarkable stability. However, it can be disrupted by several factors, leading to disturbance in the taste sensitivity (dysgeusia), loss of taste (ageusia), or decreased taste capacity (hypogeusia) (2,8). Dysgeusia is reportedly a side effect of neurosurgical interventions, mainly deep brain stimulation (3-5,9,11).

The thalamus has a unique anatomical configuration. Thalamic taste disorders were first documented in 1934 by

Adler in a patient with a glioblastoma that had infiltrated the posteromedial ventral thalamus (VMP) (1). Even though our comprehension of the neural pathways and cognitive mechanisms underlying human gustation is limited, dysgeusia mostly involves the parvicellular part of the VMP (VMPpc), namely, the gustatory thalamus, its afferent gustatory fibers from the nucleus of the solitary tract, or the thalamocortical projections to the primary gustatory cortex (PGC) (7).

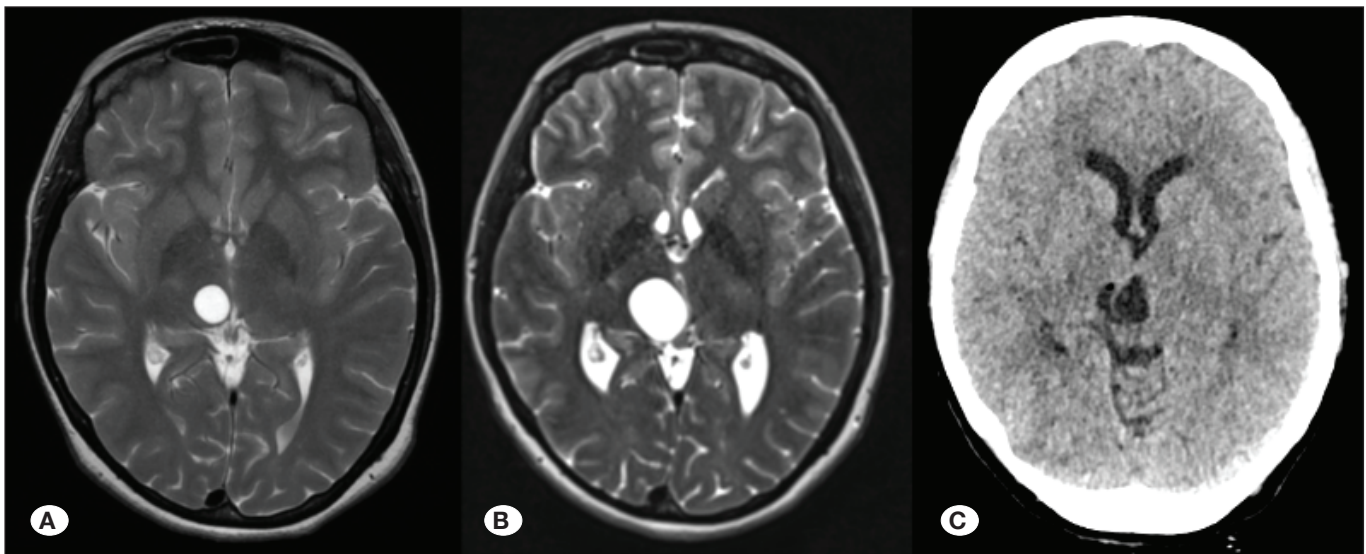
Herein, we present a patient suffering from transient ageusia, who developed metallic taste perception following the drainage of a stereotactic thalamic cyst.

## ■ CASE PRESENTATION

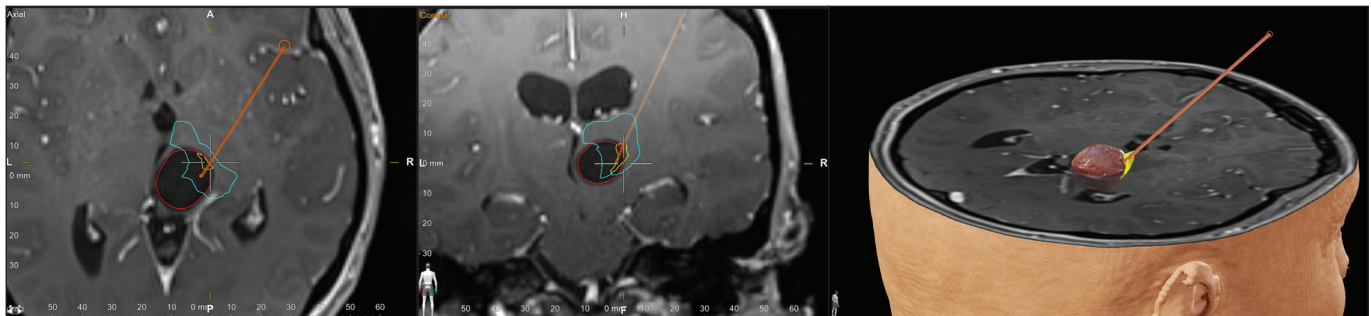
A 41-year-old right-handed woman was admitted to the outpatient clinic with a recent history of headache. She was referred to our clinic by another neurosurgeon who had diagnosed her with a right-sided incidental thalamic cyst 8 years ago and had followed her since. Her last control MRI revealed that the cyst had progressed (20 × 18 mm) and was slightly compressing the posterior part of the third ventricle (Figure 1).

On admission, her neurological examination was unremarkable, and there were no clinical signs of raised intracranial pressure. The remaining physical examination and medical histories of the patient and their family yielded no notable findings. A benign thalamic cyst was suspected, and a frame-based stereotactic drainage was performed to determine the definitive diagnosis and treatment plan. The perioperative course was uneventful (Figure 1). The cystic fluid was hypocoelular. Thus, follow-up was recommended and the patient was discharged.

At the first follow-up for a wound check and at the time of stitch removal 5 days later, she mentioned that she had developed ageusia from the second postoperative day. She reported no experiences of weakness, paresthesia, visual impairments, or speech difficulties. Furthermore, she was not on any medication. Blood tests revealed normal electrolyte levels and kidney and liver function tests. Additionally, the patient displayed no clinical signs of infection. The patient's COVID-19 test was negative. A follow-up CT scan did not reveal any evidence of intracranial bleeding or subacute infarction. Thus, she was referred to Otolaryngology clinic. However, no pathology was detected; thus, no particular therapeutic regime was recommended. When her stereotactic plan was re-evaluated, it was noted that the VPM nucleus had been in the path of the needle and the needle had passed through it (Figure 2). The patient was followed up. During her follow-up 15 days after surgery, she mentioned her sense of taste had returned along with a metallic taste. Further follow-up was recommended. Her symptoms completely resolved 2 months after surgery, and she remains progression-free 2 years after the surgery.



**Figure 1:** Axial T2-weighted magnetic resonance images obtained (A) 8 years ago and (B) on admission. Progression of the right thalamic cyst was noted, and a stereotactic cyst drainage was performed. (C) Postoperative CT scan was unremarkable.



**Figure 2:** Re-evaluation of the stereotactic plan for the thalamic cyst (red) revealed that the posteromedial ventral thalamus nucleus (yellow) was in the pathway of the needle tract and the needle had passed through it.

**Table I:** Previous Reports of Thalamic Taste Disorders Following Neurosurgical Interventions

Case report	Age, gender	Indication	Intervention	Symptom	Outcome
Roggendorf et al., 2008 (9)	58, N/A	ET	Bilateral VIM-DBS	Dysgeusia (metallic taste)	Ceases with discontinuation of stimulation
Gilard et al., 2014 (5)	52, M	ET	Bilateral VIM-DBS	Dysgeusia notably for wine	Ceases with alteration of stimulation parameters
Carlson et al., 2018 (3)	15 patients	ET	Unilateral dominant hemisphere thalamic / bilateral thalamic DBS	Dysgeusia (foul taste, metallic taste, coolness, tingling taste or sour taste)	Ceases with discontinuation of stimulation
Swinnen et al., 2022 (11)	71, F	ET	Bilateral dentatorubrothalamic tract-DBS	Dysgeusia (bitter and sour taste)	Marked improvement with bilateral directional stimulation
De Vloot et al., 2022 (4)	75, M	ET	Left-sided MRgFUS thalamotomy	Dysgeusia (foul taste)	Full recovery (19 months)
Present case	41, F	Thalamic cyst	Stereotactic cyst drainage	Ageusia followed by dysgeusia (metallic taste)	Full recovery (2 months)

**ET:** Essential tremor, **VIM:** Ventral intermediate nucleus, **DBS:** Deep brain stimulation, **MRgFUS:** Magnetic Resonance-guided focused ultrasound

## DISCUSSION

Our understanding of the neural pathways and cognitive processes that constitute the human sense of taste is limited. Dysgeusia resulting from central lesions refers to an interruption in the taste pathway extending from the brainstem to its representation in the cortex. A taste disorder primarily due to a central nervous system lesion is rare. Typically, gustatory symptoms coincide with the initial stages of the intracranial lesion when the signs and symptoms are more pronounced (6). Thus, gustatory dysfunction is frequently unreported, requiring the clinician to actively look for it. Approximately 15–50% of individuals who have undergone deep brain stimulation (DBS) of the ventral intermediate nucleus of the thalamus develop dysgeusia. Approximately half of these patients acknowledge dysgeusia when questioned directly about it (4).

The thalamus is the primary origin of information regarding the chemical and physical attributes of gustatory stimuli for the PGC (10), and the VPMpc is the fundamental relay in the human gustatory pathway. Electrophysiological measurements conducted in both anesthetized and awake animals have demonstrated that neurons within the VPMpc encode various facets of gustatory perception, including temperature, oral tactile sensation, and chemosensation (12). Additionally, Samuelsen et al. (10) demonstrated that VPMpc deactivation leads to a significant decrease in the processing of taste signals within the PGC. Thalamic taste disorders following neurosurgical interventions have mostly been reported following DBS or MRgFUS thalamotomy for essential tremors (Table I). In the present case, VPMpc nucleus manipulation, which was close to the surgical target, may account for the observed transient ageusia and subsequent dysgeusia.

## CONCLUSION

Herein, we have discussed the development of transient ageusia and subsequent dysgeusia in a patient who was managed with stereotactic cyst aspiration for a thalamic cyst. This case demonstrates the efficacy of stereotactic aspiration for benign thalamic cysts and the possible postoperative gustatory problems. Thus, care must be taken when planning stereotactic procedures for such lesions.

### AUTHORSHIP CONTRIBUTION

Study conception and design: YS, SP  
 Data collection: AEN, MEE, YS  
 Analysis and interpretation of results: AEN, MEE, YS  
 Draft manuscript preparation: AEN, MEE, YS  
 Critical revision of the article: YS, SP  
 Other (study supervision, fundings, materials, etc...): SP  
 All authors (AEN, MEE, YS, SP) reviewed the results and approved the final version of the manuscript.

## REFERENCES

- Adler A: Zur topik des Verlaufes der Geschmackssinnsfasern und anderer afferenter Bahnen im Thalamus. *Z Gesamte Neurol Psychiatr* 149:208-220, 1934. <https://doi.org/10.1007/BF02870511>
- Barlow LA: The sense of taste: Development, regeneration, and dysfunction. *WIREs Mech Dis* 14:e1547, 2022. <https://doi.org/10.1002/wsbm.1547>
- Carlson JD, McLeod KE, Mark JB, McLeod PS, Bremer BA: Dysgeusia in deep brain stimulation for essential tremor. *J Clin Neurosci* 50:242-246, 2018. <https://doi.org/10.1016/j.jocn.2018.01.013>

4. De Vloo P, Boutet A, Elias GJB, Gramer RM, Joel SE, Llinas M, Kucharczyk W, Fasano A, Hamani C, Lozano AM: Dysgeusia induced and resolved by focused ultrasound thalamotomy: Case report. *J Neurosurg* 136:215-220, 2022. <https://doi.org/10.3171/2020.11.JNS202882>
5. Gilard V, Maltete D, Lefaucheur R, Chastan N, Derrey S: Dysgeusia following ventral intermediate nucleus deep brain stimulation for essential tremor. *Parkinsonism Relat Disord* 20:1307-1308, 2014. <https://doi.org/10.1016/j.parkreldis.2014.08.020>
6. Heckmann JG, Heckmann SM, Lang CJ, Hummel T: Neurological aspects of taste disorders. *Arch Neurol* 60:667-671, 2003. <https://doi.org/10.1001/archneur.60.5.667>
7. Iannilli E, Gudziol V: Gustatory pathway in humans: A review of models of taste perception and their potential lateralization. *J Neurosci Res* 97:230-240, 2019. <https://doi.org/10.1002/jnr.24318>
8. Jafari A, Alaee A, Ghods K: The etiologies and considerations of dysgeusia: A review of literature. *J Oral Biosci* 63:319-326, 2021. <https://doi.org/10.1016/j.job.2021.08.006>
9. Roggendorf J, Vent J, Maarouf M, Haense C, Thiel A, Fink GR, Hilker R: Geschmacksstörung unter tiefer Hirnstimulation des Thalamus bei essenziellem Tremor. *Der Nervenarzt* 79:454-456, 2008. <https://doi.org/10.1007/s00115-007-2407-9>
10. Samuelsen CL, Gardner MP, Fontanini A: Thalamic contribution to cortical processing of taste and expectation. *J Neurosci* 33:1815-1827, 2013. <https://doi.org/10.1523/JNEUROSCI.4026-12.2013>
11. Swinnen BEKS, Bot M, Goes KM, Beudel M, Schuurman RP, de Bie RMA: Directional stimulation improves stimulation-induced dysgeusia in DBS for essential tremor. *Brain Stimul* 15:680-682, 2022. <https://doi.org/10.1016/j.brs.2022.04.016>
12. Verhagen JV, Giza BK, Scott TR: Responses to taste stimulation in the ventroposteromedial nucleus of the thalamus in rats. *J Neurophysiol* 89:265-275, 2003. <https://doi.org/10.1152/jn.00870.2001>