



DOI: 10.5137/1019-5149.JTN.4238-11.1

Received: 09.02.2011 / Accepted: 03.11.2011

## Case Report

# Post-Traumatic Tension Pneumocephalus: Series of Four Patients and Review of the Literature

Yashpal Singh RATHORE, Guru Dutta SATYARTHEE, Ashok Kumar MAHAPATRA

J.P.N.A Trauma Centre, Department of Neurosurgery, New Delhi, India

### ABSTRACT

Tension pneumocephalus is an uncommon and life-threatening neurological condition. It requires emergent and immediate attention to prevent fatal complications. Head injury is the most common cause of tension pneumocephalus. Air can gain access into the cranium either through a fracture involving paranasal sinus or the middle ear cavity or even more rarely in association with a compound depressed fracture of the skull vault. Its management includes simple twist drill and aspiration of intracranial air with or without placement of an under water seal. 100% oxygen should be administered by a non-breatheable mask which hastens the resorption of air. The authors report a series of 4 cases of post-traumatic tension pneumocephalus, highlighting its management, and review the pertinent literature.

**KEYWORDS:** Tension pneumocephalus, Management, Outcome

### ■ INTRODUCTION

Pneumocephalus is defined as presence of air in the cranial cavity which may be present in the subdural space, or intraventricular space. Pneumocephalus may be seen in 0.5-1.0% of head injuries (10). Air can gain access into the cranium either through a fracture involving a paranasal sinus or the middle ear cavity or even more rarely in association with a compound depressed fracture of the skull vault. Head injury is the most common cause of pneumocephalus (10).

Tension pneumocephalus is an uncommon and life-threatening neurosurgical emergency. Tension pneumocephalus is described to occur with as little as 25 cc of air (19). It may lead to progressive brain compression resulting in deteriorating mental status due to decreased oxygen supply to the brain. Consequently, the ventricles may be displaced, tentorial herniation occurs, and brainstem compression, and eventually the patient may die (19).

Immediate attention and proper management are required for the prevention of fatal complications due to tension pneumocephalus. In this paper, the authors report a series

of four cases of post-traumatic tension pneumocephalus, highlighting its management, together with a review of the literature.

### ■ CASE REPORTS

Four patients with the diagnosis of tension pneumocephalus were admitted to the department of neurosurgery between 2009 and 2010.

**Case 1:** A 30-year-old male patient was admitted to our department with a history of facial and frontal injury due to fall from a vehicle. Transient loss of consciousness was present after the injury. However, there was no history of headache, vomiting, nasal discharge/bleed or seizure at that time. Severe headache with multiple episodes of vomiting and rhinorrhea occurred four days after injury. He consulted a local physician who ordered cranial computed tomography (CT) and it revealed left frontal extradural hematoma with left frontal fracture involving the left frontal sinus. He was kept on conservative management. Next week, the severity of headache increased and rhinorrhea subsided. He was

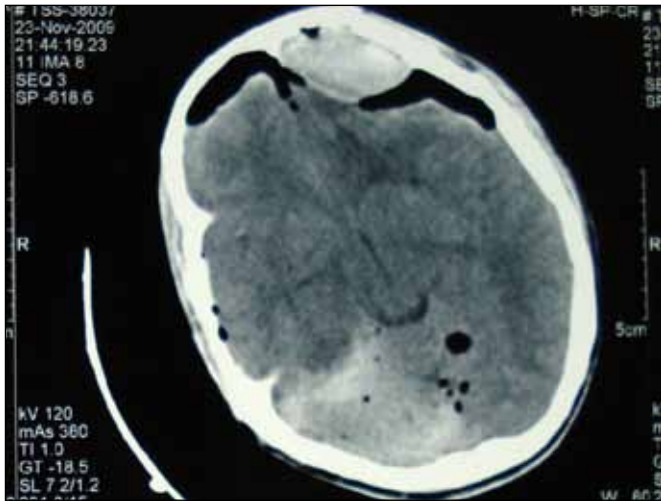
qr code

**Corresponding author:** Guru Dutta SATYARTHEE

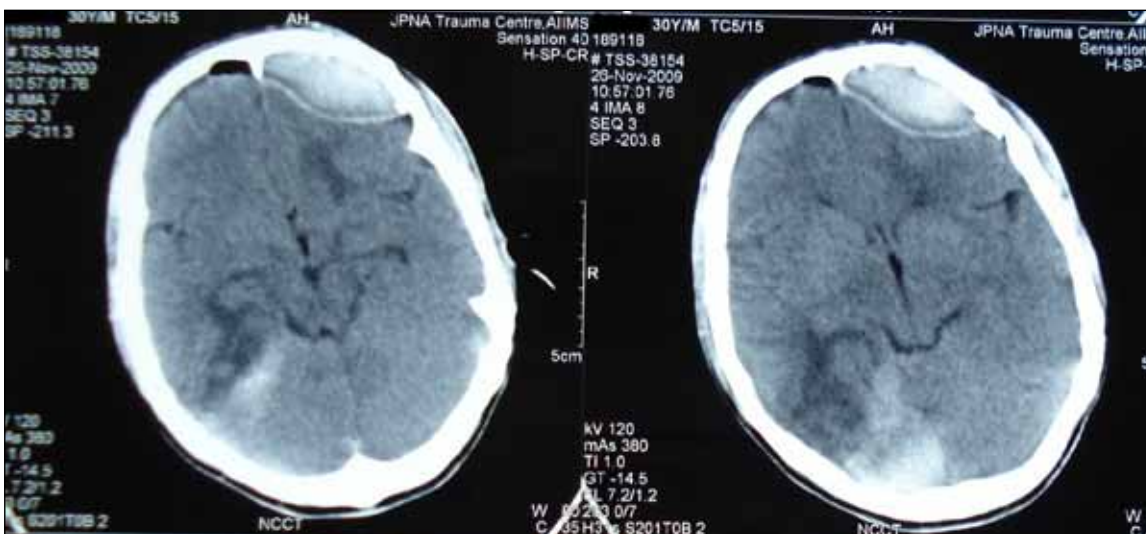
**E-mail:** duttaguru2002@yahoo.com

referred to our hospital 2 weeks post-injury. Repeat CT scan showed left frontal extradural hematoma whose size remained unchanged with tension pneumocephalus with fresh onset right tentorial subarachnoid hemorrhage (counter coup injury) (Figure 1). At the time of admission, the patient's Glasgow Coma Scale (GCS) score was 14 (E4V4M6). The patient was managed with aspiration of the pneumocephalus by a twist drill and closed water seal system and kept under observation for one week. The patient improved symptomatically, and the GCS score was 15 (E4V5M6). His headache disappeared and the nasal discharge subsided. Subsequent CT scan showed resolution of pneumocephalus (Figure 2). He was doing well at last follow up 3 months after the injury.

**Case 2:** A 64-year-old male reported 36 hours after sustaining injuries to head and face in a road-traffic accident. He was conscious and alert with GCS score of 15/15. CT scan revealed fracture of frontal sinus extending to the right orbital roof with pneumocephalus depicting the classic Mount Fuji sign. Since patient was neurologically intact and did not



**Figure 1:** CT scan of Case 1 shows left frontal epidural hematoma with tension pneumocephalus.



**Figure 2:** Postaspiration CT scan of Case 1 shows complete resolution of pneumocephalus.

have any cerebrospinal fluid leak (CSF), he was managed conservatively with decongestants and oxygen by mask. His course of hospitalization was uneventful with resolution of pneumocephalus and he was discharged after 3 days.

**Case 3:** A 42-year-old male patient presented with history of a road traffic accident and had sustained injuries to the face and head. He presented 48 hours after the injury. At the time of admission, the GCS score was 11 (E3V3M5). CT scan revealed fracture of the left frontal sinus and orbital roof with tension pneumocephalus. Twist drill with aspiration of the pneumocephalus was carried out in casualty. The patient was electively ventilated for 2 days. His general condition improved to GCS score 15 (E4V5M6), and subsequent CT showed complete resolution of the pneumocephalus. He was discharged one week after the injury.

**Case 4:** A 60-year-old male came to our emergency service with a history of a road traffic accident with multiple facial injuries. He had an open lacerated wound over his left frontal region with a communicated fracture of the frontal bone. CT scan revealed tension pneumocephalus with pneumoventricle with subarachnoid haemorrhage and multiple hemorrhagic contusion and fracture of the left frontal bone involving the frontal sinus and left orbit (Figure 3). His GCS score was 3 (E1V1M1) with pupils bilateral dilated and non-reacting. The patient was intubated and immediate twist drill with aspiration of pneumocephalus was carried out in the casualty. The patient was planned for surgery and repair of the dural tear but his GCS score did not improve and he expired.

## ■ DISCUSSION

There are 2 theories that have been proposed for the mechanism of pneumocephalus (10). Dandy postulated a "ball valve" mechanism in which air travels in only one direction (6). As air enters the cranial cavity, the intracranial pressure rises (10). The pressure gradient between the atmosphere and intracranial space is reduced and the osteomenigeal fistula is tamponaded by brain tissue as was noticed in case 1. As a consequence, air is trapped into the intracranial space which causes mass effect (6,10).

The other theory for the development of pneumocephalus, the “Inverted-soda-bottle effect”, was proposed by Horowitz (9). He postulated that negative intracranial pressure (ICP) results from excessive loss of CSF through an iatrogenic lumbar drain or settling into the distensible spinal subarachnoid space or simply drainage via normal pathways with physiologic activity such as inspiration or the Valsalva manoeuvre (10). However, when there are fistulous communication between the intracranial and outer environment, air can enter the intracranial space as a consequence of negative pressure gradient (10).

Head injury is the most common cause of pneumocephalus and pneumocephalus occurs in 0.5 to 1.0% of head trauma (10). Possible causes of tension pneumocephalus are bone fractures of the orbit and facial paranasal sinuses, gunshot injury, misplacement of nasogastric tubes and ambu-bag resuscitation (1, 4, 8, 14,19).

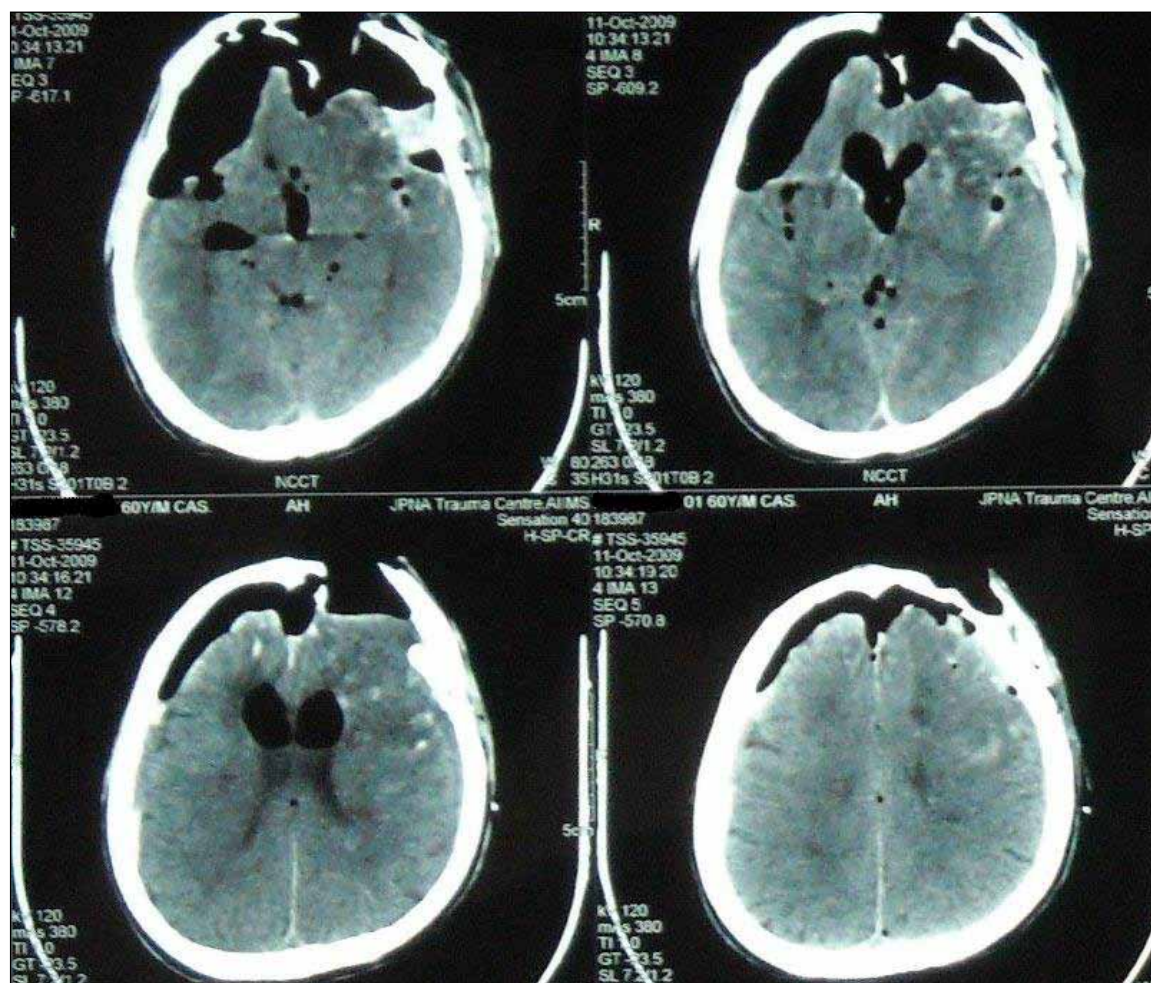
The anatomy of the frontal bone potentially predisposes the patient to a pneumocephalus following injury. The dura mater next to the frontal and paranasal sinuses is thin and tightly attached to frontal bone along the olfactory nerve, and can be easily torn by injury leading to the development of a fistulous communication ultimately resulting in pneumocephalus (2,

19). Tumors and infection of the frontal and paranasal sinuses may cause erosion of the dura mater and bony structures, resulting in pneumocephalus in the cranium (19).

Raised external pressure during frequent and severe nose-blowing (3), sneezing (20), coughing (18) or Valsalva maneuver (13) have been identified as contributing to tension pneumocephalus. Thoracic vertebral fractures may also be associated with pneumocephalus (17). During neurosurgical procedures, inhaled anaesthetic agents such as nitrous oxide may potentiate a tension pneumocephalus as it diffuses from the blood into an air-filled cavity more quickly than it diffuses out of the cavity. Then, it causes tension pneumocephalus (14,19).

All patients with craniotomies have the potential to develop tension pneumocephalus. Pneumocephalus may develop following burr holes, posterior fossa surgery (16), craniofacial surgery (5, 14, 18) transsphenoidal pituitary surgery (12), ventriculoperitoneal shunt, and lumbar drain placement. The sitting position during and following cranial surgery increases the risk of pneumocephalus (13, 18-20).

CT is the “gold standard” diagnostic tool for tension pneumocephalus. CT identifies the presence of air via the density differences between air, fluid, tissue, and bone. CT



**Figure 3:** CT scan of Case 4 shows tension pneumocephalus.



is used to identify the amount and location of air and fluid, presence of a defect, and the effect of trapped air on the brain (19). Mount Fuji sign is typical CT finding of tension pneumocephalus. In this sign, the air compresses the frontal lobes and this results in a tented appearance of the brain in the skull, called the Mount Fuji sign. This resembles Mount Fuji in Japan, which is a volcano known for its symmetrical cone (11). Management of tension pneumocephalus presents a challenge. Once tension pneumocephalus is diagnosed, pure oxygen should be administered via a mask (19). It is postulated that 100% inspired oxygen hastens the resorption of air (5, 14, 18, 22). The management is tailored according to the aetiology. If a CSF leak is the cause, then its repair via endoscopy or open surgery should be carried out to seal the dural tear. If a lumbar drain is in place, clamp or remove the drain, and place the patient in a supine position. A sitting position allows for continued inflow of air via the dural defect. When the tension pneumocephalus is diagnosed, all efforts should be made to decrease the mass effect and intracranial pressure (19). A tension pneumocephalus is a neurosurgical emergency. Twist drill with needle and syringe aspiration or catheter drainage of the air usually provides immediate patient improvement. A closed water seal system has also been reported to be very effective in decompressing the trapped air as shown in one of our cases (14, 18). In the post-operative period in cases of evacuation of a chronic subdural hematoma or excision of a brain tumour where the brain tissue does not extend to fill the empty space, a drain should be left in place and the patient should be placed in the supine position until the brain tissue rebounds. This reduces the risk of tension pneumocephalus development (19, 21). In addition to intracranial air aspiration, medical treatment such as mannitol may be ordered to decrease brain edema. This may reduce the mass effect and lower the intracranial pressure (19).

Definitive management in the form of identification and repair of the bony and/or dural defect is imperative and is the objective. It can be carried out either endoscopically or via open craniotomy. An endoscopic or extracranial approach is preferred for the patient with multiple comorbidities and who may not survive an open craniotomy. A craniotomy approach may be preferred if the defect cannot be exposed with the endoscope or if the previous endoscopic repair was not successful (15,19). The open craniotomy approach provides clear visibility and easy access to the dura defect. The success rate is equal for both techniques in terms of defect closure (7, 19). However, the operative and anesthetic time is longer for the intracranial approach and increased morbidity and longer hospital stay exist with this method.

Our two patients improved with simple twist drill and aspiration of pneumocephalus using a closed water seal system while another one improved on simple conservative management. It is imperative that tension pneumocephalus be tapped as soon as possible utilizing a simple water seal system when the patient's neurological condition starts deteriorating. One should not wait too long with conservative management. Simple twist drill with or without under water seal will break the lock for the trapped intracranial air leading to decreased mass effect and intracranial pressure, thereby improving the overall

patient condition. 100% oxygen should be administered and the dural defect should be closed if possible as definitive management.

## ■ REFERENCES

1. Adler JS, Graeb, DA, Nugent RA: Inadvertent intracranial placement of a nasogastric tube in a patient with severe head trauma. *CMAJ* 147(5): 668-669, 1992
2. Aferzon M, Aferzon J, Spektor Z: Endoscopic repair of tension pneumocephalus. *Otolaryngol Head Neck Surg* 124(6): 688-689, 2001
3. Ayala C, Watkins L, Deschler DG: Tension orbital pneumocele secondary to nasal obstruction from cocaine abuse. *Otolaryngol Head Neck Surg* 127(6), 572-574, 2002
4. Baskaya MK: Inadvertent intracranial placement of a nasogastric tube in patients with head injuries. *Surg Neurol* 52(4):426-427, 1999
5. Clevens RA, Marentette LJ, Esclamado RM, Wolf GT, Ross DA: Incidence and management of tension pneumocephalus after anterior craniofacial resection. *Otolaryngol Head Neck Surg* 120(4): 579-583, 1999
6. Dandy WE: Pneumocephalus. *Arch Surg* 12: 949-982, 1926
7. Dodson EE, Gross CW, Swerdloff JL, Gustafson LM: Transnasal endoscopic repair of cerebrospinal fluid rhinorrhea and skull base defects: A review of 29 cases. *Otolaryngol Head Neck Surg* 111: 600-605, 1994
8. Ferreras J, Junquera LM, Garcia-Consuegra L: Intracranial placement of a nasogastric tube after severe craniofacial trauma. *Oral Surg Oral Med Oral Pathol* 90(5): 564-566, 2000
9. Horowitz M: Intracranial pneumocele. An unusual complication following mastoid surgery. *J Laryngol Otol* 78:128-134, 1964
10. Lee SH, Koh JS, Bang JS, Kim MC: Extensive tension pneumocephalus caused by spinal tapping in a patient with basal skull fracture and pneumothorax. *J Korean Neurosurg Soc* 45(5):318-321, 2009
11. Michel SJ: The Mount Fuji Sign. *Radiology* 232(2):449-450, 2004
12. Satyarthee GD, Mahapatra AK: Tension pneumocephalus following transsphenoid surgery for pituitary adenoma - report of two cases. *J Clin Neurosci* 10(4):495-497, 2003
13. Schrijver HM, Berendse HW: Pneumocephalus by Valsalva maneuver. *Neurology* 60(2):345-346, 2003
14. Sprague A, Poulgrain P: Tension pneumocephalus: A case report and literature review. *J Clin Neurosci* 6(5):418-424, 1999
15. Stankiewicz J: CSF fistula and endoscopic sinus surgery. *Laryngoscope* 101:250- 256, 1991
16. Suri A, Mahapatra AK, Singh VP: Posterior fossa tension pneumocephalus. *Childs Nerv Syst* 26(4):196-199, 2000
17. Uemura K, Meguro K, Matsumura A: Pneumocephalus associated with fracture of thoracic spine. *Br J Neurosurg* 11(3):253-256, 1997
18. Wanamaker JR, Mehle ME, Wood BG, Lavertu P: Tension pneumocephalus following craniofacial resection. *Head and Neck* 17(2):152-156, 1995
19. Webber-Jones JE: Tension pneumocephalus. *J Neurosci Nurs* 37(5):272-276, 2005
20. Wein FB, Gans MS: The perils of a sneeze. *J Neuroophthalmol* 19(2):128-130, 1999
21. Wood BJ, Mirvis SE, Shanmuganathan K: Tension pneumocephalus and tension orbital emphysema following blunt trauma. *Ann Emerg Med* 28(4):446-449, 1996
22. Zasler ND: Posttraumatic tension pneumocephalus. *J Head Trauma Rehabil* 14(1):81-84, 1999