



Correlations Between Facet Tropism, Joint Mobility and Degree of Displacement in Patients with Low Grade Spondylolisthesis

Vinicius Marques CARNEIRO¹, Rodrigo Inácio PONGELUPPI¹, Denilson Sanches FERNANDES¹, Davi Casale ARAGON², José Luiz ROMEO BOULLOSA¹

¹University of São Paulo, University Hospital of Ribeirão Preto Medical School, Division of Neurosurgery, Brazil

²University of São Paulo, Ribeirão Preto Medical School, Department of Pediatrics, Brazil

Corresponding author: Rodrigo Inácio PONGELUPPI ✉ rodrigopongiluppi@gmail.com

ABSTRACT

AIM: To compare lumbar X-ray and MRI findings, and to identify the factors associated with joint instability in cases with lumbar spondylolisthesis.

MATERIAL and METHODS: We performed a retrospective and observational study of patients with a confirmed diagnosis of lumbar or lumbosacral low-grade spondylolisthesis at a single level. Preoperative X-ray and MRI examinations were evaluated. Statistical analysis was performed using Fisher's exact test and Kappa statistics.

RESULTS: The present study comprised 59 patients. Of these, 62% had Modic changes on MRI. Degenerative and isthmic spondylolisthesis was found in 49.2% and 50.8% of patients, respectively. All patients had degenerative disc changes at the level of the listesis. Moderate and severe facet asymmetry was observed 18 (30.5%) and three (5.1%) patients, respectively. Neutral facets were observed in 64.4% of patients. Dynamic X-ray detected segmental mobility in 52.5% of the cases. There was a negative correlation between the presence of tropism and joint mobility ($p=0.03$). Further, the degree of listesis was negatively correlated with the presence of FT ($p=0.02$). Substantial agreement (91.52%) was observed between MRI and X-ray examinations (Kappa, 0.81; CI, 0.66–0.97).

CONCLUSION: MRI was sufficient for the diagnosis of lumbar spondylolisthesis and dynamic lumbar imaging was important in defining segmental mobility. In addition, facet tropism appeared to have a protective effect on instability.

KEYWORDS: Low back pain, Spine diseases, Spondylolisthesis

ABBREVIATIONS: **DG:** Disc degeneration, **FT:** Facet tropism, **L2-L3:** Intervertebral space between lumbar vertebrae 2 and 3, **L3-L4:** Intervertebral space between lumbar vertebrae 3 and 4, **L4-L5:** Intervertebral space between lumbar vertebrae 4 and 5, **L5-S1:** Intervertebral space between lumbar vertebrae 5 and sacral vertebrae 1, **MRI:** Magnetic resonance imaging, **X-ray:** Energetic High-Frequency Electromagnetic Radiation

INTRODUCTION

Lumbar spondylolisthesis is a frequent cause of disabling leg and back pain. The word spondylolisthesis means “to slip” and derives from the Greek word “olistha’nein” (9). Spondylolisthesis is defined as the displacement of one vertebra over the subjacent bone of more than 4.5 mm (14).

Spondylolisthesis has been etiologically classified by Wiltse into five categories: isthmic, traumatic, degenerative, pathologic, and dysplastic (13,20). The degree of subluxation was classified by Meyerding according to subluxation of the vertebral body above on the vertebral body below according to the following grades: grade 1, less than 25%; grade 2, 25% to 50%; grade 3, 50% to 75%; grade 4, 75% to 100%; and spondyloptosis >100%. Grades 1 and 2 are considered low-grade (13).

Detailed preoperative radiological evaluation with dynamic lumbar radiography (X-rays) and nuclear magnetic resonance (MRI), is essential for the identification of instability and determining the most appropriate surgical approach for the correction of lumbar spondylolisthesis, such as arthrodesis and instrumentation or simple neurological decompression (11).

The determination of instability has been evaluated using standing lateral dynamic (flexion and extension) X-rays. Horizontal translation greater than 3 mm is considered a criterion for instability (2). A number of MRI findings have been described as suggestive of segmental instability including: the presence of facet fluid greater than 1.5 mm (6); disc degeneration (DG) according to the Pfirrmann classification (16); and facet tropism (FT) (4).

The objective of the present study was to compare the utility of preoperative lumbar X-ray (neutral and dynamic) and MRI in identifying factors associated with instability that may inform the most appropriate surgical approach for the correction of lumbar spondylolisthesis.

MATERIAL and METHODS

This was a retrospective and observational study. Patients who met the following criteria were included:

1. Confirmed diagnosis of lumbar or lumbosacral spondylolisthesis at a single level;
2. Low-grade spondylolisthesis;
3. Indication for surgical treatment between May 2012 and November 2017;
4. Availability of preoperative MRI and static and dynamic X-rays available;
5. Availability of consistent medical record information.

Imaging examinations were evaluated using Lyriapacs web software (i-medsys), which is linked to our institution’s electronic medical records, by two different doctors with experience in neuroimaging.

Lumbar spondylolisthesis etiology was classified according to Wiltse (20) into types I (dysplastic), II (isthmic), III (degenerative), IV (traumatic), or V (pathological) based on imaging and clinical history.

The degree of spondylolisthesis was defined as the ratio between the distance of displacement of the lower plateau of the upper vertebra in relation to the total size of the upper plateau of the lower vertebra (Figure 1) (10,13). Spondylolisthesis grades 1 and 2 were included.

Static and dynamic X-rays in orthostasis. Dynamic X-ray was performed in maximum flexion and extension when in orthostasis. Evaluation of MRI examinations was performed using sagittal sections in the midline.

Joint mobility was defined as slip displacement of greater than 3 mm between flexion and extension on dynamic X-ray (2,8).

In addition, the degree of DG at the level of spondylolisthesis was categorized from I to V according to Pfirrmann’s classification (16). Changes in adjacent plateaus, when present, were classified into types 1, 2, or 3, according to Modic (15).

FT was defined as the difference between the angle of the right and left facets in relation to a straight line passing through the axis of the spinous process (Figure 2). Difference less than 7° were considered symmetrical, between 7° and 15° were considered moderately asymmetrical, and above 15° were considered severely asymmetrical (4,18).

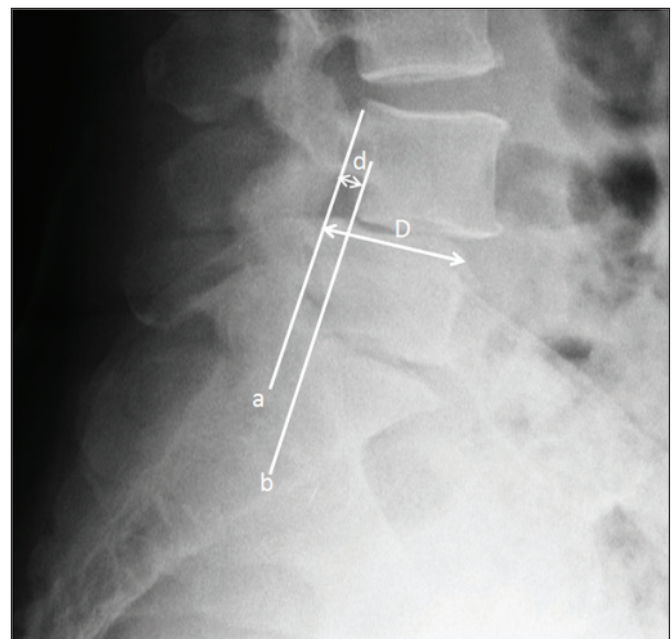


Figure 1: Method for calculating the degree of spondylolisthesis. A line is drawn passing through the posterior wall of the lower vertebra (a) and a parallel line (b) is drawn passing through the posterior wall of the lower vertebra. The degree of listhesis was defined as the ratio between the displacement distance (d) and the size of the vertebral plateau (D).

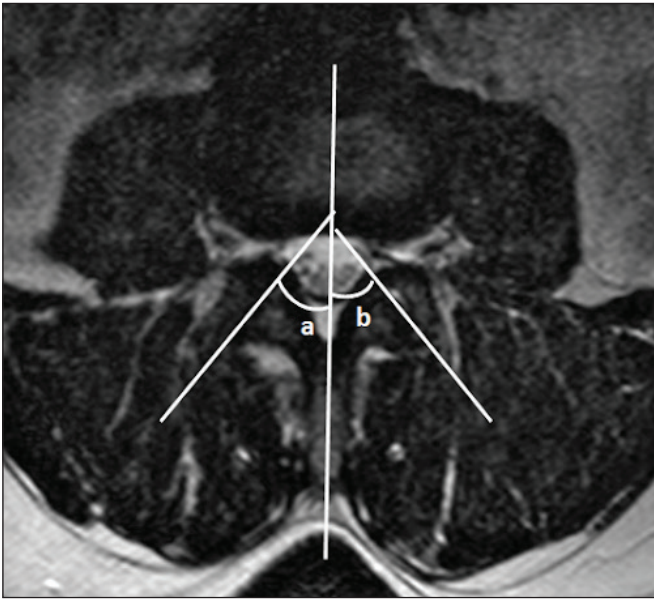


Figure 2: Method for calculating facet tropism. Facet angles (a and b) are measured in relation to the axis of the spinous process. Facet tropism was defined as the difference between the two angles.

Statistical analysis was performed using Fisher's exact test to evaluate associations between variables. The Kappa statistic was used to evaluate agreement (19).

RESULTS

A total of 59 patients with low-grade spondylolisthesis were included in the present study, comprising 50.8% males and 49.2% females. The mean age of included patients was 56.3 (17–78) years. MRI demonstrated Modic changes in 62% of patients (type 1, 21.6%; type 2, 54%; type 3, 24.3%; Table I). Degenerative spondylolisthesis was observed in 49.2% of patients, while 50.8% had isthmic spondylolisthesis. The majority of patients had listhesis at levels L4–L5 (52.5%) and L5–S1 (32.2%). Listhesis at the L3–4 level was observed in 8 patients (13.5%) and only one patient had spondylolisthesis at the L2–L3 level (1.6%; Table I).

All patients had degenerative disc changes at the level of the listhesis and most had high degrees of involvement according to the Pfirrmann classification (grade 2, 8.4%; grade 3, 11.7%; grade 4, 40.7%; grade 5, 39%; Table I).

Moderate and severely asymmetrical facets were observed in 18 (30.5%) and 3 (5.1%) patients, respectively, while 64.4% of

Table I: General and Epidemiological Characteristics of Study Participants

		Degenerative n (%)	Isthmicn (%)	Totaln (%)
Mean age (range)		61.4 (47-78)	51.1 (17-66)	56.3 years (17-78)
Sex	Male	18 (62)	10 (33.3)	30 (50.8)
	Female	11 (38)	20 (66.7)	29 (49.2)
Modic alteration type	Absent	15 (51.8)	7 (23.3)	22 (37.3)
	1	3 (10.3)	5 (16.7)	8 (13.6)
	2	9 (31)	11 (36.7)	20 (33.9)
Mobility	3	2 (6.9)	7 (23.3)	9 (15.3)
	Present	13 (44.8)	15 (50)	28
	Absent	16 (55.2)	15 (50)	31
Pfirrmann grade	1	0 (0)	0 (0)	0 (0)
	2	5 (17.2)	0 (0)	5 (8.4)
	3	5 (17.2)	2 (6.7)	7 (11.7)
	4	14 (48.3)	10 (33.3)	24 (40.7)
	5	5 (17.2)	18 (60)	23 (39)
Tropism	Symmetrical	14 (48.3)	24 (80)	38 (64.6)
	Moderately asymmetrical	12 (41.3)	6 (20)	18 (30.5)
	Severely asymmetrical	3 (10.3)	0 (0)	3 (5.1)
Level	L2-L3	0 (0)	1 (3.3)	1 (1.6)
	L3-L4	5 (17.2)	3 (10)	8 (13.5)
	L4-L5	23 (79.3)	8 (36.7)	31 (52.5)
	L5-S1	1 (3.4)	18 (60)	19 (32.2)
	Meyerding grade in neutral x-ray	1	24 (82.8)	12 (40)
	2	5 (17.2)	18 (60)	23 (39.5)
Total		29 (49.2)	30 (50.8)	59 (100)

patients had neutral facets (Table I). For statistical purposes, patients with moderate and severe asymmetry were grouped together, comprising 35.6% of patients (Tables II and III).

Dynamic X-ray detected mobility of the spondylolisthesis in 52.5% of cases. There was a negative correlation between the presence of tropism and joint mobility on dynamic X-ray ($p=0.03$; Table II). There was no correlation between mobility and Modic ($p=0.35$) or Pfirrmann ($p=0.50$) classification. The degree of listesis was negatively correlated with the presence of FT ($p=0.02$; Table II).

As expected, there was a statistically significant correlation between listesis type and the level affected, with 82% of patients with degenerative spondylolisthesis having disease at the L4–L5 level and 60% of the patients with isthmic spondylolisthesis having disease at the L5–S1 level ($p<0.01$).

When the relationship between neutral X-ray and MRI findings was evaluated, substantial agreement was found in the diagnosis of grade I and II listesis comprising 54 out of 59 (91.52%) of participants (Table III).

Neutral X-ray was sufficient for the diagnosis of listesis as dynamic X-ray did not contribute further to making a definitive

Table II: Correlations Between Tropism, Mobility and Meyerding Grade. Mobility Was Associated with Absent Tropism ($p=0.03$) and the Absence of Tropism was Significantly More Prevalent in Grade 2 Spondylolisthesis ($p=0.02$)

	Absent tropism n (%)	Present tropism n (%)	p
Present mobility	24 (77.4)	7 (22.6)	0.03
Absent mobility	14 (50)	14 (50)	
Meyerding 1	19 (52.8)	17 (47.2)	0.02
Meyerding 2	19 (82.6)	4 (17.4)	

diagnosis. Dynamic plain radiography may have utility in assessing joint mobility (Table III).

DISCUSSION

Degenerative spondylolisthesis is reportedly more frequent in females and in the L4–5 segment (12). In corroboration with previous studies, we observed 82% (24/29) of patients had listhesis at the L4–L5 level and 62% (18/29) were women. In contrast, isthmic spondylolisthesis is reportedly more frequent in the L5–S1 segment and in males (1). Similarly in our study population, 60% (18/30) of patients with isthmic spondylolisthesis were affected at the L5–S1 level and 67% (12/18) of these individuals were men.

Regarding the best diagnostic method for spondylolisthesis, there is ongoing debate regarding the roles of static and dynamic (flexion/extension) lumbar X-ray compared to MRI. Traditionally, MRI is performed in the supine position and, thus, may underestimate any instability present in the upright position (8). In our study, MRI was able to diagnose all cases of grade I listhesis with substantial agreement observed with X-ray (Kappa, 0.81; CI, 0.66–0.97). A difference between the degree of displacement observed on neutral X-ray and MRI was observed in only five cases. In all of these cases, neutral X-ray demonstrated grade 2 listhesis, while grade 1 listhesis was seen on MRI. Thus, dynamic X-ray is the recommended modality for assessing the degree of listesis and joint mobility during surgical planning.

While static lumbar X-ray was sufficient for the diagnosis of spondylolisthesis, the complementary use of dynamic X-ray helps in defining segmental mobility and classifying listhesis as static or dynamic (8). This informs decisions regarding the most appropriate surgical strategy. As fixation is recommended in cases with joint mobility, the use of dynamic X-ray may avoid unnecessary use of fixation in patients without joint mobility.

Table III: Agreement Between Neutral X-Ray, Flexion X-Ray, Extension X-Ray and MRI for the Diagnosis of Spondylolisthesis

	Meyerding grade in neutral X-ray, n (%)			Kappa (CI 95%)
	1	2	3	
Meyerding grade in flexion X-ray	1	30 (83.33)	0 (0)	0.72 (0.57; 0.87)
	2	6 (16.67)	20 (86.96)	
	3	0 (0)	3 (13.04)	
Meyerding grade in extension X-ray	1	35 (97.22)	3 (13.04)	0.80 (0.66; 0.94)
	2	1 (2.78)	18 (78.26)	
	3	0 (0)	2 (8.7)	
Meyerding grade in MRI	1	36 (87.8)	5 (12.2)	0.81 (0.66; 0.97)
	2	0 (0)	18 (100.0)	
	3	0 (0)	0 (0)	

Kappa (CI 95%) was 0,72 (0,57; 0,87), 0,80 (0,66; 0,94) and 0,81 (0,66; 0,97), respectively.

FT represents unequal rotation of the lumbar facet joints in the axial plane, leading to asymmetry (3,8). Previous studies have posited a relationship between lumbar FT and spondylolisthesis. Patients with FT have also been shown to have more sagittally oriented facet joints (7,17). In contrast, joint mobility was found to be associated with the absence of tropism in the present study ($p=0.03$). Further, the absence of tropism was significantly more prevalent in patients with grade 2 spondylolisthesis ($p=0.02$). These findings suggest that FT may contribute to stabilization of the spine despite previously being reported as a risk factor for listhesis and joint instability (17). However, this issue remains controversial and further studies are required to definitively determine the relationship between FT and spondylolisthesis.

Intervertebral DG can be assessed by MRI, with the Pfirrmann classification currently the most widely used system (16). The contribution of intervertebral disc disease is a well established in the pathophysiology of degenerative spondylolisthesis (1,5). On the other hand, disc involvement occurs at a later stage in isthmic spondylolisthesis (1). In our study, all patients had some degree of disc involvement. However, this finding may represent selection bias as cases are referred to our tertiary care center and delays in initial patient care are common. A further limitation of our study was the heterogeneity of the study population. Accordingly, further studies comprising larger and more homogenous study cohorts are required to validate the findings of the present study.

CONCLUSION

MRI was sufficient for the diagnosis of lumbar spondylolisthesis and dynamic lumbar plain radiography was important for defining segmental mobility. In addition, FT was associated with lower spinal instability in the present study. Further large-scale studies with long-term clinical follow-up may increase our understanding of the role of FT in the pathogenesis of lumbar spondylolisthesis.

Declarations

Funding: The authors have no funding sources to declare.

Availability of data and materials: The corresponding author have all data available for further inquiries.

Disclosure: The authors have no grants, technical support, corporate support or conflict of interest to declare.

AUTHORSHIP CONTRIBUTION

Study conception and design: VMC, RIP, DSF, JLRB

Data collection: VMC, RIP, DSF

Analysis and interpretation of results: VMC, RIP, DSF, DCA, JLRB

Draft manuscript preparation: RIP, DSF

Critical revision of the article: VMC, DCA, JLRB

Other (study supervision, fundings, materials, etc...): VMC, JLRB

All authors (VMC, RIP, DSF, DCA, JLRB) reviewed the results and approved the final version of the manuscript.

REFERENCES

- Bhalla A, Bono CM: Isthmic lumbar spondylolisthesis. *Neurosurg Clin N Am* 30:283-290, 2019. <https://doi.org/10.1016/j.nec.2019.02.001>
- Boden SD, Wiesel SW: Lumbosacral segmental motion in normal individuals. Have we been measuring instability properly? *Spine* 15:571-576, 1990. <https://doi.org/10.1097/00007632-199006000-00026>
- Bogduk N: *Clinical Anatomy of the Lumbar Spine and Sacrum*. Elsevier Health Sciences, 2005
- Bogduk N: Functional anatomy of the disc and lumbar spine. In: Büttner-Janitz K, Hochschuler SH, McAfee PC (eds), *Artifical Disc*. Springer, 2003:19-32. https://doi.org/10.1007/978-3-662-05347-8_3
- Bydon M, Alvi MA, Goyal A: Degenerative lumbar spondylolisthesis: Definition, natural history, conservative management, and surgical treatment. *Neurosurg Clin N Am* 30:299-304, 2019. <https://doi.org/10.1016/j.nec.2019.02.003>
- Chaput C, Padon D, Rush J, Lenehan E, Rahm M: The significance of increased fluid signal on magnetic resonance imaging in lumbar facets in relationship to degenerative spondylolisthesis. *Spine* 32:1883-1887, 2007. <https://doi.org/10.1097/BRS.0b013e318113271a>
- Dai LY: Orientation and tropism of lumbar facet joints in degenerative spondylolisthesis. *Int Orthop* 25:40-42, 2001. <https://doi.org/10.1007/s002640000201>
- Even JL, Chen AF, Lee JY: Imaging characteristics of "dynamic" versus "static" spondylolisthesis: analysis using magnetic resonance imaging and flexion/extension films. *Spine J* 14:1965-1969, 2014. <https://doi.org/10.1016/j.spinee.2013.11.057>
- Golder W: Spondyl-olisthesis more than a problem of etymology (author's transl). *Rontgenblatter* 35:111, 1982
- Gussous Y, Theologis AA, Demb JB, Tangtiphaiboontana J, Berven S: Correlation between lumbopelvic and sagittal parameters and health-related quality of life in adults with lumbosacral spondylolisthesis. *Glob Spine J* 8:17-24, 2018. <https://doi.org/10.1177/2192568217696692>
- Hasegawa K, Kitahara K, Hara T, Takano K, Shimoda H: Biomechanical evaluation of segmental instability in degenerative lumbar spondylolisthesis. *Eur Spine J* 18:465-470, 2009. <https://doi.org/10.1007/s00586-008-0842-3>
- Jacobsen S, Sonne-Holm S, Rosing H, Monrad H, Gebuhr P: Degenerative lumbar spondylolisthesis: An epidemiological perspective: The Copenhagen osteoarthritis study. *Spine* 32:120-125, 2007. <https://doi.org/10.1097/01.brs.0000250979.12398.96>
- Koslosky E, Gendelberg D: Classification in brief: The Meyerding classification system of spondylolisthesis. *Clin Orthop Relat Res* 478:1125-1130, 2020. <https://doi.org/10.1097/CORR.0000000000001153>
- Kuhns BD, Kouk S, Buchanan C, Lubelski D, Alvin MD, Benzel EC, Mroz TE, Tozzi J: Sensitivity of magnetic resonance imaging in the diagnosis of mobile and nonmobile L4-L5 degenerative spondylolisthesis. *Spine J* 15:1956-1962, 2015. <https://doi.org/10.1016/j.spinee.2014.08.006>

15. Modic MT, Steinberg PM, Ross JS, Masaryk TJ, Carter JR: Degenerative disk disease: Assessment of changes in vertebral body marrow with MR imaging. *Radiology* 166:193-199, 1988. <https://doi.org/10.1148/radiology.166.1.3336678>
16. Pfirrmann CW, Metzdorf A, Zanetti M, Hodler J, Boos N: Magnetic resonance classification of lumbar intervertebral disc degeneration. *Spine* 26:1873-1878, 2001. <https://doi.org/10.1097/00007632-200109010-00011>
17. Samartzis D, Cheung JPY, Rajasekaran S, Kawaguchi Y, Acharya S, Kawakami M, Satoh S, Chen WJ, Park CK, Lee CS, Foocharoen T, Nagashima H, Kuh S, Zheng Z, Condor R, Ito M, Iwasaki M, Jeong JH, Luk KDK, Prijambodo B, Rege A, Jahng TA, Luo Z, Tassanawipas W, Acharya N, Pokharel R, Shen Y, Ito T, Zhang Z, Aithala P J, Kumar GV, Jabir RA, Basu S, Li B, Moudgil V, Goss B, Sham P, Williams R: Critical values of facet joint angulation and tropism in the development of lumbar degenerative spondylolisthesis: An international, large-scale multicenter study by the aospine asia pacific research collaboration consortium. *Global Spine J* 6:414-421, 2016. <https://doi.org/10.1055/s-0035-1564417>
18. Vanharanta H, Floyd T, Ohnmeiss DD, Hochschuler SH, Guyer RD: The relationship of facet tropism to degenerative disc disease. *Spine* 18:1000-1005, 1993. <https://doi.org/10.1097/00007632-199306150-00008>
19. Viera AJ, Garrett JM: Understanding interobserver agreement: The kappa statistic. *Fam Med* 37:360-363, 2005
20. Wiltse LL, Newman PH, Macnab I: Classification of spondylolysis and spondylolisthesis. *Clin Orthop Relat Res* (117):23-29, 1976. <https://doi.org/10.1097/00003086-197606000-00003>