



DOI: 10.5137/1019-5149.JTN.20662-17.1

Received: 05.05.2017 / Accepted: 11.07.2017

Published Online: 18.09.2017

## Case Report

# Paramedian Forehead Flap for Repair of Refractory High-Flow Anterior Skull Base CSF Leak

Jeremy N. CIPOREN<sup>1</sup>, Brandon LUCKE-WOLD<sup>2</sup>, Haley E. GILLHAM<sup>1</sup>, David CUA<sup>3</sup>, Jason KIM<sup>3</sup>, Paul AKINS<sup>3</sup>

<sup>1</sup>Oregon Health & Science University, Department of Neurosurgery, Portland, OR, USA

<sup>2</sup>West Virginia University School of Medicine, Department of Neurosurgery, Morgantown, WV, USA

<sup>3</sup>The Permanente Medical Group, Department of Neurosurgery, Sacramento, CA, USA

## ABSTRACT

The paramedian forehead flap (PMFF) has been well described for nasal reconstruction. However, it has never been reported for use in the repair of high flow anterior skull base cerebrospinal fluid (CSF) leaks.

The patient was a 55 year-old African American male cocaine abuser who initially presented with a high flow anterior skull base CSF leak, extensive pneumocephalus, and intra-cerebral and intra-ventricular abscesses with an oro-nasal-cerebral fistula. The patient initially underwent bi-frontal craniotomy, exenteration of the frontal sinus, abdominal fat graft, resection of intra-cerebral abscesses, and repair of high flow anterior skull base CSF leak with a pedicled pericranial flap (PF). Eighteen months after the patient's surgery, he had resumed his use of cocaine and suffered necrosis of his PF. This caused his high flow CSF leak to recur. After extensive psychiatric treatment, he stopped cocaine use and was subsequently repaired with a pedicled de-epithelialized PMFF originating off the bilateral supratrochlear arteries. The patient has had no CSF leak for 3 years, and primary closure of the forehead was achieved with good cosmetic outcome.

This case highlights the use of PMFF for the treatment of recurrent high flow anterior skull base CSF leak. It also highlights the importance of treatment of the patient's underlying medical disorder, in this case, the patient's addiction to cocaine. We provide a detailed discussion for the use of the de-epithelialized PMFF and how it can be utilized as a vascularized reconstructive technique to repair complex refractory CSF leaks.

**KEYWORDS:** Cocaine abuse, High-flow cerebrospinal fluid leak, Paramedian forehead flap, Pedicled reconstruction technique

## INTRODUCTION

Cocaine is well known for its nasal toxicity (30). ~10% of cocaine abusers have nasal septal perforations that can progress to involve the vomer or ethmoidal lamina, due to vasoconstriction (7). When the perforation is large, it presents a unique challenge that must be managed surgically. If left untreated, it can lead to severe epistaxis, obstruction, erosion into the palate, and infection (21). Mixed success rates have been reported for septal closure in the literature (19). Cocaine abuse causes persistent nasal necrosis, which leads to poor wound healing and increased risk for continued defects

following surgical reconstruction (10). The nasal osteonecrosis occurs due to devascularization from continued cocaine abuse. The neurological surgeon and otorhinolaryngologist must carefully consider the reconstructive options relative to each patient's pathology and co-morbidities. Ideally, the patient should be cocaine free for multiple months to years before attempting a reconstruction surgery. If cocaine use continues post-surgery an abscess can develop, which often progresses and must be managed emergently (14). The abscess can contribute to intracerebral fistula formation and cerebrospinal fluid (CSF) leak. It is therefore critical that the patient remain cocaine free. We present an interesting case



Corresponding author: Jeremy CIPOREN

E-mail: ciporen@ohsu.edu

of pericranial flap (PF) failure and refractory CSF leak in a cocaine abuser who started using cocaine again post-surgery. A subsequent successful closure via a de-epithelialized paramedian forehead flap was performed.

## ■ CASE REPORT

The patient was a 55-year-old African American male with an extensive history of cocaine abuse. He presented to the emergency room emergently with altered mental status and a high flow CSF leak, frontal lobe abscess, ventriculitis, and leptomeningeal enhancement with pneumocephalus. The patient had a defect in his palate that communicated with his nasal cavity, which further communicated through an anterior skull base defect into the frontal lobe and lateral ventricle. He required emergent external ventricular placement, bi-frontal craniotomy, resection of the intracerebral abscess, and exenteration and obliteration of the frontal sinus. The anterior skull base defect was repaired with a temporalis fascia graft and pedicled pericranial graft. The patient's nasal cavity was devoid of nasal septum and turbinates. Chronic osteomyelitis was evident consistent with chronic cocaine abuse. After surgery, the patient recovered well and was discharged neurologically intact on intravenous (IV) antibiotics. The patient was followed with serial magnetic resonance imaging (MRI) and inflammatory markers (C-reactive protein (CRP), erythrocyte sedimentation rate (ESR) and white blood cell (WBC)). Our infectious disease specialists discontinued the IV antibiotics months after surgery based on the patient's clinical exam, results of blood work, and imaging. The patient was followed off of antibiotics without concern for recurrence. The patient had also stopped using cocaine during these months of recovery.

Eighteen months after the patient's initial presentation and surgery he presented to the emergency room with a recurrent high flow anterior skull base CSF leak and meningitis. The patient reported that he had started abusing cocaine again months prior to this recurrence. This was evident in that the pericranial flap had an area of necrosis consistent with the use of cocaine abuse (Figure 1A, B). Our skull base team, neurosurgery and otorhinolaryngologists, considered the reconstructive options. Reconstructive options were limited. He did not have nasal septal or turbinate tissue to be used for reconstruction secondary to chronic osteomyelitis. The pedicled PF had been utilized. The options were free flap or pedicled paramedian forehead flap (PMFF). Intra-operatively, we were prepared for a radial forearm free flap and a pedicled de-epithelialized PMFF. The patient had dopplerable supratrochlear and supraorbital arteries. Since the PMFF dopplered was vascularly viable it was deemed to be the best for reconstruction. In so doing the risks of free flap failure and donor site morbidity were avoided. We performed a redo-bifrontal craniotomy, exposure, and resection of the necrotic region of the PF. A medpor implant was placed to reconstruct the large bone defect in the cribriform plate (Figure 1A, B). A porous polyethylene (Medpor®) implant was chosen for its porosity increasing the likelihood for tissue in-growth. The supratrochlear arteries demonstrated good

blood flow via doppler signal and palpation. The PMFF was designed for reconstruction (Figure 2A-C). The PMFF was de-epithelialized to minimize the risk of intracerebral epidermoid growth (Figure 3). The de-epithelialized PMFF was positioned and secured with suture to the skull base dura. The frontal bone was replaced and it was ensured that the pedicle to the flap was not compromised (Figure 1A, B). The forehead and coronal incisions were closed primarily without the need for scalp rotational flaps or skin grafts. An excellent cosmetic result was obtained (Figure 4A, B). The patient was discharged neurologically intact without CSF leak. He was treated with iv antibiotics. He stopped using cocaine after extensive psychiatric treatment. Clinical examination, serum inflammatory markers (CRP and ESR, WBC), and MRI were serially followed. IV antibiotics were stopped a few months after surgery. The patient complied with a palate obturator to promote wound healing. There was no report of recurrent CSF leak or flap failure for 3 years post-PMFF reconstruction.

## ■ DISCUSSION

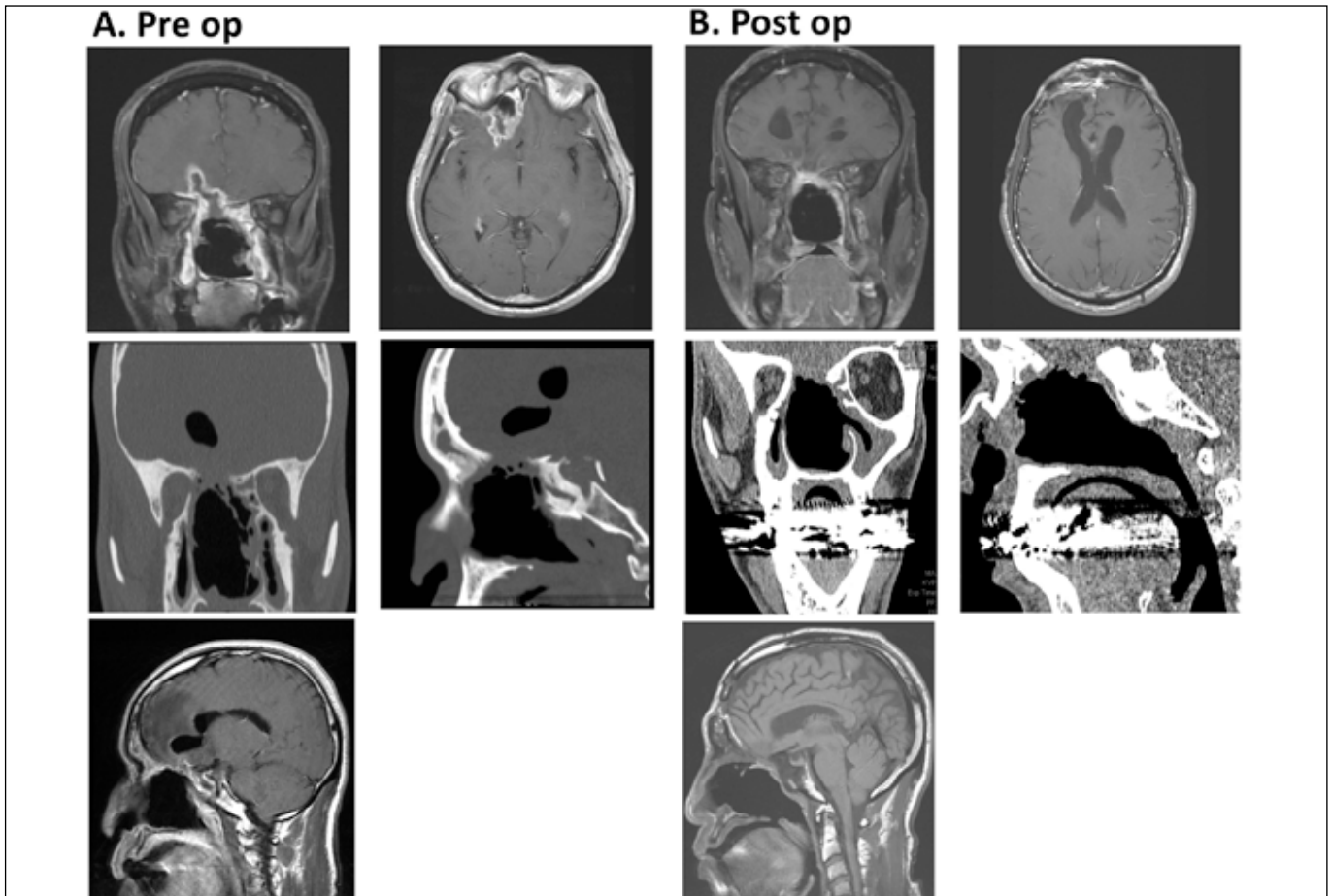
Cocaine abuse can cause devastating orofacial effects including nasal perforations, oral lesions, and erosion into the palate (5). Over time these lesions can evolve into oronasal communications that increase the risk for infection (25). In order for surgery to be successful, the patient must agree to remain cocaine free (13). When cocaine is continued post-reconstruction, the patient is at risk for frontal sinus abscesses and osteocartilaginous degeneration (40). Over time the nasal passages can collapse forming what has been termed a 'voldemort deformity' (17). In some patients, osteomyelitis may even develop if cocaine use continues unabated (33). In our patient, the devascularized tissue and osteonecrosis was so extensive (Figure 1A, B) that an endoscopic endonasal approach could not be done. A flap must be chosen that recapitulates the texture and lining of the nasal passage, but must also be strong enough to maintain the integrity of the subarachnoid space to avoid CSF leak (41). Normally, an endoscopic nasoseptal flap is utilized, but since a pericranial graft was done for the first repair, a different flap had to be chosen.

The PMFF is the gold standard for nasal reconstruction in these cases (8). Pedicled PMFF can be shaped for reconstructing full-nasal septal defects and restoring subarachnoid space integrity (1). They are the ideal choice for large perforations involving the nasal pyramid and frontal sinus (42). The advantage of the pedicled PMFF is that it can be used in a single stage nasal reconstruction procedure with little risk of contracture (31). With the appropriate maintenance of vascular supply, proper skin care, good debridement, and patient counseling, the long-term success rates with the forehead flap are quite good (38). The forehead flap is also advantageous in that it provides excellent cosmetic outcomes for patients (22). We found that the PMFF was successful even after a history of cocaine abuse. The surgery required extensive de-epithelialization and aggressive treatment of the frontal abscess, but the patient recovered remarkably well post-surgery.

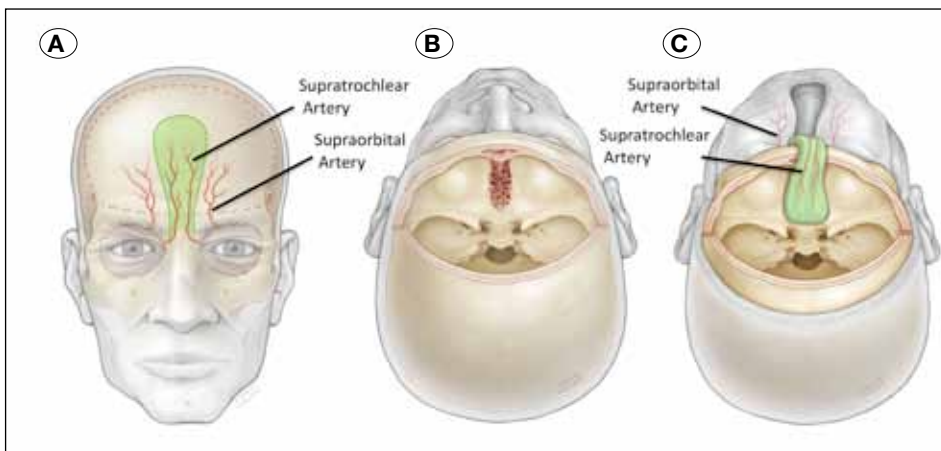
Recovery is highly dependent on vascular supply to the flap. The supraorbital and supratrochlear arteries supply the

pericranial flap (Table I) (43). The supratrochlear artery also is the primary supplier for the PMFF (18). In the reported case a PMFF was used to repair a nasal septal defect following a failed pericranial flap. The work horse pericranial and nasal septal flaps typically have rich vascular supply with abundant

anastomosis thereby facilitating superficial shaping near the periphery (16). With appropriate debridement at the site of translocation, the flaps can be preferentially shaped to avoid unnecessary removal of excess tissue at the donor site (11). Unfortunately, due to the high vascularity of the pericranial



**Figure 1: A)** Preoperative. Pneumocephalus, cerebral edema and intracerebral abscess secondary to an anterior skull base defect is seen. The nasal cavity is devoid of septum and turbinates secondary to chronic cocaine abuse and de-vascularization of the nasal mucosa, cartilage and bone. **B)** Postoperative. Well-healed and vascularized paramedian flap that is visualized on imaging. Adequately resolved pneumocephalus, cerebral edema and abscess with complete obliteration of the preoperative fistula.



**Figure 2: A)** Identifies the vascular anatomy and supply of the paramedian forehead flap via the supratrochlear arteries and the pericranial flap via the supraorbital and supratrochlear arteries. **B)** The region of the skull base defect, the cribriform plate, is detailed for reference as to the location of the anterior skull base defect. **C)** Illustrates the insert of the de-epithelialized paramedian forehead flap (PMFF) and repair technique for anterior skull base defects. The vascular anatomy supplying the PMFF is also demonstrated.

flap, it is also increasingly susceptible to ischemic infarction days to weeks post-translocation (27). Cocaine use increases the risk for ischemic events (44), which hastened the flap failure in the reported case. Pericranial flaps are also known to have increased risk for CSF leaks following ischemia (24). Fortunately, the early segments of the trochlear artery were still viable allowing successful closure and reconstruction with the PMFF.

The ongoing challenge for the surgeons and medical team post-reconstruction is working with the patient to end the cocaine abuse. This is a critical and necessary step for any long-term reconstruction success to be maintained. Regrettably, cocaine is one of the most addictive drugs known to man (3). Despite the addictive nature of cocaine, treatment-seeking cocaine abusers have a higher resolve to quit than other drug users due to the medical side effects of cocaine use (6). The approach to treat cocaine-dependence should be based on both pharmacologic and behavioral intervention. Recent advances in targeting neuropeptide receptors may offer promise

for targeting the reward center within the brain that is altered by cocaine abuse (26). Other vaccine based approaches are currently in stage 3 clinical trials and have been shown to target receptors within the brain associated with cocaine addiction (28). Additionally, attending narcotics anonymous meetings in conjunction with pharmacologic treatment has been useful for patients to remain cocaine free over extended periods of time (20).

### ■ CONCLUSION

This case highlights the use of PMFF for the treatment of recurrent high flow anterior skull base CSF leak. It also stresses the importance of treatment of the patient's underlying medical disorder. In this case, the patient's addiction to cocaine caused life threatening high flow CSF leaks and intracerebral infections. In this paper, we highlight the distinctive and well-described vascular anatomy that serves the PMFF and the PF. The PF is supplied by the supraorbital and supratrochlear arteries, whereas the PMFF is supplied by the supratrochlear arteries

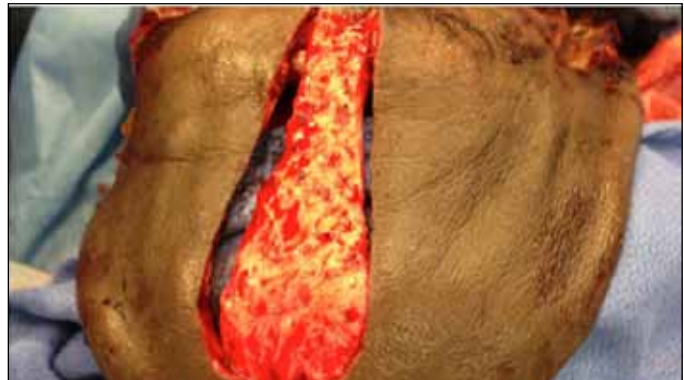
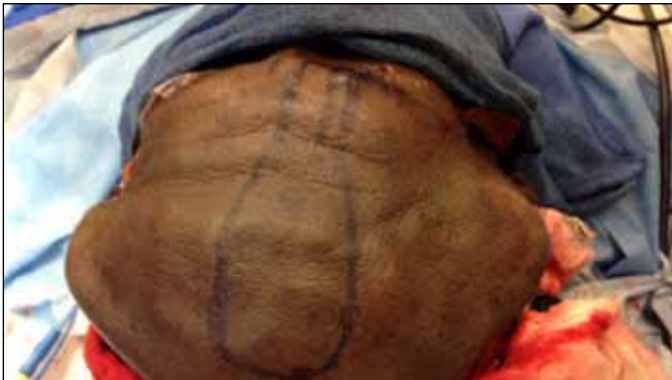
Figure 3: Intraoperative picture of flap preparation.

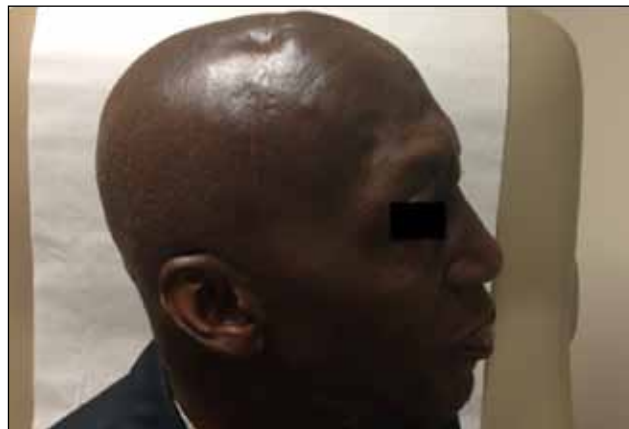

Figure 4: Postoperative excellent cosmetic outcome.



(Figure 3). In the vast majority of cases a free flap would have been the reconstruction technique utilized in a similar case. Our review of the literature supports this statement. Despite the well-described and understood vascular anatomy of the PMFF, it appears underutilized as a vascularized pedicled flap for CSF leak repair and the reconstruction of anterior skull base defects. This may be due to the assumption that a failed PF means the PMFF is likely to fail. The de-epithelialized PMFF obviated the need for free flap and the potential recipient and donor site complications that may occur. The vascular anatomy differences of the PF and PMFF allow for the PMFF to be a viable option despite the previous utilization of a PF as long as the supratrochlear arteries are dopplerable

and deemed to have good flow pre-operatively. The de-epithelialized PMFF adds to the vascularized reconstructive techniques utilized to repair complex refractory CSF leaks and anterior skull base defects.

## ■ ACKNOWLEDGEMENTS

The authors would like to thank the Oregon Health & Science University for the use of its facilities. Brandon Lucke-Wold received a Pre-doctoral Grant from the American Foundation of Pharmaceutical Education, an American Medical Association Seed Grant, and a Neurosurgery Research and Education Foundation Medical Student Summer Research Fellowship.

**Table I:** Various Uses of the Paramedian Forehead Flap

Study	Type	Indications	Findings
Ahmed et al., 2015 (2)	Paramedian Forehead Flap	Reconstruct deep and large nasal defect	Good color and texture match
Taylor and Chang, 2016 (37)	Flap Simulator	Resident training on how to fabricate flaps	Used to teach residents how to perform Z-plasty, bilobed, rhomboid, and paramedian forehead flaps
Blazquez-Sanchez et al., 2016 (4)	Paramedian Forehead Flap	Reconstruction of underlying cartilage and nasal mucosa defects	The flap is versatile and provides excellent cosmetic outcomes
Stahl et al., 2015 (36)	2-stage versus 3-stage Paramedian Forehead Flap	Aesthetic reconstruction	The 2-stage flap remains superior for nasal reconstruction
Ribeiro et al., 2015 (32)	Paramedian Forehead Flap	Complex nasal reconstruction	Advantageous for reconstruction after paracoccidioidomycosis infection
de Pochat et al., 2014 (9)	Paramedian Forehead Flap	Nasal reconstruction of lesions	The nasal subunits principle contributes to aesthetic satisfaction of the patients
Jellinek et al., 2014 (15)	Paramedian Forehead Flap	Reconstruction of large nasal defects	Nuances and variations in the technique make the flap extremely versatile
Tripathy and John, 2014 (39)	Paramedian Forehead Flap	Total Nasal Reconstruction	Workhorse flap with minimal morbidity
Smart et al., 2014 (35)	Paramedian Forehead Flap	Posttraumatic nasal reconstruction	Utilized 2-stage technique
Parker et al., 2014 (29)	Paramedian Forehead Flap	Medial Canthal Defects	Excellent function of lacrimal conduit achieved
Skaria 2015 (34)	Paramedian Forehead Flap verse Median Forehead Flap	Repair of defect on the nose	Although lacking a pedicled artery, the median forehead flap is performed similar to the pedicled paramedian forehead flap
Newman et al., 2003 (23)	Pericranial Flap and Paramedian Forehead Flap	Repair of medial canthal and lateral nasal defects	The combined use of the two flaps was successful in defect repair
Griner et al., 2014 (12)	Paramedian Forehead Flap	Treatment of chronic anterior cranial fossa defect	Treatment was successful even with history of persistent sinus outflow tracks and post-trauma soft tissue damage

## ■ REFERENCES

- Agostini T, Perello R, Russo GL, Spinelli G: Through-and-through nasal reconstruction with the bi-pedicled forehead flap. *Arch Plast Surg* 40(6):748-753, 2013
- Ahmed SS, Ghassemi A, Rehman SA, Ansari MK: Forehead flap in maxillofacial surgery: Our experiences. *Natl J Maxillofac Surg* 6:72-75, 2015
- Badin de Montjoye B, Podevin P, Pharo P: Abstinence from cocaine after long-term addiction. *Encephale* 37(6):404-409, 2011 (In French)
- Blazquez-Sanchez N, Fernandez-Canedo I, Repiso-Jimenez JB, Rivas-Ruiz F, Martin MT: Usefulness of the paramedian forehead flap in nasal reconstructive surgery: A retrospective series of 41 patients. *Actas Dermosifiliogr* 107:133-141, 2016
- Brand HS, Gonggrijp S, Blanksma CJ: Cocaine and oral health. *Br Dent J* 204(7):365-369, 2008
- Budney AJ, Radonovich KJ, Higgins ST, Wong CJ: Adults seeking treatment for marijuana dependence: A comparison with cocaine-dependent treatment seekers. *Exp Clin Psychopharmacol* 6(4):419-426, 1998
- Businco LD, Lauriello M, Marsico C, Corbisiero A, Cipriani O, Tirelli GC: Psychological aspects and treatment of patients with nasal septal perforation due to cocaine inhalation. *Acta Otorhinolaryngol Ital* 28(5):247-251, 2008
- Correa BJ, Weathers WM, Wolfswinkel EM, Thornton JF: The forehead flap: The gold standard of nasal soft tissue reconstruction. *Semin Plast Surg* 27(2):96-103, 2013
- de Pochat VD, Alonso N, Ribeiro EB, Figueiredo BS, de Magaldi EN, Cunha MS, Meneses JV: Nasal reconstruction with the paramedian forehead flap using the aesthetic subunits principle. *J Craniofac Surg* 25:2070-2073, 2014
- Dosen LK, Haye R: Endonasal surgery after cocaine abuse: Safe at any interval? *Case Rep Otolaryngol* 2012:823470, 2012
- Gordon CR, Fisher M, Liauw J, Lina I, Puvanesarajah V, Susarla S, Coon A, Lim M, Quinones-Hinojosa A, Weingart J, Colby G, Olivi A, Huang J: Multidisciplinary approach for improved outcomes in secondary cranial reconstruction: Introducing the pericranial-onlay cranioplasty technique. *Neurosurgery* 10 Suppl 2:179-89, 2014
- Griner D, Sargent LA: Paramedian forehead flap to treat chronically infected base of skull defect in a posttraumatic patient. *Ann Plast Surg* 72:S121-123, 2014
- Guyuron B, Afroz PN: Correction of cocaine-related nasal defects. *Plast Reconstr Surg* 121(3):1015-1023, 2008
- Hosemann W, Draf C: Danger points, complications and medico-legal aspects in endoscopic sinus surgery. *GMS Curr Top Otorhinolaryngol Head Neck Surg* 12: Doc06, 2013
- Jellinek NJ, Nguyen TH, Albertini JG: Paramedian forehead flap: Advances, procedural nuances, and variations in technique. *Dermatol Surg* 40 Suppl 9: S30-42, 2014
- Karsidag S, Ozcan A, Ozkaya O, Ugurlu K, Bas L: Use of wide bipedicled pericranial flap in anterior scalp reconstruction. *J Craniofac Surg* 20(6):2248-2251, 2009
- Kozin ED, Glikich RE: Voldemort deformity: Nasolabial transposition technique for severe nasal inlet stenosis. *Otolaryngol Head Neck Surg* 151(6):1078-1080, 2014
- Matthias C: Surgery of the nasal septum and turbinates. *GMS Curr Top Otorhinolaryngol Head Neck Surg* 6:Doc10, 2007
- Mocella S, Muia F, Giacomini PG, Bertossi D, Residori E, Sgroi S: Innovative technique for large septal perforation repair and radiological evaluation. *Acta Otorhinolaryngol Ital* 33(3):202-214, 2013
- Monico LB, Gryczynski J, Mitchell SG, Schwartz RP, O'Grady KE, Jaffe JH: Buprenorphine treatment and 12-step meeting attendance: Conflicts, compatibilities, and patient outcomes. *J Subst Abuse Treat* 57:89-95, 2015
- Mullace M, Gorini E, Sbrocca M, Artesi L, Mevio N: Management of nasal septal perforation using silicone nasal septal button. *Acta Otorhinolaryngol Ital* 26(4):216-218, 2006
- Namdev LN, Darbari A: Nasal reconstruction with forehead flap: Our experience. *Indian J Otolaryngol Head Neck Surg* 65(2):177-180, 2013
- Newman J, Costantino P, Moche J: The use of unilateral pericranial flaps for the closure of difficult medial orbital and upper lateral nasal defects. *Skull Base* 13:205-209, 2003
- Noone MC, Osguthorpe JD, Patel S: Pericranial flap for closure of paramedian anterior skull base defects. *Otolaryngol Head Neck Surg* 127(6):494-500, 2002
- Nord GA, Rock A, Murphy FJ, Miloslavskiy I, Miller DJ, Wasserman BS: Prosthetic and surgical management of oronasal communications secondary to cocaine abuse. *N Y State Dent J* 78(1):22-25, 2012
- Olive MF: Neurokinin-1 (NK1) receptor antagonists as possible therapeutics for psychostimulant use disorders. *CNS & neurological disorders drug targets* 14(6):700-706, 2015
- Origitano TC, Petruzzelli GJ, Vandevender D, Emami B: Management of malignant tumors of the anterior and anterolateral skull base. *Neurosurg Focus* 12(5):e7, 2002
- Orson FM, Kinsey BM, Singh RA, Wu Y, Gardner T, Kosten TR: Substance abuse vaccines. *Ann N Yk Acad Sci* 1141:257-269, 2008
- Parker AM, Richardson MA, Jordan JR: Functional reconstruction of large medial canthal defects. *Facial Plast Surg* 30: 656-660, 2014
- Patel R, Shah R, Baredes S, Spillert CR, Lazaro EJ: Nasal toxicity of cocaine: A hypercoagulable effect? *J Natl Med Assoc* 92(1):39-41, 2000
- Rao J, Deora H: Surgical excision with forehead flap as single modality treatment for Basal cell cancer of central face: Single institutional experience of 50 cases. *J Skin Cancer* 2014: 320792, 2014
- Ribeiro EB, Pochat VD, Magaldi EN, Figueiredo BS, Alonso N, Meneses JV: Complex nasal reconstruction after paracoccidioidomycosis infection-Case report. *An Bras Dermatol* 90: 203-205, 2015
- Richter RW: Infections other than AIDS. *Neurol Clin* 11(3): 591-603, 1993
- Skaria AM: The median forehead flap reviewed: A histologic study on vascular anatomy. *Eur Arch Otorhinolaryngol* 272: 1231-1237, 2015
- Smart RJ, Yeoh MS, Kim DD: Paramedian forehead flap. *Oral Maxillofac Surg Clin North Am* 26:401-410, 2014

36. Stahl AS, Gubisch W, Haack S, Meisner C, Stahl S: Aesthetic and functional outcomes of 2-stage versus 3-stage paramedian forehead flap techniques: A 9-year comparative study with prospectively collected data. *Dermatol Surg* 41: 1137-1148, 2015
37. Taylor SR, Chang CW: Gelatin facial skin simulator for cutaneous reconstruction. *Otolaryngol Head Neck Surg* 154: 279-281, 2016
38. Thornton JF, Griffin JR, Constantine FC: Nasal reconstruction: An overview and nuances. *Semin Plast Surg* 22(4):257-268, 2008
39. Tripathy S, John JR: Customizing the paramedian forehead flap for total nasal reconstruction. *J Craniofac Surg* 25:e308-309, 2014
40. van der Poel NA, Schot LJ, Menger DJ: Local complications of intranasal cocaine abuse: Diagnostic and therapeutic guidelines. *Ned Tijdschr Geneesk* 157(24):A6035, 2013
41. Walton RL, Burget GC, Beahm EK: Microsurgical reconstruction of the nasal lining. *Plast Reconstr Surg* 115(7):1813-1829, 2005
42. Yoon T, Benito-Ruiz J, Garcia-Diez E, Serra-Renom JM: Our algorithm for nasal reconstruction. *J Plast Reconstr Aesthet Surg* 59(3):239-247, 2006
43. Yoshioka N, Rhoton AL Jr: Vascular anatomy of the anteriorly based pericranial flap. *Neurosurgery* 57 Suppl 1: 11-16, 2005
44. Zhou W, Lin PH, Bush RL, Nguyen L, Lumsden AB: Acute arterial thrombosis associated with cocaine abuse. *J Vasc Surg* 40(2):291-295, 2004