

## Case Report

# Pregnant Woman With Subarachnoid Hemorrhage and Multiple Intracranial Aneurysms: A Case Report

### ABSTRACT

Aneurysmal subarachnoid haemorrhage (SAH) during pregnancy is rare but serious obstetric complication and may be confused with eclampsia. SAH occurs more often in primiparae and in the third trimester of pregnancy. The hemodynamic and endocrine changes play an important role in the growth and rupture of aneurysms. There are no differences in the clinical course of SAH among pregnant and non-pregnant patients. A 19-yr-old woman who was 34-weeks pregnant presented with an SAH, secondary to a ruptured left posterior communicating artery (L-PCoM) aneurysm. The angiogram revealed multiple cerebral aneurysms. Following initial recovery, she subsequently underwent simultaneous elective caesarean section and clipping of the aneurysms. The management and pathogenesis of a ruptured aneurysm during pregnancy is discussed.

**KEY WORDS:** Aneurysm, Pregnancy, Subarachnoid haemorrhage

### INTRODUCTION

The maternal and foetal morbidity and mortality in pregnancies complicated by cerebrovascular disorders (CVD) remain high despite the improved diagnostic capabilities of modern neuroimaging techniques. CVD's (infarction, intracranial haemorrhage, hypertensive encephalopathy) contribute to as many as 12% of all maternal deaths (3,9,15,16). These complications may be easily confused with eclampsia because they may share many clinical characteristics. Misdiagnosis of CVD's as eclampsia is not an uncommon condition (11,16). We report a pregnant woman who suffered a subarachnoid haemorrhage (SAH) due to rupture of an aneurysm.

### CASE REPORT

A 19-year-old pregnant woman at 34 weeks gestation was admitted to another hospital with complaint of severe headache and vomiting followed by transient loss of consciousness ten days ago. Eclampsia was diagnosed and treatment started. One week later she again complained a sudden, severe and progressive headache. Cranial computed tomography (CT) and magnetic resonance scans (MR) were normal. She was referred to our hospital. On admission, she was found to have a left third nerve palsy, slight right hemiparesis, and neck stiffness. Lumbar puncture was performed and SAH was confirmed. She had one previous normal delivery at term two years ago. The antenatal period was uneventful. Her labour pain became frequent and labour began. After consultation with the attending Gynaecologist and Perinatologist, a

Ayhan KOÇAK<sup>1</sup>

Özkan ATEŞ<sup>2</sup>

Süleyman Rüştü ÇAYLI<sup>3</sup>

Kaya SARAÇ<sup>4</sup>

<sup>1,2,3</sup> Department of Neurosurgery,  
Faculty of Medicine, İnönü University  
Malatya, Turkey

<sup>4</sup> Department of Radiology,  
Faculty of Medicine, İnönü University  
Malatya, Turkey

Received : 07.11.2005

Accepted : 18.11.2005

Correspondence address:

**Ayhan KOÇAK**

P.K. 125 Malatya, 44000 TURKEY

Phone : +90 422 3410660/3207

Fax : +90 422 3410600

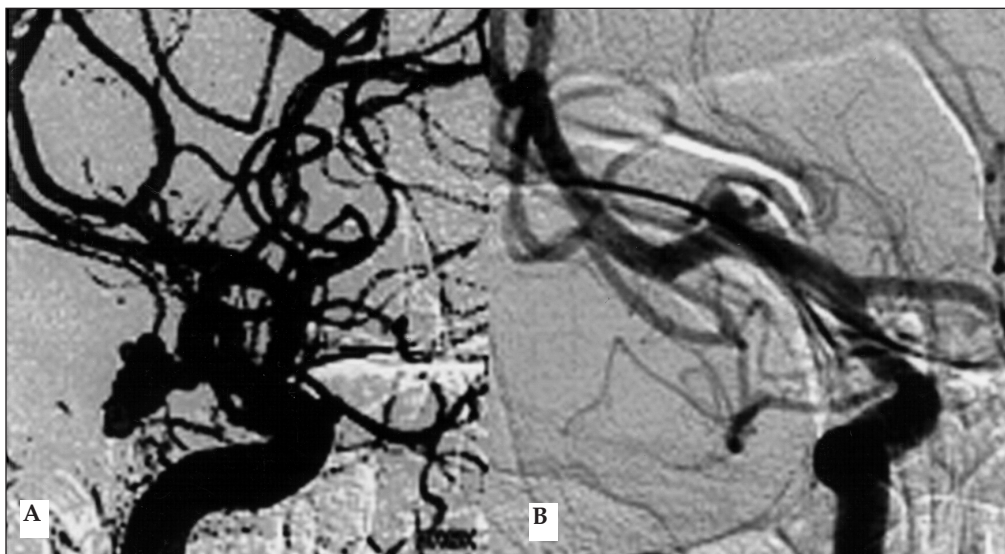
E-mail : akocak@inonu.edu.tr

: akocak\_99@yahoo.com

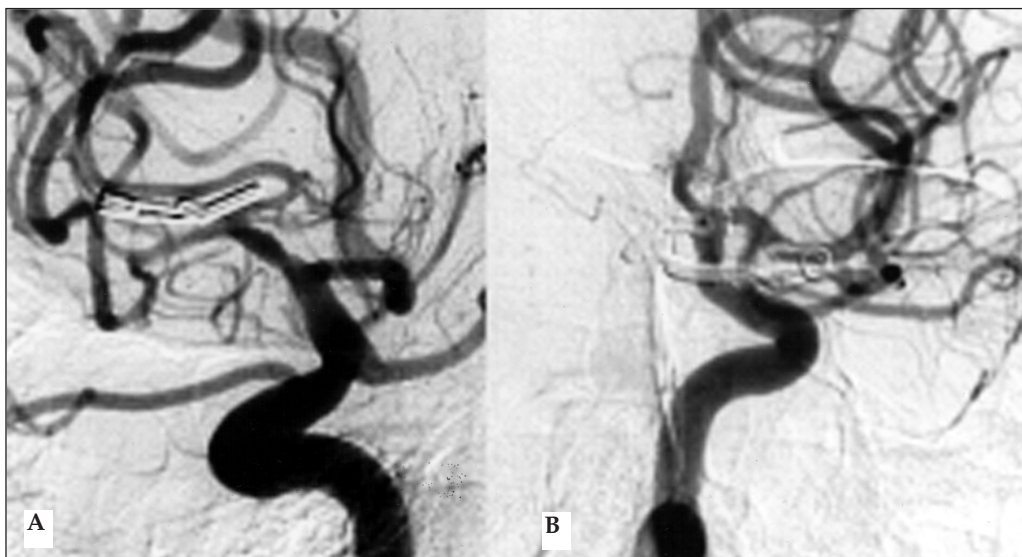
: ayhankocak112@hotmail.com

decision was made to deliver the foetus by caesarean section. The patient was placed under general anaesthesia in the operating room, and a healthy female infant was delivered by caesarean section. While still under general anaesthesia, she was transported to the neurointerventional angiography unit, and diagnostic cerebral digital subtraction angiography (DSA) was carried out which showed a 7x8 mm multi-lobulated saccular aneurysm in the left posterior communicating artery and a 3x3 mm saccular aneurysm in the right middle cerebral artery (MCA) bifurcation (Figures 1A, B). She was transported to the operating room again. Left

pterional craniotomy revealed a L-PCoM A aneurysm and its neck was successfully clipped. Another berry aneurysm of the internal carotid artery bifurcation was coagulated by non-sticking bipolar forceps and wrapped by fascia and tissue adhesive (TisseelÆ kit, Baxter AG, Austria). Using the same section, an MCA bifurcation aneurysm was exposed via right pterional craniotomy and its neck was clipped. Basal cisterns were irrigated and clot residues were taken out. The postoperative period was uneventful and the patient did well. Follow-up cerebral DSA 6 months later did not show any aneurysms (Figures 2A, B)



**Figure 1:** (A) A left carotid artery injection on cerebral angiogram demonstrates a multi-lobulated aneurysm of the left posterior communicating artery, (B) a right carotid artery injection on cerebral angiogram shows an aneurysm of the right middle cerebral artery



**Figure 2:** After clipping, there is no filling of aneurysms with either left carotid (A) or right carotid (B) artery injections.

## DISCUSSION

Preeclampsia and eclampsia are more common than SAH in pregnant women. The differential diagnosis between eclampsia and SAH should not normally pose much difficulty. Eclampsia is an acute disorder, heralded by tonic-clonic convulsions, caused in some way by the hypertension induced or exacerbated by pregnancy. It is most commonly manifest in the last trimester. A hyperexcitable state commonly precedes the convulsion. The diastolic blood pressure is generally elevated above 90 mmHg in this catastrophic condition. A weight gain of more than 900 gr per week or 2,7 kg per month occurs, the patient may have physical signs of generalized oedema and gradually increasing proteinuria will have developed. Platelet numbers may fall and disseminated intravascular coagulation supervene. Headaches, epigastric and right upper quadrant pain, visual blurring, and decreased acuity may also be complaints. The differential diagnosis includes idiopathic epilepsy, encephalitis, meningitis, cerebral tumour, acute porphyria, and hysteria as well as SAH (14,16)

The CVD's, known collectively as "stroke", afflict all ages. Among women of reproductive age the incidence of stroke is increased several-fold by pregnancy (1,19). Intracranial haemorrhage during pregnancy, from an intracranial aneurysm or arteriovenous malformation, is a grave complication that is responsible for 5% to 12% of all maternal deaths (18). The incidence of aneurysmal SAH is approximately 1 per 1000 pregnancies (2,5,12). Dias and Sekhar (5) found the mean age for pregnant patients with aneurysmal SAH to be 29.4 years, and the mean gestational age to be 30.5 weeks.

In Fox's review (6) of the world aneurysm literature up to 1979, there were 112 patients with 124 aneurysms who were in the immediate postpartum period. The location of these aneurysms corresponded to the usual distribution in the non-pregnant female population. Multiple aneurysms are present in 5%-20% of cases (5,6,12). Between October 2000 and January 2005, a total 286 patients were admitted to our department with the presenting diagnosis of SAH and surgical intracerebral haematoma (sICH). 126 of 218 (58%) SAH patients and 47 of 68 (69%) sICH patients were female. Forty-one of 218 (19%) SAH patients had multiple aneurysms (24 female, 17 male). Eight of

the patients (3%) that presented with hemorrhagic stroke were pregnant. Five of these patients had intracerebral haematomas and 3 had SAH (Table I). In other words there were three pregnant SAH patients in our female SAH series (2.3 %) and one had multiple intracranial aneurysms. Two of them were admitted during the third trimester and the other case was admitted in the second trimester.

The incidence of SAH in pregnancy or the puerperium varies from 2 to 70 per 100,000 deliveries (20 per 100,000 deliveries on average), a risk calculated as 5 times higher than outside the pregnancy period (4,17). Non-traumatic SAH may account for 5-10% of all maternal deaths in pregnancy and is described as the third most common cause of non-obstetric death in pregnant women (6,16). Minielly (12) and Robinson (15) noticed increased incidence with increased age and parity. Although it may occur at any period of gestation, it is more likely to peak in the third trimester between 30 and 34 weeks' gestation, roughly paralleling the physiological 50% increased blood volume (2,5,12,15,16). The classic notion that rupture of an arterial aneurysm occurs more frequently during labour has not been confirmed. The mean time for aneurysm rupture was the seventh month of the gestation. In two percent of the patients the aneurysm ruptured during labour and in 13 percent during the postpartum period (6). In a retrospective review of 118 patients with verified ruptured arterial aneurysms, Dias and Sekhar (5) found that 90% of ruptures occurred during pregnancy and 8% during the puerperium. More than half of all types of arterial aneurysm that rupture in females younger than 40 are related to the hemodynamic and endocrine changes due to pregnancy. Although the physiologic hypervolemia and hemodilution during the pregnancy is expected to have a positive effect against the vasospasm, mortality and morbidity of aneurysmal SAH in pregnancy is high. Reports of aneurysmal SAH in pregnancy relate it to the physiological changes, such as pregnancy-induced degeneration of collagen; hyperplasia of the arterial intima; smooth muscle proliferation and alteration in the protein and acid mucopolysaccharide content of media; haemorrhage from the vasa vasorum into the outer third of tunica media; altered prostaglandin metabolism; and the secretion of relaxin (2,5,7,16). Because aneurysms at any location present with



increasing frequency as pregnancy advances, it seems likely that there is a real, increased tendency for such lesions to form and grow because the pregnant state results in a generalized and increasing laxity of blood vessel walls.

In 1965, the neurosurgeon J. Lawrence Pool (13) sent a questionnaire to several of his colleagues. Of 11 patients with aneurysm rupture treated by "bed rest", 8 (73%) died from recurrent haemorrhage, all after initially recovering from the effects of their first SAH. Pool thus concluded that pregnant patients with a ruptured aneurysm should be treated as non-pregnant patients, and undergo operation when in good clinical condition. Hunt et al. (8) have more recently reviewed the existing literature on this subject and added cases of their own. They are in agreement with Pool that operative treatment of aneurysm is recommended. Seven of eight pregnant women with aneurysm in the series of Minielly et al. (12) had their ruptured aneurysm operated on without mortality; one had a permanent serious deficit. Seven living infants were delivered, six of them vaginally. In Yasargil's (20) series of 1012 operated aneurysm cases, seven patients had one or more SAH during pregnancy. Two patients had a caesarean section followed by aneurysmal clipping. Five had clipping of the aneurysms carried out between 5 and 7 months and subsequent vaginal delivery at term.

As a general rule, patients who are pregnant and who have a ruptured aneurysm should be treated in the same fashion as if they are not pregnant. Those with a ruptured aneurysm should have the aneurysm clipped as rapidly as possible. During such clipping, general hypotension should be avoided if possible and reliance placed on temporary clips if deemed absolutely necessary. Once the aneurysm is successfully clipped, the pregnancy can be allowed to progress to term and patient can be delivered vaginally if she is in good neurologic condition. The method of delivery should be based on obstetric consideration. Obstetric issues should take priority over neurosurgical concerns during active labour (which can be precipitated by the haemorrhage), eclampsia, or foetal distress. Delivery should be performed promptly by caesarean section, followed as soon as possible by neurosurgical treatment (2,5,10,15,16,18).

DSA is the gold standard for the detection of cerebral aneurysms, even if CT and magnetic resonance angiography are promising non-invasive

techniques. Iodinated contrast material overload may lead to foetal hypothyroidism, which is usually temporary.

In our case, DSA was delayed after caesarean section. Caesarean section was performed and the aneurysms were clipped as rapidly as possible, as she had survived an SAH attack twice. The current treatment choice is neck clipping, although endovascular techniques are likely to play a role in the near future. We preferred surgical clipping to coil embolization, because she had multiple aneurysms and right MCA obliteration and cisternal irrigation were performed.

Cerebrovascular disorders other than eclampsia are an uncommon and unpredictable complication of pregnancy associated with serious maternal and foetal morbidity and mortality. Earlier physician intervention is required, as with currently available treatment a delay in patient presentation or an initial misdiagnosis by medical personnel would result in poor prognosis and outcome in most cases. Physicians must be aware of aneurysm rupture in the differential diagnosis neurological symptoms, particularly in the last trimester of pregnancy.

## REFERENCES

1. Awada A, Al Rajeh S, Duarte R, Russell N: Stroke and pregnancy. *Int J Gynecol Obstet* 48:157-61, 1995.
2. Barret J, Van Hooydonk JE, Boehm FH: Pregnancy-related rupture of arterial aneurysms. *Obstetrical and Gynecological Survey* 37:557-566, 1982.
3. Brey RL, Hart RG, Sherman DG, Tegeler CH: Antiphospholipid antibodies and cerebral ischemia in young people. *Neurology* 40:1190-6, 1990.
4. Cannell DE, Botterell EH: Subarachnoid hemorrhage and pregnancy. *Am J Obstet Gynecol* 72:844-855, 1956.
5. Dias MS, Sekhar LN: Intracranial hemorrhage from aneurysms and arteriovenous malformations during pregnancy and the puerperium. *Neurosurgery* 27:855-866, 1990.
6. Fox MW, Harms RW, Davis DH: Selected neurological complications of pregnancy. *Mayo Clin Proc* 65:1595-1618, 1990.
7. HartmanJD, Eftychiadis AS: Medial smooth muscle lesions and dissection of aorta and muscular arteries. *Arch Pathol Lab Invest* 114:50-61, 1990.
8. Hunt HB, Schifrin BS, Suzuki K: Ruptured berry aneurysms and pregnancy. *Obstet Gynecol.* 43(6):827-37, 1974.
9. Kittner SJ, Stern BJ, Feeser BR, Hebel R, Nagey DA, Buchholz DW, Farley CS, Johnson CS, MackoRF, Sloan MA, Wityk RJ, Wozniak MA: Pregnancy and the risk of stroke. *N Engl J Med* 335:768-74, 1996.
10. Lennon RL, Sundt TM Jr, Gronert GA: Combined caesarean section and clipping of intracerebral aneurysm. *Anesthesiology* 60:240-242, 1984.

11. Levine SR, Deegan MJ, Futrell N, Welch KMA: Cerebrovascular and neurologic disease associated with antiphospholipid antibodies: 48 cases. *Neurology* 40:1181-9, 1990.
12. Minielly R, Yuzpe AA, Drake CG: Subarachnoid hemorrhage secondary to ruptured cerebral aneurysm in pregnancy. *Obstet Gynecol* 53:64-70, 1979.
13. Pool JL: Treatment of intracranial aneurysms during pregnancy. *JAMA* 192:209-214, 1965.
14. Pritchard JA, McDonald PC (eds) *Williams Obstetrics* 16th ed. New-York: Appleton-Century-Crofts, 1980.
15. Robinson JL, Hall CJ, Sedzimir CB: Subarachnoid hemorrhage in pregnancy. *J Neurosurg* 36:27-33, 1972.
16. Selo-Ojemea DO,, Marshmanb LAG, Ikomia A, Ojutikua D, Aspoasb RA, Chawdac SJ, Bawad GPS, Manjit S. Raie MS: Aneurysmal subarachnoid haemorrhage in pregnancy. *Eur J Obstet Gynecol Reprod Biol* 116:131-143, 2004.
17. Simolke GA, Cox SM, Cunningham FG. Cerebrovascular accidents complicating pregnancy and the puerperium. *Obstet Gynecol* 78:37-42, 1991.
18. Stoodley MA, Macdonald RL, Weir BK: Pregnancy and intracranial aneurysms. *Neurosurg Clin N Am* 9:549-56, 1998.
19. Wiebers DO, Whisnant JP: The incidence of stroke among pregnant women in Rochester, Minn, 1955 through 1979. *JAMA* 254:3055-7, 1985.
20. Yasargil MG: *Microneurosurgery: vol.II. Clinical Considerations Surgery of the Intracranial Aneurysm and Results.* Stuttgart: Georg Thieme Verlag, 1984.