

Case Report

Arachnoid Cyst As a Complication of Ventriculoperitoneal Shunt: Case Illustration

ABSTRACT

Development of an arachnoid cyst after ventriculo-peritoneal shunting is extremely rare. The authors present an unusual cause of arachnoid cyst formation following surgery performed for cystic dilatation of the 4th ventricle. Cyst to peritoneal shunting was performed and the patient developed a supratentorial arachnoid cyst 8 months later.

KEY WORDS: Arachnoid cyst, Complications of shunts, Hydrocephalus

CASE REPORT

A 4-year-old male patient suffering from headache, vomiting and speech impairment and difficulty in walking for the last three months was evaluated. His physical and neurological examination revealed papilledema, impairment of cerebellar function, increased deep tendon reflexes and bilaterally positive Babinsky sign. His cranial computerized tomography (CT) and magnetic resonance imaging (MRI) demonstrated cystic dilatation of the 4th ventricle (Figure 1) and secondary 3rd and lateral ventricular hydrocephalus (Figure 2). The dilatation in the 4th ventricle was evaluated as an arachnoid cyst due to the absence of vermian agenesis and the presence of displacement in brain stem anteriorly (Figure 3). Cystoperitoneal shunting with a low-pressure shunt was performed. The cystic dilatation, signs of hydrocephalus and the other symptoms completely resolved after surgery. Nearly one month later, the patient was re-evaluated due to recurrence of vomiting and headaches. An increase in the size of the cyst was detected by radiological evaluation. Revision surgery was performed and the shunt system was changed due to an obstruction in the cystic part of the shunt.

Follow-up CT and MRI performed after 8 months demonstrated an arachnoid cyst in the right middle fossa (Figure 4, 5, 6). The cystic dilatation in the 4th ventricle completely resolved after the second surgery (Figure 7). Since there were no neurological signs that could be attributed to the new arachnoid cyst, no surgical intervention was considered. The patient's periodical follow-up is still continuing.

DISCUSSION

Arachnoid and pia mater develop from mesenchyme enclosing the neural tube. This mesenchymal layer then splits into endo- and exomeninges. Endomeninges form the pia and the arachnoid and subarachnoid space lies between these two. An arachnoidal gap where

Metin KAPLAN
Fatih Serhat EROL
Ebru GERÇEK
Hacı ORHAN

Departments of Neurosurgery and
Radiology, School of Medicine,
Firat University, Elazig, Turkey

Received : 17.10.2005

Accepted: 15.12.2005

Correspondence Address:

Metin KAPLAN

Firat Üniversitesi, Tıp Fakültesi,
Araştırma Hastanesi, Nöroşirürji AD,
23200 Elazığ, TURKEY

Phone : +90 424 233 3555-1183

Fax : +90 424 238 8096

E-mail : mtkaplan02@hotmail.com

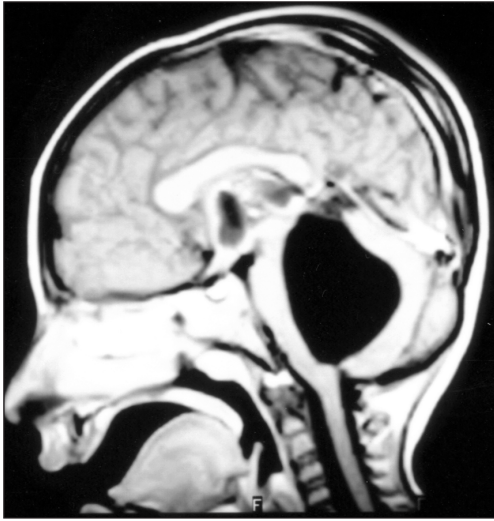

Figure 1: Sagittal T1-weighted magnetic resonance image shows the dilatation in the 4th ventricle.

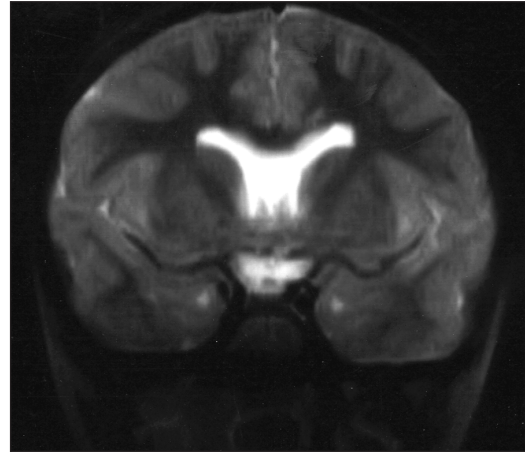


Figure 4: Early stage follow-up T2-weighted magnetic resonance image of the patient after the second operation.

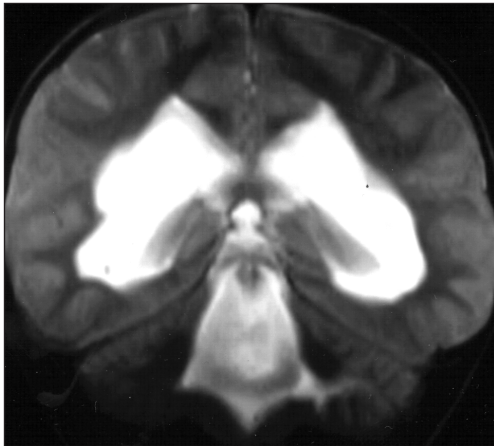

Figure 2: Coronal T2-weighted magnetic resonance image shows hydrocephaly and dilatation in the 4th ventricle.

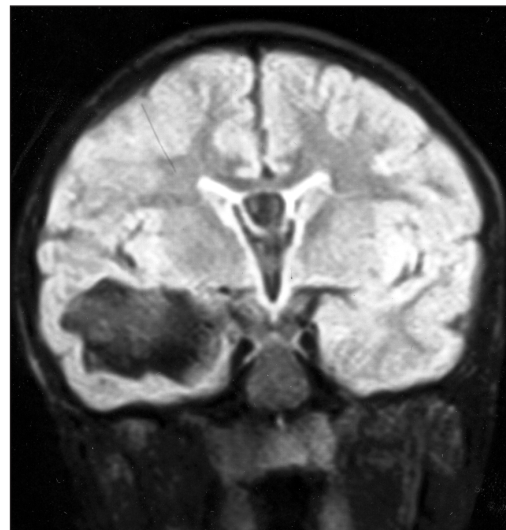


Figure 5: T1-weighted magnetic resonance image performed after 8 months demonstrated an arachnoid cyst in the right middle fossa.

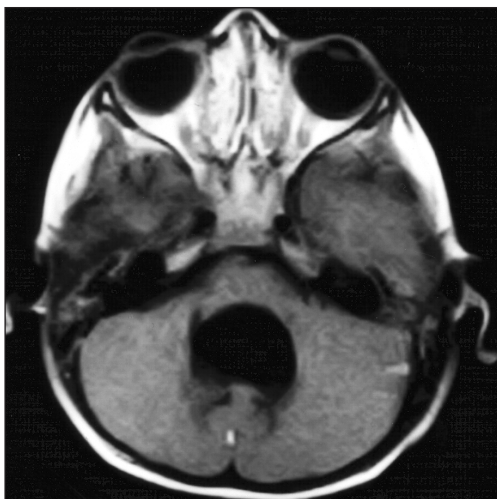


Figure 3: Axial T1-weighted magnetic resonance image show the absence of vermian agenesis and the present displacement in brain stem anteriorly.

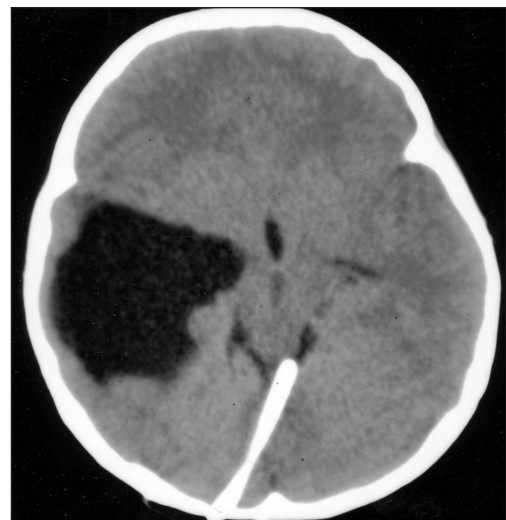

Figure 6: Computerized tomography of the same patient.

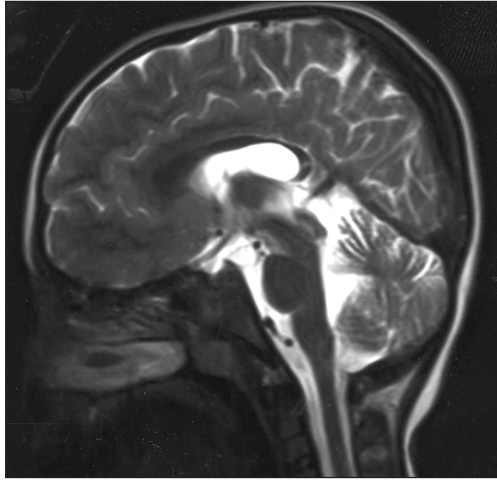


Figure 7: The cystic dilatation in the 4th ventricle completely resolved after the second operation.

cystic dilatation occurs is the result of focal impairment in this splitting process that can be due to an intrauterine inflammation or an infection (1). Arachnoid adhesions secondary to focal inflammation may also develop from acquired arachnoid cysts that can be a result of trauma, infection or neurosurgical procedures. A ball-valve mechanism is suggested to describe the accumulation of cerebrospinal fluid (CSF) in these arachnoid gaps that develop due to arachnoid adhesions (1). How arachnoid cysts develop after ventriculoperitoneal (V/P) shunting is still not clear. Four different mechanisms are suggested: 1- Martinez-Lage et al. (2) suggested that entrapment of arachnoid and CSF between subdural membranes and cerebral cortex may lead to formation of arachnoid gaps. Two cases of subdural bleeding due to overdrainage reported previously support this mechanism. However, in our case there were no signs of overdrainage or subdural bleeding. 2- Weaver et al. (3) reported a case of rapidly enlarging congenital arachnoid diverticulum that was attributed to altered CSF dynamics after ventricular

decompression. In our case, the presence of cystic dilatation in the 4th ventricle is proof of impairment in focal separation of pia and arachnoid during the intrauterine phase. This supports the idea that the enlargement of the arachnoid diverticulum is due to altered CSF dynamics after V/P shunting. 3- Ventriculomegaly can cause narrowing in the subarachnoid space leading to arachnoid adhesions. CSF circulation in the subarachnoid space recovers after V/P shunting because of the decreased size of ventricles and the decreased intracranial pressure. Entrapment of CSF in the arachnoid gap with a ball-valve mechanism leads to formation of arachnoid cysts. 4- Surgical trauma or shunt infections may result in arachnoid gap formation after surgical intervention. Both in our case and in the other reported cases there were no complications due to infection. The infratentorial surgical site in our case weakens the probability of formation of an arachnoid adhesion due to focal inflammation leading to a supratentorial right middle fossa arachnoid cyst. However, the history of shunt revision both in the case reported by Martinez-Lage et al. and in our case must be taken into consideration.

Although hydrocephaly is a common pathology, arachnoid cyst formation after V/P shunting is very rare. This makes it difficult to determine the physiopathology of arachnoid cyst formation in these cases. However, the role of V/P shunting is evident for the mechanisms mentioned above.

REFERENCES

1. Martinez- Lage JF, Ruiz-Macia D, Valenti JA, Poza M: Development of a middle fossa arachnoid cyst. A theory on its pathogenesis. *Child's Nerv Syst* 1999; 15: 94-97
2. Martinez- Lage JF, Poza M, Lopez F: Arachnoid cyst as a complication of ventricular shunting. *Child's Nerv Syst* 1991; 7: 356-357
3. Weaver KD, Ewend MG: Development of an arachnoid cyst after ventriculoperitoneal shunt placement. *J Neurosurg* 2000; 92: 363