

# Factors in Sample Volume and Quality of CT-guided Vertebral Biopsy: Location and Needle Trajectory

## BT Eşliğinde Vertebra Biyopsisinin Biyopsi Hacmi ve Kalitesi Etkenleri: Yerleşim ve İğne Yaklaşımı

### ABSTRACT

**AIM:** To assess sample volume (by its length and diameter) and sample quality (judging by its integrity) in CT-guided vertebral biopsy due to lesion location and needle trajectory method as individual study variables each.

**MATERIAL and METHODS:** Of 48 patients, 25 were men and 23 were women; ranging from 33 to 85 years of age, with a median age of 65.5 years. The independent variables were primarily vertebral location and needle trajectory. Two cervical lesions were excluded from location analysis. We examined sample length and width, and macroscopic (5-scale) and microscopic (3-scale) scores as dependent variables. We did not encounter with any major complication and infection.

**RESULTS:** Median sample length and sample diameter were found to be 10 mm and 2 mm, respectively. No relation was observed between the dependent variables and location in the spine. There was a relation between sample length and needle trajectory ( $p=0.002$ ) with values of 11 mm in the transpedicular method vs. 6 mm in the posterolateral method ( $p=0.01$ ).

**CONCLUSION:** Transpedicular trajectory had an advantage over the posterolateral method as it provides a longer sample. We believe that transpedicular biopsy should be preferred. Nevertheless, studies are needed to validate the most advantageous standard access position in spine biopsies.

**KEYWORDS:** Bone, Biopsy, Vertebra, Spine, CT-guided, Interventional radiology

### ÖZ

**AMAÇ:** BT eşliğinde vertebra biyopsisinde, her biri tek başına çalışma değişkeni olarak alınan biyopsinin uzunluk ve çapıyla belirlenen hacmi ile bütünlüğüyle karar verilen niteliğini, lezyon yerleşimi ve iğne yaklaşım şekline göre değerlendirmek.

**YÖNTEM ve GEREÇ:** Kırk sekiz hastanın yaşı 33 ile 85 arasında ve ortanca 65.5 yaş olup 25'i erkek 23'ü kadın idi. Temel bağımsız değişkenler, vertebra yerleşimi ve iğne yaklaşımı idi. Servikal iki lezyon, yerleşim analizi dışında tutuldu. Bağımlı değişken olarak kor uzunluğu ve çapını, makroskopik (5 derece) ve mikroskopik (3 derece) değerlerini araştırdık. Majör bir komplikasyon ve enfeksiyona rastlamadık.

**BULGULAR:** Ortanca biyopsi uzunluğu ve çapı, sırayla 10 mm ve 2 mm olarak bulundu. Bağımlı değişkenler ile vertebra yerleşimi arasında bir ilişki gözlemedik. Fakat, kor uzunluğu ile iğne yaklaşım şekli, transpediküler yol ile 11 mm'ye karşılık posterolateral yol ile 6 mm ( $p=0.01$ ) olup ilişkiliydi ( $p=0.002$ ).

**SONUÇ:** Transpediküler yaklaşım, daha fazla biyopsi uzunluğu sağlayarak posterolateral yöntemden daha üstün olarak gözlemlendi. Bu nedenle, transpediküler biyopsinin tercih edilmesi gerektiğini düşünüyoruz. Bununla birlikte, vertebra biyopsilerinde en iyi standart yaklaşım şeklini geçerli kılmak için çalışmalar gerekir.

**ANAHTAR SÖZCÜKLER:** Kemik, Biyopsi, Vertebra, Omurga, BT eşliği, Girişimsel radyoloji

Bilgin Kadri ARIBAS<sup>1</sup>

Gurbuz DINGIL<sup>2</sup>

Kamil DOĞAN<sup>3</sup>

Gursel SAHİN<sup>4</sup>

Isın PAK<sup>5</sup>

Fisun ARDIC<sup>6</sup>

1,2,3,4 A.Y. Ankara Oncology Training and Research Hospital, Department of Radiology, Ankara, Turkey  
5,6 A.Y. Ankara Oncology Training and Research Hospital, Department of Pathology, Ankara, Turkey

Received : 06.04.2009

Accepted : 03.10.2009

Correspondence address:

**Bilgin Kadri ARIBAS**

E-mail: bilginaribas@hotmail.com

## INTRODUCTION

Percutaneous bone biopsy under fluoroscopic or computed tomography (CT) guidance is safe and almost painless, and preferred for lesions which have a soft-tissue component or are located close to vital structures (10).

There are some studies which examine the relation between diagnostic yield and independent variables such as age, sex, radiological findings, location and needle characteristics (1-10). The features of patients, lesions, and needles and lesion location have been studied. However, there were only two studies comparing the different biopsy techniques (5,9); of which needle trajectory was examined in only one and not found to be significant (9). We presumed that needle trajectory (posterolateral, transpedicular, etc) may lead to differences in sample volume and/or quality.

This analysis was therefore performed retrospectively to assess the sample volume and quality of CT-guided vertebral bone biopsy due to location and needle trajectory (especially transpedicular versus posterolateral) as individual study variables. We examined sample volume and quality in the study as conclusive dependent variables and the lesion location and needle trajectory as major independent variables.

## PATIENTS and METHODS

### Patients

Forty-eight patients with bone lesions were admitted for a vertebral core biopsy in the last nine years (between 2000 and 2009). Of these 48 patients, 25 were men and 23 were women; ranging from 33 to 85 years of age, with mean and median ages of  $61.2 \pm 13.6$  and 65.5 years, respectively.

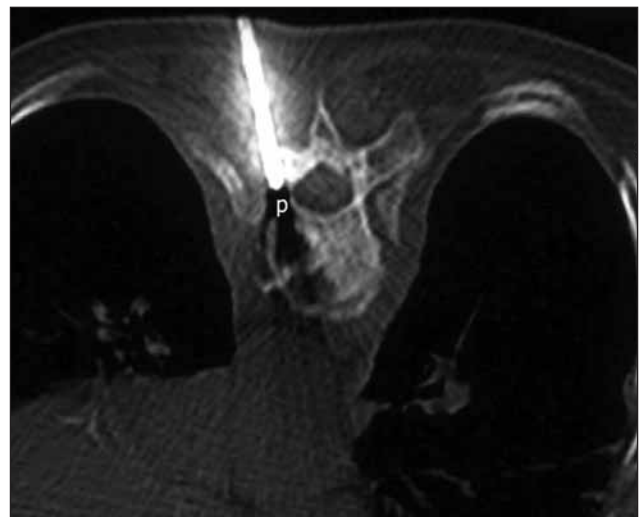
### Patient Choice

Physicians referred the patients following multidisciplinary assessment. Clotting tests, i.e. the blood platelet count, prothrombin time and partial thromboplastin time were examined before the procedure. No coagulopathy requiring treatment was encountered. All the patients had platelet counts greater than 70,000/ml and prothrombin and partial thromboplastin times up to 50% more than normal limits. Any drug that could affect coagulation parameters was withheld as a precaution. Informed consent was obtained from the patients following an

explanation of the risks and benefits. The principles of the Helsinki Declaration were complied with. All patients, of whom some had magnetic resonance imaging (MRI), underwent diagnostic CT before the biopsy to determine the site, depth, and biopsy angle and route correctly. Biopsy indications were mixed osteolytic-osteosclerotic lesions in all. Biopsy was performed once with an 11G needle in 24 patients, once with a Tru-cut needle in 20 patients and twice with a Tru-cut needle in four patients (one lumbar, transpedicular and three sacral, posterior) until a core sample was obtained.

### Vertebral Biopsy Procedure

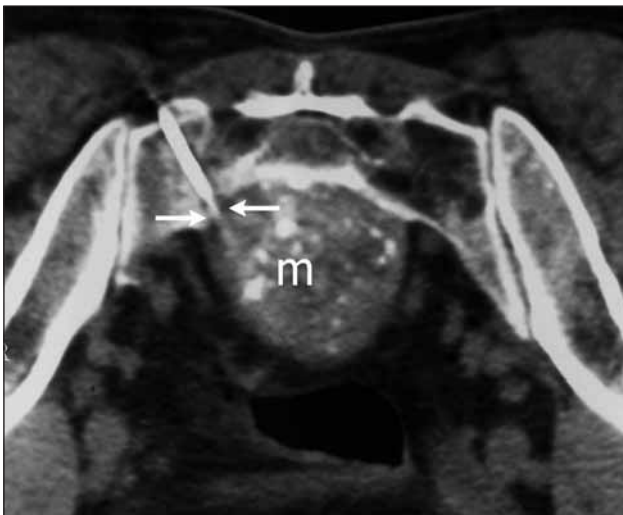
All biopsies were performed with CT of 5 mm slice thickness. The patients were in prone position during the procedure. The entry point was marked on the skin with the aid of CT lighting and markers. After prepping twice with povidone-iodine 1% against infection, ten ml prilocaine 2% was injected both subcutaneously and deeply along the needle tract into the bone periosteum with a Chiba 20G needle. The choice of which needle to be used for biopsy was based on the presence of any soft tissue component. If this component was found, a 14G Tru-cut needle passing through an 11G bone needle coaxially was chosen. If not, biopsy was performed with an 11G bone needle only. A bone biopsy needle 11G, 10 cm (US biopsy J style 3.0 mm bore; a division of Promex Technologies, LCC, Franklin, IN) was utilized in 24 lesions (Figure 1), while a Tru-Cut 14G, 15 cm needle through this 11G



**Figure 1:** Seventy-nine-year-old woman with a lytic lesion in the left pedicle and corpus of the 8th thoracic vertebra. Left transpedicular access was conducted with an 11G needle through the left pedicle (p) (diagnosis: chronic granuloma).

bone needle was coaxially used in other 24 biopsies (Figure 2).

All biopsies were performed by two staff radiologists (the first and second authors) in turn. After a small skin incision and insertion of the biopsy needle, CT was obtained to check the right approach. The needle was then advanced to the calculated depth. Periosteum and cortex were passed with a rotating motion of the needle. The needle stylet was withdrawn if CT documented the needle tip within the lesion. In case of any soft tissue component, a 14G Tru-cut needle was advanced through this needle coaxially. If not, the 11G needle cannula was advanced with a single torque motion to obtain biopsy material. Control CT was taken following the biopsy. After the biopsy, we applied pressure with a sponge for 10 minutes against hemorrhage.



**Figure 2:** Fifty-year-old man with an expansible mass (m) in the anterior of the sacral 1st vertebra. Left posterolateral approach was performed with a 14G Tru-cut needle passing through an 11G bone needle (arrows) (diagnosis: insufficient material as necrosis).

### Pathological Evaluation

The samples were examined in the pathology department by two pathologists (the fifth and sixth authors). Core length and width and macroscopic features were recorded in detail after standard formalin fixation. The width and length of each biopsy sample was measured in millimeters. In core materials the length was the total length of the sample or samples and the width was measured as a mean of their 2 vertical diameters at axial plane. Macroscopic scores were also evaluated according to a 5-point scale:

cohesive core (1), fragile core (2), large tissue fragments (3), small tissue fragments (4), and no sample (5). Microscopically, the biopsy samples were assessed with a Hematoxylin-Eosin stain using a 3 point scale: sufficient material (1), inconclusive (2), and insufficient material (3). Insufficient material was found as fragmented, crushed, or no tissue. Necrosis and blood were also considered as insufficient material.

### Statistical Analysis

The dependent variables were mainly sample length and diameter, and also macroscopic and microscopic scores. The independent variables were primarily vertebral location and needle trajectory, also age, gender, and needle type. Statistical analysis was performed by Kruskal-Wallis variance analysis and Mann-Whitney U test. A  $p$  value < (0.05/number of group combinations) was considered significant in the Mann-Whitney U test.

### RESULTS

Biopsy procedures were completed in 15-35 minutes with a median value of 25 minutes. Ten lesions were located in the thoracic region, twenty in the lumbar region, sixteen in the sacrum, and two in the cervical vertebrae. Cervical spinous lesions were biopsied by 11G bone needles with diagnoses of metastasis in a 85-year-old male patient via posterior access and a 68-year-old female patient via posterolateral access. Two patients were accepted as missing values for the location analysis due to the limited numbers for this region. Needle trajectories were as follows: 17 posterolateral, 16 transpedicular, and 15 posterior approaches.

All the values were evaluated as median. Core length and diameter were 10 mm and 2 mm, respectively. Macroscopic and microscopic scores were found to be 3 and 1, respectively. Age and gender were not significant as dependent variables (sample volume and quality) ( $p > 0.05$ ).

The variables of the needles were not different except for core diameters: macroscopic scores ( $p = 0.137$ ), microscopic scores (0.503), core lengths ( $p = 0.812$ ), and core diameters ( $p = 0.013$ ). Core diameters were, as expected, 2.0 mm (range; 2 mm) with 11G needles and 1.25 mm (range; 1 mm) with 14G needles.

No relation was observed between dependent variables and location in the spine (Table I). Table II

**Table I:** Relation between dependent variables and location<sup>a</sup>

Variable <sup>b</sup>	Thoracic	Lumbar	Sacral	p value
Macroscopic score	3.0 (3)	3.0 (4)	3.0 (4)	0.902
Microscopic score	1.0 (2)	1.0 (2)	1.0 (2)	0.448
Sample length (mm)	8.0 (11)	7.0 (35)	17.0 (42)	0.080
Sample diameter (mm)	1.8 (1)	2.0 (2)	1.4 (1)	0.441

<sup>a</sup> Cervical region was excluded from location analysis due to 2 biopsies.

<sup>b</sup> Median (range).

**Table II:** Relation between dependent variables and needle trajectory.

Variable <sup>a</sup>	PL <sup>b</sup>	P <sup>b</sup>	TP <sup>b</sup>	P Value
Macroscopic score	3.0 (4)	2.0 (3)	1.0 (4)	0.037
Microscopic score	1.0 (2)	1.0 (0)	1.0 (2)	0.004
Sample length (mm)	6.0 (20)	19.0 (42)	11.0 (35)	0.002
Sample diameter (mm)	1.5 (2)	1.5 (1)	2.0 (1)	0.285

<sup>a</sup> Median (range).

<sup>b</sup> PL: posterolateral, P: posterior, TP: transpedicular.

shows the relation between dependent variables and needle trajectory. There was an observed relation between sample length and needle trajectory (p=0.002). Sample lengths were different as 11 mm in transpedicular vs. 6 mm in posterolateral methods (p=0.01). The sixteen transpedicular biopsies were thoracic in 6 and lumbar in 10, whereas the 17 posterolateral ones were cervical in one, thoracic in 4, lumbar in 9, and sacral in 3. The sample lengths were also 6 mm in the posterolateral vs. 19 mm in the posterior groups (p=0.002). Among the 15 posterior approaches, there was one cervical biopsy, only one lumbar biopsy, and 13 sacral biopsies. There was no difference between sample lengths of the transpedicular and posterior groups (p=0.137).

There could be also an observed relation between macroscopic score and needle trajectory (p=0.037) and microscopic score and needle trajectory (p=0.004). Macroscopic scores were not different as 1 vs. 3 (p=0.017), and microscopic scores as 1 vs. 1 (p=0.05) in the Mann-Whitney U test (p values > 0.05/3) between the transpedicular and posterolateral groups, respectively. There was no difference between the transpedicular and posterior groups for macroscopic score (p=0.368) and microscopic score (p=0.164). There was a difference between the microscopic score (p=0.003) of the posterolateral and posterior groups, but their macroscopic scores were not different (p=0.076).

Table III shows the histopathological results. Immunohistochemical analysis was conducted in 17 patients. Twenty-eight lesions were identified as malignant, 15 as benign, and 5 as insufficient. Consequently, these 5 lesions were found to be malignant in 4 and benign in one. Two of three diagnoses as mature bone were found to be malignant in the open biopsy of one and clinical follow-up of the other.

There was no major complication or infection in any biopsy. Minor complications were observed with

**Table III:** Histopathological results of the lesions.

Histopathological diagnosis	No
Malignant	28
Carcinoma metastasis	22
Malignant	2
Plasmocytoma	2
Lymphoma	2
Benign	15
Mature bone <sup>a</sup>	3
Giant-cell tumor	1
Degenerative <sup>b</sup>	3
Osteomyelitis	1
Chronic granuloma	7
Insufficient <sup>c</sup>	5
Total	48

<sup>a</sup> One was true, but the others were found false

<sup>b</sup> Degenerative spondylodiskitis

<sup>c</sup> Two were necrosis, one was insufficient material, and one was fragmented bone in 4 malignancies, blood in one benign lesion

only 11G needles as pain in four patients and minor hemorrhage in 24 patients. Pain was treated with analgesics symptomatically.

## DISCUSSION

The percutaneous vertebral biopsy procedure is conducted for the diagnosis of various spinal pathological entities (8). A variety of needles that range in size from 11G to 22G are available for aspiration, cutting and trephine sampling (1). The choice of the needle to be used is based on many factors including availability, familiarity, cost, ease of use and expected sample quality (6).

We assessed sample quantity via sample length and diameter in this series. In general, specimen quality is judged based on achieved versus expected size, specimen integrity and degree of crush or distortion in the sampled tissue (6). We evaluated this quality via the macroscopic score (5-scale) and microscopic score (3-scale); the less the score, the more successful the result. We examined the most suitable approach position and lesion location by mainly focusing on sample quantity and quality in spite of the limited performed open biopsies for a definitive diagnosis.

The main approaches for biopsy samplings to the thoracolumbar vertebrae are standard posterolateral and transpedicular (8). Transcostovertebral, transforaminodiscal, lateral, and posterior access methods are also used in the spine (2,4,8,9). The standard posterolateral approach involves passing the needle lateral to the transverse process (4). The biopsy needle penetrates the vertebra through the vertebral arch in the transpedicular method (8). The posterior approach is usually performed in the sacrum where it is conducted without difficulty.

Different methods have different advantages but the transpedicular approach is currently performed more often than the posterolateral one in the thoracolumbar region (2,4,8). However, their difference in terms of accuracy was not reported in any series; Sucu et al. reported no significant difference due to needle trajectory (9). Nevertheless, they frequently performed transforaminodiscal biopsy besides other methods. We therefore examined the needle trajectory at spine biopsy to see if there was any distinction in core features. We detected that core lengths were different in the positions; the median core length of transpedicular access was longer than that of posterolateral access.

One limitation of the transpedicular approach is that intervertebral disks cannot be reached using this route (2). Transforaminodiscal biopsy provides an advantage in this condition (8, 9). However, we did not evaluate intervertebral disks in this study. The other limitation of the transpedicular approach is reported to be the complications that occur when the medial or inferior walls of the pedicle are punctured, resulting in spinal canal damage or nerve root injury (2). We also did not encounter such spinal damage under CT guidance using 11G bone needles.

Increased accuracy rate in the sacrum is likely due to easier access and the absence of vital structures (e.g. spinal cord or major vessels), which allow for more aggressive sampling of a lesion (3). We observed that the microscopic score and sample length were naturally better in the posterior approach than the posterolateral approach.

Although Kornblum et al. have reported decreased diagnostic accuracy rates in the thoracic spine; this was not the case in other series (3,5,9). We did not significantly find different dependent variables of the samples in the thoracic spine or the other regions. The reported rates for pneumothorax, a main complication of thoracic biopsy procedures, have ranged from 0 to 14% (6). We did not encounter any pneumothorax in thoracic biopsies either.

As a restriction, open biopsy was performed in only 29.2% of the series because we usually accepted our patients in extremely poor health conditions due to their diseases and old ages. Although definitive open biopsy was performed in a limited number of patients for assessing accuracy, we investigated the qualitative and quantitative features of the samples. As an alternative to open biopsy, percutaneous needle biopsy has gained popularity and shows good accuracy as a less invasive procedure in the literature as well. The cost and time involved are less than open biopsy and there is less risk of tumor spread, infection and/or wound problems (3).

CT-guided biopsy has allowed safe and accurate biopsy at virtually all segments of the spine when compared with fluoroscopy-based biopsy, (9). We therefore chose it instead of fluoroscopy-based biopsy and found it to be more successful and safe.

Percutaneous vertebral biopsy is associated with a 0-26% rate of complications; the most frequently reported ones are pulmonary, neurological, and infectious disorders (10). There were no serious

complications except for pain and minor hemorrhage in our series.

### CONCLUSION

CT-guided spine biopsy was found to be a safe and efficient method to obtain an adequate sample. Regarding sample volume and quality, transpedicular needle trajectory had an advantage over posterolateral needle trajectory in vertebral lesions, which provides a longer sample. However, different needle trajectories may be used in different locations and it is required to demonstrate the more correct method on average. We consider that this should be analyzed in prospective series using sample volume and quality to validate the most advantageous standard access position in spine biopsies.

### REFERENCES

1. Buckley O, Benfayed W, Geoghegan T, Al-Ismail K, Munk PL, Torreggiani WC: CT-guided bone biopsy: Initial experience with a commercially available hand held Black and Decker™ drill. *Eur J Radiol* 61:176-180, 2007
2. Garces J, Hidalgo G: Lateral access for CT-guided percutaneous biopsy of the lumbar spine. *AJR Am J Roentgenol* 174:425-426, 2000
3. Lis E, Bilsky MH, Pisinski L, Boland P, Healey JH, O'malley B, Krol G: Percutaneous CT-guided biopsy of osseous lesion of the spine in patients with known or suspected malignancy. *AJNR Am J Neuroradiol* 25:1583-1588, 2004
4. Renfrew DL, Whitten CG, Wiese JA, El-Khoury GY, Harris KG: CT-guided percutaneous transpedicular biopsy of the spine. *Radiology* 180:574-576, 1991
5. Rimondi E, Staals EL, Errani C, Bianchi G, Casadei R, Alberghini M, Malaguti MC, Rossi G, Durante S, Mercuri M: Percutaneous CT-guided biopsy of the spine: results of 430 biopsies. *Eur Spine J* 17: 975-981, 2008
6. Roberts CC, Morrison WB, Leslie KO, Carrino JA, Lozevski JL, Liu PT: Assessment of bone biopsy needles for sample size, specimen quality and ease of use. *Skeletal Radiol* 34:329-335, 2005
7. Saad RS, Clary KM, Liu Y, Silverman JF, Raab SS: Fine needle aspiration biopsy of vertebral lesions. *Acta Cytologica* 48:39-46, 2004
8. Sucu HK, Bezircioglu H, Cicek C, Ersahin Y: Computerized tomography-guided percutaneous transforaminodiscal biopsy sampling of vertebral body lesions. *J Neurosurg* 99:51-55, 2003
9. Sucu HK, Cicek C, Rezanko T, Bezircioglu H, Ersahin Y, Tunakan M, Minoglu M: Percutaneous computed-tomography-guided biopsy of the spine: 229 procedures. *Joint Bone Spine* 73: 532-537, 2006
10. Yaffe D, Greenberg G, Leitner J, Gipstein R, Shapiro M, Bachar GN: CT-guided percutaneous biopsy of thoracic and lumbar spine: A new coaxial technique. *AJNR Am J Neuroradiol* 24:2111-2113, 2003