

# Positional Neurological Improvement Following Sinking Skin Flap Syndrome

## Çöken Cilt Flebi Sendromu Sonrası Pozisyon Değişikliği ile Nörolojik Düzelmeye

### ABSTRACT

A 70-year-old male was operated for bilateral parasagittal meningioma. He suffered bilateral venous infarcts postoperatively. The craniotomy flap was removed and a duraplasty procedure was performed. One month later, the patient deteriorated with sinking of his skin flap. Holding the patient intermittently in Trendelenburg's position improved his neurological status.

**KEY WORDS:** Parasagittal meningioma, Sinking skin flap syndrome, Tumor

### ÖZ

70 yaşında erkek hasta bilateral parasagittal menenjiyomu sebebi ile opere edildi. Hastada postoperatif dönemde bilateral venöz infarkt gelişti. Kranyotomi flebi kaldırılarak duraplasti yapıldı. Bir ay sonra cilt flebinin çökmesi sonucu hasta kötüleşti. Hastanın nörolojik durumu, kendisini aralıklı olarak Trendelenburg pozisyonunda tutmak sonucunda, düzeldi.

**ANAHTAR SÖZCÜKLER:** Çöken cilt flebi sendromu, Parasagittal menenjiyom, Tümör

**M. İbrahim ZİYAL**

**Pınar ÖZİŞİK**

**Atilla AKBAY**

**Cezmi TÜRK**

**Bülent BAKAR**

**Osman E. ÖZCAN**

Department of Neurosurgery,  
School of Medicine, Hacettepe University,  
Ankara, Turkey

Received : 10.11.2005

Accepted : 17.11.2005

Correspondence address

**M. İbrahim ZİYAL**

Hacettepe Üniversitesi Tıp Fakültesi,  
Nöroşirürji Anabilim Dalı, Sıhhiye, Ankara,  
TURKEY

E-mail: ibrahimziyal@yahoo.com

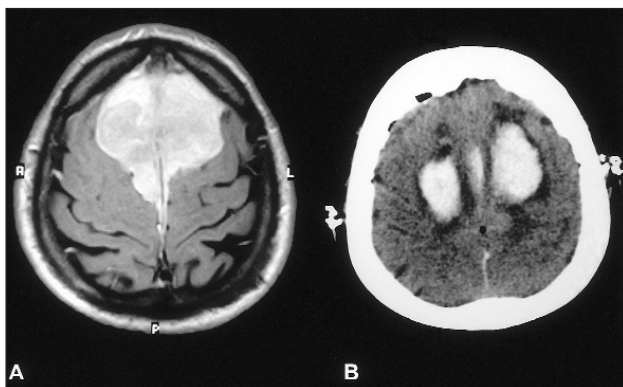
### INTRODUCTION

Resorption of a secondary hemorrhagic infarct, hematoma or edema, and removal of the falx with an occluded superior sagittal sinus may induce the existence of the sinking skin flap syndrome (SSFS). The cranioplasty procedure is not the only choice for the treatment of this condition. Positioning of the head and holding the patient intermittently in the Trendelenburg position, elevates the intracranial pressure and improves the neurological status in selected cases.

### CASE REPORT

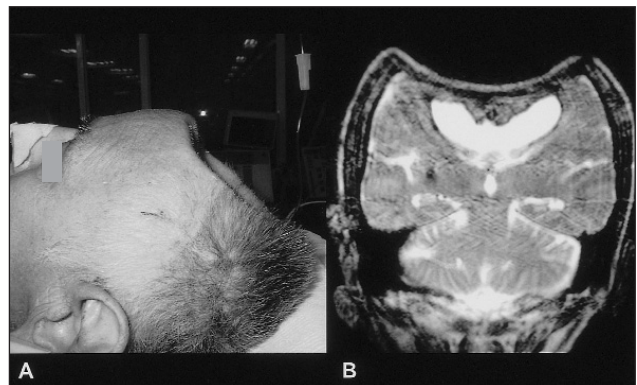
A 70-year-old male was admitted with headache and his neurological examination was normal. The magnetic resonance imaging (MRI) scan revealed a parasagittal meningioma covering the anterior 2/3 of the superior sagittal sinus bilaterally (Figure 1A). Magnetic resonance angiography (MRA) demonstrated that the anterior 2/3 of the sinus was occluded by the tumor. The patient was operated via a bilateral parasagittal craniotomy and gross total removal of the tumor with occluded sinus and falx was achieved. The patient had no neurological deficit in the early postoperative period.

After 24 hours, the patient's conscious level gradually deteriorated and computed tomographic (CT) scan revealed bilateral parietal hemorrhagic infarct (Figure 1B). The patient was reoperated on and it was observed during the operation that there was no extra- or intraaxial hematoma. Closure was performed with removal of the cranial bone flap and

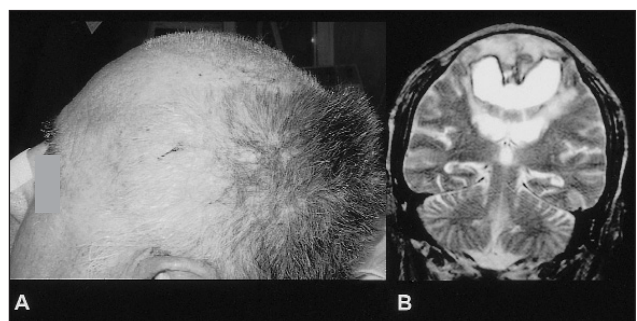


**Figure 1:** Axial T1-weighted MRI scans of a 70-year-old male with contrast administration demonstrated a parasagittal giant mass lesion covering the anterior 2/3 of the superior sagittal sinus and the falx bilaterally, resembling a meningioma (A). Twenty-four hours after removal of the meningioma, the patient's neurological status gradually deteriorated and a CT scan demonstrated bilateral parietal hemorrhagic infarct (B).

duraplasty. The patient's neurological status gradually improved. One month later, the patient's neurological status again deteriorated following sudden sinking of the skin flap (Figure 2A). At that time, the patient had flexor response but no localizing pain. The MRI scan demonstrated extensive compression of the skin flap onto the brain (Figure 2B). No change was observed in the position of the skin flap and the neurological status of the patient during the next 48 hours. It was decided to keep the patient in the Trendelenburg position two hours of every four hours. The flap returned to its normal position (Figure 3A) in two days and the patient's neurological status improved. The MRI scan revealed normal position of the flap, with the brain filling the intracranial cavity (Figure 3B).



**Figure 2:** The patient's neurological status again deteriorated again just before his discharge following sudden sinking of the skin flap (A). A coronal T2-weighted MRI scan demonstrated extensive compression of the skin flap onto the fronto-parietal cortex (B).



**Figure 3:** The flap returned to its normal position after the patient was kept intermittently in the Trendelenburg position for two days (A). The T2-weighted coronal MRI scan revealed the normal position of the flap, with the brain parenchyma filling the whole intracranial cavity (B).

## DISCUSSION

The compression of the skin flap onto the brain due removal of the cranial bone after a neurosurgical procedure is known as 'the syndrome of the trephined' (3) or 'the sinking skin flap syndrome (SSFS)' (7). The atmospheric pressure is transmitted through the flap to the intracranial cavity also causing inward rotation of the scalp flap over the bone defect (5). Cerebrospinal fluid pressure measured by lumbar puncture has revealed that the pressure in the upright position in a SSFS is greater than in a patient with closed calvaria. Even though the removal of the cranial bone flap with or without a duraplasty is the main etiological factor in the existence of SSFS, the brain usually expands and does not permit sinking of the flap. The tight dura also prevents the flap from sinking down. Therefore, the existence of SSFS after removal of a tumor is extremely rare. Secondary factors such as resorption of a hematoma or edema, and sudden occurrence of intracranial hypotension may play a role. If some part of the superior sagittal sinus and the falx is removed, this situation will make it easier for this syndrome to develop. The part of the brain under compression and the size of the defect are important factors on the gradually changing clinical status. It has been reported that the deteriorating clinical condition usually improves after a cranioplasty procedure (1, 2, 5, 6).

Although angiography showed that 1/3 anterior and 1/3 middle of the superior sagittal sinus was occluded in our case, bilateral hemorrhagic infarct occurred 24 hours after gross total removal of the parasagittal meningioma. We suggest that there is a symbiotic relationship between the tumor and the brain in such cases. The sinus does not function properly but the tumor organizes the blood transport between itself and the normal brain tissue in a parasitic fashion. Bone removal and duraplasty and previous removal of anterior and middle superior sagittal sinus and falx caused sinking of the flap after resorption of the brain edema secondary to hemorrhagic infarct. The defect was covering the parasagittal cortex bilaterally and the pressure was reflected indirectly to the brain stem causing the

patient to lose consciousness. The patient had flexor response to the pain that never became extensor. This was the maximal compression threshold of the flap, hanging down maximally along the borders of the cranial defect.

Cranioplasty for the treatment of SSFS was reported first by Woodhall in 1945 (6). Thereafter, this procedure has been preferred by many authors for the treatment of SSFS (1, 2, 5). The aim of the treatment is to break down the cascade of atmospheric pressure, to expand the brain, to push the flap out and to again form a convex skin flap. What is required is to increase the volume via either expanding the brain parenchyma, the CSF or the blood volume. Although it has been reported that the increase in intracranial volume with the head down position is relatively limited (4), we achieved enough brain expansion by holding the patient in the Trendelenburg position intermittently. We did not prefer to induce brain edema to prevent further damage of the brain. If the patient's positional change had not been successful, a cranioplasty procedure would be planned. In conclusion, putting the patient intermittently in the Trendelenburg position may expand the intracranial compartment and improve the neurological status in SSFS. A routine cranioplasty procedure may be planned later.

## REFERENCES

1. Dujovny, Agner C, Aviles A: Syndrome of the trephined. Theory and facts. *Crit Rev Neurosurg* 9: 271-278, 1999
2. Fodstad H, Love JA, Ekstedt JE, Frieden H, Liequest BL: Effects of cranioplasty on cerebrospinal fluid hydrodynamics in patients with syndrome of the trephined. *Acta Neurochir (Wien)* 70: 21-30, 1984
3. Grant FC, Norcross NC: Repair of cranial defect by cranioplasty. *Ann Surg* 110: 488-512, 1939
4. Liao CC, Kao MC: Cranioplasty for patients with severe depressed skull bone defect after cerebrospinal fluid shunting. *J Clin Neurosci* 9(5): 553-555, 2002
5. Schiffer J, Gur R, Nisim U, Pollak L: Symptomatic patients after craniectomy. *Surg Neurol* 47: 231-237, 1997
6. Woodhall B, Spurling RG: Tantalum cranioplasty for war wounds of the skull. *Ann Surg* 121: 649-668, 1945
7. Yamaura A, Makino H: Neurological deficit in the presence of the sinking skin flap following decompressive craniectomy. *Neurol Med Chir* 17:43-53, 1977