

# Ultrasound Examination in the Surgical Treatment of Lower Extremity Peripheral Nerve Injuries: Part II

## Alt Extremitte Periferik Sinir Lezyonlarının Cerrahi Tedavisinde Preoperatif ve İntraoperatif Ultrasonografi Kullanılması

### ABSTRACT

**OBJECTIVE:** The aim of this clinical study was to evaluate the benefits of ultrasonographic imaging in the surgical treatment of lower extremity peripheral nerve lesions.

**METHODS:** Peripheral nerves in the lower extremity were evaluated by using real-time ultrasonographic examination. The capability of ultrasonography in terms of determination the type of injury, the position of the proximal and distal nerve stumps, the presence or absence of a neuroma, and perilesional scar tissue were evaluated.

**RESULTS:** Twenty-two cases with lower extremity peripheral nerve injuries aged between 21-52 years old were included in this study. Five (23%) had femoral nerve injuries and 17 (77%) sciatic nerve injuries. A total nerve transection was diagnosed in 1 (5%) case while the remaining 21 (95%) cases had incomplete sectioning of the nerves.

**CONCLUSION:** Preoperative and intraoperative ultrasonography for lower extremity peripheral nerve lesions may be used in the description of the degree of injury, determination of complete or incomplete nerve sectioning, the presence of hematoma and foreign body, the continuity of the nerve, determination of nerve stumps, perilesional scar tissue, and the presence of neuroma.

**KEY WORDS:** Lower extremity, Peripheral nerve injury, Surgical treatment, Ultrasonography

### ÖZ

**AMAÇ:** Bu klinik çalışmanın amacı ultrasonografik görüntülemenin alt extremitte periferik sinir lezyonlarının cerrahi tedavisindeki yararlarını incelemektir.

**YÖNTEMLER:** Alt extremitte periferik sinirleri real-time ultrasonografik inceleme ile değerlendirildi. Ultrasonografinin yaralanma tipinin belirlenmesi, proksimal ve distal sinir uçlarının pozisyonu, noroma varlığı veya yokluğu, lezyon çevresindeki skar dokusunun gösterilmesindeki kapasitesi incelendi.

**SONUÇLAR:** Bu çalışma yaşları 21-52 arasında değişen alt extremitte periferik sinir yaralanması olan 22 olguyu kapsamaktadır. 5 (%23) olgu femoral sinir yaralanması, 17 (%77) olgu ise siyatik sinir yaralanmasından oluşmaktaydı. 1 (%5) olguda tam sinir kesisi kalan 21 (%95) olguda ise tam olmayan sinir yaralanması saptandı.

**TARTIŞMA:** Alt extremitenin periferik sinir lezyonları için preoperatif ve intraoperatif ultrasonografi yaralanma derecesinin belirlenmesinde, sinirin tam veya kısmen kesildiğinin anlaşılmasında, hematoma veya yabancı cisim tanısının konulmasında, sinirin devamlılığı ve sinir uçlarının bulunmasında, perilesiyonel skar dokusu ve noroma bulunup bulunmadığının anlaşılmasında yararlıdır.

**ANAHTAR SÖZCÜKLER:** Alt extremitte, Cerrahi tedavi, Periferik sinir yaralanması, Ultrasonografi

Cengiz ÇOKLUK

Keremettin AYDIN

Ondokuzmayıs University, Medical Faculty,  
Department of Neurosurgery, 55139  
Samsun, Turkey

Received: 14.04.2007

Accepted: 22.05.2007

Correspondence address:

**Cengiz ÇOKLUK**

Ondokuzmayıs University

Medical Faculty Department of  
Neurosurgery 55139 Samsun, Turkey

Phone: +90 362 457 60 00/ 30 86

Fax : +90 362 457 60 41

E-mail : cengizcokluk@yahoo.com

## INTRODUCTION

Peripheral nerve injuries are relatively common pathologies in clinical practice. Penetrating, compressive, sharp, and hard objects such as knives, glass and missiles are frequent causes of nerve injuries. History, physical and neurological examination, and electro-diagnostic tests are generally used to diagnose the pathology (2, 3, 5, 6). Electro-diagnostic tests have been defined as the gold standard for the diagnosis, localization, and description of a nerve lesion. However, these tests may not yield reliable information, especially in acute stage of injury. In addition, a variety of parameters may affect electro-diagnostic examination (1, 2, 3, 4, 7).

On the other hand, electro-diagnostic tests may not be able to give any information regarding localization and description of the injury, visualization of nerve stumps, diagnosis of a neuroma, and the evaluation of perilesional tissue and foreign missiles in the acute and chronic period. The physician therefore needs a reliable, cheap, practical, and readily available diagnostic method in clinical practice. We hypothesized that ultrasonographic evaluation may offer some useful information about the injury site.

This clinical study aimed to evaluate the benefits and feasibility of presurgical and intraoperative ultrasonographic examination of the lower extremity in the localization and description of injury, evaluation of nerve stumps, diagnosing a stump neuroma, the determination of perilesional scar formation and foreign missiles in and around the injury site, and the assessing the severity of the lesion.

## MATERIALS and METHODS

### Study Population:

The study population included 22 patients (10 female and 12 male) who were admitted to our department (Department of Neurosurgery, Ondokuzmayıs University Medical Faculty) because of peripheral nerve injury of the lower extremity between 2001 and 2004.

### Technique of Ultrasonography:

Ultrasonographic examination was performed by the first author of this study using a Tosbee ultrasound (Toshiba inc. Tokyo) with 5-7, 5 MHz linear probe. Patients were positioned in supine (for

femoral nerve) and prone (for sciatic nerve) positions. Ultrasound gel was plastered on the probe surface and skin to enhance visualization of peripheral nerves and musculoskeletal structures of the lower extremity. Before starting ultrasonographic examination, we grossly determined and localized the injured nerve and injury site using neurological examination findings, the result of electro-diagnostic studies, anatomical landmarks, and skin indents. We started our examination about 10 cm proximal to the suspected region and continued 10 cm distally to the injury site. Bone, muscles, tendons, vascular structures, and peripheral nerves were identified and differentiated. The continuity, architecture, shape, calibration and integrity of the involved nerve and peripheral tissues were examined in perpendicular and transverse planes. Images were paused on the monitor screen and printed on paper for archival and further examination. Sonographic findings of the patients who underwent surgery were compared with gross surgical observations.

### Evaluation of the capability of ultrasonographic examination:

We examined the capability of ultrasonographic examination in terms of visualization and identification of a peripheral nerve, localization of injury, description of the type of the injury, determination of nerve stumps and foreign missiles, diagnosing a neuroma, and evaluation of perilesional scar tissue. Ultrasonographic evaluation of the seven parameters was separated into three grades as poor, good, and excellent according to the examiner's description. A poor grade was scored as 1, good as 2 and excellent as 3. Data were expressed here as the mean  $\pm$  standard error of the mean score. Differences in mean score between poor and excellent-good results were analyzed using Student's t-test with  $p < 0,001$  being required for significance.

## RESULTS

This study included 22 adult cases (ten female and 12 male, aged between 21 and 52 years old). Five (23%) had femoral nerve injury and 17 (77%) sciatic nerve injury.

In all cases the nerves were injured by penetrating and non-penetrating objects. Thirteen (59%) of them were injured by a knife or retained metallic object, 5 (23%) by civilian gun-shot, and the remaining 4 (18%) of them by compression.

Ten (45%) of them were acute injury (first 72

hours from injury) at the admission. Remaining 12 (55%) of them were chronic (after 72 hours from injury) cases.

A total nerve transection (neurotmesis in Seddon classification and fourth and fifth degree in Sunderland classification, Group I lesion in intra-operative grading system) was diagnosed in 1 (5%) case. Perilesional scar tissue formation was found in 4 (18%) cases. 1 (5%) cases had stump neuroma diagnosed by sonographic examination. Four (18%) cases had foreign missiles in injury site.

The capability of ultrasonographic examination was satisfactory in all evaluation parameters. The differences between poor and good/excellent results was statistically significant ( $p < 0,0001$ ). The capability of ultrasound in the surgical treatment of peripheral nerve injury was shown in Table I.

**DISCUSSION**

The timing of surgical intervention for injured peripheral nerves is a challenging issue in the practice of peripheral nerve surgery. There is no common consensus among authors for the timing of surgical exploration. Some authors advocate early repair and prefer delayed surgical intervention for up to three weeks after a traumatic injury (4, 13). Others suggest early surgical exploration with repair of the injured segment as soon as possible (4, 13). The main concerns of authors who suggest late surgical intervention are the possibility of spontaneous nerve repair, and waiting for reliable information from electro-diagnostic studies. In the early stage of injury (in the first three weeks), electro-diagnostic studies may not provide reliable information about the precise details of an injury. On the other hand, even if electro-diagnostic studies are

performed after three weeks, we may still not be able to obtain objective information about the pathomorphological status of the nerve. The pathomorphological status consists of the continuity, architecture, shape, calibration, and integrity of a nerve segment.

The authors who suggest acute surgical intervention prefer direct visualization via wide exposure using skin indents. The presence of hematoma, foreign particles, necrotic tissues, and the presence of tendon and vessel injury are also important parameters in the selection of the time for surgery. They argue that direct exploration offers visualization of the complete details of the pathomorphological status of an injury.

We hypothesized that ultrasonographic examination of the lower extremity may offer reliable information about the patho-morphological status of the injured nerve including detection of a hematoma and foreign particles. Ultrasonography is a real-time, mobile, and radiation-free image processor. It may be able to show the continuity, architecture, shape, calibration, and integrity of a nerve. Some previous studies have evaluated peripheral nerves by ultrasound (8, 9, 10, 11, 12). These authors described the normal ultrasonographic appearance of peripheral nerves (8, 9, 10, 11, 12). Computerized tomography (CT) and magnetic resonance imaging (MRI) can also be used for neuroradiological imaging of nervous and musculoskeletal tissues. MRI has higher capability than CT for this purpose. However, there are some difficulties with these techniques regarding the absence of real-time images, and the necessity of reconstruction to determine and distinguish the nerves.

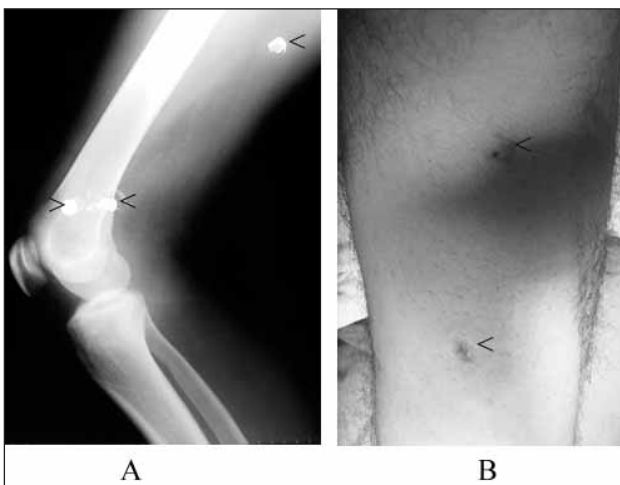
**Table I.** The capability of ultrasound in the evaluation of peripheral nerve injury

Evaluation Parameters	Capability					
	Poor		Good		Excellent	
	n	%	n	%	n	%
Visualization and identification of a peripheral nerve (n=22)	1	4.5	9	40.9	12	54.6
Localization of injury (n=22)	3	13.6	6	27.3	13	59.1
Description of the type of injury (n=22)	2	9,1	5	22.7	15	68.2
Determination of the position of proximal and distal nerve stumps (n=1)					1	100
Determination of foreign particles (n=4)					4	100
Diagnosing a stump neuroma (n=1)			1	100		
Determination of perilesional excessive scar tissue (n=4)	1	25	3	75		
Mean score (mean ± standard deviation)	1 ± 1.15		9.6 ± 6.06		19.3 ± 19.9	

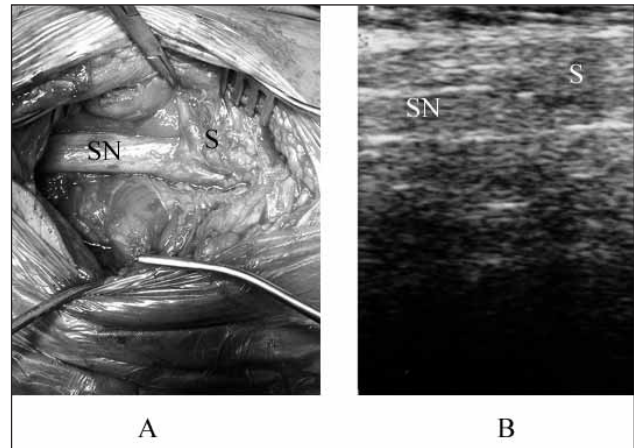
The general question is the necessity of imaging modalities in peripheral nerve lesions. It is clear that neuroradiological imaging is necessary to obtain detailed information about the current situation of a nerve after an injury. Even if early surgical exploration is selected, neuroradiological imaging studies are necessary to obtain some information regarding the current status of the nerve. In the acute stage, the degree of injury, determination of complete or incomplete nerve sectioning, the presence of a hematoma or a foreign body may be provided by the sonographic examination. In the chronic stage, the continuity of the nerve and the presence of nerve stumps, perilesional scar tissue, and a neuroma may be also demonstrated by using ultrasonography.

Our results from this study demonstrated that ultrasonography can be helpful in the imaging of peripheral nerves in the acute and chronic stages of injury (Figur 1,2,3,4,5). The capability of visualization and identification of a peripheral nerve was found to be excellent in 55.6% of the cases. Only 2.8% of cases demonstrated poor visualization. The capability to demonstrate foreign particles and diagnose a stump neuroma was excellent in 100% and 77.8% of the cases respectively.

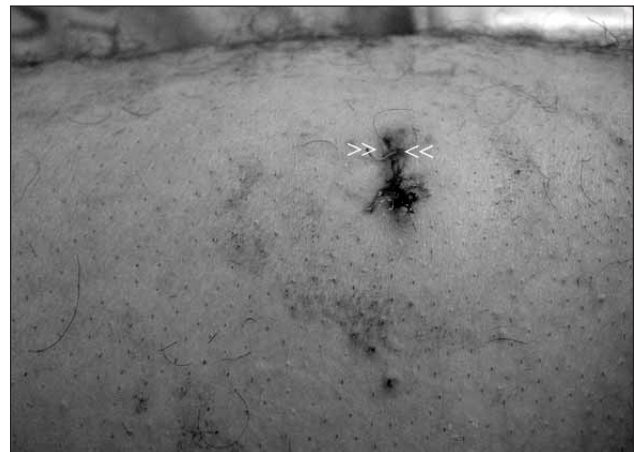Future developments for peripheral nerve imaging should be to demonstrate the anatomophysiological continuity of nerves. Axonal flow, loss



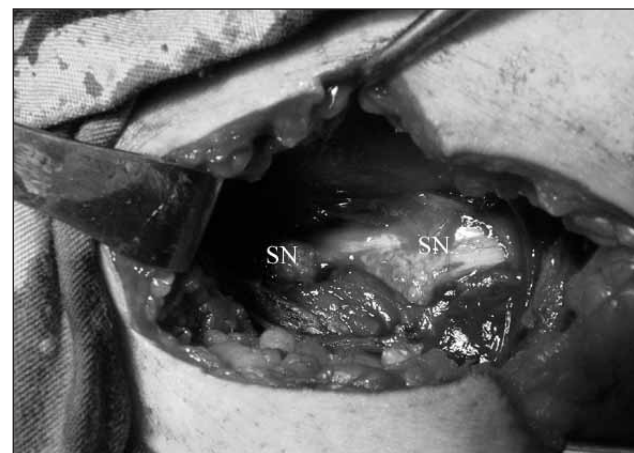**Figure 1:** A. This case was injured by a gun-shot. Direct X-ray shows the bullets (Arrows show the bullets) B. Neurological and electrophysiological examination revealed that total sciatic nerve injury. This figure shows the injured site on the skin surface (Arrows shows the skin surface)



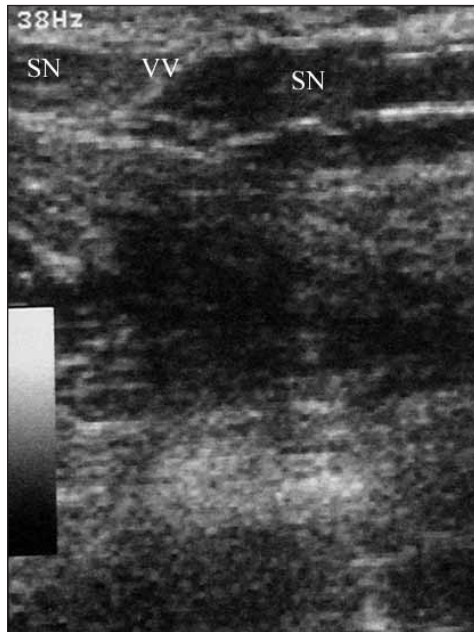**Figure 2:** A. Operative finding of the case showed in Figure 1 (SN: Sciatic nerve, S: Scar tissue). B. Ultrasonographic findings (SN: Sciatic nerve, S: Scar).



**Figure 3:** This case is an example of a retained knife. In this figure, the skin surface had the mark of a retained knife (Arrows shows the retained knife).



**Figure 4:** This figure shows the operative findings (SN: Sciatic nerve)



**Figure 5:** Ultrasonographic photograph demonstrated the injured site and sciatic nerve (Arrow shows the injured site, SN: Sciatic nerve).

of the schwann sheath, and degenerative and regenerative findings should be monitored using imaging techniques for peripheral nerves.

### CONCLUSION

This clinical study aimed to evaluate the capability of ultrasonography in the examination of lower extremity peripheral nerve injuries. Our study revealed that ultrasonography in peripheral nerve injuries is a cheap, simple and readily available diagnostic tool in clinical practice. Future detailed studies are necessary to enable the grading of lesions and determining the type of injury using the information obtained from the neuroradiological evaluation.

### REFERENCES

1. Çokluk C, Aydın K, Senel A. Presurgical ultrasound assisted neuroexamination in the surgical repair of peripheral nerve injury. *Minim Invasive Neurosurg* 2004; 47: 169-172.
2. Gentili F, Hudson AR, Midha R. Peripheral nerve injuries: Types, causes, and grading. In: Wilkins RH, Rengachary SS (eds). *Neurosurgery*. Vol 3. New York: McGraw-Hill 1996: 3105-3114.
3. Kline DG. Surgical repair of peripheral nerve injury. *Muscle Nerve* 1990; 13: 843-852.
4. Kline DG, Hudson AR. Acute injuries of peripheral nerves. In: Youmans JR (ed) *Neurological surgery* Vol 4. Philadelphia: W. B. Saunders Company 1990: 2423-2510.
5. Lee SK, Wolfe SW. Peripheral nerve injury and repair. *J Am Acad Orthop Surg* 2000; 8: 243-252.
6. Lilla JA, Phelps DB, Boswick JA Jr. Microsurgical repair of peripheral nerve injuries in the upper extremity. *Ann Plast Surg* 1979; 2: 24-31.
7. Mailander P, Berger A, Schaller E, Ruhe K. Results of primary nerve repair in the upper extremity. *Microsurgery* 1989; 10:147-50.
8. Martinoli C, Bianchi S, Dahmane M, Pugliese F, Bianchi-Zamorani MP, Valle M. Ultrasound of tendons and nerves. *Eur Radiol* 2002; 12: 44-55.
9. Martinoli C, Bianchi S, Giovagnorio F, Pugliese F. Ultrasound of the elbow. *Skeletal Radiol* 2001; 30: 605-614.
10. Martinoli C, Serafini G, Bianchi S, Bertolotto M, Gandolfo N, Derchi LE. Ultrasonography of peripheral nerves. *J Peripher Nerv Syst* 1996; 1: 169-178.
11. Peer S, Bodner G, Meirer R, Willeit J, Piza-Katzer H. Examination of postoperative peripheral nerve lesions with high-resolution sonography. *AJR* 2001; 177: 415-19.
12. Peer S, Kovacs P, Harpf C, Bodner G. High-resolution sonography of lower extremity peripheral nerves. Anatomic correlation and spectrum of disease. *J Ultrasound Med* 2002; 21: 315-22.
13. Worth RM. Anatomy and physiology of peripheral nerves. In: Wilkins RH, Rengachary SS (eds). *Neurosurgery* Vol 3. New York: McGraw-Hill 1996: 3099-3104.