

Delayed Infection 6 Years After Spinal Instrumentation: A Case Report

ABSTRACT

Infection is the major and important complication of spinal instrumentation generally requiring removal of the implant. Although findings of infection usually appear within a few months after operation, they may appear even after few years in some cases. A case with delayed postoperative infection 6 years after surgery is reported. A 27-year-old female with purulent flow from her anterolateral skin incision scar was diagnosed as delayed spinal infection 6 years after anterior and posterior combined spinal instrumentation performed for treatment of giant cell tumor of L3 vertebral body. Staphylococcus aureus was detected from purulent flow. Infection was treated by removal of the implant and antibiotherapy. Spinal infection after instrumentation may appear even a few years later. Patients must therefore be carefully followed for a long time. Staphylococcus aureus can stay silent for a long time.

KEY WORDS: Delayed infection, Instrumentation, Postoperative complication, Spinal infection

INTRODUCTION

The incidence of deep spinal infection is about 0.9-1.9% and increases with the use of instrumentation (11,18,20). However, most infections develop within 2 to 4 weeks after surgery (11,13). Kuo et al (11) divided postoperative spinal infections in three groups according to the onset of infection signs: acute (<2 weeks), subacute (2-4 weeks), and chronic (>4 weeks). In their series of postoperative deep wound infection with 30 cases after various spinal operations including simple discectomy or complex instrumentations, only 16.6% had a chronic infection. The incidence of delayed infection after spinal instrumentation is 0.2 to 4.7% (1,3-5,11,14,17). Diagnosis of delayed infections may be difficult because of their low incidence and variety of clinical symptoms (3).

CASE REPORT

A 27-year-old female was admitted with complaints of purulent flow from her anterolateral skin scar.

She was operated using a combined anteroposterior approach for treatment of giant cell tumor of L3 body in two sessions with a one-week interval in our clinic 6 years ago. Anterior and posterior instrumentations were performed after total removal of the tumor. The operation time was 4.5 hours for anterior operation, and 3.5 hours for the posterior one. Prophylactic antibiotherapy with intramuscular 1 gr cefamezin 1 hour before the surgery was performed for both operations, and the same doses was repeated for three times with 8 hours intervals postoperatively. The patient complained of severe low back pain 6 weeks after the second operation. There was a superficial wound

Erhan EMEL¹

Feyza KARAGÖZ GÜZEY²

Deniz GÜZEY³

Hakan SEYİTHANOĞLU⁴

Barış SEL⁵

İbrahim ALATAŞ⁶

1,2,4,5,6 Vakıf Gureba Eğitim Hastanesi,
Noröşirürji, İstanbul, Turkey

3 Vakıf Gureba Eğitim Hastanesi,
Genel Cerrahi, İstanbul, Turkey

Received : 25.01.2007

Accepted : 13.03.2007

Correspondence address

Feyza KARAGÖZ GÜZEY

E-mail : fkarag@yahoo.com

Phone : +90 212 534 69 00

Fax : +90 212 631 89 18

infection and *Staphylococcus aureus* was found in cultures. The erythrocyte sedimentation rate (ESR) was 56 mm/h, and C reactive protein (CRP) level was 3.56. The white blood cell count (WBC) was 14.300/mm³. Her infection markers decreased and her complaints diminished after antibiotherapy. She gave birth 2 years later, and there was no complaints. A purulent flow developed in the posterior skin scar 80 months after the surgery and the posterior implant had been removed and she had been treated by antibiotherapy for 4 weeks in another center. Five months later, she was admitted to our clinic with a complaint of discharge from her anterolateral scar.

Physical examination revealed normal neurological findings. The ESR was 68 mm/h, and the CRP level was 2.84. The white blood cell count (WBC) was 12.800/mm³. On lumbosacral X-rays, there was a strut graft in place of L3 vertebral body, and there was an anterior screw-rod instrumentation system between L2 and L4 (Figure 1). Magnetic resonance imaging (MRI) examination revealed

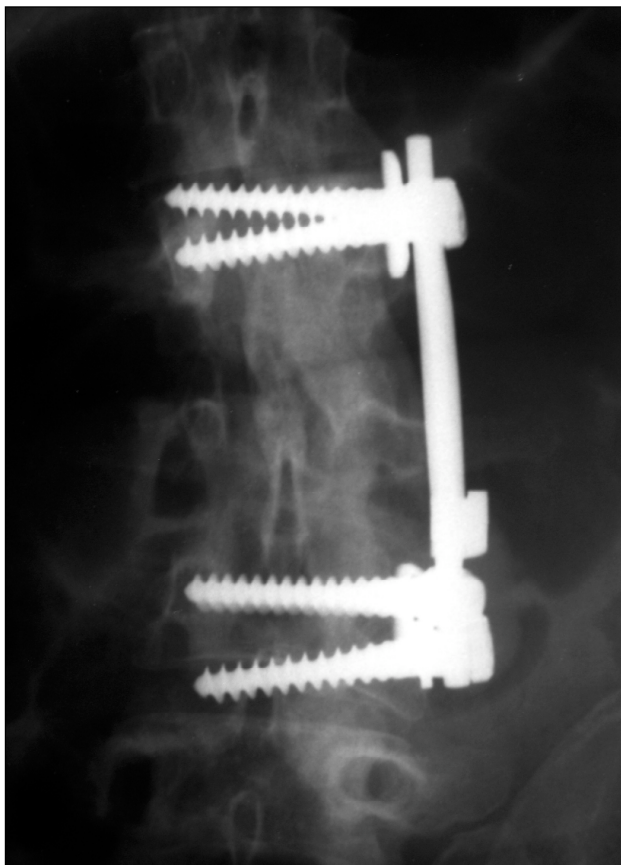
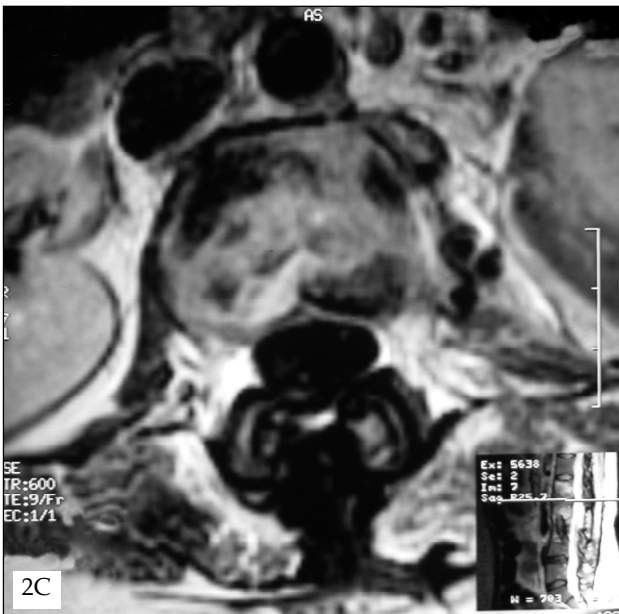
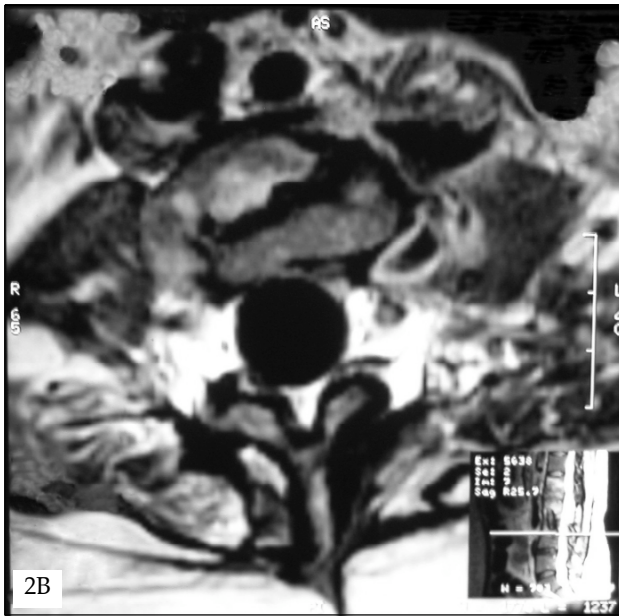


Figure 1: Anteroposterior lumbosacral radiography of the patient showing the anterior plate between L2 and L4 bodies.

osteomyelitis of the L1, L2, L4 and L5 bodies affecting especially the L1-2 intervertebral level (Figure 2A and C). The screws of the anterior implant were in the L2 and L4 bodies, and the infection reached to the rods of the implant at the left paravertebral region (Figure 2 B).

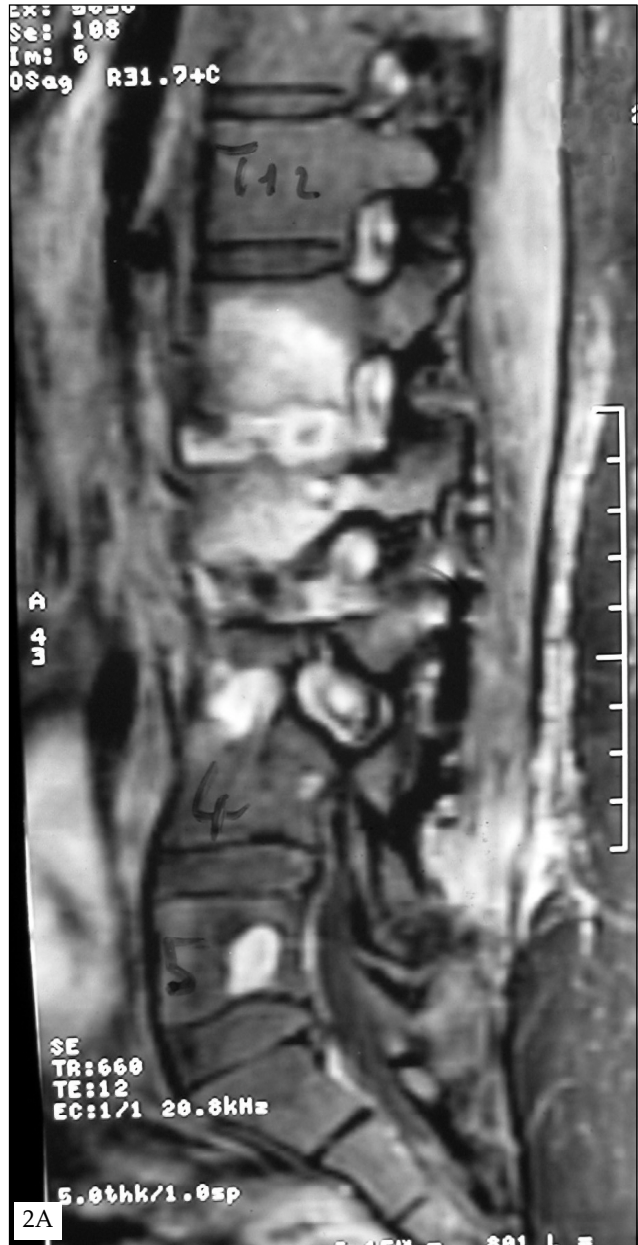

Figure 2: Sagittal T1-weighted magnetic resonance imaging (MRI) section with gadolinium enhancement (A) showed L1, L2, L4 and L5 osteomyelitis and L1-2 discitis. In axial T1-weighted MRI section with gadolinium enhancement at L3 level (B), it was seen that infection reached to the anterior implant; and axial T1-weighted MRI section with gadolinium enhancement at L1-2 intervertebral disc level (C) showed spondylodiscitis.



Cultures of purulent flow from the scar yielded *Staphylococcus aureus*, and vancomycin 2 gr/per day was started according to the sensitivity tests. The anterior implant was removed, and debridement of soft tissue and bone was made by an anterolateral approach. The strut graft was fused to the vertebral bodies and new stabilization was therefore not required. Pathological examination of surgical material was consistent with nonspecific infection and *Staphylococcus aureus* was found again in cultures.

The wound healed satisfactorily. ESR was 40 mm/h, and CRP was 0.31 after a 4-week

antibiotherapy course with vancomycin. Her control X-rays and MRI examination revealed that there was neither instability nor infection findings 10 months after the surgery. She had no complaints 34 months later.

DISCUSSION

Diagnosis of a delayed infection after spinal instrumentation is difficult as postoperative spinal infections usually develop between 2 to 4 weeks postoperatively (13), clinical symptoms may vary, and the incidence is low (3,4,17). A variety of clinical symptoms including back pain and feeling of malaise are found, but spontaneous drainage appears to be the most common (3). Fever is present in only a few patients (3), and pain may not be present (4).

Infection markers such as CRP, ESR, and white blood cell counts are significantly higher in patients who have undergone instrumentation compared to those in whom no spinal instrument has been implanted (16). The levels of these markers begin to increase 6 hours after surgery and peak on the 2nd and 3rd postoperative days. Generally, normal levels are detected between the 5th and 21st days postoperatively (16). Elevated infection markers after this period must be accepted as a warning.

Diagnostic imaging may be helpful for the diagnosis of postoperative spinal infection in the presence of infection markers. Computed tomography (CT) and MRI are used to determine the spread of infection to instruments, epidural space, vertebral bodies and soft tissues. Abscesses or drainage material are typically contiguous with the implant and the fusion mass in postoperative infection cases (3). The infection reached the anterior instrument in the presented patient as well.

Bose reported a review of 93 cases reported in literature together with his own four cases with delayed infection after spinal instrumentation (3). He proposed three possible causes for a delayed infection: intraoperative seeding, metal fretting causing a sterile inflammatory response, or stimulation of low-virulent organisms to fester and hematogenous seeding.

Intraoperative seeding often appears clinically as a wound infection that occurs early in the postoperative period. The common finding is low-virulent bacteria (9,14,15,17).

Some reports of the late presentation of local drainage indicate that metal fretting or micromotion

between the parts of the implant caused a sterile inflammatory response (7,8). Beguiristain et al (2) reported in a case with delayed infection 14 years after spinal instrumentation that bacteria might modify the rate of corrosion of metals, and they named this concept as "biocorrosion" or "microbially influenced corrosion".

Hematogenous seeding may cause delayed infection especially in patients with distant infection foci (3,9,13). The instrument is always prone to bacteria-related adherence and growth that results in clinical infection in the presence of bacteremia (13).

In the presented patient, presence of a superficial wound infection 6 weeks after operation indicated that the source of infection was intraoperative seeding. This early infection was treated by antibiotherapy alone, and removal of implant was not necessary. The case was uneventful for 6 years until delayed infection. *Staphylococcus aureus* is not a low-virulent bacterium, and it would not be expected to stay silent for such a long time. However, the presence of the same bacteria in the cultures in both early and delayed infections, and the absence of a distant infection focus before the delayed infection period indicates that the source of the delayed infection may be the early one. Bose et al (3) also reported a case with delayed infection caused by *Staphylococcus aureus* 13 months after spinal instrumentation without any distant infection focus.

Effective treatment usually includes removal of the implants, irrigation and debridement, and antibiotherapy (3). Glycocalyx substance covering the instrument is usually the source of infection, and only removal of the instrument will eradicate the glycocalyx and the bacteria (3). However, if the infection occurs before the maturation of fusion, or the patient is asymptomatic after intravenous antibiotic treatment and the ESR is reduced, the implant may remain in place and irrigation and debridement can be used successfully (3,10,13,19). In recent years, management with vacuum-assisted wound closure has also been recommended. Mehbod et al (12) reported in 20 patients with deep infection after spinal instrumentation treated with this method that all patients achieved a clean closed wound without removal of instrumentation at a minimum follow-up of 6 months. The instrument should be removed if the infection is found to be contiguous with the implant or the implant is

thought to be a cause of the infection (3). In the presented patient, the system was removed because instrumented vertebral bodies were infected, there was a soft tissue infection around the anterior rods, and the fusion had matured.

CONCLUSIONS

Spinal infection due to instrumentation may appear even after a few years and patients must therefore be carefully followed for a long time. *Staphylococcus aureus*, one of the most common bacteria causing postoperative wound infections, may stay silent for a long time, and fusion may mature even in presence of *Staphylococcal* infection.

REFERENCES

1. Antuna SA, Mendex JG, Lopez-Fanjul C, Paz Jimenes J: Cotrel-Dubousset instrumentation in idiopathic scoliosis a 5-year follow-up. *Acta Orthopaedica Belg* 63:74-81, 1997.
2. Beguiristain J, del Rio J, Duarte J, Barroso J, Silva A, Villas C. Corrosion and late infection causing delayed paraparesis after spinal instrumentation. *J Pediatr Orthop B*. 2006 15:320-323.
3. Bose B: Delayed infection after instrumented spine surgery: case reports and review of the literature. *Spine J* 3:394-399, 2003.
4. Clark CE, Shufflebarger HL. Late developing infection in instrumented idiopathic scoliosis. *Spine* 24:1909-1912, 1999.
5. Dietz FR, Koontz FP, Round EM, Marsh JL: The importance of positive bacterial cultures of specimen obtained during clean orthopedic operations. *J Bone Joint Surg Am* 73:1200-1207, 1991.
6. Dubousset J, Shufflebarger H, Wenger D: Late "infection" with CD instrumentation. *Orthop Trans* 18:121, 1994.
7. Gaine WJ, Andrew SM, Chadwick P, Cooke E, Williamson JB: Late operative site pain with Isola posterior instrumentation requiring implant removal: infection or metal reaction? *Spine* 26:583-587, 2001.
8. Hatch RS, Sturm PF, Wellborn CC. Late complication after single-rod instrumentation. *Spine* 13:1503-1505, 1998.
9. Heggeness MH, Essess SI, Errico T, Yuan HA. Late infection of spinal instrumentation by hematogenous seeding. *Spine* 18:492-496, 1993.
10. Ido K, Shimizu K, Nakayama Y, Shikata J, Matsushita M, Nakamura T: Suction-irrigation for deep wound infection after spinal instrumentation : a case study. *Eur Spine J* 5:345-349, 1996.
11. Kuo CH, Wang ST, Yu WK, Chang MC, Liu CL, Chen TH: Postoperative spinal deep wound infection: a six-year review of 3230 selective procedures. *J Chin Med Assoc*. 67:398-402, 2004.
12. Mehbod AA, Ogilvie JW, Pinto MR, Schwender JD, Transfeldt EE, Wood KB, Le Huec JC, Dressel T: Postoperative deep wound infections in adults after spinal fusion: management with vacuum-assisted wound closure. *J Spinal Disord Tech* 18:14-17, 2005.
13. Naderi S, Acar F, Mertol T. Is spinal instrumentation a risk factor for late-onset infection in cases of distant infection or surgery? *Neurosurg Focus* 15: E15, 2003.

14. Richards BS, Emara KM. Delayed infections after posterior TSRH spinal instrumentation for idiopathic scoliosis. *Spine* 18:1990-1996, 2001.
15. Robertson PA, Taylor TK. Late presentation of infection as a complication of Dwyer anterior spinal instrumentation. *J Spinal Disord* 6:256-259, 1993.
16. Takahashi J, Ebara S, Kamimura M, Kinoshita T, Itoh H, Yuzawa Y, Sheena Y, Takaoka K: Early-phase enhanced inflammatory reaction after spinal instrumentation surgery. *Spine* 26:1698-1704, 2001.
17. Viola RW, King HA, Adler SM, Wilson CB: Delayed infection after elective spinal instrumentation and fusion. A retrospective analysis of eight cases. *Spine* 22:2444-2451, 1997.
18. Weinstein MA, McCabe JP, Cammisa FP Jr: Postoperative spinal wound infection: a review of 2,391 consecutive index procedures. *J Spinal Disord* 13:422-426, 2000.
19. Wimmer C, Gluch H: Aseptic loosening after CD instrumentation in the treatment of scoliosis: a report about eight cases. *J Spinal Disord* 11:440-443, 1998.
20. Wimmer C, Gluch H, Franzreb M, Ogon M: Predisposing factors for infection in spine surgery: a survey of 850 spinal procedures. *J Spinal Disord* 11:124-128, 1998.