

# Giant Cell Tumor of the Tendon Sheath in the Cervical Spine: Case Report

## Servikal Omurgada Dev Hücreli Tendon Kılıfı Tümörü: Olgu Sunumu

ŞÜKRÜ AYKOL, GÖKHAN KURT, MEMDUH KAYMAZ, NALAN AKYÜREK, GÜLEN AKYOL

Gazi University Faculty of Medicine, Department of Neurosurgery (ŞA, GK, MK), Department of Pathology (NA, GA)

Received: 23.09.2002 ⇒ Accepted: 10.12.2002

**Abstract:** By this case report we will describe an unusual settlement of tenosynovial giant cell tumor. These lesions most often get origin from tenosynovium of the digits, knees or ankles. Rarely they can arise from bigger joints. In our case the patient had a tumor developed from the tendon sheath in the cervical spine. This is the third case of tenosynovial giant cell tumor of the cervical spine reported to date. In our study the clinical, radiological, surgical and pathologic features of this tumor are described and a brief review of the previous literature is provided.

**Key Words:** Cervical spine, giant cell tumor, tendon sheath

**Özet:** Bu olgu sunumunda tenosinoviyal dev hücreli tümörün nadir bir lokalizasyondaki yerleşiminden bahsedilmiştir. Bu lezyonlar genelde parmak, diz ve ayak bileklerinin tenosinoviyasından köken alırlar. Nadir olarak büyük eklemleri de tutabilirler. Mevcut olgu sunumunda hastanın servikal omurgasındaki tendon kılıfında tümör saptanmıştır ve bu şu ana kadar yayınlanmış üçüncü vakadır. Çalışmamızda bu tümörün klinik, radyolojik, cerrahi ve patolojik özellikleri ve daha önceki yayınların bir derlemesi yapılmıştır.

**Anahtar Kelimeler:** Servikal omurga, dev hücreli tümör, tendon kılıfı

### INTRODUCTION

Tenosynovial giant cell tumors belong to a group of lesions believed to arise from the synovium of tendon sheaths, bursae and joints (2, 4). They most often get origin from the tenosynovial structures in the digits, and are less frequently seen in large joints. This form of neoplasia was first described by Chassaignac, who referred to it as a "cancer of tendon sheath" (3). Giant cell tumor of the tendon sheath (GCTTS) is also known as: fibrous xanthoma of synovium, pigmented villonodular synovitis, benign

synovioma, sclerosing hemangioma, and tenosynovial giant cell tumor (2)

The case described in this article is only the third case of GCTTS of the cervical spine reported to date. We present the histological, radiological, intraoperative and pathological findings of this case.

### CASE REPORT

A 33-year-old man who had had neck and left arm pain for 1 year was referred to our

Neurosurgery Department for evaluation. He experienced pain not only during his daily activities but also throughout the night while he was resting. His pain did not respond to analgesics. The patient's medical history was unremarkable.

Neurological examination of the patient revealed left C5-C6-C7 hypoesthesia, motor weakness on forearm flexion and forearm extension, and diminished left triceps reflex. Also his range of neck motion was restricted due to pain.

Plain films of the cervical spine demonstrated a lytic lesion in the right lamina of the C2 vertebra.

Since the patient had typical radiculopathy symptoms and signs we planned a cervical spinal Magnetic Resonance Imaging (MRI) which demonstrated disc herniation and extrusion of disc material at C5-6 and C6-7. The images also showed an extradural intracanalicular mass lesion on the anterior aspect of the right lamina of C2. The mass had obliterated the subarachnoid space but was not compressing the spinal cord. T1-weighted MRI with gadolinium contrast administration revealed diffuse homogeneous enhancement of this lesion (Figures 1 and 2)

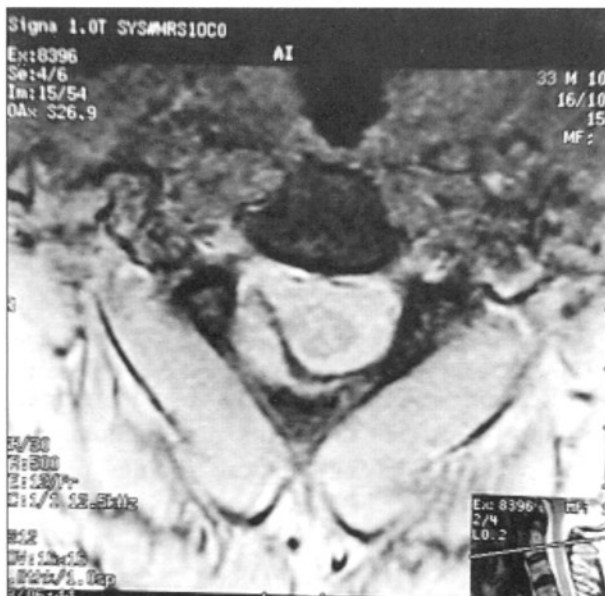

Figure 1: T1-weighted axial MRI without contrast demonstrates a mass lesion at C2 level that is isointense to muscle.

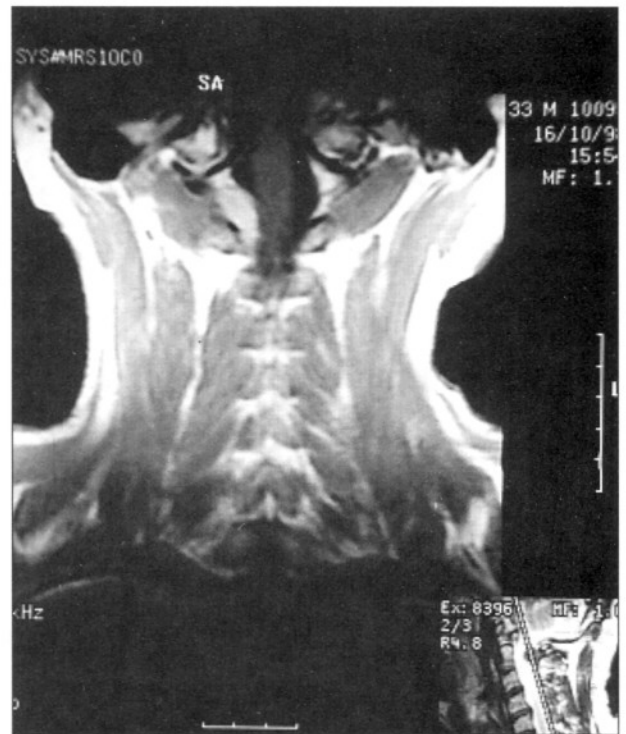


Figure 2: Contrast-enhanced coronal T1-weighted MRI shows enhancement of the same lesion at C2 level.

Based on the subjective and objective evidence of nerve root compression, surgical decompression was planned for the disc herniation and extrusion of disc material at C5-6 and C6-7. Since there was no evidence of any neurological deficits referring to the mass at the level of C2 and the radiological evaluation of the mass seemed to be benign we didn't planned a surgical decompression for the mass and left it to follow up. Anterior cervical discectomy and bilateral foraminotomy with iliac bone-graft fusion were performed at C5-6 and C6-7. After this operation, the patient's neurological deficits rapidly resolved.

However repeat MRI after 3 months post-surgery showed that the mass at the C2 level had enlarged (Figure 3). Since it was not possible to rule out malignancy without pathological diagnose, a second operation was done to remove the mass. At surgery, we found that the tumor had eroded the right C2 lamina. Hemilaminectomy exposed a solid, soft, encapsulated red-pink coloured tumor that extended through the C2 neural foramen. The mass was totally excised. Control early post

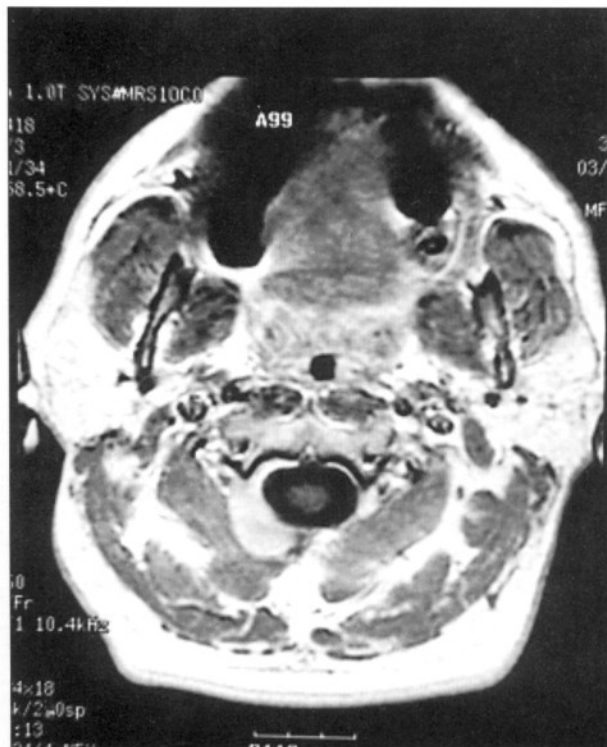

Figure 3: Contrast-enhanced axial T1-weighted MRI at 3 months after surgery at C5-6 and C6-7 demonstrates enlargement of the C2 mass.

operative MRI showed postoperative changes and no residual mass at the C2 operation site (Figure 5).

The tumor consisted of uniform, round or polygonal histiocyte-like cells mixed with xanthoma cells and multinucleate giant cells (Figure 4). The stroma contained spindle cells and

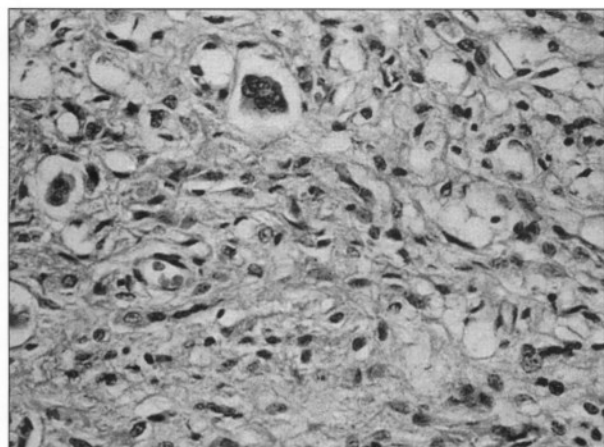


Figure 4: A high-power photomicrograph shows sheets of round cells along with xanthoma cells and multinucleate giant cells. (HE x400)

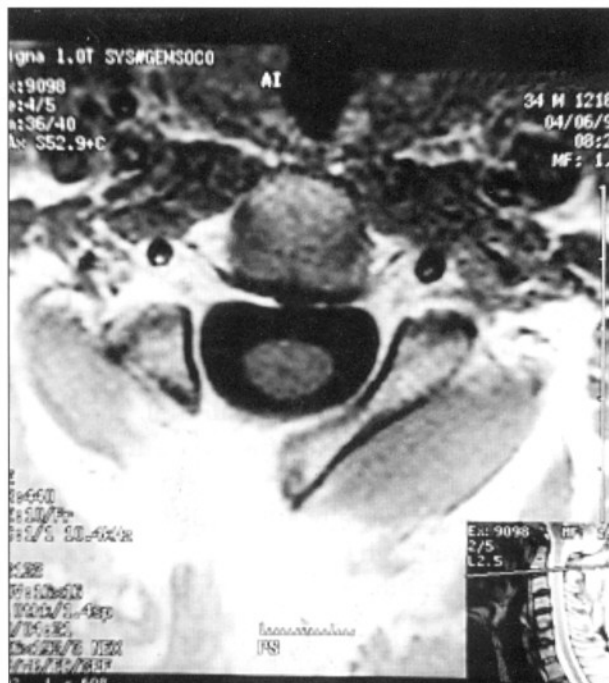

Figure 5: Post operative early gadolinium enhanced axial T1-weighted MRI demonstrates normal postoperative changes and no residual mass at the operation site.

bundles of collagen fibers. There were hemosiderin deposits, cholesterol clefts and scattered mitotic figures throughout the lesion as well. Immunohistochemical studies showed that the multinucleate giant cells were positive for CD-68 and negative for neurofilament, keratin, desmin, smooth muscle actin and synaptophysin.

## DISCUSSION

Giant cell tumor of the tendon sheath is the second most frequent subcutaneous tumor of the hand. In order of decreasing incidence, the most common sites for these masses are the hands and fingers (87.8%), knees (65.5%), ankles and feet (5.5%), and hips (1.1%) (2). There is a female bias, with a ratio of 2:1 (2) The reported age range of patients with GCTTS is 4 to 80 years, and peak incidence is in the fourth decade of life (2). Tenosynovial giant cell tumors are classified in two groups according to encapsulation and localization. The encapsulated extraarticular type (localized form) is known as nodular tenosynovitis, whereas the non-encapsulated intraarticular type (diffuse form) is known as pigmented villonodular

synovitis (4). The most common presentation for both of these forms is a palpable but painless mass. Diffuse form of the GCTTSs are locally aggressive lesions that do not metastasize. Whereas local form develop gradually over a long time and often remain the same size for several years(3). Histologically, they consist of multinucleate giant cells, histocytes, and large number of cells with varying amounts of intra and extracellular hemosiderin pigment (1, 5, 6).

The primary treatment is surgical, and most GCTTS are easily dissected from the surrounding tissue. Reports indicate that 40% to 50% of all GCTTS cases recur locally after excision (3, 4). The median interval from initial surgery to recurrence is 24 months, and the range is 2 months to 5 years (2).

On T1-weighted MRI, the signal associated with GCTTS is isointense to skeletal muscle. On T2-weighted images the signal may be isointense, hypointense or hyperintense to skeletal muscle. This variability is due to the different amounts of hemosiderin contained in these tumors (2). In our case T1-weighted axial MRI investigation without contrast agent demonstrated a mass lesion at C2 level that is isointense to muscle. Contrast-enhanced coronal T1-weighted MRI showed diffuse enhancement of the same lesion which is compatible with MRI findings described as in the literature for GCTTS.

The pathological diagnosis of our case was localized type of GCTTS. Since the pathologic diagnosis was the benign form of the GCTTS no further therapy was advocated and the patient left to follow up. In the fourth year of the follow up our patient demonstrated no recurrences and any symptoms. Radiotherapy can be a choice of therapy for treatment of surgically unresectable

tumors especially for villonodular diffuse type, but there are no reports in the literature concerning this type of treatment is adequate for the cure of GCTTS.

Spinal GCTTS is extremely rare. The radiological and clinical features of these tumors may mimic those of numerous other non-neoplastic and neoplastic lesions in the same region. More extensive surgery must be performed on lesions that continue to recur. Our case is particularly significant because GCTTS of the spine is extremely rare and in our case no recurrent disease was diagnosed for the following four years.

**Correspondence:** Gökhan Kurt, M.D.  
Gazi Üniversitesi Tıp Fakültesi  
Hastanesi Beyin ve Sinir Cerrahisi AD  
Beşevler, Ankara-Turkey  
Phone: 0-312-2141000/5116-5119  
Fax : 0-312-2129004

#### REFERENCES

- 1) Bogumill GP, Sullivan DJ, and Baker GI: Tumors of the hand: Clinical orthopaedics and related research 108:214-222, 1975
- 2) Bui-Mansfield LT, Youngberg RA, Coughlin, and Chooljian D: MRI of giant cell tumor of the tendon sheath in the cervical spine. Case report. J Comput Assist Tomogr 20:113-5, 1996
- 3) Enzinger FM, Weiss SW: Benign tumors and tumor-like lesions of synovial tissue, in Soft tissue tumors ed 4. Mosby-Year Book, 2000, chapter 28 pp 1037-1062
- 4) Mahmood A, Caccamo DV, Morgan JK: Tenosynovial giant cell tumor of the cervical spine. Case report. J Neurosurg 77:952-955, 1992
- 5) Mirra J M, Finerman G, and Lindholm S: Diffuse pigmented villonodular synovitis in association with Paget's disease of bone. Report of a case. Clinical Orthopaedics and Related Research. 149:305-9, 1980
- 6) Schiller AL: Tumors and tumor-like lesions involving joints, in Kelley WN, Harris ED, Ruddy S, et al. (ed): Textbook of Rheumatology, ed 3. Philadelphia: WB Saunders, 1989, Vol 2. pp 1775-1797