

Multifocal Medulloblastoma: A Short Report

Multifokal Medulloblastom: Kısa Bir Sunum

SAFFET TÜZGEN, MEHMET YAŞAR KAYNAR, TANER TANRIVERDİ,
AHMET HİLMİ KAYA, EMİN ÖZYURT

University of Istanbul, Cerrahpaşa Medical Faculty, Department of Neurosurgery (ST, MYK, TT, AHK, EÖ)

Received : 24.12.2001 ⇔ Accepted : 5.3.2002

Abstract: Objective: Medulloblastoma is one of the most common primary tumor of the central nervous system in childhood and is uncommon in adulthood. They are usually unilocular. Multifocal localization in cerebellum is very rare and only 3 cases were found to be reported in the literature. The aim of this report is to describe a 35-year-old female with multifocal cerebellar medulloblastoma.

Methods: The patient underwent right paramedian suboccipital craniectomy for biopsy and pathological diagnosis.

Results: The pathological diagnosis was medulloblastoma and the patient was sent to Radiologic-Oncology Clinic for radiotherapy. The patient died after 20 days of the radiotherapy.

Conclusion: We have concluded that the lesions in this patient may be due to the interruption of the migration of the embryological cells from the external granular layer.

Key Words: Cerebellar, medulloblastoma, multifocal

Özet: Amaç: Medulloblastom, çocukluk çağında en sık görülen primer merkezi sinir sistemi tümörüdür. Erişkin yaşlarda nadir görülür. Genellikle tek taraflıdır. Serebellumda multifokal yerleşim nadirdir ve literatürde sadece 3 vaka bildirilmiştir. Bu yazının amacı multifokal serebellar medulloblastom saptanan 35 yaşındaki bayan hasta tanımlanmaktadır.

Yöntem: Hastaya, biyopsi ve patolojik tanı için sağ paramedian suboksipital kraniyektomi yapıldı.

Bulgular: Patolojik tanı medulloblastom olarak belirlendi ve hasta radyoterapi için Radyasyon-Onkoloji Kliniği'ne gönderildi. Radyoterapinin 20. gününde hasta kaybedildi.

Sonuç: Bu hastadaki lezyonların, embriyolojik hücrelerin dış granüler tabakadaki migrasyon bozukluğundan kaynaklandığı sonucuna vardık.

Anahtar Kelimeler: Serebellar, medulloblastom, multifokal,

INTRODUCTION

Although medulloblastomas are rarely seen in adult age, they are more common in childhood age and originated from the embryological cells located in the roof of the 4th ventricle (2,5). About 74 percent of these tumors are located in the midline of the cerebellum and may enlarge into the 4th ventricle and cisterna magna or both. Medulloblastomas are

generally unilocular. With the exception of leptomeningeal involvement, there has been only 3 cases of multifocal cerebellar medulloblastoma reported in the literature (2,8,9).

The purpose of this study is to describe another case of medulloblastoma which had two different locations involving both hemisphere of cerebellum.

CASE REPORT

N.C. 35-year-old woman. She has been complaining headache and had tinnitus for about two years. About two weeks ago, her headache became worse and she had also nausea and neurological examination indicated that cerebellar tests were normal and there were no any pathological signs related to the cranial nerves and pyramidal system. Cranial CT showed two different contrast-enhancing lesions in both cerebellar hemispheres. There was no hydrocephaly. Cranial MRI showed two different lesions on cortico-subcortical location laterally in both cerebellar hemispheres. The lesions had cystic components and showed heterogenous contrast-enhancement. On T1-weighted MR scan, they showed low intensity but on T2-weighted MR scan they showed high intensity (Figure 1). The vermis was intact.

The patient was operated on sitting position and a right paramedian suboccipital craniectomy was performed. Subcortical cystic lesions were aspirated. Specimens from the nodular part of the lesion from both hemisphere and the wall of the cyst from the right hemisphere were removed for pathological diagnosis. The pathology was neuroectodermal tumor 'medulloblastoma' which had hyperchromatic chromatin, scanty cytoplasm and Homer-Wright type rosettes. (Fig.2) There were no any metastatic lesions in spinal and supratentorial locations seen on spinal and cranial MRI scans. We did not perform any other radical surgical treatment and the patient was sent to the Radiologic-Oncology Department for radiotherapy. After 20 days of the radiotherapy, the patient died.

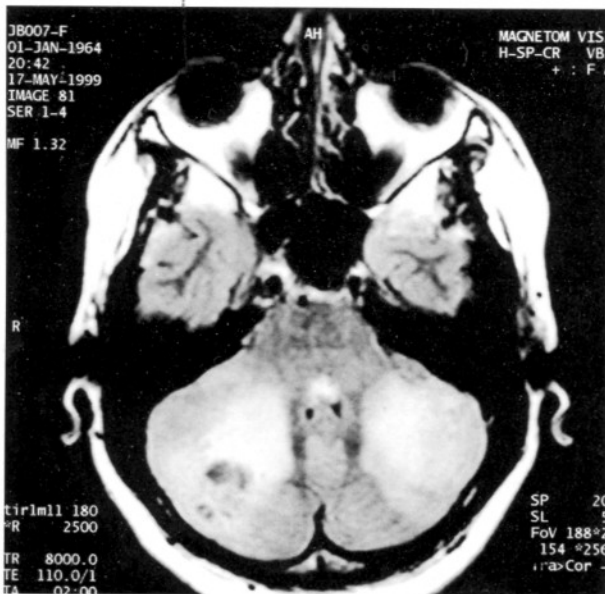


Fig.1a: Axial T2-weighted MR scan shows, hyperintens cortico-subcortical lesions on both cerebellar hemispheres. There is no midline involvement.

DISCUSSION

Medulloblastomas are the tumor of the childhood age and account for 30 percent of all intracranial tumors in children (3). They are less commonly seen in adults (1% of all intracranial tumors, 25-34% of all medulloblastomas) (1,4,6). About 75% of them usually arise from the midline and bulge into the 4th ventricle. In older children and adults, half of them are located in the cerebellum and about 30% have cystic components. Tumor margins are less well defined. Two-thirds of the tumor shows involvement of the central nervous system (CNS). Metastasis occur by the way of CSF and Virchow-Robin spaces (6). They are generally unilocular and multifocal involvement is rare. We have found only three cases in the literature

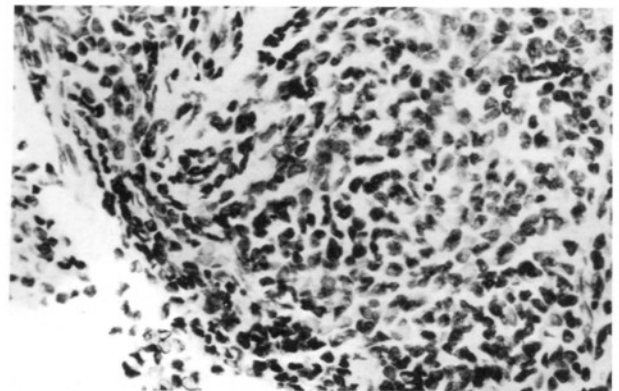


Fig.2: The infiltration of primitive, round cell tumor on cerebellar tissues. (HE x 200).

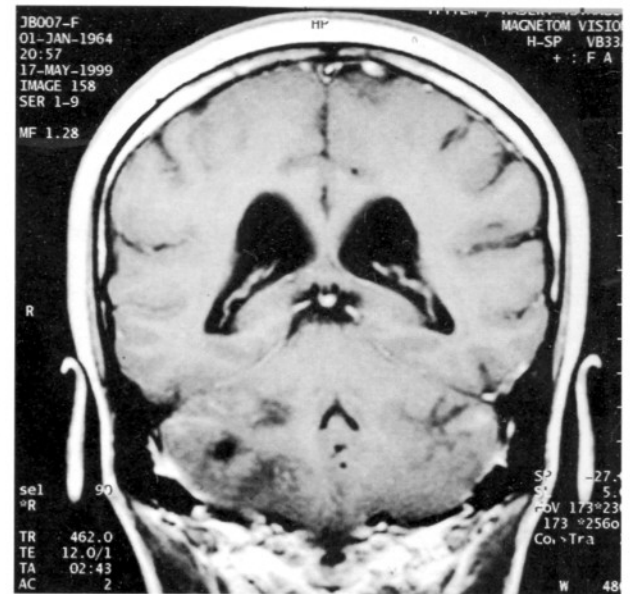


Fig.1b: Post-contrast T1-weighted coronal MR scan shows, 2 different lesions on both cerebellar hemispheres. They have heterogenous contrast enhancement and cystic components. Vermis is intact.

(2,8,9). In our case, there were two different lesions on both cerebellar hemispheres.

On MRI; contrast enhancement shows variability. Heterogeneous patterns are the rule and following contrast administration, medulloblastomas show partial contrast enhancement. They are heterogeneously hypointense to gray matter on T1-weighted and hypo-hyperintense on T2-weighted images.

In adults, they may resemble meningioma. Especially in frozen sections, due to the resemblance of histological appearance, they may be confused with the metastasis of the small cell lung carcinomas (7). On the MR scan of our case, the lesions located on both cerebellar hemispheres, had cystic components and the tumor margins were not well-defined. Thus, we did not firstly consider medulloblastoma.

The treatment of choice is surgical debulking of as much tumor as possible followed by radiotherapy and chemotherapy (3). In our case, due to the involvement of both cerebellar hemispheres, we only excised the tumor from the necrotic and contrast enhancing portions for pathological diagnosis by lateral suboccipital craniectomy. Microscopically, we have found medulloblastoma, then the patient was sent to radiotherapy.

Shen et al. (8) and Spagnoli et al. (9) could not explain completely the multifocal medulloblastoma in cerebellum. These two authors could not decide that, these lesions occur at the same time or by the cerebrospinal fluid (CSF) seeding. But Gliomroth et al. (2) have reported that, in addition to cerebellar localization, since there was occipital lesion, CSF-seeding could be the cause.

In our case, lesions were located in cortico-subcortical area, vermis was intact and no any pial involvement out of the cerebellum. So we did not consider metastatic lesion. We have supposed that, the lesions may have two different tumor focuses. It is thought that, medulloblastomas arise from the embryological cells located roof of the 4th ventricle and

if they have multifocal cerebellar involvement, we have concluded that, the lesions may be due to the interruption of the migration of the embryological cells from the external granular layer.

Correspondence: Dr. Taner Tanrıverdi
Istanbul Üniversitesi,
Cerrahpaşa Tıp Fakültesi,
Nöroşirürji ABD
PK: 4, Cerrahpaşa, İstanbul, TURKEY
Tel: 0212-632 00 26
Fax: 0212 632 00 26
e-mail: tanerato2000@yahoo.com

REFERENCES

1. Giordana MT, Schiffer P, Lanotte M, Girardi P, Chio A: Int J Cancer 80(5):689-92, 1999
2. Gliomroth J, Kehler U, Knopp U, Reusch E, Nowak G: A Multifocal Cerebellar and Supratentorial Medullablastoma in an Adult. Acta Neurochir 140: 723-24, 1998
3. Gold DR, Packer RJ, Cohen BH: Treatment strategies for medulloblastoma and primitive neuroectodermal tumors. Neurosurg Focus 7 (2): 1-23, 1999
4. Koci TM, Chiang F, Mehringer CM, et al: Adult cerebellar medullablastoma: imaging features with emphasis on MR, AJNR 14: 929-939, 1993
5. Marlin AE, Gaskill SJ: Cerebellar Medulloblastoma. In Rengachary SS, Wilkins RH (eds) Neurosurgical Operative Atlas Vol.1, Park Ridge, Illinois, AANS, 1991: 189-196
6. Osborn GA: Meningiomas and other nonglial neoplasms (in) Diagnostic Neuroradiology. Mosby, St. Louise, 579-625, 1994
7. Ramsay DA, Bonnin J, MacDonald DR, Assis L: Medulloblastomas in late middle age and the elderly: report of 2 cases. Clin Neuropathol 14(6): 337-42, 1995
8. Shen WC, Yang CF: Multifocal Cerebellar Medullablastoma: CT Findings. Journal Comp. Asis. Tomography 12(5): 894-902, 1988
9. Spagnoli D, Tomei G, Masini B, De Santes A, Grimoldi NJ, Lucarini C, Gaini SM: A case of multifocal cerebellar medulloblastoma in an adult patient. J Neurosurg Sci 34: 323-325, 1990

Adv Anat Pathol 2002 Nov;9(6):345-50

Medulloblastomas With Favorable Versus Unfavorable Histology: How Many Small Blue Cell Tumor Types are There in the Brain?: On: Histopathologic grading of medulloblastomas. A pediatric oncology group study. Eberhart CG, Kepner JL, Goldthwaite PT, et al. Cancer 200294:552-560.

Perry A.

Prognostically favorable and unfavorable variants of medulloblastoma have recently been identified, corresponding to medulloblastoma with extensive nodularity and large cell/anaplastic medulloblastoma, respectively. Significant anaplasia (moderate to severe) was identified in 24% of cases and was strongly associated with decreased survival times. Additionally, those with diffuse or extensive anaplasia fared worse than those with only focal anaplasia. Medulloblastoma grading based on anaplasia demonstrated a statistically stronger association with patient outcome than clinical staging. Therefore, histologic grading of medulloblastomas seems warranted as a routine diagnostic aid.